

Original Paper

Technique of Papineau in the Management of Chronic Osteomyelitis in a Low Setting Area. A 12 Years' Experience

Stanislas Ntungila Nkama¹ & Michel Lelo Tshikwela^{2*}

¹ Department of Surgery, Kinshasa University School of Medicine and Hospital, Kinshasa, Democratic Republic of the Congo

² Department of Radiology, Kinshasa University School of Medicine and Hospital, Kinshasa, Democratic Republic of the Congo

* Prof. Michel Lelo Tshikwela, Department of Radiology, Kinshasa University School of Medicine and Hospital, Kinshasa, Democratic Republic of the Congo

Received: April 7, 2020

Accepted: April 14, 2020

Online Published: May 11, 2020

doi:10.22158/rhs.v5n2p19

URL: <http://dx.doi.org/10.22158/rhs.v5n2p19>

Abstract

Introduction: Chronic osteomyelitis, a bone infectious pathology is difficult to treat. The authors report their experience in a series of patients treated in a low-income country.

Methods: We report a prospective study of 53 patients suffering of chronic osteomyelitis for a long time, covering our experience between January 1998 to December 2010 at the Kinshasa University Hospital in central Africa. We used the technique described by Papineau with success, until the consolidation of the bones and the drying up of the wounds.

The following elements were analyzed and taken into account: age and sex of the patients, sites involved, germs, surgical technique, length of stay in the hospital and estimated cost of the treatment.

Result: The majority of patients were between 26 and 35 years old with extremes between 15 and 80 years old, with 34 males and 19 females with a sex ratio of 1.7/1. Upper limb was involved with 7 humerus, 6 radius, 6 cubitus and the lower limb with 14 femurs and 20 tibias. *Staphylococcus aureus* was the germ most found in cultures from dead bone from intraoperative technique. Stay in hospital on average was 17 weeks for upper limb and 28 weeks for the management of lower limb injuries. The average cost for the treatment was estimated for 700 to 800 dollars.

Conclusion: Chronic osteomyelitis is a tenacious condition for long-term evolution, but it is nevertheless encouraging to dry up foci, which were the toughest challenges for orthopedics and plastic surgeons. In a low setting region, the management of the disease remains a condition with a

high economic cost and it is absolutely useless to begin a Papineau treatment if the patients do not have enough money.

Keywords

Chronic osteomyelitis, Papineau technique, low-setting region

1. Introduction

Chronic osteomyelitis is a long standing infection involving bones, leading to necrosis and destruction bone and bacterial colonies in protein/polysaccharide matrix (Rao, Ziran, & Lipsky, 2011; Shearer & Lowenberg, 2017). Its treatment remains a problem, because it's very expensive to afford for families or for healthcare providers (Stein & Lerner, 2001). Infrequent in Western, the disease is more observed in the Third World because of the late diagnostic and inadequate treatment (Bahebeck et al., 2002; Ikpeme, Ngim, & Ikpeme, 2010). Various surgical techniques exist and in this paper, we described ours 12 years experience in the management of the disease using the Papineau technique (Papineau, Alfagsseme, Dalcourt, & Pion, 1973; Panda, Ntungila, Kalunda, & Hensenkamp, 1998) at the University Hospital in central Africa.

2. Material and Methods

This is a prospective, monocentric study including 53 patients suffering of chronic osteomyelitis for a long time. The study took place from January 1998 to December 2010 and was conducted in Kinshasa University Hospital as described above. There were 34 males and 19 females, with age ranged from 15 to 80 years old and an average age of 18 years. The bones involved for upper limb were 7 humerus, 6 radius and 6 cubitus, and for lower limb, 20 tibias and 14 femurs. The aetiology was post-traumatic, haematogen and sickle cell disease. Many patient were excluded of the study because as they didn't fulfill the diagnostic criteria. To be included in the study item, patients have to manifested clinical signs, radiographic lesions, pass to Papineau treatment, stay in hospital until the end of treatment.

All the patients were classified in Cierny-Mader staging 2 and 3, presenting clinically with warm and limb tumefaction with fistula, including a full blood count, erythrocyte sedimentation rate, and C-reactive protein. In addition, the patients underwent X-ray to provide data on the site of the osteolytic lesion and periosteal thickening, the presence or absence of a sequestra and it size (Figure 1).

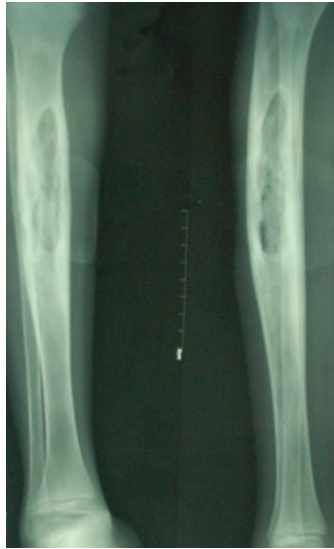

Figure 1. Frontal and Lateral Radiographs of the Tibia and Fibula with a Large Hypodense Lesion and a Sequestra Inside the Tibia

The patients were treated using the Papineau technique consisting of open wide resection of all the bone sequestra (Figure 2).

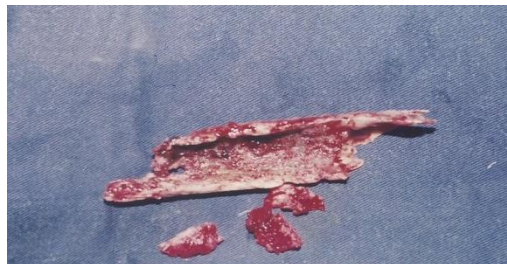

Figure 2. Picture of Some Sequestra Removed from the Infectious Foci

It will leave a gap with margin viable bone, with the preservation of the posterior bone cortex, which is no longer mechanically stable. The immobilization of the affected limb is done (Stein & Lerner, 2001). The cavity was then cleaned with Dakin's solution and saline serum. The dry cavity was packed with vaseline gauze, and covered with dry dressing applied in slight compression. We inspected the wound after 5 days. If the dressing became soiled, we changed it without disturbing the Vaseline gauze pack. When this was removed, there was fresh bleeding and the bone surface was covered with granulations tissues. After this first step, we proceed to the second step. It is performed by cleaning the cavity and then completely filled with fragments of cancellous bone as seen in Figure 3.

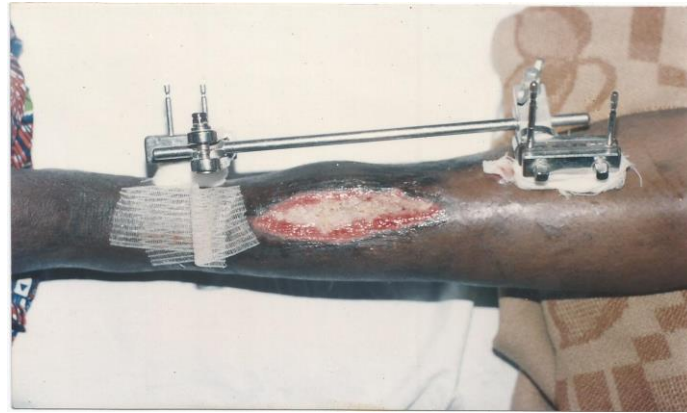

Figure 3. Picture of the Wound Completely Filled with Fragments of Cancellous Bone, and the Limb Immobilized by Hoffman Fixators

Daily drip irrigation of the grafts started using 1 liter of saline for 2 hours a day, for 45 days until the grafts were incorporated within the granulation tissue. Skin cover will be achieved by spontaneous healing or by a third step consisting of skin grafting. Radiography was necessary to control cavity and to decide when the immobilisation would be discarded and the limb might be allowed to bear weight.

3. Results

3.1 Age and sex

Fifty three patients with a mean age of 18 years were included in the study. The majority of patients were between 26 and 35 years of age with extremes between 15 and 85 years, with 34 Males and 19 Females (Figures 4 and 5).

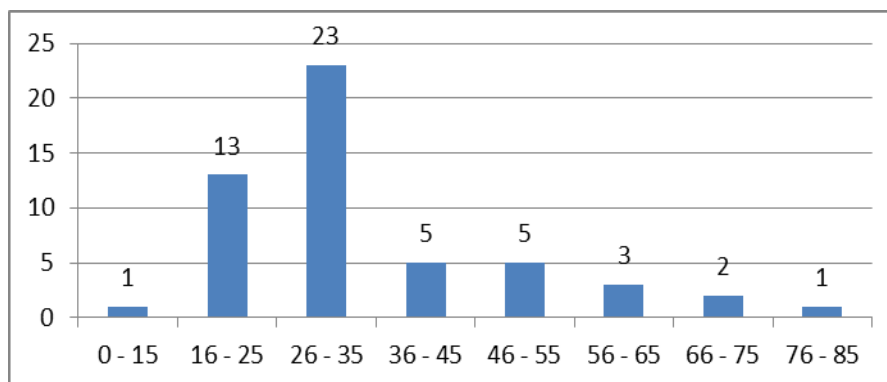


Figure 4. Age of the Patient

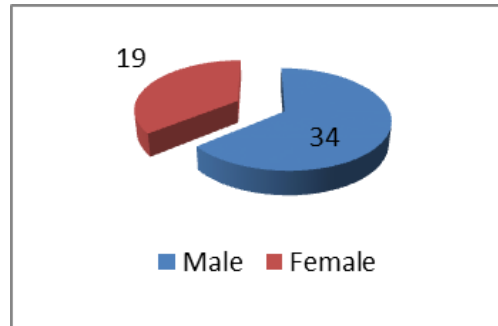


Figure 5. Characterization of the Sex. There were 34 Males and 19 Females with a Sex Ratio de 1.7/1

3.2 Sites of the Lesions

Table 1. Upper Limb with 19 Cases: 7 Humerus: 6 Radius and 6 Cubitus. Lower Limb with 34 Cases: 14 Femurs and 20 Tibias

Bone	Number of case	%
Hum érus	7	13,2
Radius	6	11,3
Cubitus	6	11,3
F énur	14	26,4
Tibia	20	37,7
Total	53	100

3.3 Bacteriology

Staphylococcus aureus was the germ most found in ours patients cultures from dead bone taken through open surgical biopsy.

We use 30 days of antibiotherapy against staphylococcus. Fifteen days after the sequestrectomy and for a similar period after bone grafting.

Length of stay in hospital was of an average around 17 weeks for upper limb and 28 weeks for treatment of lower limb injuries and the estimated cost was more than 700 to 800 dollars.

4. Discussion

The age of the patients in this study was between 26 and 35 years old with extremes between 15 and 80 years old. It is of 44, 5 years old (24-68 years old) for Deng et al. in China in 2012 (Deng, Cai, Jin, & Ping, 2014) and between 16 and 50 years old for Masquelet et al. (2012) serie in France in 2011. The explanation is that this is a group of active population.

In our series, males were more involved. It is the same for Saleh, Kreibich and Ribbans (1966), Bauer, Litellier, Mamoudy and Lortat-Job (n.d.) and Garcia Del Poz, Collazos, Carton, Camporro, Asensi (2018). Our explanation is that males develop more trauma than females.

The Upper limb was involved with 19 cases and the lower limb with 34 cases and the most frequent locations were the tibia 20 times and the femur 14 times. Our data corroborate with the literature except for the ulna, which seems to be less affected than the radius for most authors. Tibia is more involved because it is just under the skin.

In this series, staphylococcus aureus was the germ most found in cultures from dead bone taken per op. It is known that the correct identification and isolation of the causative micro-organisms is mandatory for effective antibiotic treatment (Stein & Lerner, 2011; Maffuli, Papalia, Zalpogna, Torre, Albo, & Denaro, 2016). Saleh et al., Bauer et al. found also staphylococcus aureus in their series.

In our hospital, we use the technique of Papineau. Parsons and Strauss (2004) reported the Ilizarov frame has been used successfully in treatment of large defects resulting from debridement of osteomyelitis. He cited the series of Green and Marsh et al which reported results of patients treated with Ilizarov techniques versus patients treated with Papineau bone grafting and external fixation. Similar rates of healing and time in fixators were found for both groups. Aso Paley et al cited by Parson, reported 100% union and 76% successful resolution of infection in 13 patients with infected nonunions of the tibia. No bone graft was necessary in any patient for filling the defect after debridement. Staged surgical treatment is common, with repeated debridement and delayed skin closure. Further operations may be required to remove polymethylmethacrylate (PMMA) antibiotic-loaded beads or to reconstruct bone defects.

Recently, Mc Nally et al. (2016) reported a large series of patients, managed with a single-stage protocol, facilitated by the use of CERAMENT G as a bioabsorbable dead space filler.

This protocol delivered low recurrence rates with few re-operations or complications over a one- to three-year follow-up period. Their initial experience shows that this offers a patient-friendly treatment which merits further study.

In our series, the percentage obtained after Papineau (99%), remains a solution for those chronically ill patients who find the joy of going to their business. An obvious consolidation of the treated bone is a satisfaction for us and especially for the patient and his family with good healing of bone and soft tissue (Figure 6) escaped from amputation otherwise.

Concerning medical treatment, chronic osteomyelitis is a relatively common infection and is often a lifelong disease. Many protocol exist: three months for Bauer, 1 to 1.5 months for Mac Nally. Traditionally, osteomyelitis has been treated with 4-6 weeks of parenteral antibiotics after definitive debridement surgery. There is no solid evidence in the medical literature to support the continuous use of long duration antibiotic treatment. The medical literature, including studies in animals and humans, was searched for evidence to support the use of short courses of antibiotics (Haidar, Der Boghossian, & Ayyiyeh, 2010). In our experience, we use antibiotics for 4 weeks.

Hospitalization time was 23 weeks for Saleh et al. Our average time was around 17 weeks for upper limb and 28 weeks for treatment of lower limb injuries.

The prognosis is depending of authors and technique used (Bauer, Litellier, Mamoudy, & Lortat-Job, n.d.). Anyway, in our series, the percentage obtained after Papineau (99%), remains a solution for those chronically sick patients who find the joy of walking like everyone else and going about their business. An obvious consolidation of the treated bone is a satisfaction for us and especially for the patient and his family with good repair of bone and soft tissue (Figure 6) otherwise amputation.

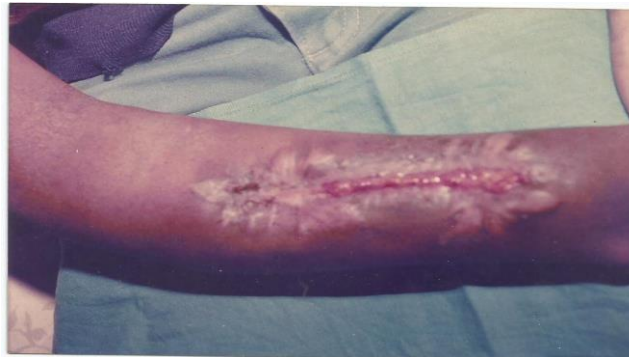

Figure 6. Picture of Skin Covering the Wound

More than 700 to 800 dollars for the treatment can't be afforded by a low income population such as in sub-Saharan Africa. And we deplore the high number of patients lost; the cost of the treatment added to the long stay in hospital seemed prohibitive. Therefore, many patients are pushed to find and to consult traditional physicians; unfortunately unqualified for the matter.

Limitations of the study. There are some limitations in this study. The first bias might be the small sample size of this monocentric study and the second, many factors may be associated with chronic osteomyelitis as diabetes mellitus, obesity, smoker, alcohol drinker were not taken into consideration in the study. Despite these limitations, this study carried out in low income country and based on local experience seems to be the first one as far as we are aware. It provides valuable information on the chronic osteomyelitis and its treatment by the technique of Papineau in austere environment.

For future study, each of these biases should be taken into consideration to demonstrate scientifically an estimate significance and robustness of the findings of this technique in a poor country. It may have an important clinical implication suggesting that even the evidence is not sufficiently robust to identify the most effective treatment of chronic osteomyelitis in low-income countries (Geurts, Hohnin, Vranken, & Moh, 2017), the technique of Papineau may be appropriate and effective.

5. Conclusion

For our 12 years' experience in the treatment of chronic osteomyelitis using Papineau technique, we can conclude that osteomyelitis is a chronic disease which is not easy to treat. The technique of

Papineau help to promote the bone union, to dry the wound and then to prevent amputations. However, this technique requires a high economic cost that the patients and their families are not ready to support in our region.

References

- Bahebeck, J. et al. (2002). The treatment of hematogene chronic osteomyelitis of children in 49 patients at Yaounde, Cameroon. *Rev. Med. Suisse*, 2, 22638.
- Bauer, T., Litellier, L., Mamoudy, P., & Lortat-Job. (2007). Infection on continuous bone of the lower limb: 127 cases. *Revue de chirurgie orthopedique*, 807-817.
- Deng, Z. M., Cai, L., Jin, W., & Ping, A. S. (2014). One-stage reconstruction with bone grafting and vacuum assisted closure for infected tibia and vacuum assisted closure for infected tibia. *Arch Med Sci.*, 10(4), 764-772. <https://doi.org/10.5114/aoms.2013.34411>
- Garcia Del Poz, E., Collazos, J., Carton, J. A., Camporro, D., & Asensi, V. (2018). Bacterial osteomyelitis: Microbiological, clinical, therapeutic and evolutive characteristics of 344 episodes. *Rev Esp Quimioter*, 31(3), 217-225.
- Geurts, J., Hohnin, A., Vranken, T., & Moh, P. (2017). Treatment strategies for chronic osteomyelitis in low and middle- income countries: Systemic review. *Trop med Int health*, 22, 1054-1062. <https://doi.org/10.1111/tmi.12921>
- Haidar, R., Der Boghossian, A., & Ayiyeh, B. (2010). Duration of post surgical antibiotics in chronic osteomyelitis: Empiric or evidence-based. *Int J Infect dis.*, 14(9), e752-758. <https://doi.org/10.1016/j.ijid.2010.01.005>
- Ikpeme, Ngim, N. E., & Ikpeme, A. A. (2010). Diagnostis and treatment of pyogenic bone infection. *Afr Healt Sci.*, 10(1), 82-85.
- Maffuli, N., Papalia, R., Zanzogna, B., Torre, G., Albo, E., & Denaro, V. (2016). The management of osteomyelitis in the adults. *Surgeon*, 14(6), 345-360. <https://doi.org/10.1016/j.surge.2015.12.005>
- Masqueleta, A. C. et al. (2012). Reconstruction of post-traumatic diaphyseal bone defects: Preoperative planning, guideline, and future developments. *Revue de Chirurgie orthopedique et traumatique*, 98, 94-103.
- McNally, M. A. et al. (2016). Single-stage treatment of chronic osteomyelitis with new absorbable gentamicin-loaded calcium sulfate/hydroxyapatite biocomposite. *Bone joint J.*, 98-B, 1289-1296. <https://doi.org/10.1302/0301-620X.98B9.38057>
- Panda, M., Ntungila, N., Kalunda, M., & Hensenkamp, M. (1998). Treatment of chronic osteomyelitis using Papineau technique. *Int Orthopaedics*, 22, 37-40. <https://doi.org/10.1007/s002640050204>
- Papineau, L. J., Alfagssese, A., Dalcourt, J. P., & Pion, L. (1973). Chronic osteomyelitis: Open excision and grafting after saucerisation. *International Orthopaedics*, 3(3), 165-176.
- Parson, B., & Strauss, E. (2004). Surgical management of chronic osteomyelitis. *American J of Surgery*, 188, 57S-66S. [https://doi.org/10.1016/S0002-9610\(03\)00292-7](https://doi.org/10.1016/S0002-9610(03)00292-7)

- Rao, N., Ziran, B. H., & Lipsky, B. A. (2011). Treating osteomyelitis: Antibiotics and surgery. *Plast Reconstr surg*, 127(suppl 1), 1775-1875. <https://doi.org/10.1097/PRS.0b013e3182001f0f>
- Saleh, M., Kreibich, D. N., & Ribbans, W. J. (1966). Circular frames in the management of infected tibial non-union: A modification of Papineau technique. *Injury*, 27(1), 31-36. [https://doi.org/10.1016/0020-1383\(95\)00164-6](https://doi.org/10.1016/0020-1383(95)00164-6)
- Shearer, D., & Lowenberg, D. (2017). *G19 Osteomyelitis: physiopathology and treatment Decisions 2017*. Osteomyelitis-Orthopaedic Trauma Association. Retrieved from <https://www.ota.org>
- Stein, H., & Lerner, A. (2001). Advances in the treatment of chronic osteomyelitis. *Current Orthopaedics*, 15, 451-456. <https://doi.org/10.1054/cuor.2002.0233>