

Original Paper

Are We over Dissecting the Cord in Orchidopexy?

Hashem Mohammad Al-Momani¹, M.D., Ahmad Aliwisat², M.D., Ibrahim Abdel Qader Khrais^{3*}, M.D., Osama Sarhan³, M.D., Ibraheem Suleiman Obaidat³, M.D., Nadeem Riyad Al Jundi³, M.D. & Fadi Atef Alhalasa⁴, M.D.

¹ Professor of Pediatric Surgery, Faculty of Medicine, University of Jordan; Consultant pediatric surgeon, Jordan University Hospital, Amman, Jordan

² Pediatric Surgery Fellow, Jordan University Hospital, Amman, Jordan

³ General Surgery Resident, Jordan University Hospital, Amman, Jordan

⁴ ENT Resident, Jordan University Hospital, Amman, Jordan

* Ibrahim Abdel Qader Khrais, M.D., School of Graduate Studies, University of Jordan, Queen Rania Al-Abdullah Street, Aljubeiha / P.O. Box: (13046) Amman (11942), Jordan

Received: February 28, 2020

Accepted: March 8, 2020

Online Published: July 2, 2020

doi:10.22158/rhs.v5n3p16

URL: <http://dx.doi.org/10.22158/rhs.v5n3p16>

Abstract

Background: *Orchidopexy is a procedure of securing the testis inside the scrotum in patients with cryptorchidism. In the literature, various dissection techniques have been described to lengthen the spermatic cord to ensure a tension-free fixation of the testis to the lowest point of the scrotum.*

Objectives: *The aim of this study is to determine if incorrect measurement of the spermatic cord's length during open inguinal orchidopexy had led surgeons to over dissect the cord in a way that may pose an increased risk of testes, vas deferens and spermatic vessels.*

Materials and Methods: *We prospectively studied the results of 40 orchidopexies performed in 40 patients with peeping or canalicular undescended testis, which was done at the Jordan university hospital in Amman from April 2018 to March 2019, We compared the position of the testis before and after tunneling inside the inguinal canal. The difference in length is measured and analyzed.*

Conclusion: *Failure to account for the subcutaneous fat layer thickness during orchidopexy increases the likelihood of over dissecting the spermatic cord which increases the risk of vas and vessels injury. In this study we found that there is a difference between the cord length outside and inside the canal with excess length after passing the cord inside the canal ranges from 1-3 cm. This means that we do not need to dissect the cord to make the testis reaches the scrotum from outside. This decreases the risk of harming the cord and its contents.*

Keywords

Cryptorchidism, Undescended testis, Inguinal Orchidopexy, Pediatric Surgery

1. Introduction

Cryptorchidism (from the Greek *kryptos*, meaning “hidden”, and *orchis*, meaning “testis”) or undescended testis (UDT) is one of the most common congenital anomalies of the genitourinary tract in males and is diagnosed in 3-8% of term males (Virtanen & Toppari, 2008). Boys with this condition are predisposed to infertility and testicular cancer (Pinczowski, McLaughlin, Lackgren, Adami, & Persson, 1991; Chung & Brock, 2001). Other well-known long-term consequences include hernia, testicular torsion, and mental stress. UDT may involve one or both of the testes and is bilateral in approximately 10% of the cases.

Although Cryptorchidism is a common problem, treatment recommendations are variable. However, surgery is still considered the gold standard treatment with many surgical approaches described in the literature (Gapany et al., 2008). The aim of any orchidopexy is to provide enough spermatic cord length to ensure a tension-free fixation of the testis to the lowest point of the scrotum without endangering the blood supply to the testis.

In our study, we review the relevant anatomy and discuss the surgical technique to avoid over dissecting the spermatic cord.

2. Procedure Description

Open inguinal orchidopexy is normally performed under general anesthesia. The patient is placed in a supine position with the legs slightly abducted and feet together. The lower abdomen, penis, scrotum, and upper thighs are prepared with aqueous Betadine®.

The pubic tubercle and anterior superior iliac spine are identified. A 2 to 3 cm horizontal skin incision is made one finger width above the inguinal ligament and just lateral to the pubic tubercle. The incision is extended through the subcutaneous fat and Scarpa’s fascia. The thickness of the subcutaneous fat layer is measured at this point.

The external oblique aponeurosis is opened. Care must be taken not to accidentally injure a testis that may be located in the superficial inguinal pouch rather than the inguinal canal. Once the testes is identified, the testis and spermatic cord are mobilized by releasing the attachments to the internal spermatic fascia and cremasteric muscle and circumferential freeing of the vessels up to the level of the internal ring. Dissection is continued into the retroperitoneum to achieve maximal proximal length of the spermatic cord. The processus vaginalis is ligated if deemed necessary.

After completion of dissection, the testis and the spermatic cord are exteriorized through the inguinal incision and laid on the skin in the same anatomical position of the normally descended testes. The skin is marked at the most distal point of the exteriorized testis (Figure 1A). The spermatic cord and testes are then pulled down inside the newly created subcutaneous inguino-scrotal tunnel into the scrotum

through a scrotal incision. The distance from the most distal point of the tunneled testes to the skin marking is measured (Figure 1B).

Finally, the testis is fixated inside the newly created subdartos pouch and skin is closed. Dressing applied at the end of the procedure.

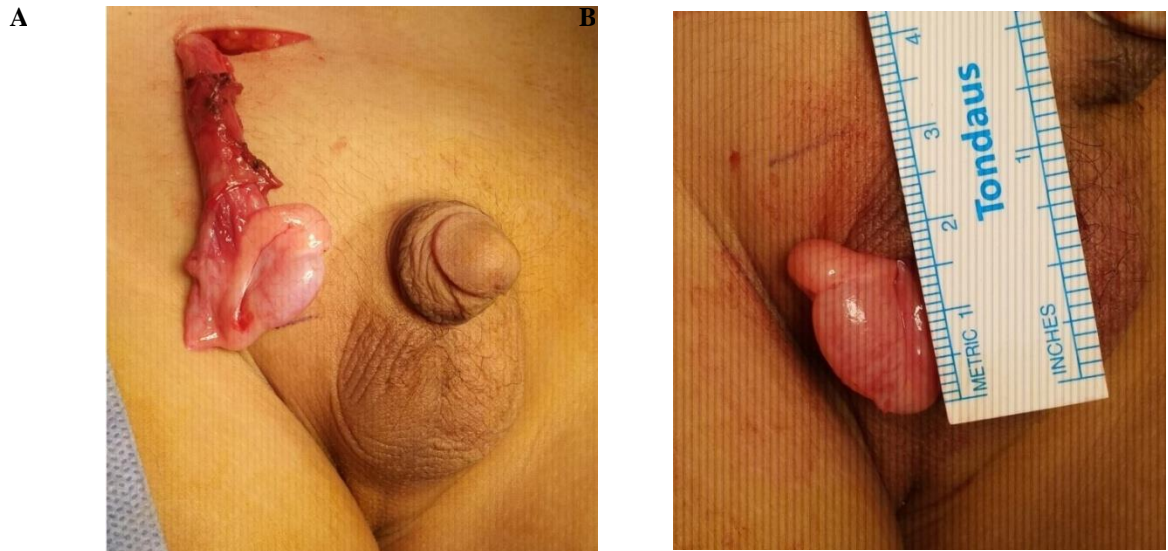


Figure 1. (A) The Most Distal Point of the Exteriorized Testis is Marked. (B) The Testis is Then Delivered through the Scrotal Incision and the Distance from the Most Distal End to the Skin Marking is Measured

3. Materials and Methods

This study provides a retrospective analysis of the prospectively collected data of a group of children with UDT who were referred to The Jordan University Hospital, Amman, Jordan. The patients included in the study were selected using a simple random sampling technique. The data of 40 patients who underwent elective open inguinal orchidopexy by a single pediatric surgery consultant for canalicular or peeping undescended testes was reviewed and analyzed. All patients with intra-abdominal, ectopic and retractile testes were excluded. All children had no history of systemic diseases and had not had any previous history of surgery. The basic demographic data of all patients including weight, height and age at time of surgery were collected. The subcutaneous fat layer thickness as well as the difference in length measured before and after tunneling the testes were measured during surgery in all cases as described above. The extra spermatic cord length gained after tunneling is compared to the thickness of the subcutaneous fat layer and other factors trying to find any predictive factor of this difference.

Finally, the collected data were entered into SPSS (version 24; SPSS Inc., Chicago, Ill., USA) and analyzed. Discrete variables are reported as numbers and percentages. Pearson's correlation is reported to measure the strength of relationship between variables. A two tailed P value of $< .05$ was considered

statistically significant.

The study was approved by the local ethical committee and an Informed consent was obtained from all patients enrolled in the study.

4. Results

40 male patients who underwent open inguinal orchidopexy for UDT were included. The mean age of the patients was 62 ± 40 months (Table 1). 16 (40%) patients had right UDTs, 11(28%) patients had left 1 UDT and 13 (32 %) patients had bilateral UDT. In the final analysis, only 40 orchidopexies were included as shown in Table 2.

Table 1. Demographic Data

	Mean
Age(months)	62.13
Weight (Kgs)	21.69
Height/Length (cm)	107.7
Subcutaneous fat thickness (cm) (SD)	1.13(0.57)
Spermatoc cord length difference (cm) (SD)	1.83(0.74)

In all cases, a significant difference was measured in the spermatoc cord length before and after tunneling the testes. In our cohort of patients, the extra length gained after the testis is tunneled into the scrotum ranged between 1 and 4 cm with an average of 1.8cm (Table 1).

Table 2. Cases Included in the Study

	Number (%)
Right	23(57.5%)
left	17(42.5%)

These results prove that improper measurement of spermatoc cord length during mobilization leads to over dissection of the spermatoc cord. However, there was no correlation between the thickness of the subcutaneous fat layer and the difference in spermatoc cord length ($r=0.053$, $p=0.745$) (Figure 2). A study with a larger number of patients may show a correlation.

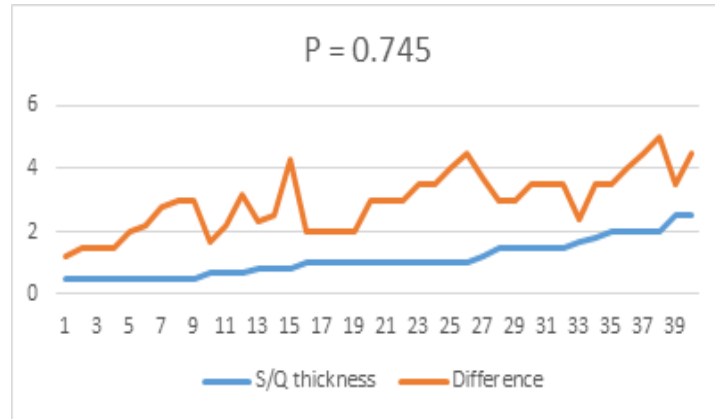


Figure 2. Correlation of SQ Thickness and Cord Length Difference

5. Discussion

During embryonic life, the testes form in the retroperitoneum beside the mesonephric kidneys and descend via the inguinal canal to the scrotum. Most of the time, they continue to descend during the first 3 months of life, and a small percentage remains for the next 9 months (Caruso, Walsh, Wolach, & Koyle, 2000). A disruption in any phase of testicular development may halt its descent along the normal path of descent (undescended or retractile testis), may travel off the normal path of descent (ectopic testis), or may die or never develop (absent testis). The primary goal of any orchidopexy is to bring the cryptoid testis down to its normal position within the scrotum while preserving its blood supply. The main limiting factor in most cases is mobilization of the retroperitoneal spermatic vessels which is mostly done by blunt dissection of the peritoneal attachments and cremasteric muscle fibers.

In the literature, the first accurate description of the abdominal position of the fetal testes was published in 1755 by Baron Albrecht von Haller in his work *Opuscula Pathologica*. However, it was the efforts of John Hunter that led to the identification of the neurovascular supply and attachments of the abdominally positioned fetal testis in 1762. The combined work of von Haller and Hunter led to the realization that the descent of the testes is guided by the gubernaculum and occurs around the 8th month of gestation (Patel & Caldamone, 2013).

The first recorded orchidopexy was performed by James Adams in 1871 (Adams, 1871). He tried to perform the surgery through a 1.5-inch incision made over the external ring for an 11-week child who presented with a perineal ectopic testis. He freed the spermatic cord and testis from any attachments and then fixated the testis into the scrotal pouch. Unfortunately, the patient developed a wound infection on postoperative day 3 that progressed to fatal peritonitis.

Six years after Adam's failed attempt, Thomas Annandale performed the first recorded successful orchidopexy in a 3-year child with a perineal ectopic testis and published it in 1879 in the "*The British Medical Journal*" (Annandale, 1879).

Since most of the UDT are located in the superficial inguinal pouch, the inguinal approach became the standard technique for performing orchidopexy (Annandale, 1879). When adequate spermatic cord

length could not be achieved after thorough dissection at the level of the inguinal canal and retroperitoneum, certain operative maneuvers such as those described by Prentiss in the 1950s and 60s have been shown to improve the final position of the testis by bringing the spermatic cord medial to the inferior epigastric vessels and thus straightening the course of the duct and vessels (Prentiss, Weickgenant, Moses, & Frazier, 1959). Distal spermatic cord peritoneal stripping is another maneuver that has been proposed to achieve additional length in cases when dependent scrotal position is not optimal (Swana, Patel, & Rich, 2015).

As shown, achieving a tension-free scrotal mobilization of the testis is the most challenging step of any orchidopexy procedure. The appropriate and conservative dissection of the spermatic cord is important to gain spermatic cord length without increasing the risk of devascularization and testicular atrophy.

However, from our experience with the open inguinal orchidopexy at our center, we noticed that inappropriate measurement of the spermatic cord was a leading cause for over dissection of the spermatic cord. The inappropriate measurement comes from the surgeon's failure to account for the subcutaneous fat layer thickness during spermatic cord dissection and mobilization.

6. Conclusion

Open inguinal orchidopexy is considered the standard approach for peeping and canalicular undescended testes. The testis and spermatic cord are mobilized by releasing the peritoneal attachments and the cremasteric muscle fibers. The mobilization ends when enough spermatic cord length is gained to ensure a tension-free fixation of the testes in the subdartous pouch of the scrotum. In our study we found that there is a difference between the cord length outside and inside the canal with excess length after tunneling ranging from 1-4 cm. This means that we do not need to dissect the cord to make the testis reaches the scrotum from outside. This decreases the risk of harming the cord and its contents.

References

- Adams, J. E. (1871). Remarks on a Case of Transition of the Testicle into the Perineum. *Lancet*. [http://doi.org/10.1016/S0140-6736\(02\)51041-2](http://doi.org/10.1016/S0140-6736(02)51041-2)
- Annandale, T. (1879). Case in which a testicle congenitally displaced into the perinæum was successfully transferred to the scrotum. *Br Med J*. <http://doi.org/10.1136/bmj.1.940.7>
- Caruso, A. P., Walsh, R. A., Wolach, J. W., & Koyle, M. A. (2000). Single Scrotal Incision Orchiopexy for the Palpable Undescended Testicle. *J Urol*. <http://doi.org/10.1097/00005392-200007000-00051>
- Chung, E., & Brock, G. B. (2011). Cryptorchidism and its impact on male fertility: A state of art review of current literature. *J Can Urol Assoc*. <http://doi.org/10.5489/cuaj.1010>
- Gapany, C. et al. (2008). Management of cryptorchidism in children: Guidelines. *Swiss Med Wkly*.
- Patel, S. R., & Caldamone, A. A. (2013). Complications of Orchiopexy. In *Complications of Urologic Surgery and Practice*. <http://doi.org/10.3109/9781420013955-20>

- Pinczowski, D., McLaughlin, J. K., Lackgren, G., Adami, H. O., & Persson, I. (1991). Occurrence of testicular cancer in patients operated on for cryptorchidism and inguinal hernia. *J Urol*. [http://doi.org/10.1016/S0022-5347\(17\)38071-0](http://doi.org/10.1016/S0022-5347(17)38071-0)
- Prentiss, R. J., Weickgenant, C. J., Moses, J. J., & Frazier, D. B. (1959). Undescended testis: surgical anatomy of spermatic vessels, spermatic surgical triangles and lateral spermatic ligament. *Trans West Sect Am Urol Assoc*.
- Swana, H. S., Patel, R., & Rich, M. A. (2015). Distal spermatic cord peritoneal stripping: An adjunct technique during inguinal orchiopexy. *Int Braz J Urol*. <http://doi.org/10.1590/S1677-5538.IBJU.2014.0499>
- Virtanen, H. E., & Toppari, J. (2008). Epidemiology and pathogenesis of cryptorchidism. *Hum Reprod Update*. <http://doi.org/10.1093/humupd/dmm027>