

Treatment of cutaneous wound using essential oil of *Varronia curassavica* Jacq in *Corallus hortulanus* – Case Report

Lourdes Marina Bezerra Pessoa¹, Guilherme Jones Souza², Paulo Roberto Bahiano Ferreira³, Marta Calasans Gomes⁴,
Cintia Ribeiro Manhães Vieira⁵, Leide Lene Coelho Ferreira⁶

1. Médica Veterinária (Universidade Estadual do Ceará, Brasil). Mestre em Saúde Animal (Universidade de Brasília, Brasil). Professora da Universidade do Estado da Bahia, Brasil.
marinapess@gmail.com <http://lattes.cnpq.br/7442357485013690> <http://orcid.org/0000-0001-5179-2894>
2. Biólogo (Faculdades Integradas Maria Thereza, Brasil). Mestre em Ensino de Ciências, Ambiente e Sociedade (Universidade do Estado do Rio de Janeiro, Brasil). Pesquisador do Instituto Vital Brazil, Brasil.
guilhermejones1@hotmail.com <http://lattes.cnpq.br/0543849251685709> <http://orcid.org/0000-0002-5774-2684>
3. Médico Veterinário e Mestre em Ciência Animal nos Trópicos (Universidade Federal da Bahia, Brasil).
paulomev@yahoo.com.br <http://lattes.cnpq.br/7377384609582609> <http://orcid.org/0000-0002-1677-4209>
4. Médica Veterinária (União Metropolitana de Desenvolvimento de Educação e Cultura, Brasil). Especialista em Clínica Médica e Cirúrgica em animais Exóticos e Silvestre criados como Pet (Qualitas-Instituto de Pós-Graduação, Brasil).
mcg234@oi.com.br <http://lattes.cnpq.br/5646878532529037> <http://orcid.org/0000-0003-0558-9144>
5. Bióloga (Universidade Estadual do Norte Fluminense Darcy Ribeiro, Brasil).
cintia.manhaes@gmail.com <http://lattes.cnpq.br/1684414885252172> <http://orcid.org/0000-0001-5293-4663>
6. Farmacêutica (Universidade Estácio de Sá, Brasil). Doutoranda em Ciências Farmacêuticas (Universidade Federal do Rio de Janeiro, Brasil). Pesquisadora do Instituto Vital Brazil, Brasil.
leide.farma@gmail.com <http://lattes.cnpq.br/0120158580089649> <http://orcid.org/0000-0003-4000-3575>

ABSTRACT

The skin is the organ very important for the reptiles, because it has a direct contact with external environment, it becomes more susceptible to injuries. The *Varronia curassavica* Jacq. is an important medicinal plant from which it is possible to extract essential oil used in the production of herbal medicines. This case report describes the successful treatment of cutaneous wound not induced in *Corallus hortulanus* using essential oil of *V. curassavica*. A free-ranging wild specimen of *C. hortulanus* was received by Fazenda Vital Brazil. Clinical examination revealed a skin laceration in the dorsal region of the animal's head. As the Farm has phytotherapeutic production, the used of the essential oil of *V. curassavica* for the treatment of the animal's injury. The treatment was accomplished using the topical application of essential oil of *V. curassavica* at 0.5% concentration, for 21 days, once daily. For a better fixation, the oil was incorporated into a hydrophobic ointment. The lesion was inspected daily and the 15th day of treatment, it was possible to observe the presence of connective tissue, fibroblastic phase and extracellular matrix deposition at the extremities towards the center of the lesion. The results shows that the essential oil of *V. curassavica* contributed positively with the healing process of cutaneous wound in *C. hortulanus*.

Keywords: herbal medicine; reptile clinic; phytotherapeutic; cutaneous wound; healing.

Tratamento de ferida cutânea usando óleo essencial de *Varronia curassavica* Jacq em *Corallus hortulanus* - Relato de caso

RESUMO

A pele é o órgão muito importante para os répteis, por ter contato direto com o ambiente externo, torna-se mais suscetível a lesões. O *Varronia curassavica* Jacq. é uma planta medicinal importante da qual é possível extrair o óleo essencial usado na produção de medicamentos fitoterápicos. Este relato de caso descreve o sucesso do tratamento de feridas cutâneas não induzidas em *Corallus hortulanus* usando óleo essencial de *V. curassavica*. Um espécime selvagem de *C. hortulanus* foi recebido pela Fazenda Vital Brazil. O exame clínico revelou laceração cutânea na região dorsal da cabeça do animal. Como a Fazenda possui produção fitoterápica, é utilizado o óleo essencial de *V. curassavica* para o tratamento da lesão do animal. O tratamento foi realizado com a aplicação tópica de óleo essencial de *V. curassavica* na concentração de 0,5%, por 21 dias, uma vez ao dia. Para uma melhor fixação, o óleo foi incorporado em uma pomada hidrofóbica. A lesão foi inspecionada diariamente e no 15º dia de tratamento, foi possível observar a presença de tecido conjuntivo, fase fibroblástica e deposição de matriz extracelular nas extremidades em direção ao centro da lesão. Os resultados mostram que o óleo essencial de *V. curassavica* contribuiu positivamente no processo de cicatrização de feridas cutâneas em *C. hortulanus*.

Palavras-chave: fitoterapia, clínica de répteis, fitoterapêutico, ferida cutânea, cura.

Introduction

Skin lesions in reptiles are caused by different factors and result in scarring and dysecdysis, predisposing to dermatitis. The skin exerts important functions for the animals (ARAUJO et al., 2015) and, because this organ has a direct contact with external environment, it becomes more susceptible to injuries. The loss of the continuity of the skin is called a cutaneous wound, being one of the most common problems in the veterinary clinic (RODRIGUES et al., 2013).

The healing is a necessary component of the repair process by providing the mechanisms which damaged tissue is prepared for reconstruction (GARROS et al., 2006). However, some complications during this process may arise, such as infection of the wound, excessive deposition of connective tissue, the chronification of a wound, among

others (SMITH et al., 2000). Thus, it is important to use therapeutic protocols to achieve a fast and controlled healing, reducing the chances of some negative manifestation that could endanger the animal's life or well-being (ARAUJO et al., 2016). For this reason, research is extremely relevant to identify and develop the best agents that promote healing. Within this context, the use of alternative medicines such as phytotherapeutics stands out.

Phytotherapy is the use of medicinal plants and their applications in cure of disease (LIMA et al., 2012). In a study to verify the effectiveness of medicinal plants in the treatment of captive snakes, the results showed that 12 plants tested were effective in controlling the endoparasites and ectoparasites, fungi, wounds and inflammations of 26 snake specimens tested in the study (DE ALBURQUERQUE et al.,

2004). *Varronia curassavica* Jacq., it has as synonyms *Cordia curassavica* (Jacq.) Roem. & Schult. and *Cordia verbenacea* DC (REFLORA, 2018), belongs to family Boraginaceae, occurs naturally from Central to South America, and in Brazil is associated with the Atlantic Forest (FEIJÓ et al., 2014; LORENZI et al., 2002). It is a medicinal plant traditionally used to treat inflammation, ulcers, arthritis, and pain (LORENZI et al., 2002).

Phytochemical studies revealed the presence of flavonoids, phenols and essential oils, responsible for its anti-inflammatory, antimicrobial and allergenic activities (PASSOS et al., 2007; COOPER, 2006), identifying as main active constituents alpha-humulene and beta-caryophyllene (COOPER, 2006). In this article we present the case of the successful treatment of cutaneous wound not induced in *Corallus hortulanus* using essential oil of *V. curassavica*.

Material and Methods

A free-ranging wild specimen of *C. hortulanus* captured in Guapimirim – RJ was received by Fazenda Vital Brazil (FVB), located in the municipality of Cachoeiras de Macacu - RJ, Brazil, presented a skin laceration approximately 2.5 cm diameter, with bleeding and cutaneous ulceration, in the dorsal region on the left side of the head. As the cutaneous wound had no infection area, and the FVB produce herbal products, it was decided to use essential oil of *V. curassavica* for the treatment of the lesion. For extraction of the essential oil, fresh leaves of *V. curassavica* were collected at the FVB and sent to the Laboratório de Pesquisa de Produtos Naturais (LPPN), located at Farm.

The oil was extracted by the steam-drag method using a Linax® distiller, in which it yielded 0.3% yield relative to the weight of fresh material. The exsicta is deposited in the Universidade Federal do Rio de Janeiro with registration number 39924. Analysis of the essential oil was performed by GC-MS in an Agilent 6890N gas chromatograph coupled to an Agilent 5973N quadrupole mass selective detector (70 eV, m/z 50-700), with DV-5MS fused silica capillary column (30m X 0.25mm X 0.25µm). Helium was used as carrier gas with a flow rate of 0.5 mL/minute. The injector temperature was maintained at 250°C. The oven temperature program was as follows: 70°C (5min) to 300°C (10,5 min) at a rate of 4°C/min. Oil components were identified by comparison of mass spectra with spectral library and literature. The area percentage composition was obtained by peak are normalization. The oil analyzes were carried out in partnership with the Laboratory of Services of Analytical Methods of Farmanguinhos, Fundação Oswaldo Cruz (Fiocruz), Rio de Janeiro.

The treatment of the animal was accomplished using the topical application of essential oil of *V. curassavica* at 0.5% concentration, for 21 days, once daily. The oil was incorporated into a hydrophobic ointment with the aim of promoting a better fixation in the cutaneous wound and thus having a longer action time. The wound was cleaned daily with 0.9% saline solution and realized the removal of ointment applied the previous day for to avoid cracking and drying of the granulation tissue. The lesion was inspected daily, considering the classic phases of healing.

Results and Discussion

Through the phytochemical analysis carried out, different chemical compounds was detected (Table 1). The oil yield was 0,15%. The GC-MS analysis revealed the presence of at least 27 components, among them the following constituents

of interest: alpha-humulene (3,9%); beta-caryophyllene (16,3%); alpha-pinene (52,3%); alpha-santalene (3,0%). The results show that the essential oil analyzes in terms of its active components has a good potential for medicinal use.

Table 1. Occurrence (%) of major chemical constituents in essential oil of leaves from *Varronia curassavica*.

Chemical Constituents (CQ)	Name	% Occurrence
CQ1	Alpha-thujene	0,29
CQ2	Alpha-pinene	52,26
CQ3	Alpha-fenchene	0,36
CQ4	Camphene	0,23
CQ5	Sabinene	0,50
CQ6	Beta-pinene	0,22
CQ7	Beta-myrcene	0,42
CQ8	Phellandrene	0,10
CQ9	Limonene	0,61
CQ10	Beta- phellandrene	1,95
CQ11	Ocimene	0,17
CQ12	Nonanal	0,09
CQ13	Terpineol	0,12
CQ14	Endobornyl acetate	0,57
CQ15	Citronellyl acetate	0,16
CQ16	Alloaromadrene	0,13
CQ17	Alpha-cubebene	0,23
CQ18	Alpha-bourbonene	0,12
CQ19	Beta-elemene	1,47
CQ20	Phellandrene 1,3 cyclohexadiene	0,42
CQ21	Beta-pinene	0,43
CQ22	Tricycio [2,2,1,0(2,6)]-heptane	2,96
CQ23	Beta-caryophyllene	16,32
CQ24	Beta- sesquiphellandrene	0,53
CQ25	Alpha-humulene	3,92
CQ26	Alloaromadrene	6,07
CQ27	Germaacrene	1,96

After the 15th day of treatment of the animal with the essential oil of *V. curassavica*, it was possible to observe the presence of connective tissue, fibroblastic phase and extracellular matrix deposition at the extremities towards the center of the lesion, which shows that the use of the essential oil of *V. curassavica* contributed positively to the healing process of cutaneous wound in *C. hortulanus* (Figure 1A). After the treatment period, the wound region presented with a dark-colored tissue without scales, characterizing healing the cutaneous wound of animal (Figure 1B).

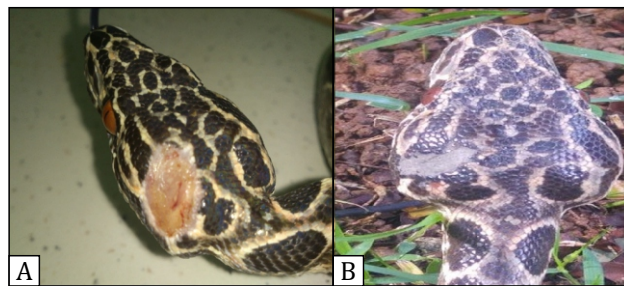


Figure 1. A - The lesion in *C. hortulanus* after the 15th day of treatment with the essential oil of *V. curassavica* with the presence of connective tissue, fibroblastic phase and extracellular matrix deposition at the extremities towards the center of the lesion. B - The lesion in the same animal after the treatment period with the essential oil of *V. curassavica* presenting a dark-colored tissue without scales, characterizing healing the cutaneous wound of reptiles.

During the treatment, the snake was kept in an acrylic box of dimensions 45 x 30 x 40cm, lined with corrugated cardboard, water *ad libitum* and with presence of branches to stimulate its arboreal behavior in a temperature-controlled environment that varied between 25 - 27 ° C and 60 - 65% humidity in order to provide thermal comfort for the animal. Feed was given to the animal only after 15 days of treatment with live prey. This time option was given because the species is constricting and requires physical strength and muscular movement for prey subjugation. Such movements could cause friction and consequently aggravate the injury.

After seven days of feeding the animal, sunbathing was done in the morning for about 30 minutes for metabolic stimulation of animal. The nutrition, quality environmental, access to ultraviolet light, reduction of stressors and environmental hygiene should be considered as part of therapeutic management (ORRIGI, 2007).

According to the literature, the mechanism of action of the active principles present in the essential oil of *V. curassavica* are characterized by the inhibition of inflammatory cytokines such as TNF α and IL-1 β and are also related to the reduction of the expression of cyclooxygenase-2 (COX-2) and the nitric oxide synthase inhibitor (iNOS) (ROYAL et al., 2012).

Currently, there is little knowledge about inflammatory chemical mediators in reptiles and whether these are similar to those of mammals (SADLER et al., 2016). Although indications and systemic use of non-steroidal anti-inflammatory drugs COXs 1 and 2 in the reptile clinic are common, studies with snakes, lizards and chelonians indicate that inflamed tissue had predominant in produce COX-1 (ROYAL et al., 2012).

The topical treatment used in open wounds influences the quality and speed of the crust closure, prevention of secondary infections, prevention of bleeding and patient morbidity. From the moment that the topical treatment used does not interfere with the aesthetics of the scar, the greatest advantage of a medicament from the clinical point of view is the rapid sealing of the lesion, since the solution of continuity of the skin favors secondary infection, dehydration for loss of liquids and evaporation, and pain (J. L. LINARDI, unpublished data).

Conclusion

The results from this study conclude that the topical use of the essential oil of *V. curassavica* was effective in the treatment of the skin lesion of the animal. However, to obtain more expressive results, this study suggests that further research, based on pharmacodynamics and pharmacokinetics, be conducted with the topical application of *V. curassavica* essential oil in the reptile clinic as a therapeutic alternative. Whereas the skin lesions in reptiles should generally be evaluated and treated individually, taking into consideration all variables associated with the process, such as age, sex, season, temperature, nutrition, general health, ecdysis, origin of the animal, type of trauma, extension of the lesion, danger of the species, among others.

References

- ARAÚJO, A. K. L.; PINHEIRO, A. D. N.; TOMÉ, A. R.; MORAIS, S. M.; OLIVEIRA, M. L. M.; FIGUEIREDO, R. C. B. Q.; NUNES-PINHEIRO, D. C. S. Atividade cicatrizante do óleo fixo de *Ouratea* sp. **Revista Brasileira de Higiene e Sanidade Animal**, v. 9, p. 154-171, 2015.
- COOPER, J. E. Dermatology. In: MADER DR, editor. **Reptile Medicine and Surgery**. 1st edition. St. Louis (MO): Saunders Elsevier; 2006.
- DE ALBUQUERQUE, H. N.; DE ALBUQUERQUE, I. C. S.; MONTEIR, J. A.; BARBOSA, A. R.; DE SOUSA, S. M.; CAVALCANTI, M. L. F. Uso de plantas medicinais no tratamento de répteis em cativeiro: um estudo preliminar. **Revista de Biologia e Ciências da Terra**, v. 4, p. 9, 2004.
- FEIJÓ, E. V. S.; OLIVEIRA, R. A.; COSTA, L. C. B. Light affects *Varronia curassavica* essential oil yield by increasing trichomes frequency. **Revista Brasileira Farmacognosia**, v. 24, p. 516-523, 2014.
- GARROS, I. C.; CAMPOS, A. C. L.; TÂMBARA, E. M.; TENÓRIO, S. B.; TORRES, O. J. M.; AGULHAM, M. A.; ARAÚJO, A. C. F.; SANTIS-ISOLAN, P. M. B.; OLIVEIRA, R. M.; DE ARRUDA, E. C. M. Extrato de *Passiflora edulis* na cicatrização de feridas cutâneas abertas em ratos: estudo morfológico e histológico. **Acta Cirúrgica Brasileira**, v. 21, p. 55-65, 2006.
- LORENZI, H.; MATOS, F. J. A. **Plantas Medicinais no Brasil: nativas e exóticas cultivadas**. Nova Odessa: Instituto Plantarum, 2002. p. 484.
- LIMA, R. P.; PALITOT, K. M.; REGO, M. A. E.; DO XAVIER, F. J. R.; DE SOUZA, A. E. F. Emprego de plantas medicinais em animais de companhia e de produção da zona rural do município de Juru-PB. **Revista de Biologia e Farmácia**, v. 8, p. 85-92, 2012.
- ORRIGI, F. C. Reptile Immunology. In: JACOBSON, E. R. (ED.). **Infectious Diseases and Pathology of Reptiles Colour Atlas and Text**. CRC Press, Taylor & Francis Group, Boca Raton, p. 131-166, 2007.
- PASSOS, G. F.; FERNANDES, E. S.; DACUNHA, F. M.; FERREIRA, J.; PIANOWSKI, L. F.; CAMPOS, M. M.; CALIXTO, J. B. Anti-inflammatory and anti-allergic properties of the essential oil and active compounds from *Cordia verbenacea*. **Journal of Ethnopharmacology**, v.110, p.323-333, 2007.
- REFLORA. 2018. *Varronia* in Lista de Espécies da Flora do Brasil. Jardim Botânico do Rio de Janeiro. Disponível em <http://reflora.jbrj.gov.br/reflora/listaBrasil/FichaPublicaTaxonUC/FichaPublicaTaxonUC.do?id=Fb105435> (accessed 04 April 2018).
- RODRIGUES, D. F.; MENDES, F. F.; NORONHA FILHO, A. D. F.; SILVA, J. A.; DA SILVA, L. A. F. O extrato da casca de barbatimão, *Stryphnodendron adstringens* (Martius) Coville, na cicatrização de feridas em animais. **Enciclopédia Biosfera**, v.9, p. 1583-1601, 2013.
- ROYAL, L. W.; LASCELLES, B. D.; LEWBART, G. A.; CORREA, M. T.; JONES, S. L.; Evaluation of cyclooxygenase protein expression in traumatized versus normal tissues from eastern box turtles (*Terrapene carolina carolina*). **Journal of Zoo and Wildlife Medicine**, v. 43, p. 289-95, 2012.
- SADLER, R. A.; SCHUMACHER, J. F.; RATHORE, K.; NEWKIRK, K. M.; COLE, G.; SEIBERT, R.; CEKANOVA, M. Evaluation of the role of the cyclooxygenase signaling pathway during inflammation in skin and muscle tissues of ball pythons (*Python regalis*). **American Journal of Veterinary Research**, v. 77, p. 487-94, 2016.
- SMITH, P. D.; KJHN, M. A.; FRANZ, M. G.; WACHTEL, T. L.; WRIGHT, T. E.; ROBSON, M. C. Initiating the Inflammatory Phase of Incisional Healing Prior to Tissue Injury. **Journal Surgery Research**, v. 92, p. 11-17, 2000.