

ISSN 0120-4157

Biomédica

Revista del Instituto Nacional de Salud

PUBLICACIÓN ANTICIPADA EN LINEA

El Comité Editorial de *Biomédica* ya aprobó para publicación este manuscrito, teniendo en cuenta los conceptos de los pares académicos que lo evaluaron. Se publica anticipadamente en versión pdf en forma provisional con base en la última versión electrónica del manuscrito pero sin que aún haya sido diagramado ni se le haya hecho la corrección de estilo.

Siéntase libre de descargar, usar, distribuir y citar esta versión preliminar tal y como lo indicamos pero, por favor, recuerde que la versión impresa final y en formato pdf pueden ser diferentes.

Citación provisional:

Galvis V, Tello A. Atypical herpetic keratitis presenting as multifocal epithelial lesions. *Biomédica*. 2020;40(4).

Recibido: 12-04-20

Aceptado: 22-07-20

Publicación en línea: 24-07-20

Atypical herpetic keratitis presenting as multifocal epithelial lesions

Queratitis herpética atípica presentándose como lesiones epiteliales multifocales

Atypical herpetic keratitis.

Virgilio Galvis, Alejandro Tello

Centro Oftalmológico Virgilio Galvis, Floridablanca, Colombia

Fundación Oftalmológica de Santander FOSCAL, Floridablanca, Colombia

Incluir sección institucional, Universidad Autónoma de Bucaramanga,

Bucaramanga, Colombia

Corresponding author:

Alejandro Tello, Centro Oftalmológico Virgilio Galvis, FOSCAL Internacional, office 3011, Floridablanca, Colombia.

Telephone: 57 7 6392929

alejandrotello@gmail.com

Authors' contribution:

Virgilio Galvis and Alejandro Tello: Conception and revision and final approval.

Alejandro Tello: redaction.

Humans are the only natural reservoir of *herpes simplex virus 1*, which can invade its host after contact with mucosal surfaces or through abraded skin.

Primary infection, either ocular or extraocular, manifests clinically only in a percentage of people, which has yet to be determined, but is considered to be less than 20% and, therefore, being around 80% of cases asymptomatic, the infection passes without being recognized most of the time.

Following this primary infection, the virus establishes in sensory neurons where it remains for the lifetime of the host, and, upon reactivation, reappears usually at mucocutaneous junction of the lips causing herpes labialis, commonly known as cold sores or fever blisters. However, rarely, following reactivation the virus involves the ophthalmic branch of the trigeminal nerve and cause ocular disease including keratitis (1-6).

A 60-year-old woman presented referring red eye, foreign body sensation and moderate photophobia in the right eye for one week. She was receiving a combination of antibiotic and topical steroid prescribed by a general practitioner. Upon examination in the slit lamp, four separate dendritic-shaped epithelial lesions were found, very suggestive of epithelial herpetic keratitis, but which was presented with a multifocal compromise, which is a very uncommon presentation, since these corneal epithelial ulcers usually are single lesions of variable size (figure 1). One factor that could lead to this atypical presentation was the use of topical dexamethasone. Since 1960s it has been considered that steroids are contraindicated when there is corneal epithelial compromise by the *herpes simplex* virus (7-11). It has been suggested that the use of steroids in epithelial herpetic

keratitis increases the risk of progressing the ulcer from dendritic to geographical, and the possibility of multifocality (10,11).

This case reaffirms the probability of worsening the clinical picture with the use of these substances when the virus is compromising the epithelium. Therefore, since this condition can be confused with infectious conjunctivitis, the general practitioner should be cautious, and look for symptoms like photophobia, which would suggest corneal involvement. The use of topical steroids should be avoided, since it can aggravate the ocular affection by the herpes virus, like in this case.

Keywords: keratitis, herpetic eye disease, herpes simplex, cornea, corticosteroids.

Palabras clave: queratitis, enfermedad ocular herpética, herpes simplex, córnea, corticosteroides.

Conflict of interest:

The authors declare that they have no conflict of interest.

Funding:

This manuscript was not funded by any institution.

References:

1. **Seitz B, Heiligenhaus A.** Das Chamäleon der Keratitis herpetischer Genese -

Diagnose und Therapie. *Klin Monbl Augenheilkd.* 2015;232:745-53.

<https://doi.org/10.1055/s-0035-1545975>

2. **Al-Dujaili LJ, Clerkin PP, Clement C, McFerrin HE, Bhattacharjee PS,**

Varnell ED, et al. Ocular herpes simplex virus: how are latency, reactivation, recurrent disease and therapy interrelated? *Future Microbiol.* 2011;6:877-907.

<https://doi.org/10.2217/fmb.11.73>

3. **Tsatsos M, MacGregor C, Athanasiadis I, Moschos MM, Hossain P, Anderson D.** Herpes simplex virus keratitis: an update of the pathogenesis and current treatment with oral and topical antiviral agents. *Clin Exp Ophthalmol.* 2016;44:824–37. <https://doi.org/10.1111/ceo.12785>
4. **Harris KD.** Herpes simplex virus keratitis. *Home Healthc Now.* 2019;37:281-4. <https://doi.org/10.1097/NHH.0000000000000791>
5. **Rowe AM, St Leger AJ, Jeon S, Dhaliwal DK, Knickelbein JE, Hendricks RL.** Herpes keratitis. *Prog Retin Eye Res.* 2013;32:88-101. <https://doi.org/10.1016/j.preteyeres.2012.08.002>
6. **Galvis V, Tello A, Revelo ML, Carreño NI.** Herpes simplex virus keratitis: epidemiological observations. *Surv Ophthalmol.* 2013;58:286-7. <https://doi.org/10.1016/j.survophthal.2013.02.003>
7. **Thygeson P, Hogan MJ, Kimura SJ.** The unfavorable effect of topical steroid therapy on herpetic keratitis. *Trans Am Ophthalmol Soc.* 1960;58:245-62.
8. **Patterson A, Jones BR.** The management of ocular herpes. *Trans Ophthalmol Soc U K.* 1967;87:59-84.
9. **Patterson A.** Management of ocular herpes simplex. *Br J Ophthalmol.* 1967;51:494-5. <https://doi.org/10.1136/bjo.51.7.494>
10. **Roobahani M, Hammersmith KM.** Management of herpes simplex virus epithelial keratitis. *Curr Opin Ophthalmol.* 2018;29:360-4. <https://doi.org/10.1097/ICU.0000000000000483>
11. **Prakash G, Avadhani K, Srivastava D.** The three faces of herpes simplex epithelial keratitis: a steroid-induced situation. *BMJ Case Rep.* 2015;2015:bcr2014209197. <https://doi.org/10.1136/bcr-2014-209197>

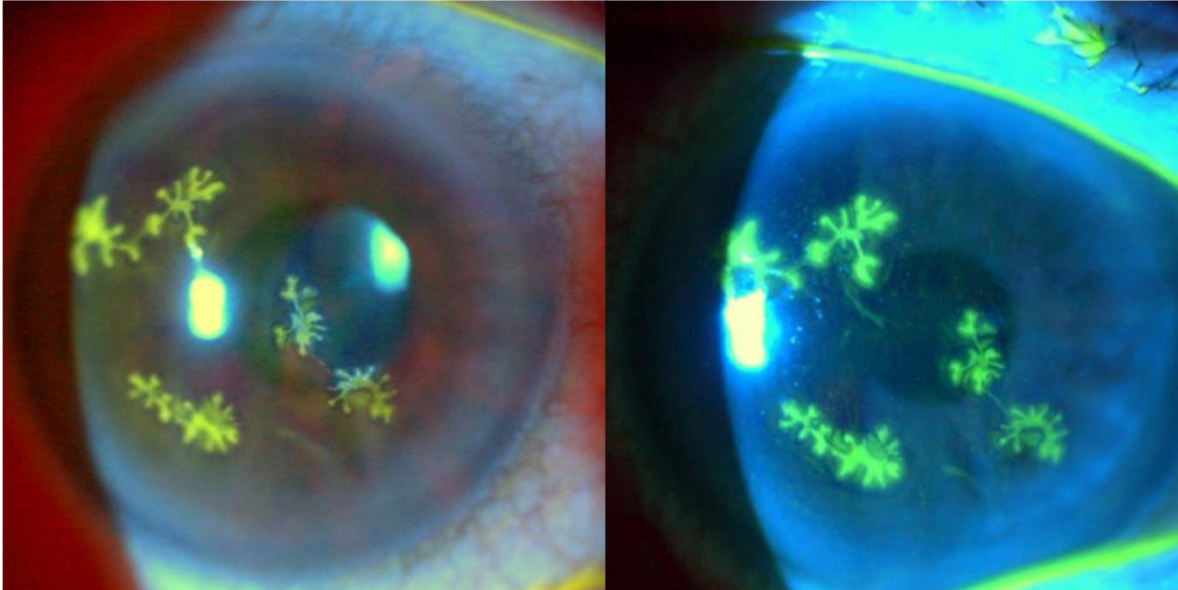


Figure 1: Multiple dendritic epithelial ulcers stained with fluorescein in a 60-year-old woman who received topical steroids prescribed by a general practitioner. Clinical photographs in slit lamp, illuminated with white light (left) and using the cobalt blue filter (right).