



**“Are textbook lungs really normal? A cadaveric study on the anatomical and clinical importance of variations in the major lung fissures, and the incomplete right horizontal fissure.”**

Journal:	<i>Clinical Anatomy</i>
Manuscript ID	CA-20-0005.R2
Wiley - Manuscript type:	Original Communications
Keywords:	anatomy, medicine
Additional Keywords:	Right horizontal fissure, Right oblique fissure, Left oblique fissure

SCHOLARONE™  
Manuscripts

1  
2  
3  
4 **Title and abstract:** “Are textbook lungs really normal? A cadaveric study on the  
5 anatomical and clinical importance of variations in the major lung fissures, and the  
6 incomplete right horizontal fissure.”  
7  
8  
9

10  
11  
12  
13 **Introduction:** The lungs have three main fissures: the right oblique fissure (ROF), right  
14 horizontal fissure (RHF), and left oblique fissure (LOF). These can be complete,  
15 incomplete or absent; **quantifying** the degree of completeness of these fissures is novel.  
16 Standard textbooks often refer to the fissures as complete, but awareness of variation is  
17 essential in thoracic surgery.  
18  
19  
20  
21  
22  
23  
24  
25  
26

27 **Materials and Methods:** Fissures in 81 pairs of cadaveric lungs were classified.  
28 Oblique fissures were measured from lung hila posteriorly to the lung hila anteriorly;  
29 and the RHF measured from the ROF to the anteromedial lung edge. The degree of  
30 completeness of fissures was expressed as a percentage of the total projected length  
31 were they to be complete. The frequency and location of accessory fissures was noted.  
32  
33  
34  
35  
36  
37  
38  
39  
40

41 **Results:** LOF were complete in 66/81 (81.5%), incomplete in 13/81 (16.0%) and absent  
42 in 2/81 (2.47%); ROF were complete in 52/81 (64.2%), incomplete in 29/81 (35.8%)  
43 and never absent; RHF were more variable, complete in 18/81 (22.2%), incomplete in  
44 54/81 (66.7%) and absent in 9/81 (11.1%). LOF and ROF were on average 97.1% and  
45 91.6% complete, respectively, being deficient posteriorly at the lung hila. The RHF on  
46 average 69.4% complete, being deficient anteromedially. There were accessory fissures  
47 in 10 left and 19 right lungs.  
48  
49  
50  
51  
52  
53  
54  
55  
56  
57  
58  
59  
60

1  
2  
3  
4 **Conclusions:** This study provides a projection of the anatomy thoracic surgeons may  
5  
6 encounter at operation, in particular the variable RHF. This knowledge is essential for  
7  
8 optimal outcomes in both benign and oncological procedures influenced by the fissures.  
9  
10  
11  
12

13 **Key words:** right oblique fissure; right horizontal fissure; left oblique fissure.  
14  
15  
16  
17  
18  
19  
20  
21  
22  
23  
24  
25  
26  
27  
28  
29  
30  
31  
32  
33  
34  
35  
36  
37  
38  
39  
40  
41  
42  
43  
44  
45  
46  
47  
48  
49  
50  
51  
52  
53  
54  
55  
56  
57  
58  
59  
60

For Peer Review

**Introduction:**

In anatomy textbooks, the lungs are typically described as being divided into lobes by three main fissures. The right lung is divided into upper, middle and lower lobes by the oblique (ROF) and horizontal (RHF) fissures, while the upper and lower lobes of the left lung are separated by the oblique fissure (LOF). The lobes are formed during embryonic development through obliteration of the spaces between bronchopulmonary segments, except at the sites of the three main fissures. Fissures comprise a double-layer of invagination of the visceral pleura, which separates the lobes of the lung. These areas may become partially or totally obliterated, resulting in an incomplete or absent fissure, respectively.

Variations in the fissures have been recognised since 1947 when a large autopsy study on 1,200 subjects demonstrated both incomplete and absent main fissures (Medlar, 1947). More recently a large number of cadaveric studies have been performed to characterise these variations in more detail, with a large number from India in particular (Lukose et al., 1999; Meenakshi et al., 2004; Prakash et al., 2010; Devi et al., 2011; Nene et al., 2011; Murlimanju et al., 2012; Dutta et al., 2013; Ghosh et al., 2013; Kommuru et al., 2013; Jacob and Pillay, 2013; Hema, 2014; Kaul et al., 2014; Quadros et al., 2014; Varalakshmi et al., 2014; Zareena, 2014; Divya et al., 2015; George et al., 2015; Magadum et al., 2015; Radha and Durai Pandian, 2015; Wahane and Satpute, 2015; Anbusudar and Dhivya, 2016; Dhanalakshmi et al., 2016; Mamatha et al., 2016). These include one study that demonstrated incomplete fissures in cadaveric fetal specimens (Zareena, 2014).

1  
2  
3  
4 In addition to the main fissures, accessory fissures may also be present. In the right  
5 lung, the apicomedial part of the upper lobe is separated from the rest of the right upper  
6 lobe by a visible azygos fissure, which contains the azygos vein. This accessory fissure  
7 is thought to form due to anomalous embryological development of the azygos vein  
8 (Akhtar et al., 2018). Rarer variants on the right include, an inferior accessory fissure  
9 separating the medial basal segment from the rest of the lower lobe, and a superior  
10 accessory fissure which divides the apical segment of the lower lobe from the basal  
11 segments. In the left lung, a horizontal fissure may occasionally be found (Standring,  
12 2008).

13  
14  
15  
16  
17  
18  
19  
20  
21  
22  
23  
24  
25  
26  
27 These anatomical variations have implications in thoracic surgery. The presence of  
28 incomplete fissures in patients with early stage adenocarcinoma of the bronchus has  
29 been shown to correlate closely with poorer long-term outcomes after attempted  
30 curative resections (Okamoto et al., 2018; Lee et al., 2016). In video-assisted  
31 thoroscopic lobectomy for early-stage non-small-cell lung cancer, the degree of  
32 pulmonary fissure completeness is likely to result in more severe postoperative  
33 cardiopulmonary complications (Li et al., 2018a); in addition, the degree of  
34 completeness is an excellent categorical predictor for both major and minor morbidity in  
35 video-assisted thoroscopic lung cancer lobectomy (Li et al., 2018b). Following any  
36 lobectomy, the presence of an incomplete fissure is a discrete risk factor for a prolonged  
37 air leak, leading to extended hospitalisation for chest drainage (Stamenovic et al., 2016).  
38 Incomplete fissures can also result in the failure of bronchoscopic lung volume  
39 reduction surgery, permitting collateral ventilation between lobes (Koster and Slebos,  
40 2016). In addition, an absent or incomplete main fissure can cause spread of infective  
41  
42  
43  
44  
45  
46  
47  
48  
49  
50  
51  
52  
53  
54  
55  
56  
57  
58  
59  
60

1  
2  
3  
4 disease such as bronchopneumonia between adjacent lobes (Tarver, 1995). In summary,  
5  
6 the less complete the major fissures are, the worse the patient outcomes.  
7  
8  
9

10  
11 In diagnostic radiology, lung fissures constitute important landmarks in chest  
12  
13 radiographs and computed tomography (CT) scans. Alterations in the appearance of the  
14  
15 main fissures can aid in the diagnosis and location of a number of pathologies, including  
16  
17 atelectasis, pleural effusions and mass lesions; a well-known example is a pleural  
18  
19 effusion tracking through the RHF giving an appearance of a horizontal white band on  
20  
21 chest radiographs (Hayashi et al., 2001). Anatomical variants within these fissures can  
22  
23 therefore lead to diagnostic difficulties. Finally, it is also important for respiratory  
24  
25 clinicians to recognise the existence of accessory fissures in segmental localisation of  
26  
27 pulmonary lesions or in the assessment of the extent of pulmonary disease, as they may  
28  
29 be misinterpreted as pathological structures (Yildiz et al., 2004).  
30  
31  
32  
33  
34  
35

36 Variations in incomplete or absent lung fissures are well reported in cadaveric and  
37  
38 radiological papers, however the extent of this incompleteness has not previously been  
39  
40 described. This observational study aims to determine the frequency, as well as the  
41  
42 extent of completeness of the main fissures in cadaveric lungs to highlight their  
43  
44 importance to thoracic surgeons to aid in operative planning. The number and location  
45  
46 of accessory fissures found will also be described.  
47  
48  
49  
50  
51  
52  
53  
54  
55  
56  
57  
58  
59  
60

## Materials and Methods

The sample consisted of 82 formalin embalmed cadavers, which were donated over two academic years. These comprised of 42 females and 40 males, with an average age at death of 84.8 (range 63 – 100). All subjects were white Caucasians from the United Kingdom, and none had undergone pulmonary surgery. One individual was excluded as they had advanced metastatic pulmonary disease, which precluded detailed assessment of the lung fissures. A total of 81 pairs of lungs were examined as part of the study. Patients with benign respiratory pathology were included as it was clear where the fissures lay in these cases.

For each pair of lungs the main fissures were noted as being complete, incomplete or absent (see Figures 1 – 3, respectively). When present, each ROF and LOF was measured from the lung hilum anteriorly to the hilum posteriorly. Measurements were taken along the ROF and LOF, as per the respective red and blue lines demonstrated in Figure 4. Each RHF was measured from the ROF to the anteromedial lung edge, as per the green line in Figure 4. The lungs were removed from their respective thoracic cavities to prevent compression or distortion occurring during measurement of the lung fissures. All measurements were taken with a measuring tape inserted into the lung fissures, to the nearest 5mm and taken from the outermost edge of the lung fissure (see Figure 2). Average fissure lengths and standard deviations (SD) were calculated to indicate dispersion of data values.

For an incomplete fissure, both its actual length and its projected complete length were recorded. The projected complete length was an estimate of where an incomplete fissure

1  
2  
3  
4 would continue, by assuming a continuation along a similar contour to their end point  
5  
6 were they to be complete. The degree of completeness was then expressed as a  
7  
8 percentage of the total projected length (see Figure 2), i.e., a complete fissure would  
9  
10 have a percentage of 100%. The mean percentage completeness for each main fissure  
11  
12 was calculated. The SD on these values was then performed to project how far a main  
13  
14 fissure would extend before its likely interruption by lung parenchyma. By expressing  
15  
16 the fissures as these percentages rather than absolute measurements variations due to  
17  
18 body size, sex or differing states of lung inflation upon embalming would be reduced.  
19  
20 The absolute values for mean lengths were also reported for to allow for comparison  
21  
22 with the literature. The number of accessory fissures present in each lung was recorded  
23  
24 and in one academic year (41 cadavers) the location of the accessory fissure was  
25  
26 recorded. Data analysis was performed using Microsoft Excel to calculate SD and  
27  
28 percentages. All donors had consented for anatomical research and non-identifiable use  
29  
30 of anatomical images prior to death in accordance with the Human Tissue Act (2004).  
31  
32  
33  
34  
35  
36  
37  
38  
39  
40  
41  
42  
43  
44  
45  
46  
47  
48  
49  
50  
51  
52  
53  
54  
55  
56  
57  
58  
59  
60



## Results

In 81 left lungs, 13 incomplete (16.0%) and two (2.47%) absent LOF were found. In 81 right lungs, 29 (35.8%) incomplete and zero absent ROF were found; 54 (66.7%) incomplete and nine (11.1%) absent RHF were observed. The mean length of the LOF was 20.8cm (SD 4.85) and mean percentage of completeness was 97.1% (SD 8.03).

The mean ROF length was 19.3cm (SD 4.97) and mean percentage of completeness was 91.6% (SD 15.3). The mean RHF was 9.25cm (SD 3.88) and mean percentage of completeness was 69.4% (SD 23.8). Table 1 summarises these findings.

All incomplete ROF and LOF were deficient posteriorly at the lung hila. When present the RHF always had its origin from the ROF and ran towards the anteromedial lung edge, if incomplete the deficiency would be between where the fissure finished and the anteromedial lung edge (see Figure 4). Accessory fissures were present in 10 (12.3%) left lungs and 19 (23.4%) right lungs. In the 41 cadavers where the nature of accessory fissures was recorded there were five left upper lobe horizontal fissures, two azygos fissures, four RHF that continued onto the right lower lobe and one right lower lobe inferior fissure.

Overall, eight (9.88%) right lungs and 58 (71.6%) left lungs from the total 162 lungs studied had a textbook appearance, with complete main fissures and no accessory fissures. The frequency of such a “typical” lung in this study was therefore 40.7%.

## Discussion

Variability within the lung fissures is well reported with papers on cadaveric populations from India, Nepal, Turkey, Ethiopia and The United States of America. These include twenty-three studies from India (Lukose et al., 1999; Meenakshi et al., 2004; Prakash et al., 2010; Devi et al., 2011; Nene et al., 2011; Murlimanju et al., 2012; Dutta et al., 2013; Ghosh et al., 2013; Kommuru et al., 2013; Jacob and Pillay, 2013; Hema, 2014; Kaul et al., 2014; Quadros et al., 2014; Varalakshmi et al., 2014; Zareena, 2014; Divya et al., 2015; George et al., 2015; Magadum et al., 2015; Radha and Durai Pandian, 2015; Wahane and Satpute, 2015; Anbusudar and Dhivya, 2016; Dhanalakshmi et al., 2016; Mamatha et al., 2016), one Nepalese (Kc et al., 2018); one Ethiopian (Gebregziabher et al., 2015); one Turkish (Unver Dogan et al., 2015); and one from The United States of America (Medlar, 1947).

This study is the single largest using formalin fixed cadavers and the largest on a population from both the United Kingdom and Europe, it is also the only paper that assesses the extent of completeness of incomplete fissures. The anatomy of the lung fissures varies considerably between these studies. These differences may be attributable to heterogeneity between methodologies and, possibly, ethnic variation. Tables 2 – 4 summarise the findings of the literature for the LOF, ROF and RHF respectively. The current study and previous studies demonstrate there is an overall preponderance for the LOF to be complete, with at least 50% of LOF studied being complete. Dutta et al. (2003) report and KC et al. (2018) are the only studies that demonstrate the LOF is less likely to be complete, with rates of only 44% and 48.1% respectively reported as complete. The LOF is uncommonly absent, Prakash et al.

(2010) report the largest absence with 10.7% absent. The ROF is similarly found to be more commonly complete. Dutta et al. (2003) was the only paper that found less than half of ROF were complete, demonstrating only 26.9% complete in their specimens. It is also unusual for the ROF to be absent, Zareena (2014) observing the highest rates of absence with 15% absent.

The current study shows that the RHF is more likely to be incomplete when compared to any other of the major fissures, with 66.7% of the RHF being incomplete. Findings from six studies in the literature also reflect this high level of incompleteness, demonstrating that 50 – 83.3% of RHF were incomplete (Meenakshi et al., 2004; Prakash et al., 2010; Jacob and Pillay, 2013; Dhanalakshmi et al., 2016; Mamatha et al., 2016; and Gebregziabher et al., 2015). Fourteen studies demonstrate conversely that at 50 – 89.5% of RHF are indeed complete (Lukose et al., 1999; Devi et al., 2011; Nene et al., 2011; Murlimanju et al., 2012; Dutta et al., 2013; Kommuru et al., 2013; Hema, 2014; Quadros, 2014; Varalakshmi, 2014; George et al., 2015; Magadum et al., 2015; Wahane and Satpute, 2015; Kc et al., 2018; Unver Dogan et al., 2015). The RHF is also the most likely major fissure to be absent and in this study 11.1% of RHF were not present. Ghosh et al. (2013) and Kaul et al. (2014) report the highest rates demonstrating absence of RHF in 47.8% and 40% of right lungs respectively. Only Mamatha et al. (2016) found no absence of RHF in their study. The RHF is therefore the most variable of the major fissures, and due to this will exert a large clinical influence due to these higher levels of unpredictability.

Variable findings have also been reported in studies of radiological images. It is

1  
2  
3  
4 difficult to assess the completeness of lung fissures on chest radiographs, as only the  
5  
6 RHF can be reliably observed (Suwatanapongched et al., 2015). The rates of  
7  
8 incompleteness of the main fissures reported in a CT series of 387 patients, found the  
9  
10 ROF, RHF and LOF to be incomplete in 69.7%, 86.9% and 48.3% of cases, respectively  
11  
12 (Ozmen et al., 2010). This differs from results shown in Tables 1 – 4, other studies,  
13  
14 however, have demonstrated that pre-operative CT scan reports are not an accurate  
15  
16 predictor of the main fissure anatomy found during thoracic surgery (Schieman et al.,  
17  
18 2011; Kent et al., 2015).  
19  
20  
21  
22  
23  
24

25 There is uncertainty as to whether cadaveric studies overestimate incomplete lung  
26  
27 fissures, as the populations studied are more likely to be elderly individuals where  
28  
29 fusion may have occurred during life. One study has been carried out looking at the  
30  
31 lung fissures in fetal specimens, where incomplete fissures were reported in the ROF  
32  
33 and RHF (Zareena, 2014). Where specimens are fixed in formalin again there is a risk  
34  
35 this process can result in obliteration of tissue planes, causing an increased reporting of  
36  
37 incomplete fissures. This was not the experience of the study conducted here, and in  
38  
39 autopsy studies, where no embalming had occurred, incomplete and absent fissures are  
40  
41 demonstrated (Dhanalakshmi et al., 2016; Unver Dogan et al., 2015; Medlar, 1947). The  
42  
43 anatomy of the fissures found in cadaveric studies should therefore be more  
44  
45 representative of what thoracic clinicians can expect to find at the time of surgery, in  
46  
47 particular in comparison to radiological studies investigating lung fissure anatomy.  
48  
49  
50  
51  
52  
53  
54

55 Absolute measurements of lengths of fissures were reported in other studies, but the  
56  
57 usefulness of this data is debatable in cadaveric lungs, the most important reason being  
58  
59  
60

1  
2  
3  
4 that the level of inflation at the time of study varies from complete collapse to full  
5  
6 inflation. In life, at the time of thoracic surgery, the lung fissures will again vary in  
7  
8 length with inhalation and exhalation. This is the first study where the percentage and  
9  
10 degree of completeness of fissures has been calculated. This is important as its value  
11  
12 should remain relatively constant despite the changes pointed out above.  
13  
14  
15  
16  
17

18 A good understanding of the anatomy of pulmonary lobes and fissures allows the  
19  
20 surgeon to correlate imaging with the pathological process, and ensures the best  
21  
22 possible operation for each patient (Ugalde et al., 2007). This study demonstrates that in  
23  
24 an elderly UK population the LOF and ROF tend to be near complete (97.1% and  
25  
26 91.6%, respectively) and are only deficient to a small degree posteriorly. Of note Dutta  
27  
28 et al. (2013) also demonstrated LOF and ROF that were incomplete anteriorly. Thus, in  
29  
30 cases where lung resection is required, the surgeon should carefully examine the  
31  
32 specific areas where the oblique fissures approach the lung hila to ensure that an  
33  
34 incomplete fissure is stapled off adequately in order to avoid a persistent air leak.  
35  
36 During bronchoscopic lung volume reduction surgery again these areas should be  
37  
38 checked to ensure that there is no collateral ventilation between lobes. If feasible  
39  
40 incomplete lung fissures can be stapled off, or if the fissure is not large enough the  
41  
42 procedure may have to be aborted or revised. When oncological resection is being  
43  
44 performed and an operable tumour involves a segment of an incomplete LOF or ROF  
45  
46 close to where the lobes are fused, an additional lobectomy or total pneumonectomy  
47  
48 may be required for optimal tumour clearance. Where the fissures are largely  
49  
50 incomplete, patients should be told peri-operatively that they may require an extended  
51  
52 hospital stay for chest drainage due to the potential for persistent air leaks.  
53  
54  
55  
56  
57  
58  
59  
60

1  
2  
3  
4  
5  
6  
7 The anatomy of the RHF is much more variable, with only a minority being complete.  
8  
9 Surgeons should be aware that it will likely be incomplete or absent, and have a lower  
10  
11 threshold for careful examination and taking the steps described above to ensure good  
12  
13 outcomes in interventional procedures. They can expect the RHF to pass approximately  
14  
15 69.4% (SD 23.8) of the distance from the ROF to the anteromedial lung edge, on the  
16  
17 basis of this study in an elderly UK population.  
18  
19  
20  
21

22  
23 Craig and Walker (1997) also aimed to characterise incomplete main fissures and divide  
24  
25 them into four classifications. Grade 1 being a complete fissure with separate lobes,  
26  
27 grade 2 demonstrates a complete visceral cleft but parenchymal fusion at the base of the  
28  
29 fissure, in grade 3 there is a visceral cleft evident for part of the fissure and finally grade  
30  
31 4 where there is complete fusion of the lobes with no evident fissural line. Some  
32  
33 previous studies have utilised this classification system, however Craig and Walker  
34  
35 (1997) do not attempt to quantify, and predict, a way to characterise fissure lengths.  
36  
37  
38 Establishing percentage completeness of the major fissures of the lungs will aid thoracic  
39  
40 surgeons to plan operative interventions.  
41  
42  
43  
44

45  
46 This study is limited by the cadaveric nature of specimens examined, which may vary  
47  
48 from radiological and operative findings in living lungs, however the benefit of being  
49  
50 able to completely remove the lungs facilitated accurate measurement of the fissures.  
51  
52 The embalming process, varying degrees of lung inflation and advanced age of the  
53  
54 cohort will also cause changes to the fissures compared to those encountered by  
55  
56 clinicians in life, this is, however, unavoidable with the nature of cadaveric studies. The  
57  
58  
59  
60

1  
2  
3  
4 only clinical data available from the cadavers was age at death, cause of death and  
5  
6 obvious pathology found during the dissection process. Patient confidentiality meant  
7  
8 medical records for the cadavers could not be obtained, this therefore limited correlation  
9  
10 between pathology and the status of the fissures encountered. The study was based on  
11  
12 gross anatomical findings and no histological analysis was performed to ensure that  
13  
14 fissures had not fused during life, this could potentially be a further avenue for  
15  
16 investigation, however for the thoracic surgeon the gross anatomy encountered at the  
17  
18 time of operation will be more important. The nature of the accessory fissures was only  
19  
20 recorded in approximately half of the specimens, although their relevance to thoracic  
21  
22 surgery is not as significant as incompleteness or absence of the major fissures, more  
23  
24 data regarding these could be collected. Establishing the degree of completeness during  
25  
26 the study was based on estimates of where incomplete fissures were likely to continue  
27  
28 to, assuming they would continue on the same contour, as there was no definite point to  
29  
30 measure to. The findings in this study therefore do not provide a definitive guide to  
31  
32 thoracic surgeons, but give a projection of what is likely to be encountered.  
33  
34  
35  
36  
37  
38  
39  
40  
41  
42  
43  
44  
45  
46  
47  
48  
49  
50  
51  
52  
53  
54  
55  
56  
57  
58  
59  
60

**Conclusions:**

In conclusion, this study not only confirms what was known from studies in different populations, but in addition demonstrates this variability in the largest cadaveric European cohort in the literature. It is also novel in its approach to characterising the percentage completeness of the major fissures of the lungs. The variability in completeness of the RHF, in particular, are very variable and in the population studied this fissure was 69.4% (SD 23.8) complete.

For thoracic surgeons this has an important impact on oncological and benign procedures, as well as post-operative complications. This study provides an estimate of the extent of incompleteness that can be expected at operation, to ensure patients receive the most appropriate operation performed optimally. Radiologists and respiratory physicians reviewing radiological studies should also be aware of these gross anatomical variations, and that they have an important influence on diagnostic imaging and respiratory pathology.

A typical “textbook” lung has three complete major fissures and no accessory fissures. In this study only 40.7% of had this classical appearance. Clinicians and anatomists should be aware that lung fissure anatomy is more variable than traditionally presented.



**References:**

Akhtar J, Lal A, Martin KB, et al. 2018. Azygos lobe: A rare cause of right paratracheal opacity. *Respir Med Case Rep* 23:136-137.

Anbusudar K, Dhivya S. 2016. Anatomical study on variations of fissures of lung. *Indian J Clin Anat Physiol* 3:449-451.

Craig SR and Walker WS. 1997. A Proposed Anatomical Classification of the Pulmonary Fissures. *J R Coll Surg Edinb.* 42(4):233-234.

Devi NB, Rao BN, Sunitha V. 2011. Morphological variations of lung – A cadaveric study in north costal Andhra Pradesh. *Int J Biol Res* 2(4):1149-1152.

Dhanalakshmi V, Manoharan C, Rajesh R, et al. 2016. Morphological study of fissure and lobes of lungs. *Int J Anat Res* 4:1892-1895.

Divya C, Venkateshu KV, Swaroop RB. 2015. Anatomical study of pulmonary fissures and lobes. *Int J Recent Sci Res* 6(6):4554-4557.

Dutta S, Mandal L, Mandal SK, et al. 2013. Natural Fissures of Lung – Anatomical Basis of Surgical Techniques and Imaging. *Natl J Med Res* 3(2):117-121.

Gebregziabher A, Berhe T, Ekanem P. 2015. Variations of Fissures and Lobes of the Lungs in Human Cadavers in Selected Universities of Ethiopia. *IJPSR* 6(6):981-990.

George BM, Nayak SB, Marpalli S. 2015. Morphological variations of the lungs: a study conducted on Indian cadavers. *Anat Cell Biol* 47(4):253-258.

Ghosh E, Basu R, Dhur A, et al. 2013. Variations of fissures and lobes in human lungs: a multicentric cadaveric study from West Bengal, India. *Int J Anat Radiol Surg* 2:5-8.

1  
2  
3  
4 Hayashi K, Aziz A, Ashizawa K, et al. 2001. Radiographic and CT Appearances of the  
5 Major Fissures. *Radiographics* 21(4):861-874.  
6  
7

8  
9  
10 Hema L. Lungs Lobes and Fissures: A Morphological Study. 2014. *IJRTSAT*  
11 11(1):122-126.  
12  
13

14  
15 Jacob SM, Pillay M. Variations in the Inter-lobar Fissures of Lungs Obtained from  
16 Cadavers of South Indian Origin. 2013. *Int J Morphol* 31(2):497-499.  
17  
18

19  
20 Kaul N, Singh V, Seth R, et al. 2014. Anomalous fissures and lobes of human lungs of  
21 North Indian population of western UP. *J Anat Soc India* 63(supplement 2):26-30.  
22  
23

24  
25 Kc S, Shrestha P, Shah AK, et al. 2018. Variations in human pulmonary fissures and  
26 lobes: a study conducted in Nepalese cadavers. *Anat Cell Biol* 51(2):85-92.  
27  
28

29  
30 Kent MS, Ridge C, O'Dell D. 2015. The accuracy of computed tomography to assess  
31 completeness of pulmonary fissures. A prospective study. *Ann Am Thorac Soc*  
32 12(5):696-700.  
33  
34  
35  
36  
37  
38

39 Kommuru H, Sree LD, Hema PJ, et al. 2013. Pulmonary fissures and lobar variations in  
40 relation to surgical and Radiological implications. *IOSR-JDMS* 5(1):51-54.  
41  
42  
43

44  
45 Koster TD, Slebos DJ. 2016. The fissure: interlobar collateral ventilation and  
46 implications for endoscopic therapy in emphysema. *Int J Chron Obstruct Pulmon Dis*  
47 11:765-773.  
48  
49  
50

51  
52 Lee S, Lee JG, Lee CY, et al. 2016. Pulmonary fissure development is a prognostic  
53 factor for patients with resected stage 1 lung adenocarcinoma. *J Surg Oncol* 114(7):  
54 848-852.  
55  
56  
57  
58  
59  
60

- 1  
2  
3  
4 Li S, Wang Z, Zhou K, et al. 2018b. Effects of degree of pulmonary fissure  
5  
6 completeness on major in-hospital outcomes after video-assisted thoracoscopic lung  
7  
8 cancer lobectomy: a retrospective-cohort study. *Ther Clin Risk Manag* 14:461-474.  
9  
10  
11  
12 Li S, Zhou K, Wang M, et al. 2018a. Degree of pulmonary fissure completeness can  
13  
14 predict postoperative cardiopulmonary complications and length of hospital stay in  
15  
16 patients undergoing video-assisted thoracoscopic lobectomy for early-stage lung cancer.  
17  
18 *Interact Cardiovasc Thorac Surg* 26(1): 25-33.  
19  
20  
21  
22 Lukose R, Paul S, Sunitha, et al. 1999. Morphology of the lungs: Variations in the lobes  
23  
24 and fissures. *Biomedicine* 19:227-232.  
25  
26  
27  
28 Magadum A, Dixit D, Bhimalli S. 2015. Fissures and lobes of lung: an anatomical study  
29  
30 and its clinical significance. *Int J Curr Res Rev* 7:8-12.  
31  
32  
33  
34 Mamatha Y, Murthy CK, Prakash BS. 2016. Study of morphological variations of  
35  
36 fissures and lobes of the lung. *Int J Anat Res.* 4:1874-1877.  
37  
38  
39  
40 Medlar EM. Variations in interlobar fissures. 1947. *Am J Roetgenol Radium Ther*  
41  
42 *57:723-725.*  
43  
44  
45 Meenakshi S, Manjunath KY, Balasubramanyam V. 2004. **Morphological** variations of  
46  
47 the lung fissures and lobes. *Indian J Chest Dis Allied Sci* 46(3):179-182.  
48  
49  
50  
51 Murlimanju BV, Prabhu LV, Shilpa K, et al. 2012. Pulmonary fissures and lobes: a  
52  
53 cadaveric study with emphasis on surgical and radiological implications. *Clin Ter*  
54  
55 *163(1):9-13.*  
56  
57  
58  
59  
60

- 1  
2  
3  
4 Nene AR, Gajendra KS, Sarma MV. 2011. Lung lobes and fissures: a morphological  
5 study. *Anatomy* 5:30-38.  
6  
7  
8  
9  
10 Okamoto J, Kubokura H, Usuda J. 2018. Prognostic effect of incompletely lobulated  
11 fissures in p-Stage I non-small-cell lung cancer. *Interact Cardiovasc Thorac Surg*  
12 26(2):264-270.  
13  
14  
15  
16  
17 Ozmen CA, Nazaroglu H, Bayrak AH, et al. 2010. Evaluation of interlobar and  
18 **accessory** pulmonary fissures on 64-row MDCT. *Clin Anat* 23(5):552-558.  
19  
20  
21  
22  
23 Prakash, Bhardwaj AK, Shashirekha M, et al. 2010. Lung morphology: a cadaver study  
24 in Indian population. *Ital J Anat Embryol.* 115(3):235-240.  
25  
26  
27  
28 Quadros LS, Palanichamy R, D'souza AS. 2014. Variations in the lobes and fissures of  
29 lungs – a study in South Indian lung specimens. *Eur J Anat* 8(1):16-20.  
30  
31  
32  
33  
34 Radha K, Durai Pandian K. Fissures and lobes of lungs: a morphological and  
35 anatomical study. 2015. *Int J Anat Res* 3(2):995-998.  
36  
37  
38  
39 Schieman C, MacGregor JH, Kelly E, et al. 2011. Can preoperative computed  
40 tomography of the chest predict completeness of the major pulmonary fissure at  
41 surgery? *Can J Surg.* 54(4):252-256.  
42  
43  
44  
45  
46  
47 Stamenovic D, Bostanci K, Messerschmidt A, et al. 2016. Fissureless fissure-last video-  
48 assisted thoracoscopic lobectomy for all lung lobes: a better alternative to decrease the  
49 incidence of prolonged air leak? *Eur J Cardiothorac Surg* 50(1):118-123.  
50  
51  
52  
53  
54 Standring S. 2008. Thorax. *Gray's Anatomy The Anatomical Basis of Clinical Practice.*  
55  
56  
57 40<sup>th</sup> Ed. Churchill Livingstone. p 993-994.  
58  
59  
60

1  
2  
3  
4 Suwatanapongched T, Bua-Ngam C, Sukkasem W, et al. 2015. Visibility and variability  
5 of pleural fissures on normal digital chest radiographs of 1,000 health adults. *Jpn J*  
6  
7  
8  
9 Radiol 33(4):201-209.

10  
11  
12 Tarver RD. 1995. How common are incomplete pulmonary fissures, and what is their  
13 clinical significance? *Am J Roentgenol.* 164(3):761.

14  
15  
16  
17 Ugalde P, Camargo Jde J, Deslauriers J. 2007. Lobes, fissures, and bronchopulmonary  
18 segments. *Thorac Surg Clin* 17(4):587-599.

19  
20  
21  
22 Unver Dogan N, Uysal II, Demirci S. 2015. Major anatomic variations of pulmonary  
23 fissures and lobes on post-mortem examination. *Acta Clin Croat* 54(2):201-207.

24  
25  
26  
27 Varalakshmi KL, Nayak JN, Sangeetha M. 2014. Morphological Variations of Fissures  
28 of Lung: An Anatomical Study. *Indian J Appl Res* 4(8):467-469.

29  
30  
31  
32 Wahane A, Satpute C. 2015. A Cadaveric Study of Morphological Variations of Lung  
33 in Vidarbha Region. *Int J Sci Res (Raipur)* 4(1):2163-2166.

34  
35  
36  
37 Yildiz A, Golpinar F, Calikoglu M, et al. 2004. HRCT evaluation of the accessory  
38 fissures of the lung. *Eur J Radiol* 49(3):245-249.

39  
40  
41  
42 Zareena SK. 2014. A study of morphology and variations of lungs in adults and foetus.  
43  
44  
45  
46  
47 IJOART 3(4):150-157.

1  
2  
3  
4  
5  
6  
7  
8  
9  
10  
11  
12  
13  
14  
15  
16  
17  
18  
19  
20  
21  
22  
23  
24  
25  
26  
27  
28  
29  
30  
31  
32  
33  
34  
35  
36  
37  
38  
39  
40  
41  
42  
43  
44  
45  
46  
47  
48  
49  
50  
51  
52  
53  
54  
55  
56  
57  
58  
59  
60

**Footnotes:**

For Peer Review

**Legends:\***

Figure 1: This shows a complete left oblique fissure extending from the lung hilum anteriorly and continuing to the hilum posteriorly.

Figure 2: The right horizontal fissure extends 65mm from the right oblique fissure before it is interrupted. The dashed line denotes the continuation the right horizontal fissure were it to be complete. In this case, the right horizontal fissure is stated to be 54.5% complete.

Figure 3: The right horizontal fissure is completely absent.

Figure 4A: Lateral view of the lungs, green line denotes the right horizontal fissure, red line the right oblique fissure and blue line the left oblique fissure. Measurements were taken along these lines. Label A denotes the region where the right horizontal fissure would be incomplete, as per Figure 2.

Figure 4B: Medial view of the lungs, labels B and C demonstrate the areas where the right oblique fissures and left oblique fissures, respectively, are incomplete in this study.

\*Figures ideally to be added to manuscript near to where they are referred to in the text

**Tables:\***

Table 1: Comparison of complete, incomplete and absent main fissures. Left oblique fissure (LOF), right oblique fissure (ROF) and right horizontal fissure (RHF).

<b>N = 81</b>	<b>Complete</b>	<b>Incomplete</b>	<b>Absent</b>	<b>Average length of main fissure in cm when present (SD)</b>	<b>Degree of completeness (SD)</b>
LOF	66 (81.5%)	13 (16.0%)	2 (2.47%)	20.8 (4.85)	97.1% (8.03)
ROF	52 (64.2%)	29 (35.8%)	0 (0%)	19.3 (4.97)	91.6% (15.3)
RHF	18 (22.2%)	54 (66.7%)	9 (11.1%)	9.25 (3.88)	69.4% (23.8)



Table 2: Comparison of incomplete or absent left oblique fissures (LOF) within the literature. Population of origin and types of specimen used are listed – formalin fixed cadavers (FFC), unspecified cadavers (UC) and autopsy study (AS). Where referenced lengths in centimetres (cm) and standard deviations (SD) are given.

STUDY	STUDY POPULATION	LOF COMPLETE	LOF INCOMPLETE	LOF ABSENT	LOF LENGTH
Current Study	United Kingdom - FFC	66/81 (81.5%)	13/81 (16.0%)	2/81 (2.47%)	20.8cm +/- 4.85c, (mean + SD)
Lukose et al., 1999	India – UC	15/19 (78.9%)	4/19 (21.1%)	0/19 (0%)	
Meenakshi et al., 2004	India – UC	16/30 (53.3%)	14/30 (46.6%)	0/30 (0%)	
Prakash et al., 2010	India – UC	14/28 (50%)	11/28 (39.3%)	3/28 (10.7%)	
Devi et al., 2011	India - FFC	12/22 (54.5%)	8/22 (36.4%)	2/22 (9.09%)	7cm - 28cm (range)
Nene et al., 2011	India - FFC	44/50 (88%)	6/50 (12%)	0/50 (0%)	
Murlimanju et al., 2012	India - UC	57/60 (95%)	2/60 (3.33%)	1/60 (1.67%)	
Dutta et al. 2013	India - FFC	22/50 (44%)	24/50 (48%)	4/50 (8%)	27.32cm +/- 7.29cm (mean + SD)
Ghosh et al., 2013	India - FFC	29/36 (80.6%)	5/36 (13.9%)	2/36 (5.56%)	
Kommuru et al., 2013	India - UC	36/40 (90%)	4/40 (10%)	0/40 (0%)	
Jacob and Pillay, 2013	India - UC	11/18 (61.1%)	7/18 (38.9%)	0/18 (0%)	
Hema, 2014	India - FFC	20/25 (80%)	4/25 (16%)	1/25 (4%)	18.0cm +/- 7.88cm (mean + SD)
Kaul et al., 2014	India - UC	30/50 (60%)	20/50 (40%)	0/50 (0%)	
Quadros et al., 2014	India - FFC	39/40 (97.5%)	1/40 (2.5%)	0/40 (0%)	
Varalakshmi et al., 2014	India - FFC	23/34 (67.6%)	10/34 (29.4%)	1/34 (2.94%)	29.89cm (mean of LOF and ROF)
Zareena 2014 (adult specimens)	India - UC	11/20 (55%)	9/20 (45%)	0/20 (0%)	
Zareena 2014 (fetal specimens)	India - fetal specimens	6/6 (100%)	0/6 (0%)	0/6 (0%)	
Divya et al., 2015	India - FFC	21/27 (77.8%)	4/27 (14.8%)	2/27 (7.41%)	

George et al., 2015	India - FFC	62/73 (84.9%)	11/73 (15.1%)	0/73 (0%)	
Magadum et al., 2015	India - FFC	32/40 (80%)	5/40 (12.5%)	3/40 (7.5%)	
Radha and Durai Pandian, 2015	India - FFC	23/30 (76.7%)	7/30 (23.3%)	0/30 (0%)	
Wahane and Satpute, 2015	India - FFC	14/21 (66.7%)	6/21 (28.6%)	1/21 (4.76%)	8cm - 28cm (range)
Anbusudar and Divya, 2016	India - UC	17/25 (68%)	8/25 (32%)	0/25 (0%)	
Dhanalakshmi et al., 2016	India - mixed AS and FFC	31/50 (62%)	19/50 (38%)	0/50 (0%)	
Mamatha et al., 2016	India - UC	12/20 (60%)	7/20 (35%)	1/20 (5%)	
Kc et al., 2018	Nepal - FFC	13/27 (48.1%)	14/27 (51.9%)	0/27 (0%)	
Gebregziabher et al., 2015	Ethiopia - FFC	13/20 (65%)	7/20 (35%)	0/20 (0%)	
Unver Dogan et al., 2015	Turkey - AS	208/210 (99.0%)	2/210 (0.95%)	0/210 (0%)	
Medlar, 1947	United States of America - AS	985/1200 (82.1%)	215/1200 (17.9%)	N/A	

Table 3: Comparison of incomplete or absent right oblique fissures (ROF) within the literature. Population of origin and types of specimen used are listed – formalin fixed cadavers (FFC), unspecified cadavers (UC) and autopsy study (AS). Where referenced lengths in centimetres (cm) and standard deviations (SD) are given.

STUDY	STUDY POPULATION	ROF COMPLETE	ROF INCOMPLETE	ROF ABSENT	ROF LENGTH
Current Study	United Kingdom - FFC	52/81 (64.2%)	29/81 (35.8%)	0/81 (0%)	19.3cm +/- 4.97cm (mean + SD)
Lukose et al., 1999	India – UC	19/19 (100%)	0/19 (0%)	0/19 (0%)	
Meenakshi et al., 2004	India – UC	19/30 (63.3%)	11/30 (36.6%)	0/30 (0%)	
Prakash et al., 2010	India – UC	15/28 (53.6%)	11/28 (39.3%)	2/28 (7.14%)	
Devi et al., 2011	India - FFC	20/22 (90.9%)	2/22 (9.09%)	0/22 (0%)	13-28cm (range)
Nene et al., 2011	India - FFC	45/50 (90%)	4/50 (8%)	1/50 (2%)	
Murlimanju et al., 2012	India - UC	60/60 (100%)	0/60 (0%)	0/60 (0%)	
Dutta et al. 2013	India - FFC	14/52 (26.9%)	32/52 (61.5%)	6/52 (11.5%)	30.15cm +/- 6.26cm (mean + SD)
Ghosh et al., 2013	India - FFC	36/46 (78.2%)	9/46 (19.6%)	1/46 (2.17%)	
Kommuru et al., 2013	India - UC	N/A	N/A	N/A	
Jacob and Pillay, 2013	India - UC	16/30 (53.3%)	15/30 (50%)	1/30 (3.33%)	
Hema, 2014	India - FFC	20/25 (80%)	5/25 (20%)	0/25 (0%)	21.0cm +/- 4.56cm (mean + SD)
Kaul et al., 2014	India - UC	34/50 (68%)	12/50 (24%)	4/50 (8%)	
Quadros et al., 2014	India - FFC	34/36 (94.4%)	2/36 (5.56%)	0/36 (0%)	
Varalakshmi et al., 2014	India - FFC	25/30 (83.3%)	5/30 (16.7%)	0/30 (0%)	29.89cm (mean of LOF and ROF)
Zareena 2014 (adult specimens)	India - UC	14/20 (70%)	3/20 (15%)	3/20 (15%)	
Zareena 2014 (fetal specimens)	India - fetal specimens	4/6 (66.7%)	2/6 (33.3%)	0/6 (0%)	
Divya et al., 2015	India - FFC	25/28 (89.3%)	3/28 (10.7%)	0/28 (0%)	
George et al., 2015	India - FFC	63/65 (96.9%)	2/65 (3.08%)	0/65 (0%)	
Magadam et al., 2015	India - FFC	25/40 (62.5%)	11/40 (27.5%)	4/40 (10%)	
Radha and Durai Pandian, 2015	India - FFC	25/30 (83.3%)	5/30 (16.7%)	0/30 (0%)	
Wahane and Satpute, 2015	India - FFC	24/29 (82.8%)	5/29 (17.2%)	0/29 (0%)	13cm - 29cm (range)
Anbusudar and Divya, 2016	India - UC	16/25 (64%)	7/25 (28%)	2/25 (8%)	
Dhanalakshmi et al., 2016	India - mixed AS and FFC	34/50 (68%)	16/50 (32%)	0/50 (0%)	
Mamatha et al., 2016	India - UC	17/20 (85%)	3/20 (15%)	0/50 (0%)	
Kc et al., 2018	Nepal - FFC	16/23 (69.6%)	7/23 (30.4%)	0/23 (0%)	
Gebregziabher et al., 2015	Ethiopia - FFC	12/23 (52.2%)	11/23 (47.8%)	0/23 (0%)	

1  
2  
3  
4  
5  
6  
7  
8  
9  
10  
11  
12  
13  
14  
15  
16  
17  
18  
19  
20  
21  
22  
23  
24  
25  
26  
27  
28  
29  
30  
31  
32  
33  
34  
35  
36  
37  
38  
39  
40  
41  
42  
43  
44  
45  
46  
47  
48  
49  
50  
51  
52  
53  
54  
55  
56  
57  
58  
59  
60

Unver Dogan et al., 2015	Turkey - AS	207/210 (98.6%)	3/210 (1.43%)	0/210 (0%)	
Medlar, 1947	United States of America - AS	835/1200 (69.6%)	365/1200 (30.4%)	N/A	

For Peer Review

Table 4: Comparison of incomplete or absent right horizontal fissures (RHF) within the literature. Population of origin and types of specimen used are listed – formalin fixed cadavers (FFC), unspecified cadavers (UC) and autopsy study (AS). Where referenced lengths in centimetres (cm) and standard deviations (SD) are given.

STUDY	STUDY POPULATION	RHF COMPLETE	RHF INCOMPLETE	RHF ABSENT	RHF LENGTH
Current Study	United Kingdom - FFC	18/81 (22.2%)	54/81 (66.7%)	9/81 (11.1%)	9.25cm +/- 3.88cm (mean + SD)
Lukose et al., 1999	India – UC	13/19 (68.4%)	4/19 (21.1%)	2/19 (10.5%)	
Meenakshi et al., 2004	India – UC	6/30 (20%)	19/30 (63.3%)	5/30 (16.6%)	
Prakash et al., 2010	India – UC	12/28 (42.9%)	14/28 (50%)	2/28 (4%)	
Devi et al., 2011	India - FFC	16/22 (72.7%)	4/22 (18.2%)	2/22 (9.09%)	10cm - 17cm (range)
Nene et al., 2011	India - FFC	39/50 (78%)	4/50 (8%)	7/50 (14%)	
Murlimanju et al., 2012	India - UC	39/60 (65%)	15/60 (25%)	6/60 (10%)	
Dutta et al. 2013	India - FFC	31/52 (59.6%)	13/52 (25%)	18/52 (34.6%)	
Ghosh et al., 2013	India - FFC	12/46 (26.1%)	12/46 (26.1%)	22/46 (47.8%)	
Kommuru et al., 2013	India - UC	24/40 (60%)	12/40 (30%)	4/40 (10%)	
Jacob and Pillay, 2013	India - UC	3/30 (10%)	25/30 (83.3%)	2/30 (6.66%)	
Hema, 2014	India - FFC	16/25 (64%)	4/25 (16%)	5/25 (20%)	
Kaul et al., 2014	India - UC	14/50 (28%)	16/50 (32%)	20/50 (40%)	
Quadros et al., 2014	India - FFC	23/36 (63.9%)	9/36 (25%)	4/36 (11.1%)	
Varalakshmi et al., 2014	India - FFC	18/30 (60%)	9/30 (30%)	3/30 (10%)	10.06cm (mean)
Zareena 2014 (adult specimens)	India - UC	9/20 (45%)	5/20 (25%)	6/20 (30%)	
Zareena 2014 (fetal specimens)	India - fetal specimens	4/6 (66.7%)	2/6 (33.3%)	0/6 (0%)	
Divya et al., 2015	India - FFC	11/28 (39.3%)	11/28 (39.3%)	6/28 (21.4%)	
George et al., 2015	India - FFC	25/65 (61.5%)	23/65 (35.4%)	2/65 (3.08%)	
Magadum et al., 2015	India - FFC	27/40 (67.5%)	8/40 (20%)	5/40 (12.5%)	
Radha and Durai Pandian, 2015	India - FFC	13/30 (43.3%)	12/30 (40%)	5/30 (16.7%)	
Wahane and Satpute, 2015	India - FFC	18/29 (62.1%)	9/29 (31.0%)	2/29 (6.90%)	10cm - 18cm (range)
Anbusudar and Divya, 2016	India - UC	9/25 (36%)	11/25 (44%)	5/25 (20%)	
Dhanalakshmi et al., 2016	India - mixed AS and FFC	15/50 (30%)	26/50 (62%)	9/50 (18%)	
Mamatha et al., 2016	India - UC	10/20 (50%)	10/20 (50%)	0/20 (0%)	

1  
2  
3  
4  
5  
6  
7  
8  
9  
10  
11  
12  
13  
14  
15  
16  
17  
18  
19  
20  
21  
22  
23  
24  
25  
26  
27  
28  
29  
30  
31  
32  
33  
34  
35  
36  
37  
38  
39  
40  
41  
42  
43  
44  
45  
46  
47  
48  
49  
50  
51  
52  
53  
54  
55  
56  
57  
58  
59  
60

Kc et al., 2018	Nepal - FFC	12/23 (52.2%)	8/23 (34.8%)	3/23 (13.0%)	
Gebregziabher et al., 2015	Ethiopia - FFC	6/23 (26.1%)	13/23 (56.5%)	4/23 (17.4%)	
Unver Dogan et al., 2015	Turkey - AS	188/210 (89.5%)	18/210 (8.57%)	4/210 (1.90%)	
Medlar, 1947	United States of America - AS	452/1200 (37.7%)	588/1200 (49%)	160/1200 (13.3%)	

\*Tables ideally to appear in manuscript near to where they are referenced in the text.

For Peer Review

**Acknowledgements:**

We acknowledge the generosity of the donors who made this study possible, and the invaluable assistance provided by Maria Wright, Senior Teaching Technician, and Darren Broadhurst, assistant teaching technician, in the Human Dissection Room.

For Peer Review

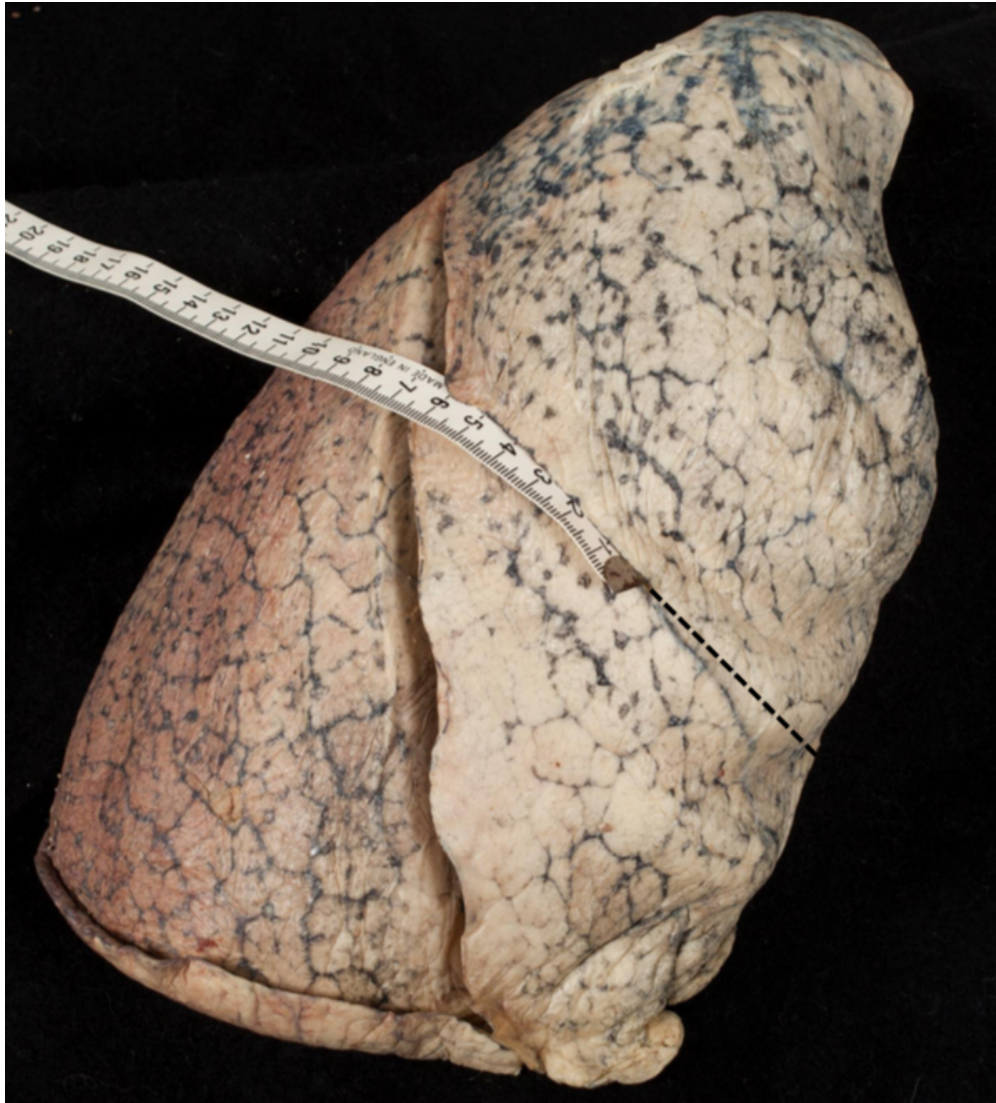


1  
2  
3  
4  
5  
6  
7  
8  
9  
10  
11  
12  
13  
14  
15  
16  
17  
18  
19  
20  
21  
22  
23  
24  
25  
26  
27  
28  
29  
30  
31  
32  
33  
34  
35  
36  
37  
38  
39  
40  
41  
42  
43  
44  
45  
46  
47  
48  
49  
50  
51  
52  
53  
54  
55  
56  
57  
58  
59  
60



This shows a complete left oblique fissure extending from the lung hilum anteriorly and continuing to the hilum posteriorly.





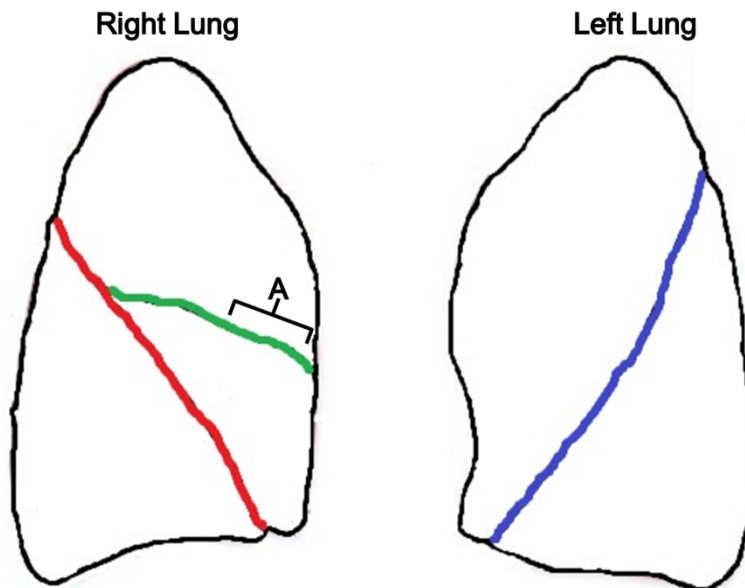
The right horizontal fissure extends 65mm from the right oblique fissure before it is interrupted. The dashed line denotes the continuation the right horizontal fissure were it to be complete. In this case, the right horizontal fissure is stated to be 54.5% complete.

92x101mm (200 x 200 DPI)

1  
2  
3  
4  
5  
6  
7  
8  
9  
10  
11  
12  
13  
14  
15  
16  
17  
18  
19  
20  
21  
22  
23  
24  
25  
26  
27  
28  
29  
30  
31  
32  
33  
34  
35  
36  
37  
38  
39  
40  
41  
42  
43  
44  
45  
46  
47  
48  
49  
50  
51  
52  
53  
54  
55  
56  
57  
58  
59  
60

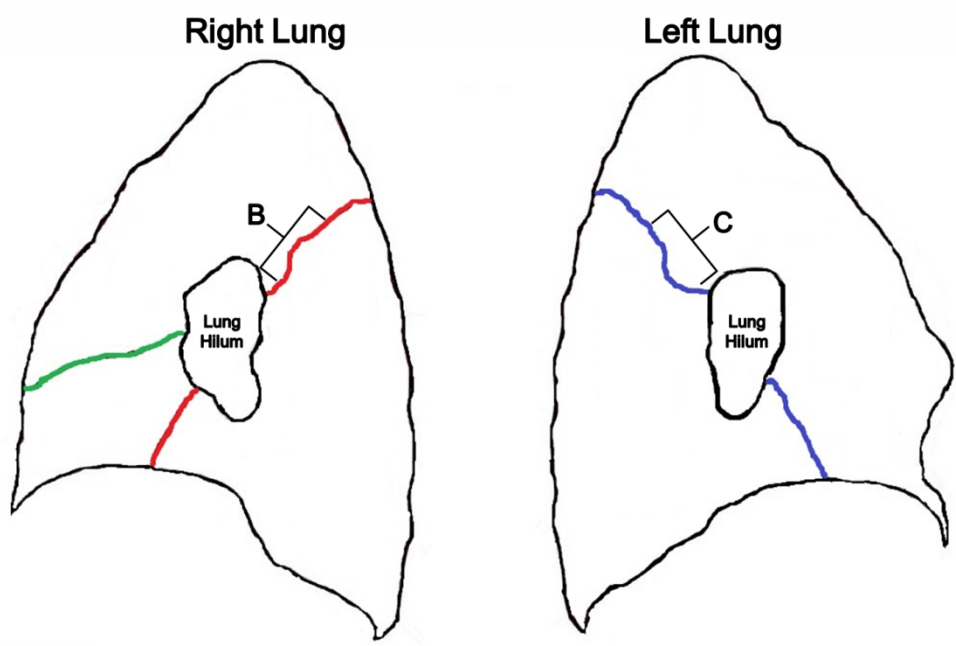


The right horizontal fissure is completely absent.



Lateral view of the lungs, green line denotes the right horizontal fissure, red line the right oblique fissure and blue line the left oblique fissure. Measurements were taken along these lines. Label A denotes the region where the right horizontal fissure would be incomplete, as per Figure 2.

1  
2  
3  
4  
5  
6  
7  
8  
9  
10  
11  
12  
13  
14  
15  
16  
17  
18  
19  
20  
21  
22  
23  
24  
25  
26  
27  
28  
29  
30  
31  
32  
33  
34  
35  
36  
37  
38  
39  
40  
41  
42  
43  
44  
45  
46  
47  
48  
49  
50  
51  
52  
53  
54  
55  
56  
57  
58  
59  
60



Medial view of the lungs, labels B and C demonstrate the areas where the right oblique fissures and left oblique fissures, respectively, are incomplete in this study.