



Gallacher, N., Gormley, M., Pring, M., & Revington, P. J. D. (2020).
Sinonasal Papilloma: Diagnosis following dental pain. *Oral Surgery*.
<https://doi.org/10.1111/ors.12538>

Peer reviewed version

Link to published version (if available):
[10.1111/ors.12538](https://doi.org/10.1111/ors.12538)

[Link to publication record in Explore Bristol Research](#)
PDF-document

This is the author accepted manuscript (AAM). The final published version (version of record) is available online via Wiley at <https://onlinelibrary.wiley.com/doi/full/10.1111/ors.12538>. Please refer to any applicable terms of use of the publisher.

University of Bristol - Explore Bristol Research

General rights

This document is made available in accordance with publisher policies. Please cite only the published version using the reference above. Full terms of use are available:
<http://www.bristol.ac.uk/red/research-policy/pure/user-guides/ebr-terms/>

TITLE

Sinonasal Papilloma: Diagnosis following dental pain.

AUTHOR NAMES

Nicola Gallacher BSc (Hons), BDS, MFDS

Dental Core Trainee in Oral and Maxillofacial Surgery

University of Bristol Dental Hospital, Lower Maudlin Street, Bristol, BS1 2LY.

Corresponding author.

Email: Nicola.Gallacher@bristol.ac.uk

Mark Gormley BDS (Hons), MFDS, M Oral Surg, FHEA

Academic Clinical Fellow in Oral Surgery

University of Bristol Dental Hospital, Lower Maudlin Street, Bristol, BS1 2LY.

Email: Mark.Gormley@bristol.ac.uk

Miranda Pring, BSc (Hons), BDS, MFDS RCPS, PhD, FRCPath

Consultant Senior Lecturer in Oral Maxillofacial Pathology

University of Bristol Dental Hospital, Lower Maudlin Street, Bristol, BS1 2LY.

Email: Miranda.Pring@bristol.ac.uk

Peter Revington TD, BDS, MBBS, MScD, FDS FRCS(Eng)

Consultant in Oral and Maxillofacial Surgery

University of Bristol Dental Hospital, Lower Maudlin Street, Bristol, BS1 2LY.

Email: Peter.Revington@UHBristol.nhs.uk

ABSTRACT

Sinonasal papillomas (SPs) are benign neoplasms that arise within the nasal cavity. Diagnosis may be challenging, given the often non-specific symptoms including nasal obstruction, headaches and rhinorrhoea. SPs can be locally destructive, have a high tendency to reoccur and may be associated with transformation to squamous cell carcinoma. Management, therefore often, involves surgical excision and careful follow-up.

We present the case of a 48-year old male who was referred to the oral and maxillofacial surgery (OMFS) department following a two-week history of dental pain affecting the upper right quadrant. This case report aims to raise awareness of SPs amongst dentists to ensure they are considered as part of a comprehensive differential diagnosis. The case report also highlights the complexities with both diagnosis and treatment, often requiring a multidisciplinary approach.

BACKGROUND

The sinonasal tract contains unique ciliated epithelium called the Schneiderian mucosa which can give rise to rare benign neoplasms called Sinonasal Papillomas (previously termed Schneiderian papillomas; SPs) They can be classified into three histological subtypes: Inverted Sinonasal Papilloma (ISP), Exophytic Sinonasal Papillomas (ESP) and Oncocytic Sinonasal Papilloma (OSP) in addition to squamous cell papilloma of the nasal vestibule ⁽¹⁻⁴⁾. ISP and ESP are most common, and the inverted form is reported to have the highest risk of malignant transformation ⁽⁵⁾. SPs are rare, accounting for only 0.4-7% of nasal neoplasms ⁽⁵⁾. In addition, they are often accompanied by non-specific symptoms, so papillomas can easily be misdiagnosed, resulting in delayed treatment. As SPs are locally destructive and difficult to fully excise, they have a high tendency to reoccur.

CASE REPORT

A 48-year-old male was urgently referred to oral and maxillofacial surgery (OMFS) team by his general dental practitioner. The patient had presented following a two-week history of pain and tenderness intra-orally, affecting the upper right quadrant. Eight years prior to this, teeth 13, 14 and 15 had been avulsed, re-implanted and root canal treated following midface trauma.

Medically, the patient was fit and well, with no known allergies but had a family history of bowel and hepatic cancer. Socially, the patient smoked cannabis and consumed 9 units of alcohol daily.

On examination, a swelling was noted in the buccal sulcus adjacent to tooth 13. An initial periapical radiograph taken revealed an abnormal periapical area, tooth 13 and external root resorption associated with a defective root canal treatment in this tooth. A further computed tomograph (CT) identified an invasive mass within in the right maxillary sinus which extended into the ethmoid sinuses and the lateral wall of the right nose, causing damage to the superior and middle conchae and medial wall of the orbit (**Fig.1a & 1b**). This was subsequently confirmed with an anterior rhinoscopy.

A Caldwell-Luc biopsy was performed under general anaesthesia and histopathological results identified the mass as an ISP with mild focal dysplasia (**Fig.2**). In order to treat this condition, a multidisciplinary approach was required and the patient was referred to the ears, nose and throat (ENT) department who performed a medial maxillectomy. Due to the extent of the papilloma, the nasal turbinates and medial wall of the maxilla were removed. This resected specimen showed no evidence of malignancy; however, the patient will continue to have regular review, as is the standard protocol for SP patients. At 7-month follow-up, flexible nasoendoscopy was performed which showed no recurrence.

DISCUSSION

SPs were first described in 1854 by Ward ⁽²⁾ and in 2017, the World Health Organisation reclassified SPs using three distinct subtypes ⁽³⁾. However, uncertainty still remains regarding their classification, aetiology and rate of malignant transformation. Proposed risk factors include smoking, chronic inflammation ^(2, 5, 7) and the human papilloma virus (HPV) ^(8, 9). Typically, non-specific symptoms such as nasal obstruction, rhinorrhoea and headaches are reported, ⁽⁸⁾ however, the patient in this case presented complaining of primarily of dental pain, meaning such patients could initially present to the dental team.

Of the three subtypes, ISP are most common in males within the 5th or 6th decades of life ^(5, 6). Similarly, ESP also have a higher predilection for males but mainly affect individuals at a

younger age, within the 3rd to 5th decades of life ^(5,6). The least commonly occurring subtype is OSP ^(5,6). SP subtypes have differing anatomical and histological features, which can be useful diagnostic markers. SPs rarely occur bilaterally, with ISP and OSP commonly arising from the lateral nasal wall and paranasal sinuses, whereas ESP are more often found closer to the nasal septum ^(2,5). ISP can have a thickened squamous, translational or respiratory epithelium and often lobulated appearance. In this ISP case there was evidence of focal mild dysplasia and reactive atypia present, which is commonly seen in these cases. Severe atypia and marked keratinisation would be more concerning features, which were not present here. (**Fig. 2**). OSPs appear as firm polyps and consist of several layers of oncocytic columnar epithelium, while ESPs are distinguished by proliferating pedunculated masses of squamous, translational or respiratory epithelium, similar in appearance to papillomas that affect other organs, such as the larynx ^(2,5).

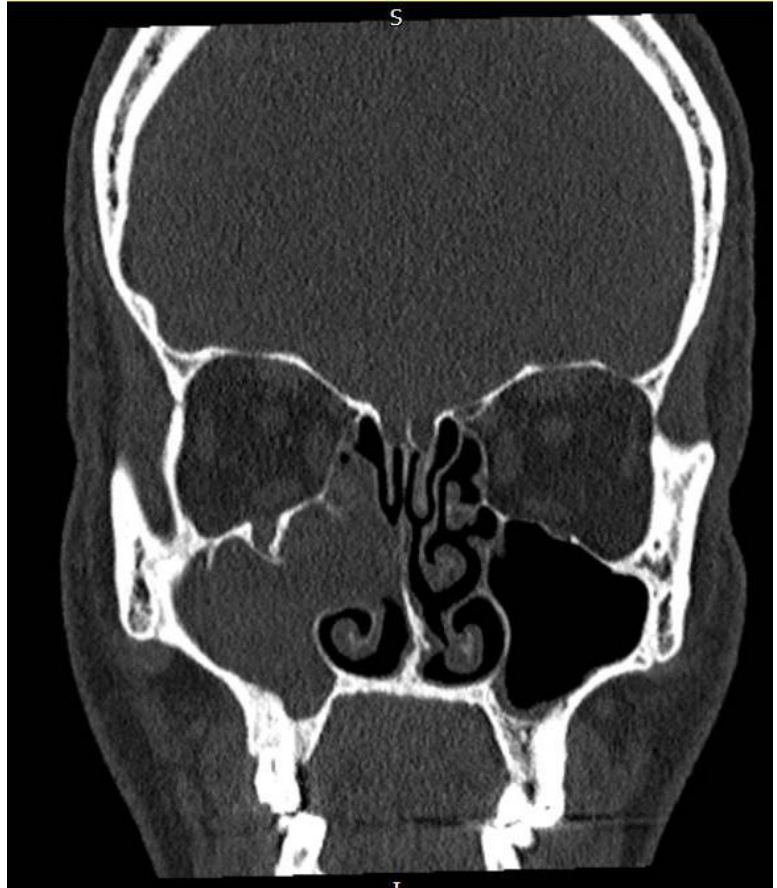
The risk of malignant transformation also varies between subtypes, with ISP having the highest rate of 5-15% ^(2,6). Molecular studies show supportive evidence of clonality in ISP. Worryingly, reports have demonstrated that if only local excision is performed 50-70% of ISP can recur ^(5,10). OSPs have a similar rate of malignant transformation to ISPs, whereas ESPs are not usually associated with malignancy, however all subtypes harbour a potential risk of recurrence and therefore warrant regular follow-up ^(2,6). An association between HPV and SPs has been described. There appears to be a stronger association with ESPs and HPV compared with ISPs or OSPs. While no HPV was detected in this case, some studies have demonstrated the presence of HPV 16 or 18 (defined as high risk HPV subtypes, also associated also with oropharyngeal squamous cell carcinoma) and an increased risk of malignancy. SPs containing other HPV subtypes 6 and 11 are defined as low risk, with a very low predilection for malignant transformation ^(10,11).

CONCLUSION

This case demonstrates the need to consider SPs when patients present with non-specific nasal symptoms alongside dental pain. There are diagnostic difficulties that may be associated with SPs, given that they can resemble benign nasal polyps, rhinosinusitis or malignancy. Due to local invasion and destruction of bone, the tendency for recurrence and associated risk of malignancy means complete surgical excision is often the treatment of choice.

FIGURES

1a

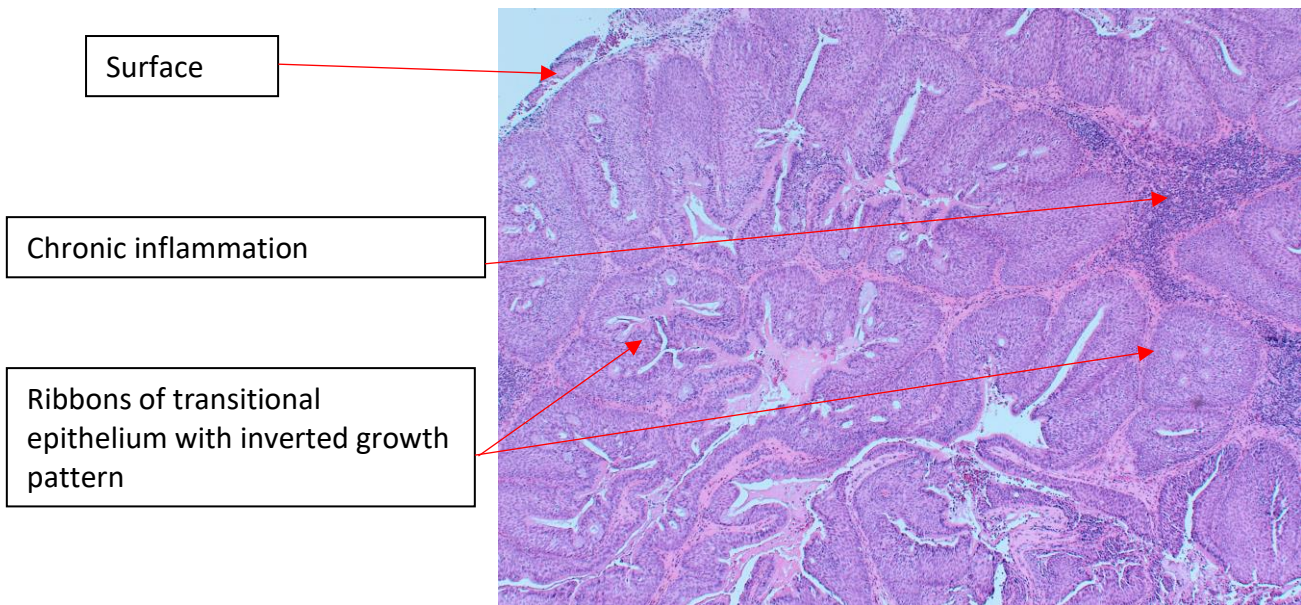


1b

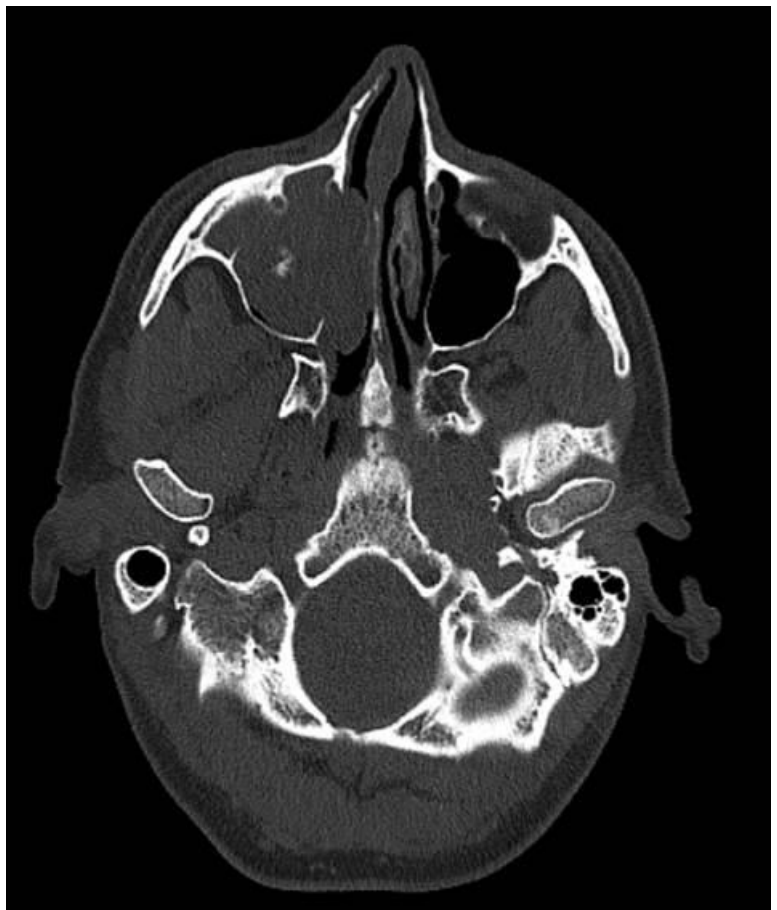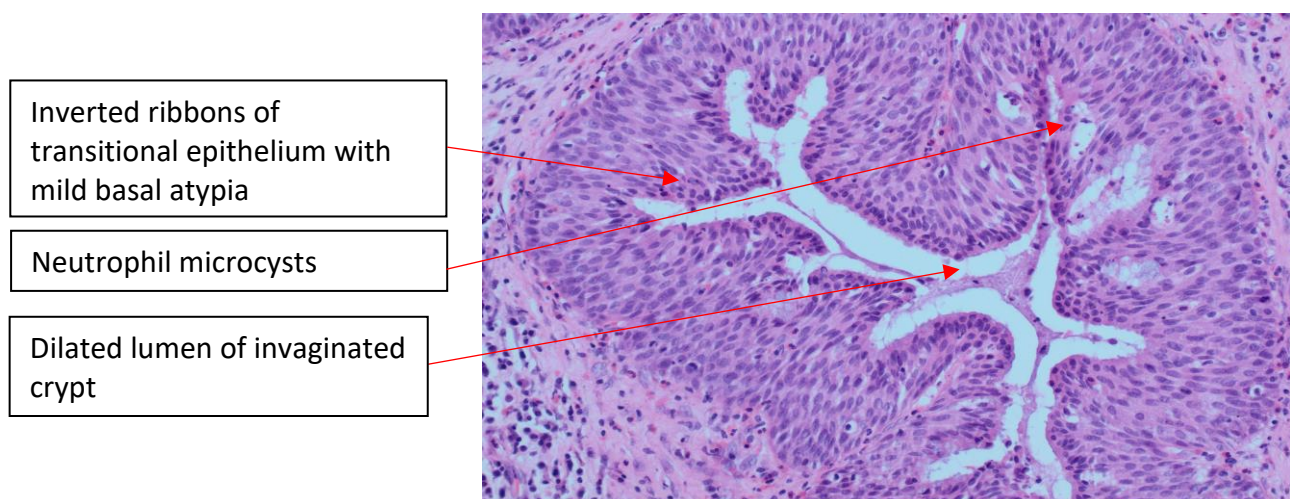


Figure 1a & 1b: Coronal (1a) and axial (1b) views of a CT scan demonstrating erosion of medial maxillary sinus wall and unilateral radiopacity of the right maxillary sinus, ethmoid sinus and nasal cavity.

Figure 2a & 2b. Photomicrograph H+E stained sections showing an inverted sinonasal papilloma comprising invaginated ribbons of transitional type epithelium with typical neutrophil microabscess. There were foci of mild basal atypia



2a. H+E examination x 2 magnification



2b. H+E x 20 magnification

References

- 1) Eggers G, Muhling J, Hassfeld S. Inverted papilloma of paranasal sinuses. *Journal of Cranio-maxillofacial Surgery*. 2007; 35(1): 21-9.
- 2) Bishop JA. OSPs and ESPs and ISPs, Oh My! An Update on Sinonasal (Schneiderian) Papillomas. *Head and Neck Pathol*. 2017; 11(3): 269-277.
- 3) Hunt JL, Bell D, Sarioglu S. Sinonasal papilloma, inverted type. In: El-Naggar A, Slootweg PJ, Chan JKC, et al., eds. *World Health Classification of Tumors: Head and Neck*. Lyon, France: IARC Press; 2017:18-19.
- 4) Neagos A, Cortocoiu A, Duca D et al. Inverted papilloma of the nasal cavity- case report. *Romanian Journal of Rhinology*. 2014; 4(13).
- 5) Bin X. Nasal cavity, paranasal sinuses, nasopharynx. *Benign/ nonneoplastic lesions: epithelial. Sinonasal papilloma*. Retrieved 15th June 2019 from: <http://www.pathologyoutlines.com/topic/nasalsinonasalpapilloma.html>. Last accessed 8/7/19.
- 6) Nicolae V, Sabau M, Fage Tan M, et al. Clinical and histological aspects of malignant inverted sinonasal papilloma. *Two case reports Romanian Journal of Morphology & Embryology*. 2016; 57(1): 289-294.
- 7) Lisan Q, Laccourreye O, Bonfils P. Sinonasal inverted papilloma: From diagnosis to treatment. *European Annals of Otorhinolaryngology, Head and Neck Diseases*. 2016; 133(5): 337-341.
- 8) Mohajeri S, Lai C, Purgina B et al. Human papillomavirus: An unlikely etiologic factor in sinonasal inverted papilloma. *Laryngoscope*. 2018; 128(11);2443-2447
- 9) Beck J, McClatchey K, Lesperance M et al. Human papillomavirus types important in progression of inverted papilloma. *Otolaryngol Head Neck Surg*. 1995; 113(5):558-63.
- 10) Mak W, Webb D, Al-salihi et al. Sinonasal inverted papilloma recurrence rates and evaluation of current staging systems. *Rhinology*. 2018; 56(4):407-414.
- 11) Mendenhall W, Hinerman R, Malyapa R et al. Inverted papilloma of the nasal cavity and paranasal sinuses. *AM J Clinic Oncol*. 2007; 30(5): 560-3.