



Hoey, C., Nye, G., Fadda, A., Bradshaw, J., & Barker, E. N. (2020). Sub-arachnoid diverticulum associated with feline infectious peritonitis in a Siberian cat. *Journal of Feline Medicine and Surgery Open Reports*, 6(2). <https://doi.org/10.1177/2055116920941477>

Publisher's PDF, also known as Version of record

License (if available):
CC BY-NC

Link to published version (if available):
[10.1177/2055116920941477](https://doi.org/10.1177/2055116920941477)


[Link to publication record in Explore Bristol Research](#)
PDF-document

This is the final published version of the article (version of record). It first appeared online via Sage Publications at <https://doi.org/10.1177/2055116920941477>. Please refer to any applicable terms of use of the publisher.

University of Bristol - Explore Bristol Research

General rights

This document is made available in accordance with publisher policies. Please cite only the published version using the reference above. Full terms of use are available: <http://www.bristol.ac.uk/red/research-policy/pure/user-guides/ebr-terms/>



Subarachnoid diverticulum associated with feline infectious peritonitis in a Siberian cat

Christopher Hoey¹, George Nye¹, Angela Fadda², Janet Bradshaw¹ and Emi N Barker^{1,3} 

Journal of Feline Medicine and Surgery Open Reports
1–8

© The Author(s) 2020

Article reuse guidelines:

sagepub.com/journals-permissions

DOI: 10.1177/2055116920941477

journals.sagepub.com/home/jfmsopenreports

This paper was handled and processed by the European Editorial Office (ISFM) for publication in *JFMS Open Reports*



Abstract

Case summary A 7-month-old Siberian cat was presented for investigation of acute onset multifocal neurological deficits. Neurological examination documented dull mental status and an ambulatory left hemiparesis. Serum biochemistry documented marked hyperglobulinaemia. MRI of the brain identified marked leptomeningeal contrast enhancement extending along the brainstem caudally to involve the cranial cervical spinal cord. MRI of the cervical spine further identified a subarachnoid diverticulum that extended from the level of the obex to the C2–C3 vertebrae. Cerebrospinal fluid quantitative RT-PCR was positive for the presence of feline coronavirus. Histopathology revealed pyogranulomatous meningitis and choroid plexitis, uveitis and nephritis.

Relevance and novel information This article describes the first reported case of a subarachnoid diverticulum associated with feline infectious peritonitis.

Keywords: Feline infectious peritonitis; FIP; MRI; neurolocalisation; spinal cord

Accepted: 18 June 2020

Case description

A 7-month-old female spayed Siberian cat was presented with a 4-day history of acute progressive dullness, left hemiparesis and ataxia. There was no known history of trauma. The cat was up to date with core vaccinations, had no travel history outside of the UK and was fed a veterinary practice own-brand grain-free chicken-based diet designed for kittens. The cat had intermittent mixed-pattern diarrhoea since ownership. Prior faecal analysis detected both *Giardia* species and feline coronavirus (FCoV) by PCR (IDEXX Feline Diarrhoea Panel; IDEXX Laboratories). The *Giardia* species infection had been managed with fenbendazole (50 mg/kg PO q24h) initially and, owing to compliance issues, subsequently switched to metronidazole (10 mg/kg PO q12h for 5 days), which improved faecal consistency. No medications had been administered in the 3 weeks prior to presentation and during hospitalisation other than those associated with performance of diagnostic procedures (eg, anaesthetic agents and contrast agent).

On physical examination the cat was in lean body condition (body condition score 4/9) and weighed

2.3 kg. Ophthalmic examination revealed bilateral iris pigment changes suggestive of uveitis (Figure 1). Neurological examination (Table 1) documented dull mental status and absent proprioception (hopping and paw placement) in the left forelimb and hindlimb, resulting in left-sided hemiparesis. The rest of the examination was unremarkable.

Haematology (Table 2) revealed a moderate, microcytic, non-regenerative anaemia, lymphopenia and neutrophil toxicity. Blood biochemistry (Table 2) revealed marked hyperproteinaemia secondary to an extreme hyperglobulinaemia, with an albumin:globulin ratio of 0.2; a mild

¹Bristol Veterinary School, University of Bristol, Langford, Bristol, UK

²Langford Vets, Langford, Bristol, UK

³The Feline Centre, Langford Vets, Langford, Bristol, UK

Corresponding author:

Emi N Barker BSc (Hons), BVSc (Hons), PhD, DipECVIM-CA, The Feline Centre, Langford Vets, Langford, Bristol BS40 5DU, UK
Email: emi.barker@bristol.ac.uk



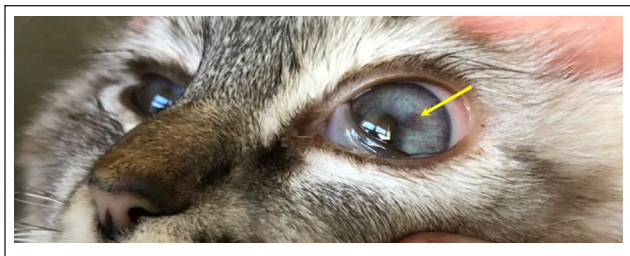


Figure 1 Ophthalmic examination revealed bilateral iris pigment changes (arrow) suggestive of uveitis

hypoalbuminaemia; mildly increased alanine aminotransferase, creatine kinase and aspartate aminotransferase activities; a low creatinine; and mild hyperglycaemia. *Toxoplasma gondii*, feline leukaemia virus and feline immunodeficiency virus serology was negative, while feline coronavirus serology was positive with a high titre (Table 2).

An MRI study of the brain and cervical spine, including postcontrast images, was performed under general anaesthesia (see document 1 in the supplementary

Table 1 Neurological examination findings for the cat at time of admission

Observation					
Mentation (alert/depressed/disoriented/stupor/coma):	Depressed				
Posture (normal/head tilt/tremor/falling):	Falling				
Gait (normal/ataxia/circling; limb[s] affected):	Ataxia; tetra				
Paresis (absent/present; limb[s] affected):	Present; hemi (left)				
Other:	Absent proprioception (hopping and paw placement) in the left forelimb and hindlimb				
Postural reactions	Left forelimb	Right forelimb	Left hindlimb	Right hindlimb	
Wheelbarrow	NE	NE	NE	NE	
Hopping	0	2	1	2	
Extensor postural thrust	NE	NE	NE	2	
Proprioceptive positioning	0	2	1	2	
Hemi-standing/walking	NE	2	NE	2	
Placing (tactile)	0	2	NE	NE	
Placing (visual)	0	2	NE	NE	
Spinal reflexes	Left forelimb	Right forelimb	Left hindlimb	Right hindlimb	
Patellar	–	–	2	2	
Extensor carpi/tibialis cranialis	2	2	NE	NE	
Withdrawal	2	2	2	2	
Perineal	–	–	2	2	
Cranial nerves	Left	Right	Left	Right	
Vision, menace (II, VII)	2	2	Resting nystagmus (VIII)	2	2
Pupils at rest (II, III)	2	2	Positional nystagmus (VIII)	2	2
Pupillary light reflex (left eye)	2	2	Facial sensation (V)	2	2
Pupillary light reflex (right eye)	2	2	Facial movement (VII)	2	2
Fundus (II)	2	2	Palpebral reflex (V, VII)	2	2
Resting strabismus (III, IV, VI)	2	2	Gag reflex (IX, X)	2	2
Positional strabismus (III, IV, VI, VIII)	2	2	Tongue movement (XII)	2	2
Comments: Bilateral iris pigment changes suggestive of uveitis					
Sensation	Grade	Location and description of abnormalities			
Hyperaesthesia	2	–			
Superficial pain	2	–			
Cutaneous trunci reflex	2	–			
Deep pain	2	–			

4 = exaggerated, clonus; 3 = exaggerated; 2 = normal; 1 = diminished; 0 = none; NE = not evaluated

Table 2 Haematology, blood biochemistry and infectious disease screening for the cat at time of admission

Test	Result	RI
Manual reticulocytes ($\times 10^{12}/l$)	0.00	
Haemoglobin (g/dl)	6.2*	8.1–14.2
Haematocrit (%)	18.2*	27.7–46.8
Red blood cells ($\times 10^{12}/l$)	4.18	6.00–10.10
Mean cell volume (fl)	43.5	41.3–52.6
Mean cell haemoglobin (pg)	14.9	12.0–16.0
Mean cell haemoglobin concentration (g/dl)	34.2	27.0–32.8
Platelets ($\times 10^9/l$)	153*	156–626
White blood cells ($\times 10^9/l$)	5.64*	6.30–19.60
Neutrophils ($\times 10^9/l$)	5.19	3.00–13.40
Lymphocytes ($\times 10^9/l$)	0.39*	2.00–7.20
Monocytes ($\times 10^9/l$)	0.06	0–1.00
Eosinophils ($\times 10^9/l$)	0*	0.3–1.7
Basophils ($\times 10^9/l$)	0	0–0.1
Smear comment	Platelets plentiful with macrothrombocytes present; neutrophil toxicity (cytoplasmic basophilia and Doehle bodies); 5% Heinz bodies; mild anisocytosis, moderate microcytosis and mild rouleaux formation	
Creatinine ($\mu\text{mol}/l$)	71*	133–175
Urea (mmol/l)	7.2	6.5–10.5
Total protein (g/l)	121.0*	77.0–91.0
Albumin (g/l)	20.4*	24.0–35.0
Globulin (g/l)	100.6*	21.0–51.0
Albumin:globulin ratio	0.2	
Total bilirubin ($\mu\text{mol}/l$)	8.5	0–10.0
Alanine aminotransferase (U/l)	94*	15–45
Alkaline phosphatase (U/l)	13*	15–60
Gamma-glutamyl transferase (U/l)	0	0–2
Creatine kinase (U/l)	726*	50–150
Aspartate aminotransferase (U/l)	82*	0–20
Sodium (mmol/l)	152.2	149.0–157.0
Potassium (mmol/l)	4.00	4.00–5.00
Chloride (mmol/l)	118	115–130
Total calcium (mmol/l)	2.22*	2.30–2.50
Phosphorus (mmol/l)	1.44	0.95–1.55
Glucose (mmol/l)	9.4*	3.5–5.0
<i>Toxoplasma gondii</i> quantitative PCR	Not detected in whole blood	
<i>Toxoplasma gondii</i> serology	IgG and IgM antibody not detected	
Feline leukaemia virus serology	Antigen not detected	
Feline immunodeficiency virus serology	Antibody not detected	
Feline coronavirus serology	Positive (antibody titre $\geq 10,240$)	

*Outwith the reference interval (RI)

material) and revealed dorsal and ventral dilation of the subarachnoid space that extended from the obex to the first cervical segments, and showed abrupt narrowing at the level of the C2–C3 intervertebral space (Figure 2a). This resulted in dorsoventral flattening of the cord at this level on transverse images, which was more marked on the right (Figure 2b). Immediately caudally to the end of this lesion and throughout most of the

cervical spine, the cord assumed a swollen appearance and showed irregular distributed T2-weighted hyperintensity within the left dorsal compartment at the level of C1, and diffusely surrounding the central canal from C2 to C6 (Figure 2a). There was marked leptomeningeal contrast enhancement surrounding the cranial cervical cord (Figure 2c,d) and along the brainstem, suggestive of an inflammatory process.

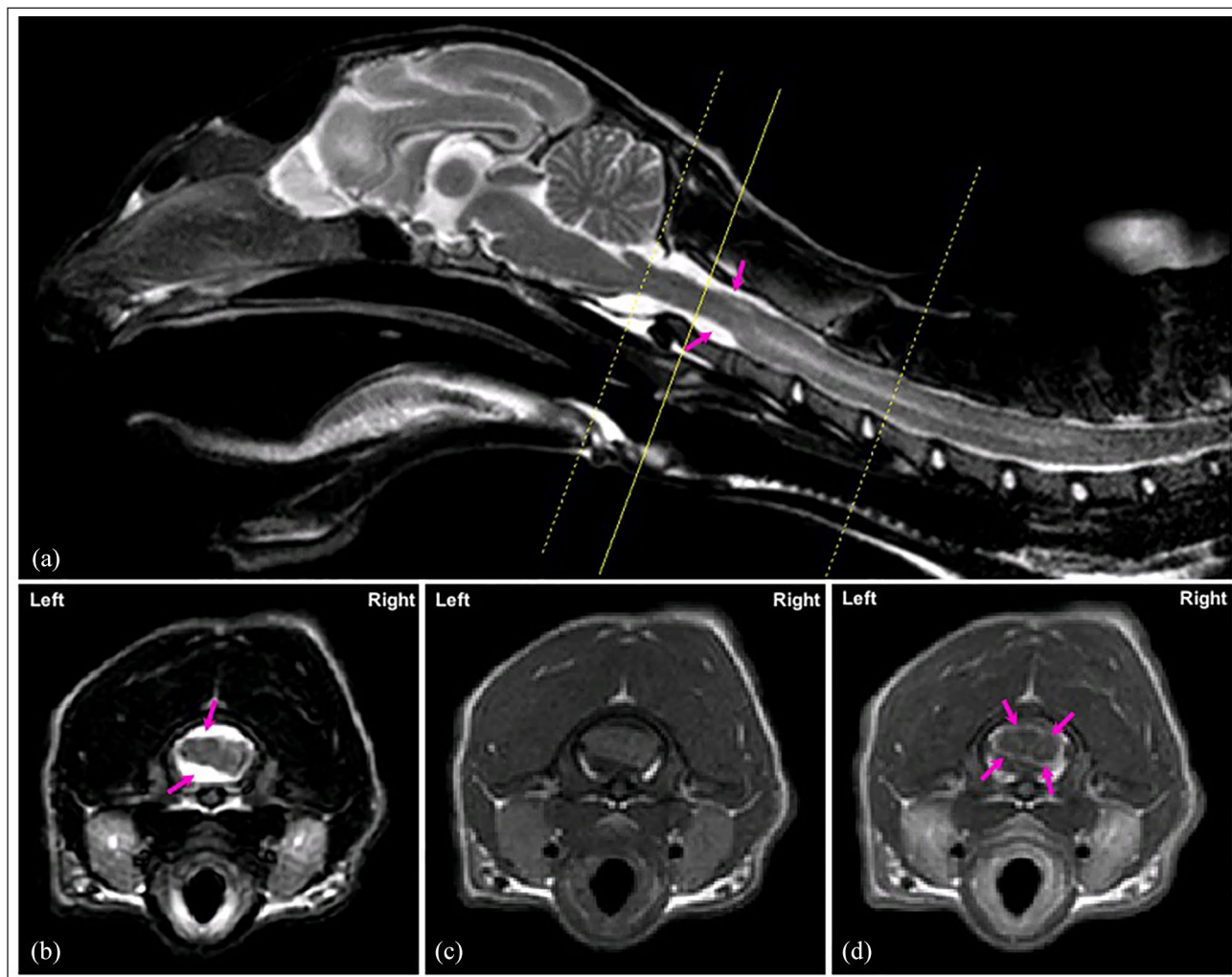


Figure 2 (a) Midline, sagittal, T2-weighted (T2W) MRI of the brain and cranial cervical spinal cord and (b) transverse T2W, (c) T1-weighted (T1W) and (d) T1W post-gadolinium MRI of the vertebral column at the level of mid-C1 (indicated by the solid yellow line on image [a]). Marked compression of the caudal medulla oblongata and cranial cervical spinal cord compression by a partially right-lateralised subarachnoid diverticulum is visible, particularly on T2W images (a,b; arrows). Leptomeningeal contrast enhancement is seen surrounding the cranial cervical cord (d; arrows)

Table 3 Cerebrospinal fluid analysis results

	Result	Reference interval ^{1,2}
Protein (mg/dl)	457.2	<30.0
Total nucleated cell count (cells/ μ l)	267	<2
Cytology	88% non-degenerative neutrophils, 2% small lymphocytes, 10% large mononuclear cells	
FCoV RT-qPCR	Positive. Detected at a moderate copy number (CT value 24.69)	

Sample collected by cisternal puncture

FCoV = feline coronavirus; RT-qPCR = reverse transcriptase quantitative PCR; CT = cycle threshold

Analysis of cerebrospinal fluid (CSF) collected by cisternal puncture documented a marked neutrophilic pleocytosis (Table 3; Figure 3). The presence of FCoV RNA within the CSF at a moderate-to-high level was revealed using reverse transcriptase quantitative PCR (RT-qPCR).³

The cat was subsequently euthanased owing to further decline in its condition, in conjunction with the strong suspicion of FIP and poor associated prognosis. The owner consented to a post-mortem examination, which was performed (by ENB) immediately after

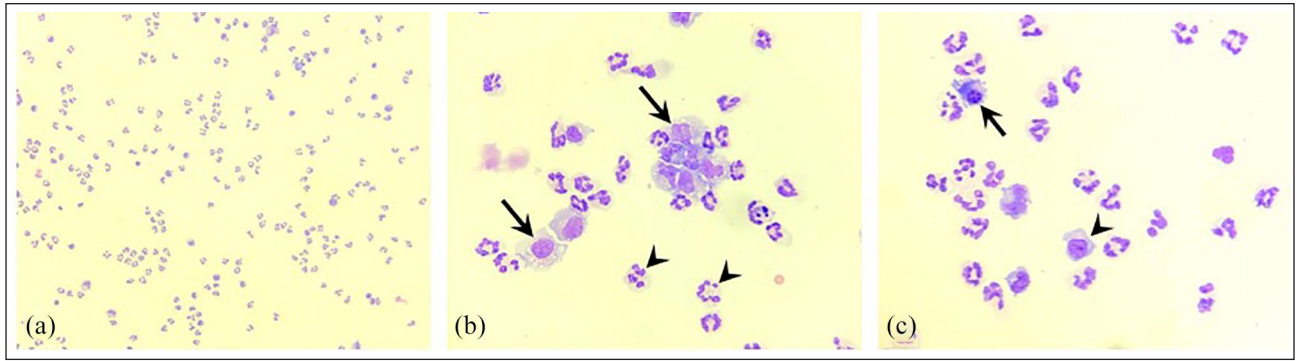


Figure 3 (a) Cisternal cerebrospinal fluid cytology revealed a predominantly neutrophilic pleocytosis, with (b) non-degenerative neutrophils (arrowheads) and large mononuclear cells (arrows). (c) Less frequently reactive lymphocytes (arrowhead) and plasma cells (arrow) were noted. Modified Wright's stain (cytospin preparation; (a) $\times 20$) and (b,c) $\times 50$ objective magnification). Courtesy of Elpida Sarvani, Diagnostic Laboratories, Langford Vets

euthanasia. There was no evidence of effusion within any body cavity. Both kidneys had multiple, pale, mass lesions present within the cortices (Figure 4a). Upon

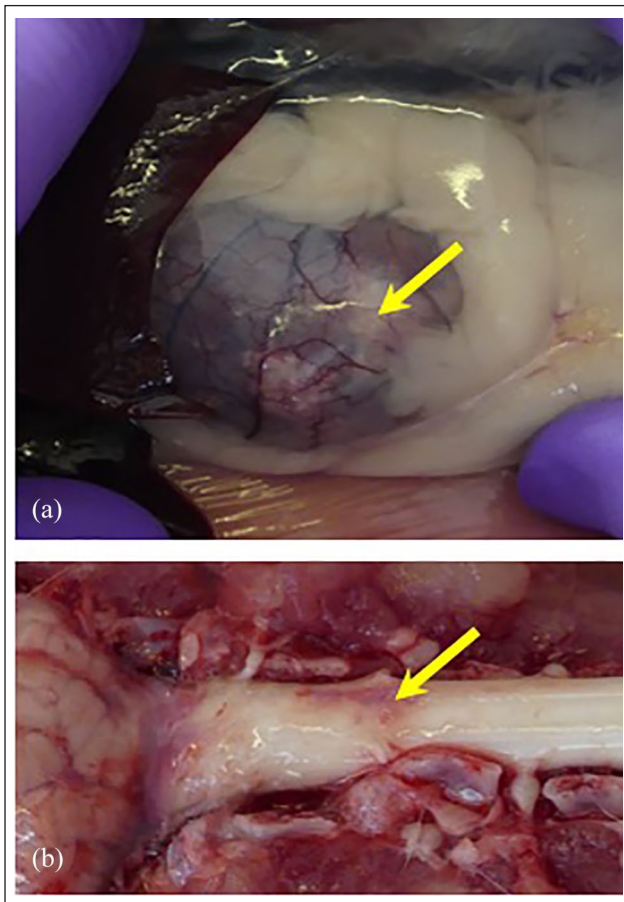


Figure 4 At post mortem examination (a) multiple, pale, mass lesions (arrow; left kidney shown) were visible within the renal cortices. Following removal of the overlying bone and meninges, (b) the dorsal surface of the spinal cord appeared bruised at the level C2 (arrow)

removal of the overlying bone and meninges the spinal cord appeared bruised at the level of the previously noted compression (Figure 4b).

Histopathology of the brain and spinal cord documented marked inflammation expanding the meninges, particularly around the medulla, mid-brain (most marked around the thalamus and hippocampus), ventral forebrain and spinal cord (at all levels examined). Inflammation was mixed, with many plasma cells, histiocytic cells and moderate numbers of neutrophils. There was some free blood and eosinophilic fibrinous fluid within the meninges, and the occasional vessel walls were degenerate or contained a proliferation of fibroblastic cells within their lumen. The choroid plexuses at these levels were markedly inflamed and hyperplastic. There was also mild inflammation within the ventricles. Elsewhere in the body there was mild-to-moderate pyogranulomatous uveitis, extensive pyogranulomatous nephritis and mild hepatic portal inflammation (predominantly plasma cells and histiocytic cells). Within the mesenteric lymph nodes and spleen there was evidence of immune stimulation with active lymphoid follicles, mild increases in plasma cells and histiocytes. The small and large intestine showed evidence of mild inflammation, alongside the presence of protozoa within the small intestine (likely *Giardia* species based on prior faecal analysis).

Discussion

This is the first report, to our knowledge, to describe a subarachnoid diverticulum associated with FIP.

Spinal arachnoid diverticula (SAD) are characterised by a focal dilation of the meninges permitting the accumulation of CSF, which, in turn, compresses the spinal cord.⁴ SAD are considered rare in cats and often thoracolumbar in localisation, with only one case report of acquired cervical SAD found in the literature.⁵ Intervertebral disc disease, spinal cord trauma and inflammatory spinal cord disease have been

suggested as possible causes of acquired SAD in cats, dogs and humans;^{4,5} however, as most cases are not imaged prior to the development of SAD, the presence of a congenital lesion cannot be ruled out. Clinical signs attributed to the presence of SAD are consistent with a chronic, progressive myelopathy with neurolocalisation dependent upon the site of compression.⁶ Differentials initially considered for the subarachnoid diverticulum in this case included a primary/congenital structural lesion exacerbated by acquired inflammatory infiltrate or, more likely, an acquired structural lesion secondary to inflammatory infiltrate causing adhesions. Ante-mortem, we were strongly suspicious of an FIP-associated arachnoiditis as the origin of the SAD, supported by the MRI findings and presence of FCoV within the CSF. Ultimately, post-mortem collected samples revealed the presence of granulomatous to pyogranulomatous inflammation affecting the meninges, ventricles, choroid plexus and spinal cord, consistent with a diagnosis of neurological FIP, with evidence of additional non-effusive FIP changes involving the eyes, liver and kidneys.⁷

Treatment options for SAD are limited, with most feline case reports describing surgical decompression.⁵ In a large case series of dogs with SAD, the outcome of conservatively (ie, medically, often with the glucocorticoid prednisolone) managed cases was relatively poor (n = 50; neurological signs were stable in 30% and improved in 30%), when compared with the outcome of surgically managed cases (n = 46; neurological signs were stable in 3% and improved in 82%);⁴ however, this was a retrospective case series and it is possible that more severely affected cases were elected to be managed medically. Recurrence of clinical signs after surgery for SAD has been reported infrequently for both cats and dogs, with the median time from surgery to recurrence of SAD being 20.5 months.⁶

In the absence of the experimental antiviral drug GS-441524, prognosis associated with neurological FIP is generally grave,⁸ although there are occasional reports of cats surviving clinical FIP.⁷ The presence of neurological signs has also been associated with poor response to, or relapse following, initial trial doses of recently described antiviral drugs GC376 and GS-441524, which have been successful in the management of effusive FIP.^{9,10} A median survival onset of clinical signs of 14 days (range 2–115 days) in 24 cats with neurological FIP has been reported in one study,¹¹ comparable to that of the effusive form of the disease.¹² Neurological FIP describes a subset of cats that present with predominantly neurological signs.¹³ Around 40% of cats with the non-effusive (ie, 'dry') form of FIP have neurological signs, although neurological signs also occur in around 5–10% of cats with effusive (ie, 'wet') FIP.^{11,13,14}

No evidence of effusions were found in this case. Management is aimed at supportive palliative care, with corticosteroids or other immunosuppressive medications administered in an attempt to slow disease progression. In the absence of readily available antivirals shown to be effective in the management of FIP,^{9,10} and given the dire prognosis, surgical decompression of the SAD was not considered to be ethical in this case.

The clinicopathological results were also suggestive of FIP. The microcytic, non-regenerative anaemia was considered most consistent with anaemia of chronic inflammatory disease with iron sequestration, with hepatic dysfunction or absolute iron deficiency considered less likely. Microcytosis, with or without anaemia, is frequently reported in FIP.¹⁴ The lymphopenia and neutrophil changes were consistent with a systemic inflammatory process. Although the differential list for hyperglobulinaemia is wide,¹⁵ the degree of hyperglobulinaemia was considered most consistent with a chronic inflammatory or infectious disease such as FIP, or a lymphoproliferative disease (eg, lymphoma or malignant plasma cell disorders). The mild hypoalbuminaemia was considered most likely compensatory to the severe hyperglobulinaemia and resultant elevated blood osmolarity. The elevations in liver and muscle enzyme activities were considered most likely secondary to systemic inflammation or tissue hypoxia resulting from increased blood viscosity. The low creatinine was attributed to reduced muscle mass.

FIP is the most common infectious cause of neurological disease in cats.¹⁶ A marked inflammatory reaction is triggered by release of inflammatory cytokines from FCoV-laden monocytes/macrophages resulting in multisystemic pyogranulomatous vasculitis.⁷ MRI abnormalities detected in FIP include meningeal contrast enhancement, ependymal contrast enhancement, ventriculomegaly (inflammation may cause obstruction of the ventricular system, which may cause a secondary mass effect and compromise surrounding parenchyma), syrinx formation and foramen magnum herniation.¹¹ Commonly recognised spinal signs include hindlimb or generalised ataxia and paraspinal hyperaesthesia, with associated spinal pathology, which may contain a syrinx or myelitis.

Ideally, prompt diagnosis of FIP is required to minimise further distress to patient and client through additional diagnostic procedures; however, ante-mortem diagnosis of FIP can be challenging, particularly for neurological FIP where minimally invasive sampling of the affected tissue is limited by the skull and vertebral column, and advanced imaging studies are not 100% sensitive. In a study that described the MRI features of feline meningoencephalitis, 2/8 cats with neurological FIP had unremarkable MRI studies.¹⁷ Further, cats with

non-effusive FIP are less likely to show fever or classical haematological and serum biochemical changes (eg, lymphopenia, hyperbilirubinaemia, hyperproteinaemia and hypoalbuminaemia).¹⁴ Confirmation of FIP using immunocytochemistry to co-localise the presence of FCoV within macrophages or by the demonstration of viral RNA within CSF are limited by sensitivity and specificity. One study that used immunocytochemical staining of CSF preparations for FCoV antigen to diagnose FIP had a specificity of 83% and a sensitivity of 85%.¹⁸ Interestingly, more of the cats with FIP but without neurological deficits were positive using this assay than those with neurological deficits. One study that examined the sensitivity of RT-qPCR of CSF in the diagnosis of FIP to be 42.1% overall, rising to 85.7% for seven cats with neurological or ocular involvement.¹⁹ Another study looking at the use of RT-qPCR found viral RNA in the CSF of 50% of 10 cats with FIP that had samples collected post mortem, although whether neurological signs were present in these cats was not reported.³ Specificity in both RT-qPCR studies was 100% with a total of 34 samples from cats without FIP.³ Unfortunately, owing to limitations of RT-qPCR and immunocytochemistry, many consider that definitive diagnosis of FIP requires immunohistology to co-localise pyogranulomatous vasculitis with presence of FCoV in macrophages.⁷

Conclusions

To our knowledge, this unusual presentation is the first reported case of a subarachnoid diverticulum associated with FIP. Although not definitive, MRI can be a sensitive method for detecting evidence of meningoencephalitis, further supporting a diagnosis of neurological FIP alongside compatible signalment, clinical history, physical examination findings, haematology, serum biochemistry and CSF analysis.

Acknowledgements We thank our colleagues at the Veterinary Pathology Unit, Langford Vets, University of Bristol, who assisted in obtaining post-mortem samples.

Conflict of interest The authors declared no potential conflicts of interest with respect to the research, authorship, and/or publication of this article.

Funding The authors received no financial support for the research, authorship, and/or publication of this article.

Ethical approval This work involved the use of non-experimental animals only (including owned or unowned animals and data from prospective or retrospective studies). Established internationally recognised high standards ('best

practice') of individual veterinary clinical patient care were followed. Ethical approval from a committee was therefore not necessarily required.

Informed consent Informed consent (either verbal or written) was obtained from the owner or legal custodian of all animal(s) described in this work (either experimental or non-experimental animals) for the procedure(s) undertaken (either prospective or retrospective studies). For any animals or humans individually identifiable within this publication, informed consent (either verbal or written) for their use in the publication was obtained from the people involved.

ORCID iD Emi N Barker  <https://orcid.org/0000-0001-6293-6662>

References

- Rand JS, Parent J, Jacobs R, et al. **Reference intervals for feline cerebrospinal-fluid – biochemical and serologic variables, IgG concentration, and electrophoretic fractionation.** *Am J Vet Res* 1990; 51: 1049–1054.
- Rand JS, Parent J, Jacobs R, et al. **Reference intervals for feline cerebrospinal fluid: cell counts and cytologic features.** *Am J Vet Res* 1990; 51: 1044–1048.
- Barker EN, Stranieri A, Helps CR, et al. **Limitations of using feline coronavirus spike protein gene mutations to diagnose feline infectious peritonitis.** *Vet Res* 2017; 48: 60. DOI: 10.1186/s13567-017-0467-9.
- Mauler DA, De Decker S, De Risio L, et al. **Spinal arachnoid diverticula: outcome in 96 medically or surgically treated dogs.** *J Vet Intern Med* 2017; 31: 849–853.
- Adams RJ, Garosi L, Matiasek K, et al. **Acquired cervical spinal arachnoid diverticulum in a cat.** *J Small Anim Pract* 2015; 56: 285–288.
- Alcoverro E, McConnell JF, Sanchez-Masian D, et al. **Late-onset recurrence of neurological deficits after surgery for spinal arachnoid diverticula.** *Vet Rec* 2018; 182: 380. DOI: 10.1136/vr.104579.
- Kipar A and Meli ML. **Feline infectious peritonitis: still an enigma?** *Vet Pathol* 2014; 51: 505–526.
- Dickinson PJ, Bannasch M, Thomasy SM, et al. **Antiviral treatment using the adenosine nucleoside analogue GS-441524 in cats with clinically diagnosed neurological feline infectious peritonitis.** *J Vet Intern Med.* Epub ahead of print 22 May 2020. DOI: 10.1111/jvim.15780.
- Pedersen NC, Kim Y, Liu H, et al. **Efficacy of a 3C-like protease inhibitor in treating various forms of acquired feline infectious peritonitis.** *J Feline Med Surg* 2018; 20: 378–392.
- Pedersen NC, Perron M, Bannasch M, et al. **Efficacy and safety of the nucleoside analog GS-441524 for treatment of cats with naturally occurring feline infectious peritonitis.** *J Feline Med Surg* 2019; 21: 271–281.
- Crawford AH, Stoll AL, Sanchez-Masian D, et al. **Clinicopathologic features and magnetic resonance imaging findings in 24 cats with histopathologically confirmed**

- neurologic feline infectious peritonitis. *J Vet Intern Med* 2017; 31: 1477–1486.
- 12 Ritz S, Egberink H and Hartmann K. **Effect of feline interferon-omega on the survival time and quality of life of cats with feline infectious peritonitis.** *J Vet Intern Med* 2007; 21: 1193–1197.
 - 13 Foley JE, Lapointe JM, Koblik P, et al. **Diagnostic features of clinical neurologic feline infectious peritonitis.** *J Vet Intern Med* 1998; 12: 415–423.
 - 14 Riemer F, Kuehner KA, Ritz S, et al. **Clinical and laboratory features of cats with feline infectious peritonitis – a retrospective study of 231 confirmed cases (2000–2010).** *J Feline Med Surg* 2016; 18: 348–356.
 - 15 Taylor SS, Tappin SW, Dodkin SJ, et al. **Serum protein electrophoresis in 155 cats.** *J Feline Med Surg* 2010; 12: 643–653.
 - 16 Bradshaw JM, Pearson GR and Gruffydd-Jones TJ. **A retrospective study of 286 cases of neurological disorders of the cat.** *J Comp Pathol* 2004; 131: 112–120.
 - 17 Negrin A, Lamb CR, Cappello R, et al. **Results of magnetic resonance imaging in 14 cats with meningoencephalitis.** *J Feline Med Surg* 2007; 9: 109–116.
 - 18 Gruendl S, Matiasek K, Matiasek L, et al. **Diagnostic utility of cerebrospinal fluid immunocytochemistry for diagnosis of feline infectious peritonitis manifesting in the central nervous system.** *J Feline Med Surg* 2017; 19: 576–585.
 - 19 Doenges SJ, Weber K, Dorsch R, et al. **Detection of feline coronavirus in cerebrospinal fluid for diagnosis of feline infectious peritonitis in cats with and without neurological signs.** *J Feline Med Surg* 2016; 18: 104–109.