



**University of Dundee**

**Changes in RTPCR test results and symptoms during the menstrual cycle of female individuals infected with SARSCoV2**

Zheng, Hua; Tan, Juan; Ma, Ke; Meng, Weihua

*Published in:*  
Journal of Medical Virology

*DOI:*  
[10.1002/jmv.26275](https://doi.org/10.1002/jmv.26275)

*Publication date:*  
2021

*Document Version*  
Peer reviewed version

[Link to publication in Discovery Research Portal](#)

*Citation for published version (APA):*  
Zheng, H., Tan, J., Ma, K., & Meng, W. (2021). Changes in RTPCR test results and symptoms during the menstrual cycle of female individuals infected with SARSCoV2: report of two cases. *Journal of Medical Virology*, 93(1), 541-545. <https://doi.org/10.1002/jmv.26275>

**General rights**

Copyright and moral rights for the publications made accessible in Discovery Research Portal are retained by the authors and/or other copyright owners and it is a condition of accessing publications that users recognise and abide by the legal requirements associated with these rights.

- Users may download and print one copy of any publication from Discovery Research Portal for the purpose of private study or research.
- You may not further distribute the material or use it for any profit-making activity or commercial gain.
- You may freely distribute the URL identifying the publication in the public portal.

**Take down policy**

If you believe that this document breaches copyright please contact us providing details, and we will remove access to the work immediately and investigate your claim.



Hua Zheng ORCID iD: 0000-0003-0134-0990

## **Changes in RT-PCR test results and symptoms during the menstrual cycle of female individuals infected with SARS-CoV-2: report of two cases**

Hua Zheng<sup>1</sup>, Juan Tan<sup>1</sup>, Ke Ma<sup>2</sup>, Weihua Meng<sup>3</sup>

<sup>1</sup>Department of Anesthesiology, Tongji Hospital, Tongji Medical College, Huazhong University of Science and Technology, Wuhan, China.

<sup>2</sup>Department of Infectious Disease, Tongji Hospital, Tongji Medical College, Huazhong University of Science and Technology, Wuhan, China.

<sup>3</sup>Division of Population Health Sciences, School of Medicine, University of Dundee, Dundee, UK.

Correspondence:

Juan Tan, Department of Anesthesiology, Tongji Hospital, Tongji Medical College, Huazhong University of Science and Technology, 430030 Wuhan, China

Email: msdove@126.com

This article has been accepted for publication and undergone full peer review but has not been through the copyediting, typesetting, pagination and proofreading process, which may lead to differences between this version and the Version of Record. Please cite this article as doi: 10.1002/jmv.26275.

This article is protected by copyright. All rights reserved.

Accepted Article

---

**Abstract**

**Background:** The implications of the menstrual cycle for disease susceptibility, development, and severity of acute respiratory syndrome coronavirus 2 (SARS-CoV-2) infection are largely unknown.

**Case presentation:** Here we describe two women infected with SARS-CoV-2 whose RT-PCR test results and symptoms changed during the menstrual cycle. The first patient developed a fever on the first day of her menstrual period, and again on the first day of her next menstrual period after hospital discharge. RT-PCR test results were positive during the first menstrual period before admission, but turned negative during hospitalization, and then were positive again during the second menstrual period after hospital discharge. Another one also developed a fever again on the first day of her menstrual period after hospital discharge. RT-PCR test results were negative before admission and during hospitalization, but turned positive during the first menstrual period after hospital discharge.

**Conclusions:** The cases indicate sex hormones may play an important role in SARS-CoV-2 infection. For women with history of exposure to SARS-CoV-2, the management protocol should include assessment of the menstrual status.

**Keywords:** SARS-CoV-2, COVID-19, Menstrual cycle, Fever

This article is protected by copyright. All rights reserved.

---

## Background

The 2019 novel coronavirus infection (COVID-19), caused by severe acute respiratory syndrome coronavirus 2 (SARS-CoV-2), has emerged as a major global health threat since December 2019<sup>1-4</sup>. As of June 27, 2020, the pandemic had registered 9,473,214 cases and 484,249 deaths worldwide<sup>5</sup>. A population level observational study by Sun and colleagues<sup>6</sup> revealed that a sharp increase of COVID-19 was reported among people aged between 30 and 50 years, and 40% of the patients were female, indicates women of childbearing age are at high risk of infection. Growing evidences indicate that female immunity changes over the menstrual cycle<sup>7,8</sup>. However, the implications of the menstrual cycle for disease susceptibility, development, and severity of COVID-19 are largely unknown. Here, we report the epidemiologic and clinical features of two female individuals with SARS-CoV-2 infection and the infection's association with the menstrual cycle.

## Case presentation

### Case one

A 37-year-old, previously healthy (gravida 2, para 2, regular menstrual cycle, no history of hormonal therapies), woman had dinner with her relative on January 12, 2020. Five days later, her relative had a fever and was confirmed to be infected

---

with SARS-CoV-2. The woman had no fever or any other gastrointestinal or respiratory symptoms until January 28, 2020, the first day of her menstrual period (Figure 1A). At first, she had only a slight and intermittent fever. However, the next day afternoon, she developed high fever, tiredness, and lack of appetite. Because of the possibility of infection with SARS-CoV-2, she was prescribed ibuprofen, oseltamivir (75 mg every 12 h orally), arbidol (0.2 g every 8 h orally), and moxifloxacin (0.4 g every day orally) by a community physician. Lopinavir and Ritonavir tablets (200 mg/50 mg every 12 h orally) were added to her antiviral regimen two days later. Her symptoms did not improve, which prompted her to come to the emergency department on February 2, 2020. Although chest auscultation was normal, chest CT scans showed bilateral lower lobe infiltrates (Figure 2A). Real-time reverse transcriptase–polymerase chain reaction (RT-PCR) test for nucleic acid of SARS-CoV-2 on an oropharyngeal swab was performed as described in a previous study<sup>2</sup>. The same technician and brand of test kit (Novel Coronavirus PCR Fluorescence Diagnostic Kit, BioGerm Medical Biotechnology), which was recommended by the Chinese Center for Disease Control and Prevention, was used in this report. The result of RT-PCR test was positive. The patient was asked to self-quarantine at home because of the limited number of hospital beds in Wuhan at that time. Her temperature dropped to normal one day later, the last day of her menstrual period.

---

On February 4, 2020, the patient was hospitalized with COVID-19. On admission, the physical examination revealed body temperature of 97.5°F (36.4°C), blood pressure of 98/61 mmHg, pulse rate of 78 beats per minute, respiratory rate of 20 breaths per minute and oxygen saturation of 95% on room air. The results of her laboratory testing showed a C-reactive protein count 12.3 mg/L (< 1 mg/L indicates low risk of cardiovascular disease; 1 - 3 mg/L indicates medium risk of cardiovascular disease; > 3 mg/L indicates high risk of cardiovascular disease; > 10 mg/L indicates infection or inflammation) and erythrocyte sedimentation rate of 30 mm/H (normal range 10 - 30 mm/H). Other pertinent laboratory tests, including complete blood count, coagulation tests, liver function tests, kidney function tests, metabolic panel tests, and high-sensitivity cardiac troponin tests did not reveal any clinically significant results. A follow-up chest CT scan on February 8, 2020, showed the shadow on bilateral lung was partly absorbed (Figure 2B). Thus, all of her antiviral and antibacterial medications were canceled. RT-PCR tests for nucleic acid of SARS-CoV-2 on oropharyngeal swabs were performed 3 and 6 days after admission and the results were positive. The RT-PCR tests on oropharyngeal swabs were repeated 10 and 12 days after admission, and both showed negative results. On February 14, 2020, a repeated chest CT scan showed a further improvement of ground-glass opacification (Figure 2C). Her temperature remained normal during hospitalization. According to the criteria for hospital discharge in China including: (1) normal temperature

---

for at least 3 days, (2) resolution of respiratory symptoms, (3) substantially improved radiological signs, and (4) negative results in two consecutive RT-PCR tests performed  $\geq 24$  h apart, this patient was discharged on February 18, 2020.

After hospital discharge, the patient was asked to continue home quarantine for 14 days. She felt well until February 24, 2020, the first day of her menstrual period. The patient did not report contact with any other person but had fever again, peaking at 100.2°F (37.9°C). Except for tiredness, she had no other symptoms at that same time. She took arbidol (0.2 g every 8 h orally) and moxifloxacin (0.4 g every day orally) for three days. The results of a RT-PCR test on February 25, 2020 and a repeated test on oropharyngeal swabs four days later were both positive. However, chest CT scans showed no changes from the previous results (Figure 2D). The patient still had a slight and intermittent fever until February 29, 2020, the last day of her menstrual period. Since then, her temperature had remained normal. The RT-PCR test on oropharyngeal swab was performed on March 10, 2020, and the result was negative. However, her blood was positive for both IgG and IgM antibodies (YHLO-CLIA-IgG, YHLO-CLIA-IgM kits, YHLO Biotech Co. Ltd Shenzhen, China), against SARS-CoV-2.

---

## Case two

A 44-year-old, previously healthy (gravida 1, para 1, regular menstrual cycle, no history of hormonal therapies), woman was working as a nurse in a hospital in Wuhan, China. On January 24, she began to have a slight fever, peaking at 100.4 °F (38 °C) at night (Figure 1B). Because of the possibility of infection with SARS-CoV-2 due to occupational contact history, she was prescribed arbidol (0.2 g every 8 h orally) by a physician. On January 26, 2020, the first day of her menstrual period, she developed tiredness, muscle soreness, palpitation, and lack of appetite. She continued taking arbidol during the menstrual period, but the symptoms did not improve. On February 2, the patient went to outpatient department in a hospital. Chest CT scans showed multiple infiltration in the bilateral lung view (Figure 2E). Blood examination showed a white blood cell count  $3.88 \times 10^9 / L$  and lymphocyte count  $0.94 \times 10^9 / L$ . Although the result of RT-PCR test on an oropharyngeal swab was negative, the woman was diagnosed with COVID-19 based on the occupational exposure history, symptoms and chest CT results.

On February 3, 2020, the patient was hospitalized with COVID-19. On admission, the physical examination revealed body temperature of 99.5°F (37.5°C), blood pressure of 105/85 mmHg, pulse rate of 110 beats per minute, respiratory rate of 20 breaths per minute and oxygen saturation of 94% on room air. The



---

results of her laboratory testing showed a C-reactive protein count 14.8 mg/L and erythrocyte sedimentation rate of 40 mm/H. The serum-specific IgM antibodies to eight respiratory pathogens (IgM detection kit for respiratory pathogens, EUROIMMUN Co. Ltd Beijing, China), including respiratory syncytial virus, adenovirus, type A and type B influenza virus, parainfluenza virus, Legionella pneumophila, Mycoplasma pneumonia and Chlamydia pneumonia, were detected negative. Her temperature returned to normal on the next day after her admission. Thus, all of her antibacterial medications were canceled. A follow-up chest CT scan on February 8, 2020, showed decreased infiltration in both left and right lungs (Figure 2F). RT-PCR tests for nucleic acid of SARS-CoV-2 on oropharyngeal swabs were performed 3, 7, 9 and 11 days after admission and the results were negative. On February 14, 2020, a repeated chest CT scan showed a significant improvement of infiltration in all lesions (Figure 2G). Her temperature remained normal during hospitalization.

After hospital discharge on February 18, 2020, the patient was asked to continue home quarantine for 14 days. She felt well until February 21, 2020, the first day of her menstrual period. She had fever again with tiredness and dizziness, peaking at 99.3°F (37.4°C). She took arbidol (0.2 g every 8 h orally) and moxifloxacin (0.4 g every day orally) for five days. The results of a RT-PCR test for nucleic acid of SARS-CoV-2 on oropharyngeal swabs on February 23, 2020

---

was positive. Her blood was also positive for both IgG and IgM antibodies against SARS-CoV-2 (YHLO-CLIA-IgG, YHLO-CLIA-IgM kits, YHLO Biotech Co. Ltd Shenzhen, China). However, chest CT scans did not show any sign of increased infiltration (Figure 2H). The patient still had a slight and intermittent fever until February 25, 2020, the day before the last day of her menstrual period. Since then, her temperature had remained normal. The RT-PCR test on oropharyngeal swab was performed on February 28, 2020, the results were negative.

### **Discussion and conclusions**

There are reported sex differences in the susceptibility and outcomes of infectious disease<sup>9,10</sup>. A recent epidemiological study of the COVID-19 outbreak shows that SARS-CoV-2 might have a longer incubation period and less pronounced symptoms in women than in men<sup>11</sup>. However, the mechanism underlying these differences remains unclear. Here, we report two women infected with SARS-CoV-2 whose RT-PCR test results and symptoms changed during the menstrual cycle. The first patient developed a fever on the first day of her menstrual period, and again on the first day of her next menstrual period after hospital discharge. RT-PCR test results were positive during the first menstrual period before admission, turned negative during hospitalization, and then positive again during the second menstrual period, which occurred after hospital discharge. Another patient also developed a fever again on the first day of her menstrual period after hospital discharge. RT-PCR test results were negative before

---

admission and during hospitalization, but turned positive during the first menstrual period after hospital discharge. These cases indicate sex hormones may play an important role in SARS-CoV-2 infection.

In female humans, the levels of sex hormones, largely estrogens and progesterone, vary during the menstrual cycle and decrease sharply before menstruation<sup>12</sup>. The dramatic fluctuation in sex hormone levels is associated with changes in immune function and response to respiratory virus infections<sup>13</sup>. In an animal model of influenza A virus infection, estrogen is reported to be a potent anti-inflammatory hormone and to reduce adaptive immune responses and protect hosts from influenza A virus-mediated pathogenesis<sup>14</sup>. In another animal model of the severe acute respiratory syndrome coronavirus (SARS-CoV) infection, treatment with an estrogen receptor antagonist or ovariectomy can increase mortality in females, indicating a critical role of estrogen receptor signaling in protecting females from severe SARS-CoV infection<sup>15</sup>. Consistent with these previous studies, our findings in the current case showed a close association between symptoms, positive RT-PCR test results and the menstruation. This phenomenon might be partly explained by the findings of Sangappa et al.<sup>16</sup>. They found that the expression of angiotensin converting enzyme 2 (ACE2), by which SARS-CoV-2 enters human cells, is high in human endometrial stroma and increases in the secretory phase. Furthermore, ACE2 expression in human endometrial stroma is promoted by progesterone. Future studies exploring the role

---

and mechanism of sex hormones in the pathogenesis of SARS-CoV-2 infection are warranted.

In the first case, fever occurred on the first day and disappeared on the last day of her menstrual period. In the second case, symptoms worsened when menstruation started. These observations suggest that the menstrual status needs to be included in the observation period. During the observation period, the identification of potentially infected patients should be based on the results of RT-PCR tests or CT scans rather than symptoms.

The patients in this report had a recurrence of fever and positive RT-PCR test results during their first menstrual period after hospital discharge. Although the negative RT-PCR test results during hospitalization might be false-negative<sup>17</sup>, there are increasing reports regarding positive RT-PCR test results among convalescent COVID-19 patients<sup>18-20</sup>. These observations suggest that some of the recovered patients still might be virus carriers. The management protocol for hospital discharge might need to be reevaluated, and the 14 days of home quarantine should include assessment of the menstrual status of female patients.

In summary, our report provides an initial view of the association between the menstrual cycle, symptoms and RT-PCR test results. Future studies in large cohorts are necessary to address the effect of sex hormones on the clinical course of COVID-19.

---

## **Abbreviations**

COVID-19: the 2019 novel coronavirus infection; SARS-CoV-2: severe acute respiratory syndrome coronavirus 2; RT-PCR: Real-time reverse transcriptase–polymerase chain reaction; SARS-CoV: severe acute respiratory syndrome coronavirus; ACE2: angiotensin converting enzyme 2

## **Ethics approval and consent to participate**

Institutional Review Board (IRB) approval for this report was granted through the ethic committee of Tongji hospital, Tongji Medical College, Huazhong University of Science and Technology (TJ-C20200142).

## **Consent for publication**

The signed consent has been obtained from the patients in this case report.

## **Availability of data and materials**

All data generated or analysed during this study are included in this published article.

**Competing interests** All authors declare that they have no conflicts of interest.

---

## Funding

This research did not receive any specific grant from funding agencies in the public, commercial, or not-for-profit sectors.

## Authors' contributions

All authors discussed the results and commented on the manuscript. Specifically, HZ and JT contributed to the conception of the idea and the study design. HZ and JT prepared the data set, performed the analysis and wrote the manuscript. KM contributed to analysis and interpretation of data. WM provided intellectual inputs for the project and critical comments on the manuscript.

**Acknowledgments** The authors thank the patients for cooperating with the investigation. The authors also thank Dr. Haobo Ma, Department of Anesthesia, Critical Care and Pain Medicine, Beth Israel Deaconess Medical Center and Harvard Medical School, Boston, MA, for critical comments on the manuscript.

## References

1. Zhu N, Zhang D, Wang W, et al. A Novel Coronavirus from Patients with Pneumonia in China, 2019. *N Engl J Med.* 2020;382(8):727-733.
2. Wang D, Hu B, Hu C, et al. Clinical Characteristics of 138 Hospitalized Patients With 2019 Novel Coronavirus-Infected Pneumonia in Wuhan, China. *JAMA.* 2020.

- 
3. Huang C, Wang Y, Li X, et al. Clinical features of patients infected with 2019 novel coronavirus in Wuhan, China. *Lancet*. 2020;395(10223):497-506.
  4. Xu XW, Wu XX, Jiang XG, et al. Clinical findings in a group of patients infected with the 2019 novel coronavirus (SARS-Cov-2) outside of Wuhan, China: retrospective case series. *BMJ*. 2020;368:m606.
  5. WHO. Coronavirus disease 2019 (COVID-19) Situation Report-158. [https://www.who.int/docs/default-source/coronaviruse/situation-reports/20200626-covid-19-sitrep-158.pdf?sfvrsn=1d1aae8a\\_2](https://www.who.int/docs/default-source/coronaviruse/situation-reports/20200626-covid-19-sitrep-158.pdf?sfvrsn=1d1aae8a_2) (accessed June 27, 2020). 2020.
  6. Sun K, Chen J, Viboud C. Early epidemiological analysis of the coronavirus disease 2019 outbreak based on crowdsourced data: a populationlevel observational study. *Lancet*. 2020.
  7. Oertelt-Prigione S. Immunology and the menstrual cycle. *Autoimmun Rev*. 2012;11(6-7):A486-492.
  8. Alvergne A, Hogqvist Tabor V. Is Female Health Cyclical? Evolutionary Perspectives on Menstruation. *Trends Ecol Evol*. 2018;33(6):399-414.
  9. Karlberg J, Chong DS, Lai WY. Do men have a higher case fatality rate of severe acute respiratory syndrome than women do? *Am J Epidemiol*. 2004;159(3):229-231.
  10. Alghamdi IG, Hussain, II, Almalki SS, Alghamdi MS, Alghamdi MM, El-Sheemy MA. The pattern of Middle East respiratory syndrome coronavirus in Saudi Arabia: a descriptive epidemiological analysis of data from the Saudi Ministry of Health. *Int J Gen Med*. 2014;7:417-423.

- 
11. Xiong Q, Xu M, Zhang J, et al. Women May Play a More Important Role in the Transmission of the Corona Virus Disease (COVID-19) than Men. *SSRN*. 2020.
  12. Cupini LM, Corbelli I, Sarchelli P. Menstrual migraine: what it is and does it matter? *J Neurol*. 2020.
  13. Kadel S, Kovats S. Sex Hormones Regulate Innate Immune Cells and Promote Sex Differences in Respiratory Virus Infection. *Front Immunol*. 2018;9:1653.
  14. Robinson DP, Hall OJ, Nilles TL, Bream JH, Klein SL. 17beta-estradiol protects females against influenza by recruiting neutrophils and increasing virus-specific CD8 T cell responses in the lungs. *J Virol*. 2014;88(9):4711-4720.
  15. Channappanavar R, Fett C, Mack M, Ten Eyck PP, Meyerholz DK, Perlman S. Sex-Based Differences in Susceptibility to Severe Acute Respiratory Syndrome Coronavirus Infection. *J Immunol*. 2017;198(10):4046-4053.
  16. Chadchan SB, Maurya VK, Popli P, Kommagani R. The SARS-CoV-2 receptor, Angiotensin converting enzyme 2 (ACE2) is required for human endometrial stromal cell decidualization. *bioRxiv*. 2020:2020.2006.2023.168252.
  17. Xie X, Zhong Z, Zhao W, Zheng C, Wang F, Liu J. Chest CT for Typical 2019-nCoV Pneumonia: Relationship to Negative RT-PCR Testing. *Radiology*. 2020:200343.

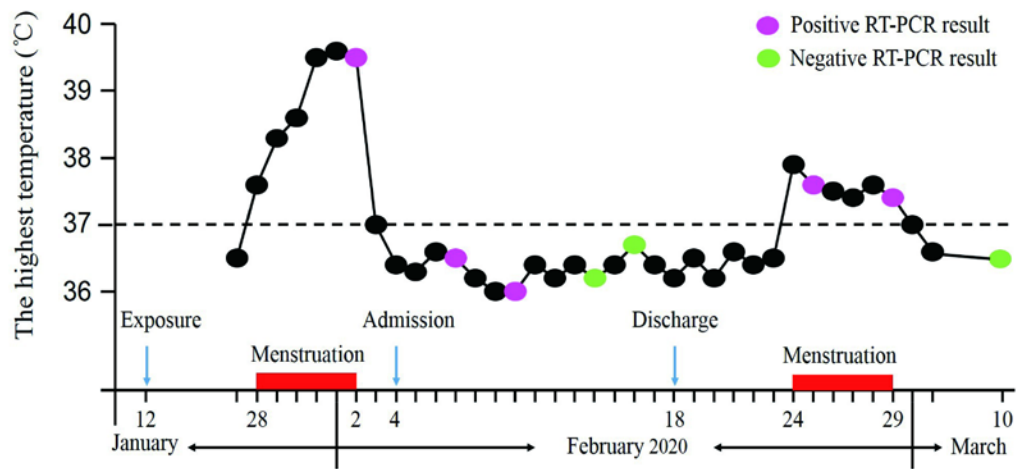


- 
18. Lan L, Xu D, Ye G, et al. Positive RT-PCR Test Results in Patients Recovered From COVID-19. *JAMA*. 2020.
  19. Chen Z, Hu J, Zhang Z, et al. Caution: The clinical characteristics of COVID-19 patients at admission are changing. *MedRxiv*. 2020.
  20. Chen D, Xu W, Lei Z, et al. Recurrence of positive SARS-CoV-2 RNA in COVID-19: A case report. *Int J Infect Dis*. 2020.

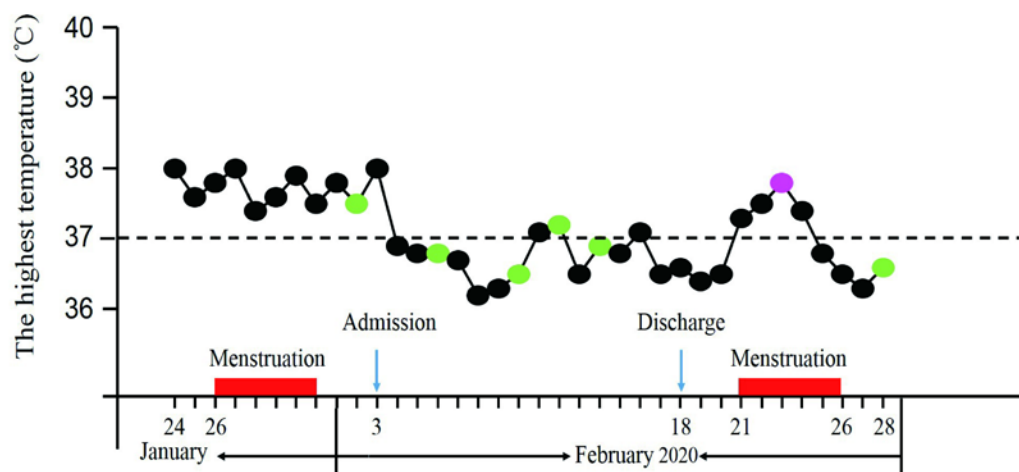
### Figure Legends

**Figure 1. Timeline of changes of RT-PCR test results and symptoms during the menstrual cycle of cases infected with SARS-CoV-2.** Case one (A). (A) Sixteen days after exposure to SARS-CoV-2, fever occurred on the first day of her menstrual period, and again on the first day of her next menstrual period after hospital discharge. RT-PCR test results were positive during the first menstrual period before admission, turned negative during hospitalization, and then positive again during the second menstrual period, which occurred after hospital discharge. Case two (B). (B) Fever occurred two days before her menstrual period, and again on the first day of her next menstrual period after hospital discharge. RT-PCR test results were negative before admission and during hospitalization, but turned positive during the first menstrual period after hospital discharge. RT-PCR indicates real time polymerase chain reaction test for the coronavirus disease 2019 (COVID-19) nucleic acid.

A case one



B case two



**Figure 2. Transverse chest CT images of cases infected with SARS-CoV-2.**

Case one (A-D). Representative images of the chest CT scans showing (A) bilateral ground-glass opacity and subsegmental areas of consolidation on day 6 after symptom onset, (B) bilateral ground-glass opacity on day 12 after symptom onset, (C) bilateral patchy ground-glass opacity on day 18 after symptom onset, and (D) focal ground-glass opacity on day 29 after symptom onset. Case two (E-H). Representative images of the chest CT scans showing (E) multiple ground-glass opacity and consolidation shadow in the right upper lung lobe and left lower lung lobe on day 10 after symptom onset, (F) absorption of bilateral ground glass opacity on day 16 after symptom onset, (G) a significant absorption of the shadow in all lesions on day 22 after symptom onset, and (H) the shadow was absorbed almost completely on day 31 after symptom onset.

