

Management of orbital complications of acute rhinosinusitis in pediatric patients: a 15-years single-center experience

Aleksandar Trivic PhD^{1,2}, Muge Cevik MRCP (UK)^{3*}, Miljan Folic MD^{1*}, Sanja Krejovic-Trivic PhD^{1,2}, Salvatore Rubino PhD⁴, Jelena Micić PhD^{2,5}, Goran Stevanovic PhD^{2,6}, Jovica Milovanovic PhD^{1,2}, Ana Jotic PhD^{1,2}, Aleksandra Barac PhD^{2,6}

¹Clinic for Otorhinolaryngology Maxillofacial Surgery, Clinical Centre of Serbia, Belgrade, Serbia

² Faculty of Medicine, University of Belgrade, Belgrade, Serbia

³ School of Medicine, University of St. Andrews, St Andrews, United Kingdom

⁴ Department of Biomedical Sciences, University of Sassari, Sassari, Italy

⁵ Clinic for Gynecology and Obstetrics, Clinical Center of Serbia, Belgrade, Serbia

⁶ Clinic for Infectious and Tropical Diseases, Clinical Centre of Serbia, Belgrade, Serbia

***These authors contributed equally**

Abbreviated title: Orbital complications of rhinosinusitis in children

Running title: Orbital complications of rhinosinusitis

Corresponding author:

Aleksandra Barac, MD, PhD, Scientific Associate

Clinic for Infectious and Tropical Diseases, Clinical Centre of Serbia, Belgrade, Serbia

Bul. Oslobođenja 16, 11000 Belgrade, Serbia

Email: aleksandrabarac85@gmail.com; Tel: +38163/1869502

Keywords: acute rhinosinusitis; orbital complications; pediatric; children; Chandler classification

Conflicts of Interest and Source of Funding: The authors declare that they have no competing interests and no funding received for this work

Abstract

Background: The major clinical dilemma managing acute rhinosinusitis (ARS) in pediatric population is distinguishing uncomplicated rhinosinusitis from a complicated bacterial ARS and orbital complications, the latter requiring antimicrobials and surgical intervention. However, factors associated with severe orbital complications and the optimum management strategy remains controversial. The objectives of this study were to characterize the clinical outcomes of children with orbital complications of ARS and to identify risk factors associated with disease severity.

Methods: This retrospective cohort analysis evaluated the clinical outcomes of 61 children admitted for orbital complications between 1st January 2002 and 31st December 2017. Descriptive statistics were performed to examine the demographics and clinical findings. We compared groups using Mann–Whitney test for continuous variables and Chi-square for categorical variables.

Results: Although two-thirds of children had received pre-hospital antibiotics, half of the cohort presented with post-septal orbital complications. While 83% of isolates obtained from the same patients were susceptible to the pre-hospital antibiotics given, the majority of those who received pre-hospital antibiotics nevertheless required surgical intervention. We observed significant association between the age of presentation and disease severity. Children older than 5 years of age presented with more severe orbital complications despite pre-hospital antibiotics and were more likely to require surgical intervention ($p < 0.001$).

Conclusion: In this study, stage II/III orbital complications at presentation and older age were the most important determinants of medical treatment failure. Early referral to ENT should be considered for children >5 years with ARS due to worse orbital complications despite pre-hospital antibiotics.

Introduction

Acute rhinosinusitis (ARS) is a common childhood illness characterized by inflammation of the nose and paranasal sinuses, which usually follows a viral infection or allergic rhinitis and can be complicated by bacterial infection.^{1,2} ARS is often a self-limiting illness and although rare, carries a potential risk of severe complications and fatal outcome.^{1,3} Orbital involvement is the most common complication of ARS in the pediatric population,^{4,5} usually emerging from the direct extension of infection, local thrombophlebitis and acute ethmoid sinusitis, which is exacerbated in children due to an immature immune system and developmental anatomy.^{6,7}

Chandler et al.⁸ defined the orbital septum as an anatomical landmark setting the boundaries between pre- and post-septal spaces, differentiating the first two stages of orbital inflammation. The spread of infection to the post-septal space carries a significant risk of complications such as permanent visual loss, cerebral abscess and cavernous sinus thrombosis as well as adverse outcomes, i.e. prolonged hospitalization and antibiotic therapy, and the requirement for surgical intervention.^{6,9,10} Chandler has classified orbital complications into five stages based on disease severity, which is still being used today to establish treatment response and prognosis.

The diagnosis of post-septal orbital complications is often difficult based on clinical examination; yet, early recognition and appropriate treatment are the only means by which to achieve a successful outcome in the pediatric population.^{5,11-14} The management of ARS in children remains a controversial and emerging subject.^{1,15} There is considerable variability between published literature in terms of the population at risk of severe orbital complications^{4,16-18}, the need for imaging studies¹⁹ and indication for surgical intervention,^{20,21} thus, the optimum management strategy remains controversial.

This study aimed to describe 15-years of experience managing orbital complications of ARS in the pediatric population, to explain the real-life success of different management strategies and to identify risk factors associated with disease severity.

Materials and Methods

Study design and population

A retrospective cross-sectional study was conducted between 1st January 2002 and 31st December 2017. During this period, all children who were admitted to hospital with orbital complications of ARS under the care of otorhinolaryngology and maxillofacial surgical team were included in this study. Diagnosis of ARS was made based on the European Position Paper on Rhinosinusitis and Nasal Polyps (EPOS 2012) criteria.³ Orbital complications were categorized according to the Chandler classification; Stage I: inflammatory edema and pre-septal cellulitis, Stage II: orbital cellulitis, Stage III: subperiosteal abscess (SPOA), Stage IV: orbital abscess and Stage V: cavernous sinus thrombosis. For those patients with post-septal orbital complications (Stage 2 or greater) final classification was done after obtaining CT results.

Data collection

Patient demographics, length of hospital stay, previous antimicrobial therapy and clinical data including presenting symptoms, physical examination (eye, nose and throat/ENT specialist, ophthalmology and neurology), radiology findings and details of medical and surgical treatment were extracted from the medical records. Patient samples submitted for microbiology evaluation were identified and detailed microbiology data were retrieved from the laboratory database.

Clinical and radiological examination

All patients were examined by an ENT specialist to confirm the diagnosis of ARS at the time of admission. Characteristics of sinonasal secretion were visually evaluated, and pus samples collected from all patients were sent for culture. Subsequently, all patients underwent ophthalmology and neurology examinations to clinically ascertain orbital complications. Patients with an abnormality found in either examination underwent further evaluation with computer tomography (CT). CT imaging was also performed in patients where the ophthalmology examination was inconclusive and in those who were non-responsive to medical treatment.

Sampling and microbiology

All patients had sinonasal aspiration sampling as a standard procedure prior to antibiotic treatment. Sinonasal aspiration involves endoscopic guided sampling of the middle meatus as described by Vogan JC *et al.*²² This technique has been shown to accurately identify the predominant bacterial pathogens with 90% culture correlation. Antral puncture is a painful procedure, and it is not recommended in children, except in specific occasions. In patients who underwent surgery, sinus secretions and pus sample from the drained abscess were also obtained and sent for microbiology evaluation. Routine microbiology procedures were used to identify pathogens involved; Gram stain, aerobic and anaerobic cultures and antibiotic susceptibility testing.

Surgical treatment

Patients who had visual impairment at the time of admission and failure of medical treatment warranted surgical intervention. Failure of medical treatment was defined as fever despite 48 hours of antibiotic treatment, progressive symptomatology and worsening inflammatory markers.

Endoscopic sinus surgery (ESS) was aimed at exposing the lamina papyracea (ethmoidal labyrinth) to identify possible dehiscence and evacuate the pathological tissue. In some cases, it was necessary to fracture or partially remove a part of lamina papyracea due to extensive dehiscence. Grade IV orbital complications were managed by a multidisciplinary team involving ENT, ophthalmology and infectious diseases/clinical microbiology.

Statistical analyses

Descriptive statistics were performed to examine the demographics and clinical findings. Categorical variables were summarized by frequencies and percentages. Continuous data were presented as counts or percentages (%). We compared groups using Mann–Whitney test for continuous variables and Chi-square test for categorical variables. To assess the role of pre-hospital antimicrobial treatment in preventing orbital complications, we compared the use of antibiotic treatment before hospital admission with the stage of orbital complications and the clinical outcome. Clinical presentation and treatment outcomes were also compared between younger (≤ 5 years of age) and older children (> 5 years of age). All analyses were performed using SPSS (version 19.0).

Results

Sociodemographic and clinical characteristics of children with ARS

A total of 61 children who were hospitalized due to orbital complications following ARS were included in the study. Thirty-four patients were male (56%), F:M ratio was 1:1.3. The mean age was 5.4 years (7 months -14 years), 52.5% were less than 5 years of age. In total, 55 (90.1%) had documented fever, and 2 (3%) patients had visual impairment. At the time of admission, the

majority of patients (45/61; 74%) had Chandler grade I or II orbital complications. Fourteen patients (23%) had a SPOA (grade III), and two patients (3%) had an orbital abscess (grade IV). None of the patients had cavernous sinus thrombosis (stage V). CT imaging of paranasal sinuses was performed in 52/61 (85%) patients. Among those who underwent CT imaging, ethmoid sinuses were involved in all patients (52/52), and 46/52 (88%) had maxillary sinus involvement. Summary of sociodemographic and clinical characteristics are presented in Table 1.

Treatment (medical and surgical)

Because of visual impairment and limited ocular movement, two patients (3%) required immediate surgical intervention. The other patients (59/61; 97%) were initially managed medically with antibiotic treatment, and additional surgical treatment was indicated in 30/59 (50.8%) patients who were non-responsive to medical treatment. The most frequently used treatment combination, in 90% of this cohort, was third-generation cephalosporin and metronidazole. All patients who failed to respond to medical treatment and warranted surgical intervention (30/59; 50.8%) had stage II or III orbital complications, whereas the majority of patients who responded to the medical treatment (29/59; 49%) had stage I orbital complication (25/29; 86%). In total, 32 patients underwent ESS, 87.5% of those were appropriately managed with surgical drainage whereas four patients required an additional ophthalmology intervention. All patients recovered well after treatment without long-term complications.

Microbiology analysis

In total, 93 samples were obtained; 61 sinonasal secretion samples from all patients and 32 tissue samples from those who underwent EES. The microbiology results are shown in Figure 2. Positive

bacterial growth has been found in 80% (74/93) samples: 72% (44/61) in sinonasal secretion samples and 94% (30/32) in tissue samples. In total, 71 patients had one isolate, two patients had two isolates, while one patient had three isolates. Multiple isolates were identified from the sinonasal secretions of three patients. The most frequently cultured bacteria were *Streptococcus pyogenes* (27/74; 36.5%) and *Staphylococcus aureus* (21/74; 28%) followed by *Streptococcus pneumoniae* (13/74; 18%), *Haemophilus influenzae* (7/74; 9.5%) and *Moraxella catarrhalis* (6/74; 8%). Comparing microbiology growth in sinonasal secretions and tissue samples, isolates were matched in only 37.5% of patients. Three patients who were readmitted to the hospital had no microbial growth.

Clinical outcome in association with pre-hospital antibiotics and age

In total, 61% (37/61) of children received antibiotics before hospital admission. The most commonly prescribed antibiotics were amoxicillin, amoxicillin/clavulanic acid and third-generation cephalosporins. Out of all, 75% of those who received pre-hospital antibiotics required surgical intervention. Overall, 83% of isolates obtained from these patients were susceptible to the pre-hospital antibiotics given. Pre-hospital antibiotic treatment had no significant impact on the severity of disease at presentation based on Chandler's classification ($p = 0.393$) and management during hospitalization ($p = 0.270$). However, a significant association was observed between the age of presentation and disease severity (Table 2). The average hospital stay for all patients was 8.8 days (range 3-18 days). The average hospital stay for the younger and older children were 7.9 days and 10.2 days, respectively ($p=0.06$). At the time of admission, among those who received pre-hospital antibiotics, 28% of older children and none of the younger children presented with Chandler III or IV stage orbital complications ($p<0.001$). In addition, older children were more

likely to require surgical intervention compared to younger children, 72% and 25%, respectively ($p < 0.001$). No recurrence was observed among older children, while 3 recurrences have occurred in the ≤ 5 years group. These three patients required multiple admissions, and subsequently required surgical intervention during the final hospitalization.

Discussion

In the current study, although two-thirds of children had received pre-hospital antibiotics, half of the cohort presented with post-septal orbital complications. While the isolates obtained from the same patients were susceptible to the pre-hospital antibiotics given, the majority of those who received pre-hospital antibiotics nevertheless required surgical intervention.

Although hematogenous dissemination through infected thrombo-emboli or local thrombophlebitis has been reported as pathogenic mechanisms in the development of orbital complications, dehiscence of lamina papyracea has been indicated to play an important part in disease progression.⁸ During sinusitis, ethmoid inflammation may jeopardize the integrity of lamina papyracea, causing infection to progress further into the orbit.^{5,7,23} Supporting this pathogenic mechanism, histopathology evidence of lamina papyracea osteitis has been observed in children with SPOA.²⁴ Pyogenic ethmoid osteitis could then lead to sequestrum formation resulting in vascular obliteration, local ischemia and bone necrosis.²³ Accordingly, due to the insufficient blood supply to these avascular areas, the penetration of antibiotics and inflammatory cells may decrease. In this study, half of the cohort, the majority with stage I orbital complication, responded well to the intravenous antibiotics. In contrast, the other half, all with stage II or III complications, failed to improve with intravenous antibiotics although the isolates were found to

be susceptible to the antibiotics given. This supports the hypothesis that bone involvement and dehiscence, likely decreased antibiotic penetration to the affected areas may be the principal cause of treatment failure.

Several studies describe that a subset of patients with SPOA can successfully be treated with antibiotics;^{20,21,25} however, it is unclear which patients can be suitable for medical management.²⁶ In a prospective study of patients less than 9 years of age with small and medial SPOA, 93% cure rate was reported without surgery.²⁰ On the other hand, a retrospective study of patients with SPOA showed a considerably lower success of medical treatment; only 26% of the patients recovered without surgery.²⁵ The response rate to medical treatment varies in all available studies. In this cohort, all patients with SPOA failed to improve on medical treatment and warranted ESS for evacuation and removal of the pathological process. In contrast to the perception that orbital complications of ARS are treated more conservatively today than in the past, Capra *et al.* has shown that surgical rates nearly doubled from 10.8% in 2000 to 19.5% in 2009 in the older children.²⁷ There is likely a shift towards surgical intervention especially in the older age group.

Furthermore, in the literature there is conflicting evidence in regard to age being a significant determinant in the development of orbital complications. Different treatment protocols have been proposed for younger and older children,^{4,16-18} although some studies have demonstrated no significant difference in clinical presentation and clinical outcome based on age.^{21,25} In this study, children older than 5 years of age were significantly more likely to present with stage III or IV orbital complications despite pre-hospital antibiotics and more likely to require surgical intervention. In comparison, the majority of younger children who received pre-admission

antibiotics presented with stage I complications and were more likely to improve with in-hospital antibiotic treatment. Our findings support some available evidence that the infections in older children are more complicated at presentation regardless of pre-hospital antibiotics and younger children with stage I complications could be managed medically.^{17,18,20} These results are also in agreement with recently published studies. According to a population based study in the United States, older children with orbital complications of ARS were more likely to have been treated surgically.²⁷ In a recent study, toddlers (<2 years of age) were shown to have milder disease and had better outcomes without surgical intervention.²⁸

The most common microorganism responsible for complicated ethmoiditis in the pediatric population is *S. aureus*, followed by *Streptococcus* spp.^{6,29} In the current study, the most frequently cultured bacteria were *Streptococcus* spp. and *S. aureus*. Compared with available studies, *S. pneumoniae* had a very high incidence rate in this cohort, which may be due to the pneumococcal vaccine not being part of the routine vaccination program in Serbia whereas *H. influenzae* was cultured in a small percentage of patients reflecting the *H. influenzae* serotype b vaccine coverage in the population.³⁰ Additionally, in this study, microbiology concordance between the sinonasal secretions and tissue samples was poor, isolates were matched in only 37.5% cases. This emphasizes the importance of obtaining sterile samples during nasal sampling, as the nasal cavity contains a diversity of bacteria which do not usually originate from the sinuses. On the other side, the most reliable sample was a tissue sample as we confirmed bacterial presence in 94% tissue samples, while significantly less in sinonasal secretions (72%) ($p < 0.001$).

Contrast-enhanced CT has been recognized as the imaging study of choice in patients with a suspicion of orbital involvement. However, there is some controversy as to whether CT scan can distinguish an abscess collection from an inflammatory phlegmatous process.³¹ On the other hand, diffusion-weighted magnetic resonance imaging (MRI) is a more sensitive imaging modality which has recently gained attention as a tool to identify orbital abscess and describe intracranial complications.^{32,33} In this study, CT imaging was indicated in the majority of patients who had failed medical treatment to ascertain the next steps in the management of these patients. Imaging could help clinicians to assess the requirement for surgical drainage in patients with visual impairment or who are non-responsive to medical treatment.

The significance of the present study is that we provide 15-years of real-life clinical experience of managing orbital complications of ARS in the pediatric population. There are some limitations. The study is based on observational data and due to its retrospective nature, some relevant information might have been missed during data collection. Additionally, likely reflecting the real-life setting, we did not have an absolute strict criterion for treatment failure which was defined as not improving following 48h treatment, worsening inflammatory markers and/or clinical deterioration. Although our case series is unique to incorporate clinical, microbiology and surgical information, sample size remains limited.

In conclusion, orbital complications of acute sinusitis remain a persisting problem in pediatric otorhinolaryngology. In this study, the most important determinants of antibiotic treatment failure were stage II or III orbital complications at presentation and older age (>5 years of age). Early referral to ENT should be considered for children >5 years with ARS as they present with worse

orbital complications despite pre-hospital antibiotic therapy. All isolates obtained were susceptible to the antibiotics given pre-admission and during the hospital stay, supporting the hypothesis that bone involvement and dehiscence may be the primary explanation for the failure of medical treatment.

Authors contributions

MF and AB conceptualised this paper, MF collated the data and performed the statistical analysis, MF, MC and AB drafted the first manuscript, MF and MC contributed equally to this manuscript, and all authors provided critical feedback and contributed to the manuscript writing.

Conflict of interest

The authors declare that they have no competing interests.

Financial support and sponsorship

No funding received for this work

Acknowledgement

Dr Aleksandra Barac received support for research from the Project of Ministry of Education, Science and Technology of the Republic of Serbia (No. III45005).

References:

1. Anon JB. Acute bacterial rhinosinusitis in pediatric medicine: current issues in diagnosis and management. *Paediatr Drugs*. 2003;5 Suppl 1:25-33.
2. Holzmann D, Willi U, Nadal D. Allergic rhinitis as a risk factor for orbital complication of acute rhinosinusitis in children. *Am J Rhinol*. 2001;15(6):387-390.

3. Fokkens WJ, Lund VJ, Mullol J, et al. European Position Paper on Rhinosinusitis and Nasal Polyps 2012. *Rhinol Suppl.* 2012;23:3 p preceding table of contents, 1-298.
4. Schollin Ask L, Hultman Dennison S, Stjarne P, et al. Most preschool children hospitalised for acute rhinosinusitis had orbital complications, more common in the youngest and among boys. *Acta Paediatr.* 2017;106(2):268-273.
5. Sultesz M, Csakanyi Z, Majoros T, Farkas Z, Katona G. Acute bacterial rhinosinusitis and its complications in our pediatric otolaryngological department between 1997 and 2006. *Int J Pediatr Otorhinolaryngol.* 2009;73(11):1507-1512.
6. Brook I. Microbiology and antimicrobial treatment of orbital and intracranial complications of sinusitis in children and their management. *Int J Pediatr Otorhinolaryngol.* 2009;73(9):1183-1186.
7. Marseglia GL, Pagella F, Caimmi D, et al. Clinical presentation of acute rhinosinusitis in children reflects paranasal sinus development. *Rhinology.* 2007;45(3):202-204.
8. Chandler JR, Langenbrunner DJ, Stevens ER. The pathogenesis of orbital complications in acute sinusitis. *Laryngoscope.* 1970;80(9):1414-1428.
9. Clayman GL, Adams GL, Paugh DR, Koopmann CF, Jr. Intracranial complications of paranasal sinusitis: a combined institutional review. *Laryngoscope.* 1991;101(3):234-239.
10. Herrmann BW, Forsen JW, Jr. Simultaneous intracranial and orbital complications of acute rhinosinusitis in children. *Int J Pediatr Otorhinolaryngol.* 2004;68(5):619-625.
11. Atfeh MS, Khalil HS. Orbital infections: five-year case series, literature review and guideline development. *J Laryngol Otol.* 2015;129(7):670-676.
12. Bedwell J, Bauman NM. Management of pediatric orbital cellulitis and abscess. *Curr Opin Otolaryngol Head Neck Surg.* 2011;19(6):467-473.
13. Leo G, Mori F, Incorvaia C, Barni S, Novembre E. Diagnosis and management of acute rhinosinusitis in children. *Curr Allergy Asthma Rep.* 2009;9(3):232-237.
14. Nocon CC, Baroody FM. Acute rhinosinusitis in children. *Curr Allergy Asthma Rep.* 2014;14(6):443.
15. Wald ER. Sinusitis in children. *N Engl J Med.* 1992;326(5):319-323.
16. Harris GJ. Subperiosteal abscess of the orbit. Age as a factor in the bacteriology and response to treatment. *Ophthalmology.* 1994;101(3):585-595.
17. Greenberg MF, Pollard ZF. Medical treatment of pediatric subperiosteal orbital abscess secondary to sinusitis. *J AAPOS.* 1998;2(6):351-355.
18. Huang SF, Lee TJ, Lee YS, Chen CC, Chin SC, Wang NC. Acute rhinosinusitis-related orbital infection in pediatric patients: a retrospective analysis. *Ann Otol Rhinol Laryngol.* 2011;120(3):185-190.
19. Wong SJ, Levi J. Management of pediatric orbital cellulitis: A systematic review. *Int J Pediatr Otorhinolaryngol.* 2018;110:123-129.
20. Garcia GH, Harris GJ. Criteria for nonsurgical management of subperiosteal abscess of the orbit: analysis of outcomes 1988-1998. *Ophthalmology.* 2000;107(8):1454-1456; discussion 1457-1458.
21. Oxford LE, McClay J. Medical and surgical management of subperiosteal orbital abscess secondary to acute sinusitis in children. *Int J Pediatr Otorhinolaryngol.* 2006;70(11):1853-1861.
22. Vogan JC, Bolger WE, Keyes AS. Endoscopically guided sinonasal cultures: a direct comparison with maxillary sinus aspirate cultures. *Otolaryngol Head Neck Surg.* 2000;122(3):370-373.
23. Ragab A, Samaka RM. Is pyogenic ethmoidal osteitis the cause of complicated rhinosinusitis with subperiosteal orbital abscess? *Eur Arch Otorhinolaryngol.* 2010;267(8):1231-1237.
24. Eviatar E, Sandbank J, Kleid S, Gavriel H. The role of osteitis of the lamina papyracea in the formation of subperiosteal orbital abscess in young children. *Int J Pediatr Otorhinolaryngol.* 2014;78(12):2267-2270.
25. Rahbar R, Robson CD, Petersen RA, et al. Management of orbital subperiosteal abscess in children. *Arch Otolaryngol Head Neck Surg.* 2001;127(3):281-286.

26. Coenraad S, Buwalda J. Surgical or medical management of subperiosteal orbital abscess in children: a critical appraisal of the literature. *Rhinology*. 2009;47(1):18-23.
27. Capra G, Liming B, Boseley ME, Brigger MT. Trends in orbital complications of pediatric rhinosinusitis in the United States. *JAMA Otolaryngol Head Neck Surg*. 2015;141(1):12-17.
28. Jabarin B, Marom T, Gavriel H, Eviatar E, Pitaro J. Orbital complications secondary to acute rhinosinusitis in toddlers: A unique age group. *Int J Pediatr Otorhinolaryngol*. 2019;121:46-49.
29. Coudert A, Ayari-Khalfallah S, Suy P, Truy E. Microbiology and antibiotic therapy of subperiosteal orbital abscess in children with acute ethmoiditis. *Int J Pediatr Otorhinolaryngol*. 2018;106:91-95.
30. Sharma A, Liu ES, Le TD, et al. Pediatric orbital cellulitis in the Haemophilus influenzae vaccine era. *J AAPOS*. 2015;19(3):206-210.
31. Ryan JT, Preciado DA, Bauman N, et al. Management of pediatric orbital cellulitis in patients with radiographic findings of subperiosteal abscess. *Otolaryngol Head Neck Surg*. 2009;140(6):907-911.
32. Kapur R, Sepahdari AR, Mafee MF, et al. MR imaging of orbital inflammatory syndrome, orbital cellulitis, and orbital lymphoid lesions: the role of diffusion-weighted imaging. *AJNR Am J Neuroradiol*. 2009;30(1):64-70.
33. Sepahdari AR, Aakalu VK, Kapur R, et al. MRI of orbital cellulitis and orbital abscess: the role of diffusion-weighted imaging. *AJR Am J Roentgenol*. 2009;193(3):W244-250.

Table legends

Table 1. Sociodemographic and clinical characteristics of children with ARS

Table 2. Relationship between age and clinical presentation/outcome

Figure legend

Figure 1. Bacterial species isolated from the sinuses of children with ARS

Table 1. Sociodemographic and clinical characteristics of children with ARS

Variable	N (%) (n=61)
Age (years)	5.4 (7 months – 14 years)
Sex	
Female	27 (36)
Male	34 (56)
High fever	55 (90)
Visual impairments	2 (3)
Chandler stage	
I	25 (41)
II	20 (33)
III	14 (23)
IV	2 (3)
V	0 (0)
Sinus involvement (based on CT imaging)	(n=52)
Ethmoid	52 (100)
Maxillary	46 (88)
Frontal	10 (19)
Sphenoid	9 (17)
Pre-admission antibiotics	37 (61)
Failure of medical treatment	30 (51)
Surgical treatment	32 (52)
Average hospital stay (days)	8.8 (3-18)

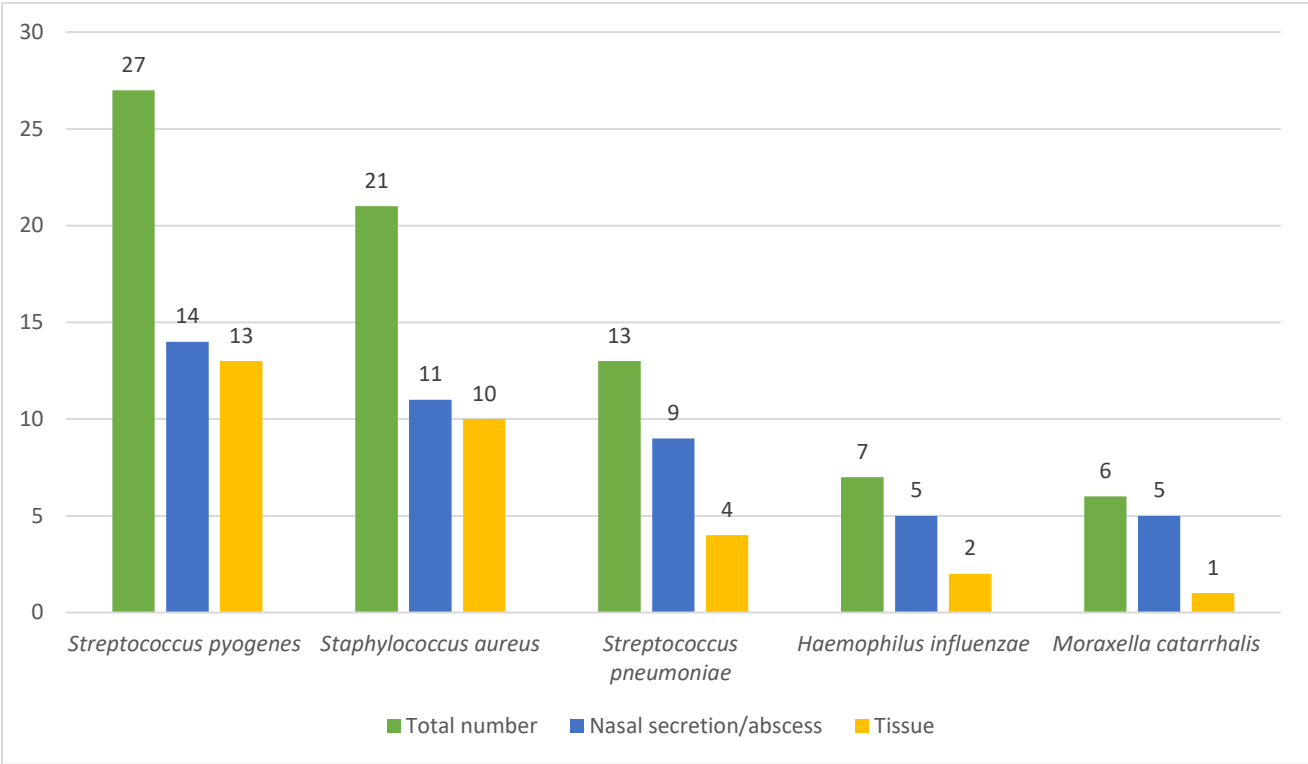
Table 2. Relationship between age and clinical presentation/outcome

	Younger (<5) n=32 (%)	Older (>5) n=29 (%)	<i>p</i>
Chandler stage III and IV at presentation	0 (0)	8 (28)	<0.001*
Requirement for surgery	10 (25)	22 (72)	<0.001*
Average hospital stay (days)	7.9±2.8	10.2±2.1	0.06**

* According to Chi-square test, $p < 0.05$

** According to Mann–Whitney U test, $p < 0.05$

Figure 1. Bacterial species isolated from sinuses of children with ARS



* Total number of isolated species = 74 (44 from nasal secretion and 30 from tissue)