



UNIVERSITÀ  
DEGLI STUDI  
FIRENZE

## FLORE

# Repository istituzionale dell'Università degli Studi di Firenze

### Liver transplantation for neonatal haemochromatosis

Questa è la Versione finale referata (Post print/Accepted manuscript) della seguente pubblicazione:

*Original Citation:*

Liver transplantation for neonatal haemochromatosis / Muiesan P.; Rela M.; Kane P.; Dawan A.; Baker A.; Ball C.; Mowat A.P.; Williams R.; Heaton N.D.. - In: ARCHIVES OF DISEASE IN CHILDHOOD. - ISSN 0003-9888. - ELETTRONICO. - 73(1995), pp. F178-F180.

*Availability:*

This version is available at: 2158/1200025 since: 2020-07-07T08:49:53Z

*Terms of use:*

Open Access

La pubblicazione è resa disponibile sotto le norme e i termini della licenza di deposito, secondo quanto stabilito dalla Policy per l'accesso aperto dell'Università degli Studi di Firenze (<https://www.sba.unifi.it/upload/policy-oa-2016-1.pdf>)

*Publisher copyright claim:*

(Article begins on next page)

# Liver transplantation for neonatal haemochromatosis

P Muiesan, M Rela, P Kane, A Dawan, A Baker, C Ball, A P Mowat, Roger Williams, N D Heaton

## Abstract

**Two cases of neonatal haemochromatosis, a rare and often fatal metabolic disorder, presenting with acute liver failure, are reported. Both presented in the first week of life with hypoglycaemia, jaundice, and coagulopathy, with rapid deterioration of liver function. Both received a transplantation using reduced liver grafts. One child was well 18 months later.**

**Few survivors have been reported and despite the difficult perioperative management, liver transplantation is the best treatment for neonatal haemochromatosis.**

(*Arch Dis Child* 1995; 73: F178-F180)

Keywords: liver transplantation, neonatal haemochromatosis, fulminant hepatic failure.

Neonatal haemochromatosis is a rare and frequently fatal disorder which causes either death in utero or acute liver failure in the neonate. The pathogenesis is uncertain: there may be more than one cause. It has been observed in siblings and in these cases seems to be inherited as an autosomal recessive gene.<sup>1 2</sup> No infectious aetiology has been identified. Histologically, the condition is characterised by intense deposition of stainable iron in the liver, hepatocellular necrosis, and diffuse hepatic fibrosis with nodular regeneration. Other organs affected include the pancreas, heart, thyroid and salivary glands, with a characteristic sparing of the reticuloendothelial system. About 60 cases have been reported, with sporadic survivors described following supportive treatment. Liver transplantation is a definitive treatment but few successful cases have been reported.<sup>3 4</sup> We report two cases born to parents with no consanguinity or familial history of death in early infancy.

## Case reports

### CASE 1

A full term baby girl weighing 2.32 kg at birth had an Apgar score of 9 at 5 minutes and became hypoglycaemic within the first 48 hours of delivery with a blood glucose of 0.8 µmol/l. During the first week of life she developed seizures related to hypoglycaemia, jaundice, rectal bleeding, haematuria and ascites. Despite a normal serum aspartate transaminase (AST), the total serum bilirubin was 320 mmol/l, alkaline phosphatase 1140 IU/l, albumin 24 g/l and the International Normalised Ratio (INR) 5.6.

In both cases hepatitis A, B, and C, cytomegalovirus (CMV) Coxsackie virus, Epstein Barr virus (EBV), echo 11-, adeno-, herpes and parvoviruses were excluded by specific serological and virological methods. The following biochemical and metabolic disorders were excluded: α 1 antitrypsin deficiency, galactosaemia, tyrosinaemia, fatty acid oxidation defects and bile acid disorders. Haemophagocytic syndrome was excluded after a bone marrow aspirate.

Serum iron was 31.3 mg/dl (range 10-30 mg/dl). The liver function continued to deteriorate and she received a transplantation at 5 weeks of age, receiving a reduced graft (left lobe) from an 8.5 kg donor matched for blood group.

The artery was reconstructed with a donor iliac conduit and biliary drainage was established with a Roux-en-Y hepatico-jejunostomy. The first day after surgery her INR gradually rose to 5 and an abdominal Doppler ultrasound scan showed a blocked portal vein. She was managed conservatively and developed abdominal distension, ascites, and sepsis and died three weeks after transplantation.

Histopathological features of the explanted livers were typical of neonatal haemochromatosis in both cases, with hepatitis with giant cell transformation and massive parenchymal siderosis (figure). Postmortem findings showed substantial haemosiderin deposition in the pancreas.

### CASE 2

A girl born at 40 weeks and weighing 3.46 kg had an Apgar score of 9 at 1 and 5 minutes. She developed asymptomatic hypoglycaemia on day 2 and was admitted on day 9 because of lethargy, jaundice, and poor feeding. Laboratory findings (AST 74 IU/l, serum bilirubin 453 µmol/l, and INR 2.3) were consistent with poor liver function. Further investigation revealed a patent ductus arteriosus with a left to right shunt on Doppler ultrasonography. Despite supportive treatment her liver function progressively deteriorated with an INR of 4.5 and she developed renal failure. She became increasingly jaundiced, hypoglycaemic, and acidotic, required ventilatory support and was referred to our centre. She received a transplantation on the 15th day of life with a reduced graft (segments II and III) from a 17 kg donor with a donor iliac conduit and Roux loop for arterial and biliary reconstruction, respectively. Ligation of the patent ductus arteriosus was undertaken

## Liver Transplant Surgical Service

P Muiesan  
M Rela  
N D Heaton

## Department of Radiology

P Kane

## Department of Child Health

A Dawan  
A Baker  
C Ball  
A P Mowat

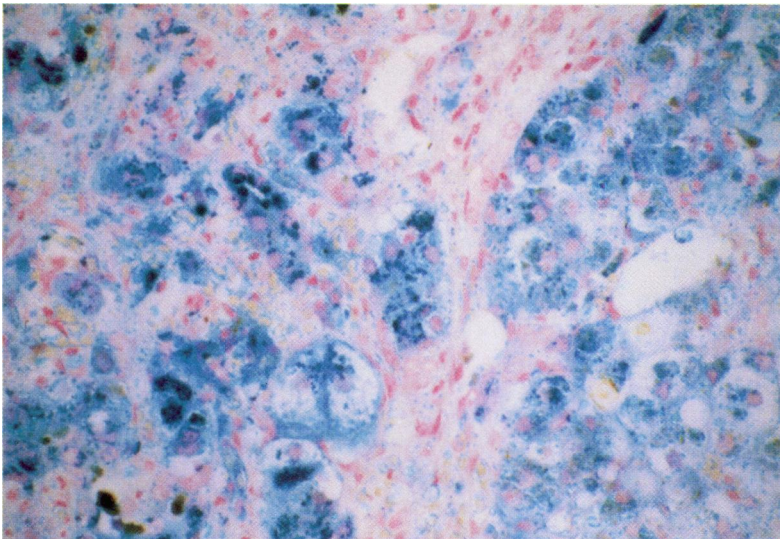
## The Institute of Liver Studies

Roger Williams

## King's College Hospital, Denmark Hill, Camberwell, London SE5 9RS

Correspondence to:  
Mr N D Heaton.

Accepted 19 July 1995



Liver histology of case 2: massive parenchymal iron deposition and giant cell transformation.

immediately before transplantation. The operative blood loss was 580 ml. Immunosuppressive treatment included prednisolone, azathioprine, and cyclosporin. The acute renal failure began to resolve 36 hours later, but she was ventilated for 26 days after transplantation. Other complications included CMV infection treated with gancyclovir and two episodes of gastrointestinal bleeding, for which no cause could be found. She was discharged 42 days after surgery and remained well with normal liver function at the time of writing. There was no evidence of iron deposition in a liver biopsy specimen at 18 month follow up.

The measured iron concentration in the hepatic tissue was significantly increased at 7631 mg/g dry weight (normal value <2000 mg/g dry weight).

### Discussion

Neonatal haemochromatosis is a distinct clinicopathological entity characterised by severe hepatic insufficiency, with onset during intrauterine life, in association with hepatic and extrahepatic siderosis. Neonatal haemochromatosis may present in pregnancy as oligo- or polyhydramnios, placental oedema, stillbirth, prematurity and growth retardation. In affected neonates it invariably produces acute liver failure within 20 days of life.

Neonatal haemochromatosis is unrelated to, and has a different pathogenesis from, adult haemochromatosis, although both have a similar pattern of iron deposition. Hereditary haemochromatosis is an autosomal recessive inherited disease and the iron overload is caused by excessive absorption from the gut. Intestinal absorption of iron is normal in neonatal haemochromatosis and the defect is believed to be in the placenta, although no affected placentas have been available for examination. Regulation of transferrin and ferritin in fibroblasts and the transferrin receptor and ferritin genes seem to be normal.<sup>5</sup> It has been suggested that some cases of neonatal

haemochromatosis occur after hepatic injury in utero rather than because of excessive transport of iron from mother to fetus and that, in some instances, an infective agent may be responsible.<sup>6</sup>

Diagnosis of neonatal haemochromatosis is usually made at necropsy on the basis of the characteristic pattern of iron deposition in the liver and other parenchymal organs, sparing the reticulo-endothelial system. In neonates presenting with acute liver failure underlying viral and metabolic causes must be excluded, particularly haemophagocytosis. The diagnosis of neonatal haemochromatosis is usually made postoperatively and the criteria for transplantation are those used for children with fulminant hepatic failure.<sup>7</sup> Iron studies may support the diagnosis but are non-specific and may be misleading if performed after blood transfusions for concomitant anaemia. Liver biopsy is not usually possible because of the severe coagulopathy, but buccal mucosal biopsy,<sup>8</sup> urinary cytology and magnetic resonance imaging (MRI) may assist in reaching a diagnosis. MRI is established as a method of defining the distribution of iron overload in haemochromatosis or haemosiderosis in children and adults. The presence of an increased amount of the ferric ( $\text{Fe}^{3+}$ ) ion shortens both T1 and T2 values of the affected organ, causing a reduction in signal intensity on the resultant image. T2 weighted sequences are proving the most sensitive and have been used in both antenatal and postnatal periods to investigate potential cases of neonatal haemochromatosis. A recent report describes the use of MRI at 34 weeks of gestation to diagnose neonatal haemochromatosis.<sup>9</sup> Screening of 'at risk' families may be useful if MRI can give a reliable diagnosis before 24 weeks' gestation and would permit early antioxidant treatment and iron chelation, which has successfully been used in three infants with neonatal haemochromatosis.<sup>10</sup> The severity of acute liver failure was not outlined and the potential of this treatment remains unproved. Chelation treatment alone has been shown to be ineffective in altering the course of the disease.

Neonatal haemochromatosis is a complex condition requiring multidisciplinary management which includes neonatal intensive care and exchange transfusion therapy to keep the child stable while waiting for a suitable graft. Liver transplantation in neonates poses technical problems, including the use of reduced grafts to overcome extreme disparity in size, mismatch in vessel calibre, and the need for microsurgical techniques for vascular anastomoses. The postoperative care is demanding, but long term survival and normal development are possible.

A better understanding of neonatal haemochromatosis would lead to a classification of the disorder and assist in genetic counselling of affected families. To date effective medical treatment is not available and liver transplantation is presently the treatment of choice for neonates with acute liver failure as a result of neonatal haemochromatosis.

- 1 Collins J, Goldfischer S. Perinatal hemochromatosis: one disease, several diseases or a spectrum? *Hepatology* 1990; **12**: 176–7.
- 2 Knisely AS. Neonatal hemochromatosis. *Advances in Pediatrics* 1992; **39**: 383–403.
- 3 Lund DP, Lillehei CW, Kevy S, Perez-Atayde A, Maller E, Treacy S, *et al*. Liver transplantation in newborn liver failure: treatment for neonatal hemochromatosis. *Transplant Proc* 1993; **1**: 1068–71.
- 4 Rand EB, McClenathan DT, Whittington PF. Neonatal hemochromatosis: report of successful orthotopic liver transplantation. *J Pediatr Gastroenterol Nutr* 1992; **15**: 325–9.
- 5 Knisely AS, Harford JB, Klausner RD, Taylor SR. Neonatal hemochromatosis – the regulation of transferrin receptor and ferritin synthesis by iron in cultured fibroblastic-line cells. *Am J Pathol* 1989; **134**: 439–45.
- 6 Hoogstraten J, de Sa DJ, Knisely AS. Fetal liver disease may precede extrahepatic siderosis in neonatal hemochromatosis. *Gastroenterology* 1990; **98**: 1699–701.
- 7 Corbally MT, Rela M, Heaton ND, Ball C, Portmann B, Mieli-Vergani G, *et al*. Orthotopic liver transplantation for acute liver failure in children. *Transplant Int* 1994; **7** (suppl 1): S104–7.
- 8 Knisely AS, O’Shea PA, Stocks JF, Dimmick JE. Oropharyngeal and upper respiratory tract mucosal-gland siderosis in neonatal hemochromatosis: an approach to biopsy diagnosis. *J Pediatr* 1988; **113**: 871–4.
- 9 Marti-Bonmati L, Baamonde A, Poyatos CR, Monteagudo E. Prenatal diagnosis of idiopathic neonatal haemochromatosis with MRI. *Abdom Imaging* 1994; **19**: 55–6.
- 10 Shamieh I, Kibort PK, Suchy FJ, Freese DK. Antioxidant therapy for neonatal iron storage disease (NISD). *Ped Res* 1993; **33**: 109A.