



## A mini review on the Lactic Acidosis in goats and its remedial approaches

Asad Ali Khaskheli<sup>1,\*</sup>, Muhammad Ibrahim Khaskheli<sup>2</sup>, Allah Jurio Khaskheli<sup>3</sup>, Arshad Ali Khaskheli<sup>4</sup>

<sup>1</sup>Department of Animal Nutrition, Sindh Agriculture University, Tando jam, Pakistan

<sup>2</sup>Department of Plant Protection, Sindh Agriculture University, Tando jam, Pakistan

<sup>3</sup>Department of Biotechnology, Sindh Agriculture University, Tando jam, Pakistan

<sup>4</sup>Department of Poultry Husbandry, Sindh Agriculture University, Tando jam, Pakistan

### ARTICEL INFO

### ABSTRACT

#### Keywords:

Concentrates  
Intestinal motility  
Lactic acid  
Metabolic disorder

Received: 14 May 2020

Accepted: 10 June 2020

Available online: 16 June 2020

DOI: 10.13170/aj.5.2.16733

The current study was performed in order to investigate the threat of lactic acidosis in goats worldwide and explore the curative strategies. In this regards a detailed review was performed, however obtained facts were found to be much interesting and valuable. It was indicated by researchers that lactic acidosis is the most common problem in goats throughout the worlds. It represents significant economic loss due to direct and indirect effects. It was further stated that goats with lactic acidosis show decreased body temperature up to  $98.1 \pm 0.89$  °F, rumen and intestinal movement  $0.23 \pm 0.48$  /m, rumen pH  $4.8 \pm 0.07$ , blood pH  $7.1 \pm 0.08$ , increased respiration rate  $56.14 \pm 7.15$  /m and heart rate,  $136.28 \pm 4.71$  /m. Affected goats also show signs of dyspnea, anorexia, inactivity, incoordination and recumbancy. The glucose level remains  $190.14 \pm 36.49$  mg/dl, total bilirubin  $0.75 \pm 0.04$  mg/dl, direct bilirubin  $0.27 \pm 0.03$  mg/dl, indirect bilirubin  $0.40 \pm 0.03$  mg/dl, alanine aminotransferase ALT  $36.42 \pm 3.04$  U/l and alkaline phosphatase  $420 \pm 3.65$  U/l. Furthermore, Glucose level, total bilirubin, direct bilirubin, ALT (SGPT) and alkaline phosphatase increase with treatment of Cassia Fistula, serum biochemical changes rapidly return to normal compared to treatment with Sodium bicarbonate or Magnesium hydroxide. The ruminal juices changes are also significantly improved with the treatment. The changes in the ingesta color, odor and consistency and rumen pH return to normal with the use of Cassia Fistula, Sodium bicarbonate and Magnesium hydroxide. In conclusion, Cassia fistula, Sodium bicarbonate and Magnesium hydroxide could be used as valuable strategies against lactic acidosis in goats. These therapies have been proved to be effective for treating the acidosis in goats.

### Introduction

Goats are globally reared mainly for meat and milk purpose (Escareno *et al.*, 2012). To promote the efficient growth and achieve fast weight gain, the wheat grains or its' by products are fed in pure or mixed form. These grains are highly fermentable in the rumen part of stomach (Kamra, 2005). Fermentable grains over feed always lead to the development metabolic disorders, particularly lactic acidosis. However, ruminal acute and sub-acute lactic acidosis have significant economic impact by causing animal or indirect effects like formation of liver abscess, laminitis and rumenitis (Penner *et al.*, 2007).

Lactic acidosis can develop with excessive intake of any highly fermentable diet. Many rumen bacteria are involved but especially *Lactobacillus* and *Streptococcus*

*bovis* (acid resistant bacteria) cause rapid fermentation of carbohydrates and changes the rumen function through proliferation and an increased lactate and volatile fatty acids production which cause the fall in rumen pH to  $< 5.00$  (Gozho *et al.*, 2005; Gonzalez *et al.*, 2010). The severity of lactic acidosis depends on the type and amount of carbohydrate-rich feed consumed (Gentile *et al.*, 2004). There are two main causes of acidosis, first the ingestion of fermentable carbohydrates and sudden increase in ruminal microbial population, second the systemic and metabolic acidosis occurs due to absorption of acids into the blood stream (Radostits *et al.*, 2007). Morbidity rate of ruminal acidosis varies from 10 to 50 percent in clinically affected animals, characterized by sudden increase in respiratory rate,

\* Corresponding author.

Email address: [khaskheli@unsyiah.ac.id](mailto:khaskheli@unsyiah.ac.id)

heart rate, decrease body temperature, distension of abdomen, pain, anorexia, constipation or pastry diarrhea, depression, weakness, dehydration and death if not treated (Radostits et al., 2000).

Curing the lactic acidosis has always been challenging for the goat farmers. The recovery depends on the severity of condition. Treatment of less severe cases can be possible by withholding the dietary concentrates and feeding hay or dry grasses to stimulate saliva (Karapinar et al., 2008). However, in severe cases most of therapies fails and animal dies due cardiac and arrest. Keeping in view these facts about the lactic acidosis in goats, current study was planned, whereby the main aim of study was investigate world impact of lactic acidosis on goats and exploring the curative measures.

**Threat of lactic acidosis in goats**

Lactic acidosis is a metabolic disorder of the ruminants that occurs due to the feeding of carbohydrates or highly fermentable feed that may be manifested in acute or sub-acute form, it causes a significant economic losses due to direct effects in alterations of the ruminal metabolism and changes in the ruminal micro-flora that could leads to death while indirect effects results rumenitis, liver abscess and laminitis (Oliveira et al., 2009). Acute ruminal lactic acidosis commonly is known grain engorgement which is an acute disorder of the rumen. This condition always arises due to the sudden and excess ingestion of carbohydrate-rich feed such as wheat grains, flour or wheat byproducts (Lean et al., 2000).

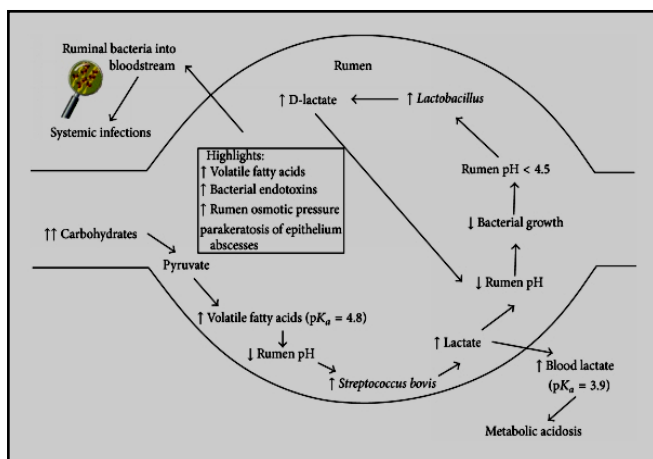


Figure 1. Cascade of events in lactic acidosis (Hernández et al., 2014)

The amount or type of highly fermentable carbohydrate rich feed intake can directly determine the severity by clinical signs (Haji et al., 2006). Small and large animals grain feeding aggravate the condition by feed competition (Piccione et al., 2010).

Experimentally lactic acidosis may be induced for kind of study. In a study, an experiment was conducted on the goats by Ullah et al. (2012). Each of 4 adult female goats was given sucrose orally at the dose rate of 18g/kg body weight twice. Changes in rumen pH, osmolality of plasma and blood were examined for 48hrs and it was found that the decrease in rumen pH (<5.00) was prominent (Figure. 1). Further, it has been studied that decrease of rumen pH, increases the ruminal mucosa to allow the body compartment fluid to enter into the rumen compartment from blood vessels that leads to severe dehydration with the passage of time (Aschenbach and Gabel, 2000). In lactic acidosis presenting goat rumen contents were examined under low power lens and seen 5-7 protozoa per lens field normally but at 5 pH or below these protozoa were absent in lactic acidosis (Annane, 2002). Table 1 is indicating the clinical signs of lactic acidosis in goat.

Table 1. Clinical signs of lactic acidosis in goats

Sample No.	Clinical aspect	Average range
1	Body temperature	98.1±0.89° F
2	Heart rate/min	136.28±4.71/m
3	Respiration rate/min	56.14±7.15/m
4	Ruminal motility	0.23±0.48/m
5	Rumen pH	4.8±0.07
6	Rumen ingesta color	Yellowish
7	Rumen ingesta odor	Soured
8	Rumen ingesta consistency	Watery
9	Appetite	Anorexic
10	Regurgitation	Absent
11	Behavior	Dull
12	Urination	Absent
13	Feces	Absent
14	Gait	Staggering
15	Blood pH	7.1±0.08
16	Hb%	15.02±1.30
17	Glucose (mg/dL)	190.14±36.49
18	Total bilirubin (mg/dL)	0.75±0.04
19	Direct bilirubin (mg/dL)	0.27±0.03
20	Indirect bilirubin (mg/dL)	0.40±0.03
21	ALT (SGPT) (U/L)	36.42±3.04
22	Alkaline phosphatase (U/L)	420±3.65

Acute lactic acidosis in goat causes rapid proliferation of acid resistant bacteria (*Lactobacillus* and *Streptococcus*) and directly an increase in the production of volatile fatty acids (VFA) and lactate, which causes drop in rumen pH to (<5.00) in most severe cases (Aziz et al., 2017). Neurologic symptoms in lactic acidosis goats including depression, anorexia, blindness, convulsions and incoordination have been recorded most common (Abeysekara et al., 2007). In carbohydrate engorgement other clinical which develops are abnormal distension of rumen, atony of

ruminal walls leading to the retention of fermented gases, low perfusion of the kidneys that leads to low output of the urine that leads to death if untreated the animal, addition of yeast culture into the basal diet help in to alleviate the severity and decreases the effect of acidosis such as depression in feed intake and supports the ruminal fermentation (Kawas et al., 2007). Further studies have indicated that lactic acid recovered goats show typical star grazing and opisthotonos in standing or at recumbency position with laminitis when increase the release of histamines in body (Kleen et al., 2003). In lactic acidosis affected goat normal parameters change from normal to abnormal like, rumen pH, ruminal contraction and motility, rumen liquor, protozoa population, hematological and biochemical values, increase in blood pH and vitamin B1 deficiency directly induce the polio encephalomalacia and nervous signs (Dehkordi and Dehkordi, 2011).

Microscopic examination of rumen fluid revealed absence of normal gram negative bacteria and protozoa that were replaced by increase in gram positive bacterial population. Sharp rise in hematocrit value from 50 to 60 percent (normal value 32 percent) and fall in blood pressure was noticed and that is indicative of dehydration. Further, fall in blood calcium contents, bicarbonates and pH but increase in lactate and inorganic phosphate are other evidence of acidosis (Lascano et al., 2011). Acute rumen lactic acidosis leads to disorder of microbial fermentation process by sudden and excess ingestion of carbohydrate-rich feed, grains, flour and wheat byproducts, these essential micro fauna and Gram+ve bacteria are replaced by increase in the Gram-ve bacteria of the rumen (Karapinar et al., 2008). Further, Bonadiman et al. (2018) reported acute rumenitis due to lipid overload has been reported in lactic acidosis. Ruminal content was composed of voluminous and moderate amount of white-gray liquid with a greasy appearance. Hydropic degeneration of keratinocytes at the top of the ruminal papilla and a mild multifocal infiltrate of neutrophils forming intraepithelial pustules were observed. Marked necrosis of the epithelium associated with marked inflammatory infiltrate that extends to the lamina propria, composed predominantly of neutrophils was observed. Bacterial myriads were also noticed in the superficial mucosa. Necrosis of the epithelium; inflammatory infiltrate of neutrophils, lymphocytes, and plasma cells; fragmentation of the keratinized layer; and coccoid bacterial myriads were also seen (Figure 2). In another research it stated that lactic acidosis is a

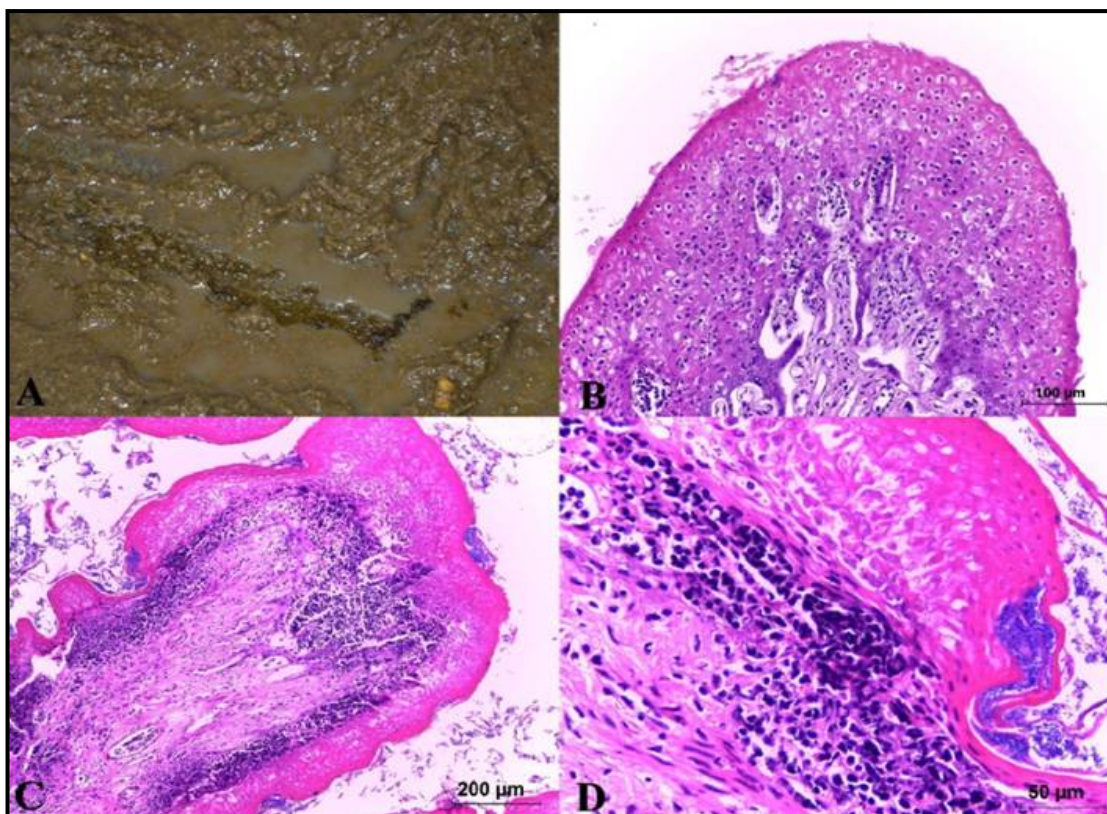
metabolic disorder caused by feeding errors to ruminants clinically manifested an acute or sub-acute form. It represents significant economic losses due to alterations in the ruminal metabolism which could lead to acute or chronic rumenitis, liver abscesses and laminitis (Husain et al., 2008). Handekar et al. (2010) reported that goat average rumen liquor pH falls up to 4.24 by 36 hours after experimentally induction of lactic acidosis that change the rumen flora from anaerobic to aerobic *Streptococcus lactis* (Figure 3).

Escareno et al. (2012) conducted the experiment on goats and studied therapeutic effects of *Cassia fistula* (Amaltas). A total of 38 goats had shown lactic acidosis while total prevalence rate of the disease was observed 19%. The Forty animals were distributed into three groups "A", "B" and "C" comprising of 10 animals each. Group "A" was treated with Magnesium hydroxide at 1.11g/kg body weight, group "B" was offered Sodium bicarbonate at 1g/Kg body weight. Group C was treated with *Cassia fistula*, whereby *Cassia fistula* (powdered form) was mixed with 500ml water and given to the animals at the dose rate of 30g/Kg body weight at the interval of 24, 48 and 72 hours. Group "D" was kept untreated control group. The body temperature, respiration rate, pulse rate, rumen pH and protozoa motility was observed before and after treatment. It was found that group "A" had significantly different effect on rumen and serum pH. The physiological parameters were returned to normal after the temperature, respiration and pulse rate soon after the treatment. It was concluded that Magnesium hydroxide was effective at the dose rate of 1.11g/Kg orally reducing the severity of the lactic acidosis goat. The respiratory rate was recorded 56/m, pulse rate 92/min and body temperature 102.2° F on average basis in all goats after development of lactic acidosis, while rumen motility was reduced.

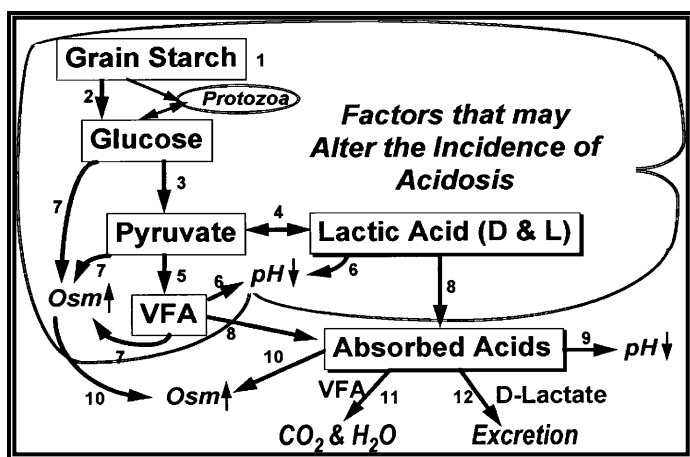
Hernández et al. (2014) conducted an experimental study on lactic acidosis in goats, prevalence rate, intra-ruminal and hematological investigations. A total of 2029 goats from 8 villages of Lahore, Pakistan were diagnosed for lactic acidosis on the basis of differential diagnostic signs and rumen fluid analysis. The morbidity, mortality and case fatality rates were recorded as 1.2, 0.6 and 50%, respectively. The goats were divided on the basis of average rumen fluid pH into four groups' viz. pH 4, 5, 6 and 7. A rumen pH of 4 was recorded as a lethal in all cases. However, no seasonal influence was observed for the disease. Haematological record indicated that significant increase in total leukocyte count (TLC), packed cellular volume (PCV) and

mean corpuscular volume (MCV) was recorded. The mortality rate of the disease was recorded with the severity than sub-acute ruminal acidosis (SARA). The similar study was conducted by [Minuti et al. \(2014\)](#) to investigate the induced acute rumen lactic acidosis in sheep. Sheep were kept off feed before the induction of lactic acidosis, after 24hrs of wheat flour 0.5 kg intake orally at 0h and 12hrs, after the experimental period of 96hrs, animals were offered dry grasses and hay. At 24hrs, rumen, fecal and blood samples were

collected. Samples collected at 24hrs showed markedly ( $P < 0.01$ ) reduce in lactic acidosis but rumen d- and l-lactic acid were increased. A significant level of fecal pH and (VFA) was observed. The increase level of lactulose in blood of acidosis animals showed increase gastrointestinal permeability after 2hrs and increased the lactate-producing bacteria *Streptococcus bovis* in rumen.



**Figure 2.** (A) Ruminal content composed of voluminous and moderate amount of white-gray liquid with a greasy appearance, (B) Hydropic degeneration of keratinocytes at the top of the ruminal papilla and a mild multifocal infiltrate of neutrophils, (C) Marked necrosis of the epithelium associated with marked inflammatory infiltrate that extends to the lamina propria, (D) Necrosis of the epithelium; inflammatory infiltrate of neutrophils, lymphocytes, and plasma cells ([Bonadiman et al., 2018](#))



**Figure 3.** Key reactions occurring during lactic acidosis in ruminants ([Owens et al., 1998](#))

**Table 2.** Effect of Magnesium hydroxide, Sodium bicarbonate and *Cassia fistula* on the clinical signs of lactic acidosis

Clinical signs	Magnesium hydroxide (400gm/50kg)	Sodium bicarbonate (400 gm/50kg)	Cassia fistula (30g/ 50Kg)
Rectal temperate / min	101.41±0.76b	102.97±0.41a	101.36±0.72b
Heart rate/min	99.28±5.46b	83.14±5.17c	100.62±6.32b
Respiration rate/min	45.14±3.80b	27.42±5.56c	41.75±3.95b
Rumen motility/min	2±0.40b	3.07±0.53a	2.06±0.41b

### Curative strategies against lactic acidosis

The carbohydrate rich feeds cause severe clinical signs of lactic acidosis. The severity of ruminal acidosis can be decreased by using the alkalosis producing agents or compounds that neutralize the acidic pH of rumen. Magnesium hydroxide is an effective antacid used in ruminants as alkalinizing agent (Ding and Yu, 2011). Magnesium hydroxide at the dose rate of 400gm can effectively treat lactic acidosis in goat. For achieving the therapeutic effects, Magnesium hydroxide is dissolved in 10 liters water and the solution is infused into rumen by using stomach tube. Given solution remains very effective in neutralizing the acids (Bashir et al., 2004). The vitamin B1 (Thiamine) is an important vitamin for the normal body functions (Harper, 2006). Oral administration of vitamin B1 (Thiamine) restores the function of the ruminal cells and increase the tissues replenishing thiamine deficiency and promotes metabolism of excess lactic acid of rumen by reducing acidosis (Cottee et al., 2004). In another study, it was found that sodium bicarbonate is an important buffering agent. It is used in veterinary medicine to increase the ruminal pH and it is also used as additives in many products as a buffering agent for the rumen that prevents ruminal acidosis the animals which consume high-grain diets. It also improves the productive performance of feedlot animals (Chand et al., 2016). Sodium bicarbonate orally drenched twice daily for two days at the dose rate of 400 gm/50kg has shown more effective results in goats to recover from acute phase of lactic acid (Joaquin et al., 2014). Further animals observed on intake of roughages diet show a range of ruminal pH 6 to 7, while animals on grain or mixed concentrated feed have been observed with pH 5.5 to 6 (Yang et al., 2012). Number of protozoa varies from animal to animal and changing in rumen protozoa depend on feed intake, seasonal variations of the year, time of the day, the number of normal protozoa and the frequency of healthy ruminant, the normal goats has been found with total number of protozoa  $6.50 \pm 0.96$ , 105/ml in rumen fluid and differential sum of Entodinium  $75.09 \pm 7.60\%$  Diplodidium  $13.01 \pm 3.99\%$ , Isotricha  $5.61 \pm 2.08\%$ , Dusytricha and Ophryoscolex  $5.68 \pm 2.36\%$ , the pH of rumen liquor decreased in acidosis, low rumen pH leads in changing rumenal protozoa (Lascano et al., 2011). Callaghan et al. (2016) conducted an experiment to observe the total serum proteins in SARA (Sub-Acute Ruminal Acidosis). They evaluated the variations of Acute Phase Proteins (APPs), blood parameters and pathological lesions. A

total of 108 cows from 12 farms were randomly selected and divided into three groups comprising of 36 animals in each group, all cows were exposed to a rumenocentesis. Group "A" was selected with a rumen pH  $>5.8$ , group "B" was presented with a rumen pH  $5.5 \leq 5.8$  and group "C" was observed with a rumen pH  $<5.5$ . Blood serum samples were evaluated for serum amyloid A (SAA), total proteins (TP), albumin (Alb), haptoglobin (Hp), and white blood cells (WBC). The selected time data analyzed on one way ANOVA showed a statistical significance on rumen pH, SAA and Hp. The APPs production from liver was not stimulated in SARA. Table 2 indicates the comparative influence of Magnesium hydroxide, Sodium bicarbonate and *Cassia fistula* on the clinical signs of lactic acidosis.

In another study, Zein-Eldin et al. (2014) observed the clinical, haemato-biochemical and ruminal changes from the induction of lactic acidosis to recovery in sheep. Five sheep were induced lactic acidosis with sucrose and treated with Sodium bicarbonate and ruminal yeast as probiotics and gentian root powder. Sheep showed decrease in body temperature and increase in the respiration and pulse rate significantly ( $P < 0.05$ ), while other signs were recorded like anorexia, depression, reluctance to move, acute general weakness, holding their heads at lower position and passing soft feces. All sheep were improved after the treatment with Sodium bicarbonate and amino yeast mixture and there was slow improvement by the treatment of gentian root powder. It was concluded that treatment of lactic acidosis in sheep using sodium bicarbonate and yeast help rapidly recovery from lactic acidosis.

### Conclusions

Present study concludes that lactic acidosis is common threat to the goat worldwide. It results substantial economic loss to famers either by impairing the normal physiology of animal or by posing the animal to the death. It is further concluded that *Cassia fistula* (commonly known as Amaltas), Sodium bicarbonate and Magnesium hydroxide could be used as effective strategies against lactic acidosis in goats. *Cassia fistula* administration in lactic acidosis increases the ruminal and intestinal motility and rapidly restore all physiological parameters to normal level of the. *Cassia fistula* is effective laxative to expel the ruminal ingesta containing grain and protect liver. On other hand Sodium bicarbonate and Magnesium hydroxide are also helpful in restoring normal rumen and blood pH.

## Declarations of interest

The author(s) declare that there is no conflict of interest with regards to the research, authorship and/or publication of this article.

## References

- Abeyssekara, S., J.M. Naylor, A. Wassef, U.V. Sak, G.A. Zello. 2007. D-Lactic acid-induced neurotoxicity in a calf model. *American Journal of Physiology and Medicine*, 293: 558-565.
- Annane, D., V. Sebille, C. Charpentier. 2002. Effect of treatment with low doses of hydrocortisone and fludrocortisone on mortality in patients with septic shock. *American Journal of Veterinary Medicine*, 7: 862-871.
- Aschenbach, J., R.G. Gabel. 2000. Effect and absorption of histamine in sheep rumen significance of acidotic epithelial damage. *Journal of Animal Science*, 78: 464-470.
- Aziz, M., A. Khan, A.H. Adnan, M. Izatullah. 2017. Traditional uses of medicinal plants reported by the indigenous communities and local herbal practitioners of Bajaur Agency, Federally Administrated Tribal Areas Pakistan. *Journal of Ethno Veterinary Medicine*, 198: 268-281.
- Bashir S., T. Hussain, M.A. Dar, A.A. Dar, A.A. Bhat, J. Farooq. 2004. Ruminant lactic acidosis in cow clinical assessment. *Journal of Livestock Science*, 6: 73-76.
- Bonadiman, H.B., C.I. Schwertz, S.H.D. Sousa, R.M. Bianchi, R.A. Caprioli, A.G.C. Dalto. 2018. Acute rumenitis due to lipid overload in a bovine. *Ciência Rural*, 48(9): 1231-1244.
- Callaghan, M., J.M. Auliffe, P. Rodgers, R.J. Hernandez-Medrano, V.E.F. Perry. 2016. Sub-acute ruminal acidosis reduces sperm quality in beef bulls. *Journal of Animal Science*, 8: 3215-3228.
- Chand, R., R. Kaur, A. Kaur, V. Kumar, C. Nirmala, A.N. Singh. 2016. Assessment of ethnomedicinal plant diversity of Una and Hamirpur district of Himachal Pradesh, India: an ethno-ecological approach. *Journal of Animal and Plant Science*, 12: 1475-1490.
- Cottee, G., I. Kyriazakis, T.M. Widowski, M.I. Lindinger, J.P. Cant, T.F. Duffield, V.R. Osborne, B.W. McBride. 2004. The effects of subclinical ruminal acidosis on Sodium bicarbonate supplements water intake for lactating dairy cows. *Journal of Dairy Science*, 7: 2248-2253.
- Dehkordi, A., Z.K. Dehkordi. 2011. Occurrence of metabolic alkalosis in rumen lactic acidosis a review article. *Journal of Clinical Pathology*, 1: 1-3.
- Ding, Z., Y. Xu. 2011. Physiological, biochemical and histopathological effects of fermentative acidosis in ruminant production: A minimal review. *Spanish Journal of Agriculture Science*, 2: 414-422.
- Escareno, L., H. Salinas-Gonzalez, M. Wurzinger, L. Iniguez, J. Solkner, C. Meza-Herrera. 2012. Dairy goat production systems. *Tropical Animal Health and Production*, 1: 17-34.
- Gentile, A., S. Sconza, I. Lorenz. 2004. D-Lactic Acidosis in Calves as a Consequence of Experimentally Induced Ruminal Acidosis. *Journal of Veterinary Medicine*, 51: 64-70.
- Gonzalez, F., J.M. Ruiperez, J.C. Sanchez, S. Souza, M. Martinez-Subiela, J.J. Ceron. 2010. Haptoglobin and serum amyloid A in subacute ruminal acidosis. *Reviews of Veterinary Medicine and Zoology*, 57: 159-167.
- Gozho, G., N.J.C. Plaizier, G.O. Krause, A.D. Kennedy, K.M. Wittenberg. 2005. Sub-acute ruminal acidosis induces ruminal lipopolysaccharide release and triggers an inflammatory response. *Journal of Dairy Science*, 88: 1399-1403.
- Haji, H., M.R.M. Kolae, F. Nouri, A. Saberi, A. Jafari, M. Dehkordi. 2006. Effects of Experimentally Induced Ruminal lactic acidosis on Blood pH, Bicarbonate and in the sheep. *Pakistan Journal of Bioscience*, 4: 9-10.
- Handekar, P., B. Kolte, A.Y. Mendhe, H.C. Puri, R.M. Ravikanth, S. Maini, D.S. Rekhe. 2010. Effect of Polyherbal formulations on ruminal digestion in goat. *Veterinary World*, 5: 230-233.
- Harper, C. 2006. Thiamine (vitamin B1) deficiency and associated brain damage is still common throughout the world and prevention is simple and safe. *European Journal of Neuroscience*, 10: 1078-1082.
- Hernández, J., J.L. Benedito, A. Abuelo, C. Castillo. 2014. Ruminal acidosis in feedlot: from aetiology to prevention. *World Journal*, 10: 123-130.
- Husain, S., R.N. Malik, M. Javaid, S. Bibi. 2008. Ethnobotanical properties and uses of medicinal plants of Morgah biodiversity park, Rawalpindi. *Pakistan Journal of Botany*, 5: 1897-1911.
- Joaquin, H., L.B. Jose, A. Angel, C. Cristina. 2014. Ruminal Acidosis in Feedlot from Aetiology to Prevention. *Journal of Veterinary Medicine*, 4: 2018-2028.
- Kamra, D.N. 2005. Rumen microbial ecosystem. *Current Science*, 1: 124-135.
- Karapinar, T., M. Dabak, O. Kizil, E. Balıkcı. 2008. Severe thiamine deficiency in sheep with acute ruminal lactic acidosis. *Journal of Veterinary Internal Medicine*, 3: 662-665.
- Kawas, J., R. Garcia-Castillo, H. Fimbres-Durazo, F. Garzacazares, J.F. Hernandez-Vidal, E. Olivares-Saenz. 2007. Effects of Sodium bicarbonate and yeast on nutrient intake, digestibility, and ruminal fermentation of light-weight lambs fed finishing diets. *Small Ruminant Research*, 67: 149-156.
- Kleen, J., G.A. Hoojjer, J. Rehage. 2003. Subacute ruminal acidosis (SARA): A review. *Journal of Veterinary Medicine Series*, 50: 406-414.
- Lascano, G.J. 2011. Optimizing nutrient utilization of a precision feeding system for dairy heifers using low and high forage diets. *Veterinary Medicine Series*, 40: 409-419.
- Lean, I.J., L.K. Wade, M.A. Curtis, J. Porter. 2000. New approaches to control of ruminal acidosis in dairy cattle. *Asian-Australasian Journal of Animal Science*, 13: 266-269.
- Minuti, A., S. Ahmed, E. Trevisi, F. Piccioli-Cappelli, G. Bertoni, N. Jahan, P. Bani. 2014. Experimental acute rumen acidosis in sheep: Consequences on clinical rumen, and gastrointestinal permeability conditions and blood chemistry. *Journal of Animal Science*, 9: 3966-3977.
- Oliveira, D.M., J.M.A. Medeiros, A.C.O. Assis, A.B. Neves, G.J.N. Galiza, S.V.D. Simoes, A.F.M. Dantas, F. Riet-Correa. 2009. Acidose lática ruminal aguda em caprinos. *Ciência Animal Brasileira*, 117-122.
- Owens, F. N., D.S. Secrist, W.J. Hill, D.R. Gill. 1998. Acidosis in cattle: a review. *Journal of animal science*, 76(1): 275-286.
- Penner, G., B.K.A. Beauchemin, T. Mutsvangwa. 2007. Severity of ruminal acidosis in primiparous Holstein cows during the periparturient period. *Journal of Dairy Science*, 90: 365-375.
- Piccione, G., S. Casella, L. Lutri, I. Vazzana, V. Ferrantelli, G. Caola. 2010. Reference values for some hematological, hematochemical and electrophoretic parameters in Girgentana goat. *Turkish Journal of Veterinary and Animal Science*, 34(2): 197-204.
- Radosüts, O., M.C.C. Gay, K.W. Hinchcliff, P.D. Constable. 2007. *Veterinary Medicine, A textbook of the diseases of cattle, horses, sheep, pigs, and goats*. Saunders-Elsevier (USA). pp: 898.
- Radosüts, O.M., C.C. Gay, D.C. Blood, K.W. Hinchcliff KW. 2000. *Rumen Acidosis*. In: *Veterinary Medicine*, 9th Edition: Saunders, Elsevier, London, pp. 293-303.
- Ullah, H.A., J.A. Khan, M.S. Khan, U. Sadique, M. Shah, M. Idrees, Z. Shah. 2013. Clinico-therapeutical trials of lactic acidosis in small ruminants. *Journal of Animal and Plant Sciences*, 23: 80-83.
- Yang, W.Z., Y.L. Li, T.A. McAllister, J.J. McKinnon, K.A. Beauchemin. 2012. Wheat distillers grains in feedlot cattle diets: Feeding behavior, growth performance, carcass characteristics, and blood metabolites. *Journal of Animal Science*, 4: 1301-1310.
- Zein-Eldin, M.M., M.M. Ghanem, A.Y. El-Raof, H.M. El-Attar, H.M. El-Khaat. 2014. Clinical, haematobiochemical and ruminal changes during the onset and recovery of induced lactic acidosis in sheep. *Journal of Biology and Animal Husbandry*, 4: 647-659.