

**THE NONINVASIVE LOCALISATION OF BRAIN  
ABNORMALITY IN INTRACTABLE FOCAL EPILEPSY IN  
CHILDHOOD**

Thesis submitted for the Degree of Doctor of Philosophy  
in the Faculty of Medicine

*by*

**Judith Helen Cross**

Institute of Child Health

University of London

1998


ProQuest Number: U644132

All rights reserved

INFORMATION TO ALL USERS

The quality of this reproduction is dependent upon the quality of the copy submitted.

In the unlikely event that the author did not send a complete manuscript and there are missing pages, these will be noted. Also, if material had to be removed, a note will indicate the deletion.



ProQuest U644132

Published by ProQuest LLC(2016). Copyright of the Dissertation is held by the Author.

All rights reserved.

This work is protected against unauthorized copying under Title 17, United States Code.  
Microform Edition © ProQuest LLC.

ProQuest LLC  
789 East Eisenhower Parkway  
P.O. Box 1346  
Ann Arbor, MI 48106-1346

## ABSTRACT

The work described in this thesis evaluates the role of noninvasive magnetic resonance and nuclear medicine techniques in the investigation of focal epilepsy of childhood, and more specifically in the presurgical evaluation of children who are potential candidates for surgery. Seventy five children were prospectively investigated after referral for assessment and investigation of intractable focal epilepsy. Initial clinical localisation was made on the basis of full clinical assessment with EEG.

All underwent magnetic resonance imaging. Abnormalities were found in 88% of children, concordant with the seizure focus in 80%. Further magnetic resonance techniques were assessed with regard to lateralisation of temporal lobe epilepsy (TLE). T2 relaxometry of the hippocampi and proton magnetic resonance spectroscopy ( $^1\text{H}$  MRS) of the mesial temporal lobes were demonstrated to be lateralising in a high proportion of these children, and also showed a high rate of bilateral abnormality.

In order to relate these structural abnormalities to the epileptogenic focus, the technique of ictal single photon emission computed tomography (SPECT), using  $^{99}\text{Tc}^m$  HMPAO as a marker of cerebral blood flow, was developed for this study. Focal hyperperfusion was seen in 72% of ictal scans when compared to interictal scans, concordant with the seizure focus in all. Where no perfusion change was noted after an ictal injection, slowing of the EEG was present at the time of injection consistent with ischaemia, suggesting rCBF does not increase in all focal seizures. Correlation of interictal SPECT scans with  $^1\text{H}$  MRS of the mesial temporal regions in children with TLE demonstrated correlation between neuronal loss or dysfunction and hypoperfusion. Where similar damage on the two sides was demonstrated by  $^1\text{H}$  MRS, no asymmetry of interictal perfusion was seen.

These findings have led to a better understanding of the underlying pathophysiology of intractable focal epilepsy of childhood and have resulted in an increase in the number of children evaluated for epilepsy surgery. The thesis concludes with a discussion of an optimised noninvasive strategy for presurgical evaluation in children.

## DECLARATION

I, Judith Helen Cross, declare that this thesis is all my own work. I clinically reviewed all 75 children within the study. All ictal EEG's were initially read by me, with subsequent verification of the report, and review of all interictal EEG's with the Consultant Neurophysiologist, Dr Stewart Boyd. The magnetic resonance images and spectroscopy were performed and processed by the research radiographer, Miss Cheryl Johnson, but I reviewed all the magnetic resonance images in conjunction with the independent observer, Dr Graeme Jackson. I read all T2 maps as the second independent observer following the first observer, Miss Cheryl Johnson. All T2 relaxometry and  $^1\text{H}$  MRS results were analysed by me.

The technique of ictal  $^{99}\text{Tc}^{\text{m}}$  HMPAO SPECT was developed for routine clinical use on the ward by me in conjunction with the Consultant in Nuclear Medicine, Dr Isky Gordon. All but a small number of ictal injections were given by me; the remaining injections were given by the Epilepsy Liaison Nurse, Sister Alison Harper. I processed and read all ictal, postictal and interictal scans and subsequently analysed the results, and performed the correlative studies with MRI, EEG and  $^1\text{H}$  MRS.



J Helen Cross

**PhD Student**

Professor BGR Neville



Professor DG Gadian



**Supervisors**

## TABLE OF CONTENTS

<b>ABSTRACT</b> .....	<b>2</b>
<b>DECLARATION</b> .....	<b>3</b>
<b>CONTENTS</b> .....	<b>4</b>
<b>LIST OF TABLES</b> .....	<b>10</b>
<b>LIST OF FIGURES</b> .....	<b>14</b>
<b>ABBREVIATIONS</b> .....	<b>18</b>
<b>ACKNOWLEDGEMENTS</b> .....	<b>19</b>
<b>CHAPTER 1: The presurgical evaluation of focal epilepsy in childhood</b> .....	<b>20</b>
1.1 Introduction	20
1.2 Definitions and epidemiology	21
1.3 Prognosis and the concept of intractability	24
1.4 The argument for epilepsy surgery in childhood	26
1.5 The problem of localisation	30
1.7 Structural vs functional abnormality	32
1.8 Aims of the study	36
<b>CHAPTER 2: Clinical and electroencephalographic localisation of the ‘seizure focus’</b> .....	<b>38</b>
2.1 Introduction	38
2.2 The problem of seizure localisation	40
2.3 The problem of seizure detection	41
2.4 Patient population	42

<b>2.5</b>	<b><i>Clinical localisation</i></b>	<b>43</b>
	2.5.1 <i>Methods</i>	43
	2.5.2 <i>Results</i>	44
<b>2.6</b>	<b><i>EEG localisation</i></b>	<b>49</b>
	2.6.1 <i>Methods</i>	49
	2.6.2 <i>Results</i>	51
<b>2.7</b>	<b><i>Clinical and EEG localisation</i></b>	<b>53</b>
<b>2.8</b>	<b><i>Clinical features of the patient population</i></b>	<b>54</b>
<b>2.9</b>	<b><i>Discussion</i></b>	<b>56</b>

**CHAPTER 3: Magnetic resonance imaging.....59**

<b>3.1</b>	<b><i>Pathological substrates in epilepsy</i></b>	<b>59</b>
	3.1.1 <i>Cortical development and implications</i> <i>of its disruption</i>	60
	3.1.2 <i>Tumours</i>	62
	3.1.3 <i>The hippocampus and its role in epilepsy</i>	63
	3.1.4 <i>Progressive disorders</i>	66
	3.1.5 <i>Ischaemic lesions</i>	67
<b>3.2</b>	<b><i>Magnetic resonance imaging in epilepsy</i></b>	<b>67</b>
<b>3.3</b>	<b><i>Methods</i></b>	<b>68</b>
<b>3.4</b>	<b><i>Results</i></b>	<b>74</b>
	3.4.1 <i>Temporal lobe epilepsy</i>	74
	3.4.2 <i>Extratemporal epilepsy</i>	77
	3.4.3 <i>Hemisyndromes</i>	79
	3.4.4 <i>Unlocalised epilepsy</i>	81
<b>3.5</b>	<b><i>Discussion</i></b>	<b>82</b>

**CHAPTER 4: Quantitative T2 relaxometry in focal epilepsy.....85**

<b>4.1</b>	<b><i>Introduction</i></b>	<b>85</b>
<b>4.2</b>	<b><i>Methods</i></b>	<b>88</b>

<b>4.3</b>	<i>Control data</i>	90
<b>4.4</b>	<i>Patient population</i>	93
<b>4.5</b>	<i>Data analysis</i>	94
<b>4.6</b>	<i>Results</i>	94
	4.6.1 <i>Temporal lobe epilepsy</i>	94
	4.6.2 <i>Extratemporal epilepsy</i>	98
	4.6.3 <i>Hemisyndromes</i>	99
<b>4.7</b>	<i>Summary of results</i>	100
<b>4.8</b>	<i>Relationship between T2 relaxometry, a history of early childhood convulsions and status epilepticus</i>	100
<b>4.9</b>	<i>Discussion</i>	102
	<i>Appendix</i>	108

**CHAPTER 5: Proton magnetic resonance spectroscopy.....112**

<b>5.1</b>	<i>Introduction</i>	112
<b>5.2</b>	<i>Methods</i>	116
<b>5.3</b>	<i>Control data</i>	117
<b>5.4</b>	<i>Patient population</i>	118
<b>5.5</b>	<i>Data analysis</i>	119
<b>5.6</b>	<i>Results</i>	119
	5.6.1 <i>Temporal lobe epilepsy</i>	119
	5.6.2 <i>Repeated studies</i>	123
	5.6.3 <i>Extratemporal epilepsy</i>	124
<b>5.7</b>	<i>Comparison of <sup>1</sup>H MRS and T2 relaxometry</i>	125
	5.7.1 <i>Temporal lobe epilepsy</i>	125
	5.7.2 <i>Extratemporal epilepsy</i>	126
<b>5.8</b>	<i>Discussion</i>	127
	<i>Appendix</i>	132

**CHAPTER 6: Regional cerebral blood flow in localisation  
of the seizure focus.....133**

<b>6.1</b>	<i>Introduction</i>	<b>133</b>
<b>6.2</b>	<i>Single photon emission computed tomography</i>	<b>135</b>
<b>6.3</b>	<i>SPECT in epilepsy</i>	<b>136</b>
<b>6.4</b>	<i>Methods</i>	<b>138</b>
	6.4.1 <i>Definitions</i>	138
	6.4.2 <i>Radioisotope injection</i>	139
	6.4.3 <i>Scan acquisition</i>	141
	6.4.4 <i>Data reconstruction and interpretation</i>	141
<b>6.5</b>	<i>Results</i>	<b>146</b>
	6.5.1 <i>Scans performed</i>	146
	6.5.2 <i>Limited frame acquisition</i>	148
	6.5.3 <i>Asymmetry of perfusion</i>	149
	6.5.4 <i>Ictal scans</i>	155
	6.5.5 <i>Postictal scans</i>	155
	6.5.6 <i>Interictal scans</i>	158
	6.5.7 <i>Ictal/postictal vs interictal scans</i>	160
<b>6.6</b>	<i>Ictal/postictal rCBF in special situations</i>	<b>160</b>
	6.6.1 <i>Secondary generalisation</i>	160
	6.6.2 <i>Hyperventilation</i>	162
	6.6.3 <i>Ictal/postictal scans in unlocalised epilepsy</i>	162
<b>6.7</b>	<i>Discussion</i>	<b>163</b>
	<i>Appendix</i>	<b>171</b>

**CHAPTER 7: Specific patterns of regional cerebral blood  
flow during seizures.....175**

<b>7.1</b>	<i>Introduction</i>	<b>175</b>
<b>7.2</b>	<i>Relationship of ictal/postictal rCBF to magnetic resonance imaging</i>	<b>177</b>
	7.2.1 <i>Patient population</i>	178



	7.2.2 Results	178
7.3	Regional cerebral blood flow in subcortical structures	185
	7.3.1 Basal ganglia	185
	7.3.2 Cerebellum	186
7.4	Regional cerebral blood flow in relation to the 'seizure focus'	186
	7.4.1 Patient population	187
	7.4.2 Results	188
7.5	Discussion	197
	7.5.1 Relationship of ictal rCBF to pathology	197
	7.5.2 Ictal perfusion of subcortical structures	198
	7.5.3 Focal hypoperfusion in relation to the 'seizure focus'	200
	7.5.4 Conclusions to ictal rCBF to pathology	202

## **CHAPTER 8: The pathology underlying interictal SPECT.....204**

8.1	Introduction	204
8.2	Relationship of interictal rCBF to MRI	207
	8.2.1 Patient population	207
	8.2.2 Results	207
8.3	Repeat interictal studies	211
8.4	Relationship of interictal hypoperfusion to neuronal loss or damage	213
	8.4.1 Patient population	214
	8.4.2 Results	214
8.5	Discussion	220

## **CHAPTER 9: The presurgical evaluation of children with drug resistant focal epilepsy: An optimised strategy.....225**

9.1	The problem of the evaluation of outcome	225
9.2	Neuroimaging in the localisation of the seizure focus	228

9.2.1	<i>Magnetic resonance imaging</i>	229
9.2.2	<i>Quantitative magnetic resonance</i>	229
9.2.3	<i>Single photon emission computed tomography</i>	230
9.3	<i>The relative localising value of EEG, MR and SPECT</i>	231
9.4	<i>The presurgical evaluation of children with focal epilepsy- where are we at present?</i>	234
9.5	<i>The way forward</i>	235
9.5.1	<i>Presurgical evaluation</i>	235
9.5.2	<i>Postoperative outcome</i>	236
9.5.3	<i>Underlying pathophysiology of focal seizures in childhood</i>	237

**BIBLIOGRAPHY.....239**

**PUBLICATIONS ARISING FROM THIS WORK.....Back cover**

## LIST OF TABLES

### **CHAPTER 1: The presurgical evaluation of focal epilepsy in childhood**

1.1	<i>Classification of seizure types</i>	22
1.2	<i>Classification of epilepsy syndromes ILAE 1989/92</i>	23

### **CHAPTER 2: Clinical and electroencephalographic localisation of the 'seizure focus'**

2.1	<i>Clinical features of seizures in children classified as having temporal lobe epilepsy</i>	46
2.2	<i>Clinical features of seizures in children classified as having extratemporal epilepsy</i>	48
2.3	<i>Details of the medications withdrawn</i>	52
2.4	<i>Interictal and ictal EEG localisation in the 75 children within the study</i>	52
2.5	<i>Overall clinical and EEG localisation in the 75 children</i>	54

### **CHAPTER 3: Magnetic resonance imaging**

3.1	<i>Key stages in normal cerebral development</i>	61
3.2	<i>MRI findings in children with a clinical diagnosis of temporal lobe epilepsy</i>	75
3.3	<i>MRI findings in children with a diagnosis of extratemporal epilepsy</i>	79
3.4	<i>MRI findings in children with hemisyndromes</i>	81

### **CHAPTER 4: Quantitative T2 relaxometry in focal epilepsy**

4.1	<i>Comparison of visual analysis of MR images and quantitative T2 measurements of the hippocampus</i>	95
4.2	<i>T2 relaxometry of the hippocampi in nonlesional TLE in relation to early convulsions</i>	101

A4.1	<i>Clinical details, MRI and results of T2 relaxometry in children with nonlesional temporal lobe epilepsy</i>	108
A4.2	<i>Clinical details, MRI and results of T2 relaxometry in children with lesional temporal lobe epilepsy</i>	109
A4.3	<i>Clinical details, MRI and results of T2 relaxometry in children with extratemporal epilepsy</i>	110
A4.4	<i>Clinical details, MRI and results of T2 relaxometry in children with hemisindrome epilepsy</i>	111
A4.5	<i>Clinical details, MRI and results of T2 relaxometry in children with unlocalised epilepsy</i>	111

## **CHAPTER 5: Proton magnetic resonance spectroscopy**

5.1	<i>Relative mean percentage change in absolute intensity data</i>	120
5.2	<i>Mean signal intensities for 13 controls and 20 patients.</i>	121
5.3	<i>Lateralisation of the seizure focus</i>	121
5.4	<i><sup>1</sup>H MRS data on three children who underwent repeat studies two years apart</i>	123
5.5	<i>Results of <sup>1</sup>H MRS of the mesial temporal regions contralateral to the seizure focus pre and post-operatively in eleven patients who underwent surgery</i>	123
5.6	<i>Absolute intensity data for NAA, Cho and Cr ipsilateral and contralateral to the seizure focus in extratemporal epilepsy compared to controls</i>	125
5.7	<i>Comparison of <sup>1</sup>H MRS and T2 relaxometry in temporal lobe epilepsy</i>	126
5.8	<i>Comparison of <sup>1</sup>H MRS and T2 relaxometry in extratemporal epilepsy</i>	126
A5.1	<i><sup>1</sup>H MRS in relation to clinical, EEG, MRI and pathology data in children with TLE</i>	132

## **CHAPTER 6: Regional cerebral blood flow in localisation of the seizure focus**

6.1	<i>Details of six children who underwent injection during secondary generalisation</i>	161
A6.1	<i>Results of ictal/interictal SPECT in children with temporal lobe epilepsy</i>	171
A6.2	<i>Results of ictal/interictal SPECT in children with extratemporal and hemisindrome epilepsy</i>	172
A6.3	<i>Results of postictal/interictal SPECT</i>	173
A6.4	<i>Results of remaining interictal SPECT scans, where there was no ictal/postictal scan performed</i>	174

## **CHAPTER 7: Specific patterns of regional cerebral blood flow during seizures**

7.1	<i>Abnormality seen on the comparison of 55 ictal/postictal SPECT to respective interictal scans in 51 children related to MRI findings</i>	181
7.2	<i>MRI and SPECT data of Group 1</i>	190
7.3	<i>EEG data of Group 1</i>	191
7.4	<i>MRI and SPECT data of Group 2</i>	193
7.5	<i>EEG data of Group 2</i>	194
7.6	<i>Summary of EEG findings in Group 3</i>	195

## **CHAPTER 8: The pathology underlying interictal SPECT**

8.1	<i>Interictal SPECT compared to MRI in children with temporal lobe epilepsy</i>	208
8.2	<i>Interictal SPECT compared to MRI in children with extratemporal epilepsy</i>	208
8.3	<i>Interictal SPECT compared to MRI in children with hemisindromes</i>	211

8.4	<i>Details of 14 children with temporal lobe epilepsy who underwent both <math>^{99}\text{Tc}^m</math> HMPAO SPECT and <math>^1\text{H}</math> MRS of the mesial temporal regions</i>	215
-----	---	-----

**CHAPTER 9: The presurgical localisation of children with drug resistant focal epilepsy: An optimised strategy**

9.1	<i>Engel classification of outcome from epilepsy surgery</i>	227
9.2	<i>The relative localising value of each of the investigations used in this study for children who proceeded to temporal lobectomy</i>	232
9.3	<i>The relative localising value of each of the investigations used in this study for children who proceeded to hemispherectomy</i>	233

## LIST OF FIGURES

### CHAPTER 3: Magnetic resonance imaging

3.1:	<i>The position of the hippocampus along the mesial surface of the temporal lobe</i>	63
3.2	<i>Diagram of the transverse section of the hippocampal body</i>	64
3.3	<i>Optimised magnetic resonance imaging</i>	71
3.4	<i>Tilted coronal images through the hippocampus of patient T1 showing left hippocampal sclerosis</i>	72
3.5	<i>Tilted coronal images of patient T32 showing a foreign tissue lesion and hippocampal sclerosis</i>	76
3.6	<i>Tilted coronal section, T2 weighted sequence of patient T13, showing right temporal gliosis</i>	78
3.7	<i>Tilted coronal image through the frontal lobes of patient E2 showing right frontal cortical dysplasia</i>	78
3.8	<i>Tilted coronal section, T2 weighted sequence of patient H7 showing a porencephalic cyst in the right middle cerebral artery territory and a small hippocampus</i>	80

### CHAPTER 4: Quantitative T2 relaxometry in focal epilepsy

4.1	<i>Sagittal scout image to show the angle of slice orientation for the acquisition of images for T2 relaxometry</i>	88
4.2	<i>Diagram to illustrate methodology for calculation of a T2 map</i>	89
4.3	<i>T2 map with the position of the region of interest within the left hippocampus from which a mean T2 value is taken</i>	90
4.4	<i>T2 relaxometry in a control population</i>	91
4.5	<i>Percentage of water in whole brain by age as determined at postmortem</i>	92
4.6	<i>T2 relaxation of water in cerebral tissue as a function of gestational age</i>	92

4.7	<i>T2 relaxometry in nonlesional TLE</i>	97
4.8	<i>T2 relaxometry in lesional TLE</i>	98
4.9	<i>T2 relaxometry in extratemporal epilepsy</i>	99

## **CHAPTER 5: Proton magnetic resonance spectroscopy**

5.1	<i>Coronal magnetic resonance image, to demonstrate the 8ml cubic volume of interest, and <math>^1\text{H}</math> spectrum from a normal subject.</i>	115
5.2	<i><math>^1\text{H}</math> spectra from patient T24</i>	120
5.3	<i>Individual right and left NAA/(Cho+Cr) ratios in children with right TLE and left TLE compared to normal subjects.</i>	122

## **CHAPTER 6: Regional cerebral blood flow in localisation of the seizure focus**

6.1	<i>Angle of slice for semiquantitative analysis of SPECT scans</i>	142
6.2	<i><math>^{99}\text{Tc}^m</math> HMPAO SPECT scan, transverse section showing regions of interest in the frontal and parietal lobes for semiquantitative analysis.</i>	143
6.3	<i><math>^{99}\text{Tc}^m</math> HMPAO SPECT scan, transverse section through the temporal lobes showing regions of interest for semiquantitative analysis.</i>	144
6.4	<i><math>^{99}\text{Tc}^m</math> HMPAO SPECT scan, coronal section through the frontal lobes showing the regions of interest used for semiquantitative analysis.</i>	145
6.5	<i><math>^{99}\text{Tc}^m</math> HMPAO SPECT scan showing analysis of the same data set using <math>360^\circ</math> data and limited acquisition of data.</i>	147
6.6	<i>Total number of interictal and ictal/postictal scans demonstrating abnormality according to percentage asymmetry used.</i>	150
6.7	<i>Proportion of ictal/postictal scans demonstrating asymmetry of perfusion according to percentage asymmetry used.</i>	151



6.8	<i>Proportion of interictal scans demonstrating asymmetry of perfusion according to percentage asymmetry used.</i>	151
6.9	<i>Ictal and interictal <math>^{99}\text{Tc}^m</math> HMPAO SPECT scans from patient T6.</i>	153
6.10	<i>Ictal and interictal <math>^{99}\text{Tc}^m</math> HMPAO SPECT scans from patient E11.</i>	154
6.11	<i>Ictal, postictal and interictal <math>^{99}\text{Tc}^m</math> HMPAO SPECT scans from patient T2.</i>	156
6.12	<i>Postictal and interictal <math>^{99}\text{Tc}^m</math> HMPAO SPECT scans from patient T12.</i>	157
6.13	<i>Overall results of ictal, immediate postictal and interictal SPECT scans in temporal, extratemporal and hemisindrome epilepsy.</i>	159
6.14	<i>Ictal and interictal <math>^{99}\text{Tc}^m</math> HMPAO SPECT scans from patient H3</i>	161

## **CHAPTER 7: Specific patterns of regional cerebral blood flow during seizures**

7.1	<i>Coronal sections perpendicular to the temporal lobe, T2 weighted sequence MRI and <math>^{99}\text{Tc}^m</math> HMPAO SPECT scans of patient T34.</i>	179
7.2	<i>Coronal sections perpendicular to the temporal lobe, T2 weighted sequence MRI and <math>^{99}\text{Tc}^m</math> HMPAO SPECT scans of patient U1.</i>	180
7.3	<i>Transverse sections, MRI (reconstructed from a 3D MP-RAGE data set) parallel to the axis of the temporal lobes, and <math>^{99}\text{Tc}^m</math> HMPAO SPECT scans of patient H4.</i>	183
7.4	<i>Transverse sections, MRI (reconstructed from a 3D MP-RAGE data set) parallel to the axis of the temporal lobes, and <math>^{99}\text{Tc}^m</math> HMPAO SPECT scans of patient H14.</i>	184
7.5	<i><math>^{99}\text{Tc}^m</math> HMPAO SPECT scans and EEG at the time of injection of patient E7</i>	189
7.6	<i><math>^{99}\text{Tc}^m</math> HMPAO SPECT scans and EEG at the time of injection of patient T32</i>	196

## **CHAPTER 8: The pathology underlying interictal SPECT**

- 8.1 *Inversion recovery MRI transverse section parallel to the temporal lobes and interictal  $^{99}\text{Tc}^m$  HMPAO SPECT scans from patient T4.* 209
- 8.2 *MRI (reconstructed from a 3D MP-RAGE data) set transverse section parallel to the temporal lobes and interictal  $^{99}\text{Tc}^m$  HMPAO SPECT scans from patient H2.* 210
- 8.3 *Graph to show the results of  $^1\text{H}$  MRS of the mesial temporal regions in 14 children with TLE compared to 13 control subjects.* 217
- 8.4  *$^1\text{H}$  MR spectra and interictal  $^{99}\text{Tc}^m$  HMPAO SPECT scan from patient T16.* 218
- 8.5 *Comparison of NAA/(Cho+Cr) ratios from ipsilateral and contralateral temporal lobes, grouped according to whether SPECT was predictive or nonpredictive of the seizure focus in children with TLE.* 219

## ABBREVIATIONS

<b>AHS</b>	Ammon's horn sclerosis
<b>Cho</b>	Choline containing compounds, such as phosphoryl- and glycerphosphorylcholine
<b>Cr</b>	Creatine + phosphocreatine
<b>CSI</b>	Chemical shift imaging
<b>CT</b>	Computerised tomography
<b>DNET</b>	Dysembryoplastic neuroepithelial tumour
<b>EEG</b>	Electroencephalogram
<b>EPC</b>	Epilepsia partialis continua
<b>ETE</b>	Extratemporal epilepsy
<b>FTL</b>	Foreign tissue lesion
<b>HA</b>	Hippocampal atrophy
<b>HS</b>	Hippocampal sclerosis
<b>HMPAO</b>	Hexamethylpropylene amine oxime
<b><sup>1</sup>H MRS</b>	Proton magnetic resonance spectroscopy
<b>L</b>	Left
<b>MCA</b>	Middle cerebral artery
<b>MRI</b>	Magnetic resonance imaging
<b>MP-RAGE</b>	Magnetization-Prepared-Rapid-Acquisition-Gradient-Echo
<b>NAA</b>	N-acetylaspartate
<b><sup>31</sup>P MRS</b>	Phosphorus magnetic resonance spectroscopy
<b>R</b>	Right
<b>rCBF</b>	Regional cerebral blood flow
<b>SPECT</b>	Single photon emission computed tomography
<b><sup>99</sup>Tc<sup>m</sup></b>	Technetium
<b>T</b>	Tesla
<b>TI</b>	Inversion time
<b>TR</b>	Recovery time
<b>TE</b>	Echo time

## ACKNOWLEDGEMENTS

This research has been dependent upon funding from Action Research and The Wellcome Trust, for which I am extremely grateful. My grateful thanks are also extended to my supervisors, Brian Neville and David Gadian who have guided me and provided support throughout.

Such a project as this inevitably involves contributions from multiple disciplines, and my thanks must go to Stewart Boyd (Neurophysiology), Graeme Jackson and Alan Connelly (Magnetic Resonance) and Isky Gordon, Peter Anderson and Andrew Todd-Pokropek (Nuclear Medicine) for help and advice in their respective fields. I am also grateful to Cheryl Johnson, Alison Harper and Barbara MacDonald for their practical support in achieving MRI and SPECT scans.

Much discussion is carried out in the light of such results, and for this I am grateful not only to my supervisors and others listed above, but also David Taylor for sharing his vast experience in epilepsy surgery, Jean Aicardi for his experience of epilepsy, and Fenella Kirkham for discussion about cerebral blood flow.

My thanks must also go to Simon Robinson and Amanda Robinson for their expertise of the data base, to Sally Dowsett and Michelle Gange for their more recent administrative support, the Department of Medical Illustration at Great Ormond Street Hospital for the production of prints, and Carlos de Sousa for the use of his scanner.

Finally, to my two daughters, Nicola and Sarah, and my husband Graham, I wish to acknowledge their understanding and tolerance.

# CHAPTER 1

## THE PRESURGICAL EVALUATION OF FOCAL EPILEPSY IN CHILDHOOD

---

### Contents

- 1.1 *Introduction*
  - 1.2 *Definitions and epidemiology*
  - 1.3 *Prognosis and the concept of intractability*
  - 1.4 *The argument for epilepsy surgery in childhood*
  - 1.5 *The problem of localisation*
  - 1.7 *Structural vs functional abnormality*
  - 1.8 *Aims of this study*
- 

### *1.1 Introduction*

Epilepsy is a chronic condition that causes significant disability in adults and children. The majority of patients diagnosed as having epilepsy respond promptly to medical treatment, with good long-term outlook for seizure remission off medication (Annegers *et al.*, 1979; Brorson and Wranne, 1987; Thurston *et al.*, 1982). However, around 20% continue to have seizures despite appropriate anticonvulsant therapy (Brorson and Wranne, 1987; Reynolds *et al.*, 1983). Resective epilepsy surgery is not a new concept, although in children it has only been considered in the past 20 years (Falconer, 1972b; Taylor, 1990). Problems have arisen in determining candidates for epilepsy surgery in childhood, as young children may always be considered to have the chance of 'growing out' of the condition, and also because the focal nature of the seizures may be difficult to recognise both clinically (Duchowny, 1987; Holmes, 1986; Wyllie and Luders, 1989) and electrophysiologically (Holmes, 1984; Wyllie *et al.*, 1993; Yamamoto *et al.*, 1987). The

ultimate decision as to what type of resective surgery may be appropriate has also been difficult without the use of invasive investigative techniques, which have understandably been used more sparingly in children.

The majority of adults coming to an epilepsy surgery programme have had a history of seizures since childhood (Cross *et al.*, 1996; Wyllie *et al.*, 1988). The consequences of such a long history of recurrent seizures may be several-fold. Seizures occurring in the young child may have an influence on learning and acquisition of skills, and the psychosocial consequence of recurrent seizures through school and the teenage years is apparent (Harrison and Taylor, 1976; Ounsted *et al.*, 1987). One can see a case, therefore, for early recognition of children who may benefit from surgery. As we gain insight into prognostic indicators of long-term outlook as well as experience in recognition of children who may have seizures of focal onset, we need techniques to guide us to which part of the brain may be responsible for seizure activity. This thesis describes investigations of the role of new neuroimaging techniques in determining focal brain abnormalities in children with medically intractable partial seizures, and assesses how such techniques may aid in presurgical evaluation.

## ***1.2 Definitions and epidemiology***

Epilepsy refers to a condition dominated by recurrent epileptic seizures; the word is derived from the greek word επιλαμδασειω meaning 'to seize' (Aicardi, 1994). An epileptic seizure itself is a transient clinical event, a change in behaviour, sensation and/or consciousness, resulting from a change in electrical activity within the brain. A variety of different clinical manifestations may occur, depending on the region of the brain in-

volved, whether a single area of the brain resulting in a focal (or partial) seizure, or the whole of the brain causing a generalised seizure. Epilepsy is not a diagnosis in itself but a symptom of underlying cerebral disturbance. It may occur in isolation or in association with other diagnoses, with a wide variety of aetiologies, and as a result with a variable prognosis.

In view of the heterogeneity of the disorder, attempts have been made at classification. For a long period of time *seizure types* formed the basis of classification (see Table 1.1), and this still remains useful, in particular with regard to decisions about

**Table 1.1: Classification of seizure types**

<b>Overall seizure type</b>	<b>Subtype</b>
<b>Generalised</b> <i>Involve both hemispheres from the onset</i>	Absence
	Myoclonic
	Atonic
	Tonic
	Tonic clonic
<b>Partial</b> <i>Onset and initial manifestation limited to one part of one hemisphere</i>	Sensory
Simple <i>retained awareness</i>	Motor
Complex <i>loss of awareness</i>	Autonomic
	Psychic

treatment. Seizure types also form the basis of the most recently proposed classification (Anonymous 1989) into *epilepsy syndromes*. The epilepsy syndromes are clusters of symptoms and signs occurring together (Aicardi, 1994), and are largely based on

**Table 1.2: Classification of the epilepsy syndromes *ILAE 1989/92* (Anonymous 1989)**

**Localisation-related (focal, local, partial) epilepsies and syndromes.**

- Idiopathic: eg Benign childhood epilepsy with centro-temporal spikes;  
Childhood epilepsy with occipital paroxysms;
- Symptomatic: eg *Chronic progressive epilepsia partialis continua of childhood*;  
*Other epilepsies and syndromes based on localization or aetiology*;  
eg *Temporal (mesial temporal sclerosis)*
- Cryptogenic

**Generalised epilepsies and syndromes.**

- Idiopathic: eg Childhood absence epilepsy;  
Juvenile absence epilepsy;  
Juvenile myoclonic epilepsy;
- Cryptogenic and/or symptomatic:  
eg West syndrome;  
Lennox-Gestaut syndrome;
- Symptomatic: Nonspecific aetiology: eg Early myoclonic encephalopathy;

**Epilepsies and syndromes undetermined whether focal or generalized**

Both generalised and focal seizures;  
Neonatal seizures;  
Severe myoclonic epilepsy in infancy;  
Epilepsy with continuous spike-waves during slow wave sleep;  
Acquired epileptic aphasia;

**Special syndromes**

Situation-related seizures;  
Febrile convulsions;  
Seizures associated with acute toxic/metabolic event;  
Isolated seizures or isolated status epilepticus

electroclinical data, although neuroradiological or other investigative findings may play a part (see Table 1.2). Within the syndrome classification, the terms idiopathic, symptomatic and cryptogenic are used to identify with likely aetiology. 'Idiopathic' includes those epilepsies where there is no recognisable associated brain disorder; they are probably of genetic basis and generally have a good prognosis. 'Symptomatic' refers to the epilepsies where there is a known primary cause, and 'cryptogenic' to those



secondary to some undetermined brain disorder. One of the advantages to such syndromic diagnoses is that some guide toward prognosis can be given; for example idiopathic encompasses the syndromes likely to have a good outcome. A large number of the syndromes are age-specific and present in childhood. However such a classification inevitably cannot account for all aspects of the condition, and gives no indication as to the pathophysiology.

The incidence of epilepsy is highest at the two extremes of age, that is in the very young and the elderly (Hauser, 1992). There have been a number of epidemiological studies investigating the prevalence of childhood epilepsy, but they have varied in methodology and inclusion criteria; a number have included single seizures and febrile convulsions not within the strict definition of epilepsy. The prevalence of 'active' epilepsy (that is those who had at least one seizure within the last 1-5 years, according to the study, or those who remain on anticonvulsant medication) for children however varies, between 3/1000-6/1000 (Brewis *et al.*, 1966; Haerer *et al.*, 1986; Hauser *et al.*, 1991). The prevalence also increases with increasing age during childhood, ranging from a mean of 3.8/1000 in children aged 0-9 years of age to 7.8/1000 in children aged 10-19 years (Forsgren, 1996). This reflects the number of age-specific syndromes diagnosed in childhood, more specifically those that are ongoing from which there is no remission.

### ***1.3 Prognosis and the concept of intractability***

Longitudinal epidemiological studies suggest that the majority of children and adults with epilepsy respond to anticonvulsant medication (Harrison and Taylor, 1976; Oka *et al.*, 1989), and as many as 70% achieve long-term remission from seizures (Annegers *et al.*,

1979; Brorson and Wranne, 1987; Thurston *et al.*, 1982). The recognition of an increasing number of epilepsy syndromes has enabled a likely prognosis to be formed at the time of diagnosis, such as in the benign syndromes, where children are likely to 'grow out' of a seizure tendency. Longitudinal data have also provided us with certain clinical indicators to those children more likely to have a poorer prognosis with regard to seizure control. Early onset of seizures (Annegers *et al.*, 1979; Emerson *et al.*, 1981; Lindsay *et al.*, 1979), associated neurological impairment (mental retardation or neurological deficit) (Emerson *et al.*, 1981; Lindsay *et al.*, 1979; Sillanpaa, 1990), and lack of early response to treatment (Anonymous 1992; Sillanpaa, 1990) have all been implicated. Seizure type has also been associated, in that partial seizures are less likely to remit than generalised seizures. Moreover, studies rigorous at excluding the now well-recognised benign syndromes of partial epilepsy (eg benign epilepsy of childhood with centrotemporal spikes) have reported long-term remission in the focal epilepsies in as few as 10-30% (Harbord and Manson, 1987; Kotagal *et al.*, 1987; Loiseau *et al.*, 1983).

Medically intractable or drug-resistant epilepsy may be defined as epileptic seizures that recur despite appropriate anticonvulsant treatment. An arbitrary definition of intractability that is used in adult epilepsy is resistance to at least two anticonvulsant drugs for at least two years (Duchowny, 1989; Oxbury and Adams, 1989). This would be consistent with the finding that failure to respond promptly to anticonvulsants indicates that an individual is less likely to achieve long term remission from seizures (Anonymous 1992; Sillanpaa, 1990). However, it is difficult to apply such a strict definition in childhood, particularly in the very young where medical intractability may be suspected at an earlier stage and acquisition of developmental skills may be compromised by frequent drug-resistant

seizures. At present we lack quantitative prognostic indicators, and we can therefore only surmise from epidemiological data.

#### ***1.4 The argument for epilepsy surgery in childhood***

Epilepsy surgery is not new; it has been performed for over one hundred years. Victor Horsley performed the first recorded operation for epileptic seizures in 1886, and reported on three operations that 'cured epilepsy' (Horsley, 1886). He subsequently performed further successful neurosurgical operations for epilepsy. However, his practice was severely curtailed following surgery on his own son (Taylor, 1986) who presented with seizures in his late teens. Horsley was the only surgeon regarded as competent to operate; his son recovered adequately to join the army but he was discharged on medical grounds, and died a few years later. Surgery at this time was very much based on the knowledge acquired of brain function from motor stimulation in animals, and therefore localisation was based on motor semiology and associated lesions found at surgery. Later Wilder Penfield, arriving at the Montreal Institute in 1928, became a pioneer in establishing surgery in the management of epilepsy (Feindel 1993). Initial attempts again were limited to the motor cortex, as selection for surgery was based on clinical criteria. The development of electroencephalography (EEG), however, a technique first published by Berger (Berger, 1929) and introduced to the Montreal Institute by Herbert Jasper in 1937 (Feindel 1993), enabled other areas to be reviewed. As a result, temporal lobe resection also became an established procedure.

Horsley recognised 'small tumours' or lesions on the cerebral cortex as surgically remediable causes of focal epilepsy. It was a considerable time later, however, that such

focal lesions were characterised pathologically. 'Ammon's horn' or true hippocampal sclerosis had first been described by Bouchet and Cazauvieil in 1825 (Bouchet and Cazauvieil, 1825), seen as a visible and palpable temporal lobe change in eight of 14 autopsied hippocampi from patients with epilepsy. Sommer was the first to describe the histological changes, estimating that about 30% of patients with epilepsy coming to autopsy had such changes (Sommer, 1880). Stauder (1936) correlated this pathology with the occurrence of the complex partial seizures of temporal lobe epilepsy (TLE) (Stauder, 1936), a finding later confirmed by the temporal lobe epilepsy autopsy studies of Margerison and Corsellis (Margerison and Corsellis, 1966). Hippocampal or mesial temporal sclerosis remains the most common recognisable cause of focal seizures in adults, although developmental anomalies are now found with increasing frequency (Daumas-Duport *et al.*, 1988; Raymond *et al.*, 1994b).

Hemispherectomy is the one surgical procedure that was performed initially on children. Krynauw reported a series of 12 hemispherectomies performed on children with epilepsy and behaviour disorder associated with infantile hemiplegia (Krynauw, 1950). Short term results in this and other series (Ignelzi and Bucy, 1968; White, 1961) were excellent with seizure relief and no deterioration in cognitive function or hemiplegia, provided the pre-existing damage was confined to one cerebral hemisphere. Longterm problems became evident, however, with hydrocephalus from haemosiderosis, the result of recurrent bleeding into the resultant cavity (Falconer and Wilson, 1969; Oppenheimer and Griffith, 1966; Rasmussen, 1983 ). The procedure therefore went out of favour. Later use of modified procedures designed to avoid such problems (Beardsworth and Adams, 1988;

Rasmussen, 1983 ; Tinuper *et al.*, 1988) has led to a similar degree of relief from seizures without the apparent long-term complications.

Murray Falconer became the pioneer of epilepsy surgery within the United Kingdom. In 1966, Falconer operated on his first child with TLE, referred by Christopher Ounsted from the Park Hospital in Oxford (Taylor, 1990). He later published on the subject, referring to his wide experience, reporting on the common association of febrile convulsions and TLE (Falconer, 1971; Falconer, 1972a), and developing the term 'mesial temporal sclerosis' to include hippocampal sclerosis as well as the changes noted in other mesial temporal structures such as the amygdala (Falconer and Taylor, 1968). He also recognised that the syndrome existed in children and that earlier surgery may have prevented some of the long-term consequences of chronic epilepsy (Davidson and Falconer, 1975; Falconer, 1970; Falconer, 1972b; Falconer, 1972c; Falconer, 1972d).

A limited number of surgical series in children have been reported since this time. In contrast to adult epilepsy surgery, they have involved more extratemporal than temporal procedures, have only in a few cases been limited to one lobe and have been primarily directed by the presence of a structural lesion (Adelson *et al.*, 1992; Blume, 1989; Duchowny *et al.*, 1992; Hopkins and Klug, 1991; Otsubo *et al.*, 1995; Wyllie *et al.*, 1993). However, although a large proportion of epilepsy cases present in childhood, there remains a delay in those who are considered for resective surgery (Cross *et al.*, 1996; Wyllie *et al.*, 1988). The length of time seen in adults between presentation with their first seizure and surgery suggests that more could have been considered as children, particularly as outcome figures with regard to seizure control are similar to adult studies

(Adams *et al.*, 1990; Meyer *et al.*, 1986). Some evidence suggests that frequent seizures are not without ongoing risk to the individual. This is particularly relevant in the case of the developing brain. The Collaborative Perinatal Project of the National Institute of Neurological and Communication Disorders and Stroke (NCPD) did not demonstrate a difference in intellectual outcome between matched groups of children with and without epilepsy (Ellenberg *et al.*, 1986), and an increased prevalence of mental retardation amongst the group with epilepsy was attributed to the presence of neurological impairment prior to the onset of seizures. However, studies of selected groups of children with ongoing seizures suggest that severe epilepsy is associated with cognitive decline (Besag, 1988; Dam, 1990), and that early cessation of seizures is associated with better developmental outcome (Czochanska *et al.*, 1994). This can also be illustrated in children with congenital hemiplegia where the presence or absence of seizures is a major determining factor as to neuropsychological outcome (Vargha-Khadem *et al.*, 1992).

The long-term psychosocial consequences of difficult epilepsy are also evident, and are well illustrated by the Oxford biographical study of temporal lobe epilepsy. This followed 100 children with TLE over a 38 year period, and found that about one third (30%) of the group had long term psychosocial problems as a result of their condition and were fully dependent on others (Ounsted *et al.*, 1987). Twenty nine percent also had a history of 'rage'. Thirty two percent required special schooling and 22% had a history of hyperkinetic behaviour. Other authors (Harrison and Taylor, 1976; Ross *et al.*, 1980) have also described the impact on the community of chronic epilepsy as well as on the individual. In addition, recurrent epileptic seizures are not without danger to the individual, both with regard to self injury during a seizure and the risk of sudden death

(Nashef *et al.*, 1995). An early remission from seizures could therefore be assumed to improve the long-term consequences of epilepsy (Mizrahi *et al.*, 1990).

### ***1.5. The problem of localisation***

After establishing a rationale for early surgery, identifying candidates who may be suitable and thereafter the area of the brain responsible for seizures remains the next challenge. Epileptic seizures are a consequence of disturbed electrical function, and by definition we are therefore seeking the site of electrical origin of seizure onset. Although in an adult this may be easily apparent on surface ictal recording, in the young child interictal and ictal EEG abnormalities may be seen over a wide area, even bilaterally despite a likely focal onset (Burnstine *et al.*, 1991; Holmes, 1984; Yamamoto *et al.*, 1987). Moreover, the clinical semiology of seizures in young children may not be apparent as focal in onset in contrast to the older child and adult (Duchowny, 1987; Holmes, 1986; Wyllie, Luders, 1989). The question also has to be addressed as to how we decide what tissue it is necessary to remove?

There has also been discussion as to whether seizure foci may 'migrate' with age (Andermann and Oguni, 1990; Blume, 1990). Follow-up studies of children with epilepsy have demonstrated a predominance of occipital foci in early childhood, midtemporal foci in midchildhood, and anterior temporal spikes in teenage years (Gibbs *et al.*, 1954; Trojaborg, 1966). Although in early studies 'midtemporal' spikes probably fell within the benign rolandic group (Gibbs and Gibbs, 1960), the appearance of anterior temporal spikes in late childhood and their association with persistence of seizures appears to be a real phenomenon (Gibbs *et al.*, 1954). Although there has been some debate as to

whether such 'migration' occurs, particularly in relation to some studies where comparison was made between different groups of children, and whether the appearance of further spikes is related to secondary epileptogenesis, such a finding could be related to cortical maturation. This would be supported by recent findings with regard to changes over time in the maximal amplitude of cortical evoked potentials (N1), which is seen at temporal sites in children and frontotemporal sites in adults (Bruneau *et al.*, 1997), with further evidence that the change occurs between the ages of 11 and 15 years (S Boyd, personal communication). This leads to a number of questions: how reliable is the EEG with regard to localisation in early childhood, is all electrical disturbance detected on EEG primarily responsible for seizure onset, and does all electrical abnormality have to be removed for good post-operative outcome?

Post-operative follow-up studies have shown that good post-surgical outcome with regard to seizure control is more likely if pathology is detected within the surgical specimen (Kuzniecky *et al.*, 1993; Fish *et al.*, 1993). This implies that an underlying structural abnormality is responsible for the electrical disturbance resulting in a focal epileptic seizure. Pre-operative selection may be enhanced therefore by the detection of such pathology on neuroimaging. Prior to the availability of computerised tomography (CT), imaging of the cerebral tissue was not possible, and therefore epilepsy surgery relied totally on clinical and EEG data. Imaging of the brain using CT scanning provided information about gross pathology, but the yield of structural brain abnormality in individuals with epilepsy using this form of imaging remained low (Minford and Forsythe, 1992; Resta *et al.*, 1994), particularly of nontumoural lesions. Magnetic resonance imaging (MRI) provides a much more detailed image of the brain, clearly



demonstrating abnormalities of grey and white matter previously only detected at postmortem.

### ***1.6 Structural vs functional imaging***

Initial studies of patients with drug-resistant epilepsy using MRI revealed small tumours (Bergen *et al.*, 1989; Ormson *et al.*, 1986; Sperling *et al.*, 1986) and cortical dysplasia (Guerrini *et al.*, 1992; Palmini *et al.*, 1991a; Palmini *et al.*, 1991b) not previously detected using CT. The hippocampal region in particular was of obvious interest, particularly in adults with TLE, as hippocampal sclerosis (HS) is the most common cause of surgically remediable temporal lobe epilepsy. Standard imaging techniques continued to fail in finding abnormalities of this area pre-operatively, but optimised magnetic resonance imaging was subsequently shown to detect HS with a high degree of reliability (Jackson *et al.*, 1990).

Following the increasing evidence that abnormalities could be detected on MRI in a high proportion of adults with intractable focal epilepsy, a series of studies have reviewed the incidence of abnormalities detectable in children (Grattan Smith *et al.*, 1993; Kuzniecky *et al.*, 1993). As a prelude to further study, the MRI scans of thirty children presenting to a tertiary referral centre with medically resistant focal epilepsy were reviewed retrospectively (Cross *et al.*, 1993). Abnormalities on MRI were found in all children; furthermore hippocampal and/or additional temporal lobe abnormalities were found in all those with a clinical diagnosis of temporal lobe epilepsy and in 86% of those where the focus could not be determined on clinical data. No child with a clear diagnosis of extratemporal epilepsy had abnormalities of the temporal lobe. This and subsequent

studies (Grattan Smith *et al.*, 1993; Kuzniecky *et al.*, 1993) imply a high incidence of focal brain abnormality as detected by MRI in children with drug-resistant focal epilepsy, and therefore suggest that a high number may be considered for surgical management.

There continues to be discussion as to the relevance of the hippocampus in childhood epilepsy and whether hippocampal sclerosis is an acquired lesion (Harvey *et al.*, 1995; Holthausen, 1994; Kuks *et al.*, 1993; Liu *et al.*, 1995; Mathern *et al.*, 1995c). Previous surgical series in childhood TLE have indicated a relatively high incidence of tumour, and a low incidence of hippocampal sclerosis as the underlying responsible pathology, but data from our own institution (Cross *et al.*, 1993), and more recently from others (Grattan Smith *et al.*, 1993) indicate that hippocampal sclerosis is equally common in children as in adults and that it can be detected on MRI.

Although abnormalities of the hippocampal region can now be reliably detected visually using optimised MRI sequences, quantitative techniques for determining hippocampal pathology have been advocated in adult epilepsy. Volumetric analysis of the hippocampus has shown good correlation between hippocampal atrophy and pathologically proven hippocampal sclerosis (Cendes *et al.*, 1993b; Cook *et al.*, 1992; Jack, Jr. *et al.*, 1990; Lencz *et al.*, 1992). This is an apparently reliable measure and requires a short time for data acquisition, but volume measurements are subjective and depend on a high degree of expertise. T2 relaxometry (see Chapter 4) is more limited in the information provided if it is performed in a single plane, but is less dependent on the degree of expertise necessary to extract information from the resulting images. Adult series have identified

abnormalities with respect to a normal range, and hippocampal sclerosis has been demonstrated to be associated with high T2 values (Jackson *et al.*, 1993b).

Proton magnetic resonance spectroscopy ( $^1\text{H}$  MRS) (see Chapter 5) can assess neuronal damage by the detection of N-acetylaspartate (NAA), a compound located primarily in neurons (Koller *et al.*, 1984; Urenjak *et al.*, 1993). Single voxel techniques centred on the mesial temporal lobes have demonstrated abnormalities in the signal intensity ratio NAA/(Cho+Cr) (Cho = choline-containing compounds, Cr = creatine + phosphocreatine) in adults with epilepsy. In patients with TLE, it has been shown not only to aid in lateralisation, but also to identify a relatively high incidence of bilateral abnormalities (Connelly *et al.*, 1994; Gadian *et al.*, 1994). The hippocampus occupied only a small proportion of the relatively large regions of interest (8ml) used in these single voxel  $^1\text{H}$  MRS studies, with the majority of the voxel containing temporal white matter. The information provided therefore may be complementary to that available from imaging techniques, since it reflects changes at a cellular level over a relatively diffuse region which are not necessarily visualised at a structural level.

On returning to the question of what is the area that needs to be removed, demonstration of a structural abnormality may be helpful, but this still needs to be related to the epileptogenic region. Epileptic seizures arise as the result of disorganised brain function. How can we relate brain structure, as determined by the techniques described above, to brain function, both during and between seizures, and how can we be confident that such seizures are arising from the region of structural or biochemical abnormality detected?

Furthermore, what is the relevance of defining an area of electrical abnormality in relation to such structural abnormalities?

In studies observing the cerebral cortex during intraoperative stimulation, Penfield reported focal hyperaemia at the site of seizure onset during seizures (Penfield *et al.*, 1939). Single photon emission computed tomography (SPECT) provides a means of mapping cerebral perfusion following injection of a radiolabelled ligand. This technique has proved to be a useful tool in the investigation of focal epilepsy; focal hyperperfusion concordant with the seizure focus has been demonstrated to be predictive of the seizure focus in 95-99% of individuals injected during a seizure (Berkovic *et al.*, 1993; Newton *et al.*, 1992a; Newton *et al.*, 1992b). Although temporal lobe epilepsy in adults remains well explored, there is limited information on children, particularly those with extratemporal epilepsy. The minimally invasive nature of SPECT makes it an attractive option in the pre-operative evaluation of children with intractable focal epilepsy. The paediatric group is heterogeneous, and the extratemporal group, which is thought to be larger than the temporal lobe group in children coming to investigation for surgery, poses particular questions. Are characteristic patterns of cerebral perfusion seen in children with intractable focal epilepsy, and are these patterns similar to those in adults? This question is particularly important in view of the range of developmental pathologies responsible for intractable epilepsy of childhood. The roles of interictal and ictal SPECT in the localisation of the seizure focus are discussed in Chapter 6, and specific patterns of ictal rCBF in Chapter 7.

## 1.5 Aims of this study

The aims of this study were to define the roles of neuroimaging techniques in the presurgical evaluation of children with epilepsy, and in particular to address the following questions.

*Does magnetic resonance imaging detect focal brain abnormalities in children with intractable focal epilepsy?*

Post-surgical outcome in epilepsy surgery is optimal if pathology is found in the surgical specimen. Detailed neuroimaging could enable such pathology to be detected pre-operatively, and hence aid in the selection of possible surgical candidates. Chapter 3 evaluates the incidence of structural brain abnormalities as determined by magnetic resonance imaging in children presenting with drug-resistant focal epilepsy, and reports the findings.

*Do the additional quantitative techniques of T2 relaxometry and  $^1\text{H}$  MRS aid in lateralisation of brain abnormalities in children with temporal lobe epilepsy?*

T2 relaxometry of the hippocampus and  $^1\text{H}$  MRS of the temporal lobe have been reported to aid in the lateralisation of brain abnormality in adults with temporal lobe epilepsy. The use of these techniques to aid lateralisation of brain abnormalities in children with temporal lobe epilepsy is described in Chapters 4 and 5.

*Can ictal functional brain studies in the form of  $^{99}\text{Tc}^m$  HMPAO SPECT be performed as a 'routine' procedure in children?*

Single photon emission computed tomography, particularly when used ictally, has been advocated as a useful tool in the detection of the seizure focus in adults, and in a selected group of children. This study set out to determine whether the technique could be achieved in routine clinical practice, and the results of this are described in Chapter 6.

*Do ictal and interictal  $^{99}\text{Tc}^m$  HMPAO SPECT studies aid in localisation of the seizure focus in children with intractable focal epilepsy?*

The high predictive yield of ictal SPECT studies reported in adults and children would make this an extremely attractive technique in presurgical evaluation. This study set out to verify the reliability of ictal and interictal studies in a consecutive group of children with drug resistant focal epilepsy presenting for presurgical evaluation. The results are given in Chapters 7 and 8.

*What relative value does each of the above investigations currently have in the presurgical evaluation of the child with intractable focal epilepsy?*

In practice, presurgical evaluation remains multidisciplinary, with the understanding that each investigation reveals different information about the area apparently responsible for seizure onset. The thesis concludes by reviewing the relative localising potential of each of the investigations in question. Although the primary aims of the study are to determine the value of the investigations in presurgical evaluation, the results also provide further information about the underlying pathophysiology of the disorder.

## CHAPTER 2

### CLINICAL AND ELECTROENCEPHALOGRAPHIC LOCALISATION OF THE 'SEIZURE FOCUS'

---

#### Contents

- 2.1 *Introduction*
  - 2.2 *The problem of seizure localisation*
  - 2.3 *The problem of seizure detection*
  - 2.4 *Patient population*
  - 2.5 *Clinical localisation*
    - 2.5.1 *Methods*
    - 2.5.2 *Results*
  - 2.6 *EEG localisation*
    - 2.6.1 *Methods*
    - 2.6.2 *Results*
  - 2.7 *Clinical and EEG localisation*
  - 2.8 *Clinical features of the patient population*
  - 2.9 *Discussion*
- 

#### 2.1 *Introduction*

For the purpose of resective epilepsy surgery, it is necessary to define the region that needs to be removed for the desired outcome of relief from seizures. The obvious approach is to define this as the region from where the seizures arise. Such a definition presumes a knowledge of the electrical focus, as an epileptic seizure arises as the result of a change in electrical activity within the brain. In the presence of multiple areas of electrical abnormality, are all of these areas responsible or indeed capable of producing seizures in isolation? Data from invasive subdural recordings imply that this is unlikely to be the case (Wyllie *et al.*, 1987). Here we can consider the concept of the epileptogenic zone vs the epileptic focus. Some writers differentiate between these terms. Engel defines

the area from which the seizure arises as the epileptic focus, as opposed to the epileptogenic zone, which is the surrounding area which may have the potential to give rise to seizures although not having a role in the generation of habitual seizures; the epileptogenic region encompasses both the epileptic focus and the epileptogenic zone (Engel, Jr., 1990a). Other authors have proposed from animal studies that each focus may be surrounded by an area of functionally abnormal tissue that may be receiving a powerful inhibitory drive ('surround inhibition') (Prince and Wilder, 1967). However, how do regions of electrical abnormality relate to regions of structural abnormality? The evidence from early surgery in the presence of widespread EEG disturbance in infants with infantile spasms suggests that the concept of the 'epileptogenic zone', that is, the search for localised electrical abnormality may have little relevance in the immature brain (Chugani *et al.*, 1993; Shields *et al.*, 1992).

On testing the reliability of different modalities for the detection of regions of brain abnormality and the degree to which they are responsible for epileptic seizures, one presumes a fixed reference point or 'gold standard' to which one can refer. In epilepsy surgery, the only true gold standard should be outcome with regard to seizure control and complete abolition of seizures. For a study such as the one to be discussed, ultimately a decision is made on multidisciplinary discussion of all modalities under test. Although the power of clinical semiology and scalp EEG in the young child has been felt to be unreliable (Burnstine *et al.*, 1991; Holmes, 1984; Yamamoto *et al.*, 1987) (see Section 1.5), the point from which I start must be with these tools. From there, the correlation with techniques in magnetic resonance and nuclear medicine, and the power of such modalities to determine the area that could be removed, or indeed investigated further, can



be tested. Ultimately, the full test of comparison is that with postsurgical outcome and this will be discussed in Chapter 9.

## ***2.2 The problem of seizure localisation***

In clinical practice, a diagnosis of epilepsy and seizure type is made predominantly on a description of attacks. Depending on certain clinical features of such attacks, suspicion may arise as to whether the seizures are focal or generalised in their electrical origin.

Clinical semiology with regard to seizure origin has been well documented in adults, and specific characteristics of temporal (Gabr *et al.*, 1989; Quesney, 1986), frontal

(Williamson *et al.*, 1985; Williamson and Spencer, 1986), parietal (Salanova *et al.*, 1995;

Williamson *et al.*, 1992) and occipital lobe epilepsy (Williamson *et al.*, 1992) are listed

within the literature. There is little documentation, however, as to the seizure semiology

in children and whether the characteristics seen in adults are applicable. Where

documented, seizures either involve predominantly motor features (Blume, 1989), or the

studies involve the very young child (Duchowny, 1987; Wyllie *et al.*, 1996). Studies in

young children suggest that complex partial seizures often start as a motionless stare or

'behavioural arrest', whereas an 'aura' becomes more common with age (Holmes, 1986;

Duchowny, 1987; Blume, 1989; Wyllie *et al.*, 1993). Automatisms are seen but in the

infant are less complex; sucking or lip smacking are seen rather than complex gestural

movements (Jayakar and Duchowny, 1990; Wyllie and Luders, 1989). It is also evident

that apparently nonfocal manifestations may occur despite focal onset (Holmes, 1986).

The electroencephalogram (EEG) provides a means for recording electrical activity

although it has relative limitations with regard to spatial resolution. An EEG taken in

between seizures may be helpful in a child with focal epilepsy if an abnormality, particularly a focal abnormality, is demonstrated. However, it may well be normal or multifocal abnormalities may be seen (Blume, 1989; Holmes, 1984). This need not preclude evaluation for surgery. The definitive investigation is an EEG performed during an event; an ictal recording. Seizures occur within the clinical setting or during routine EEG only rarely by chance. Certain activation procedures such as hyperventilation (Miley, Forster, 1977) or sleep (Sammaritano *et al.*, 1991) may induce abnormalities or even seizures. However, we cannot rely on such procedures, and in order to document seizures long term monitoring with video-EEG telemetry is required, to confirm clinical features and determine any evidence of electrical localisation.

### ***2.3 The problem of seizure detection***

With a limitation on resources, there is increasing pressure to monitor patients with video-EEG telemetry for as short a period of time as possible. It is not clear how many seizures are required to be confident of the electrical region responsible for seizure onset, although statistical analysis suggests that ideally this should be a greater number than is generally practicable (Van Ness *et al.*, 1990). Furthermore, it is desirable to minimise hospital admission within a restricted environment, particularly in children. Seizures are unpredictable in their occurrence, and therefore it would be practical to try and manipulate seizure frequency in some way. Abrupt withdrawal of anticonvulsants could be considered as one way of precipitating seizures. Studies investigating this have predominantly involved adults (Bromfield *et al.*, 1989; Duncan *et al.*, 1990; Marciani *et al.*, 1985; Marciani and Gotman 1986; Marks *et al.*, 1991; Spencer *et al.*, 1981). Such studies have involved a limited number of anticonvulsant medications (namely phenytoin

and carbamazepine) and not the newer anticonvulsants such as vigabatrin and lamotrigine. They have shown, however, that seizures are likely to occur when anticonvulsant levels fall to subtherapeutic levels (Bromfield *et al.*, 1989; Marciani *et al.*, 1985; Marks *et al.*, 1991). The majority of such seizures documented were the habitual partial seizures (Marciani and Gotman, 1986; Marks *et al.*, 1991; Spencer *et al.*, 1981). However, they could be prolonged, and there was an increased incidence of secondary generalisation during the drug withdrawal period (Marciani *et al.*, 1985; Marciani, Gotman, 1986). Review of the EEG data suggests that drug withdrawal does not alter the morphology of EEG changes (So and Gotman, 1990), and where a second focus is documented it usually indicates multifocal disease (Spencer *et al.*, 1981) as determined by postsurgical outcome.

It is difficult to transpose adult data directly to children. However, these adult data suggest that abrupt withdrawal of anticonvulsants in a controlled setting may be a means of provoking seizure occurrence in children for presurgical evaluation.

In the following sections of this chapter, a description is given of the patient population that formed the basis of the studies described in this thesis, and the results of clinical and EEG localisation in these patients are presented.

#### **2.4 Patient population**

The children entered into this study were a group referred to a tertiary referral centre for investigation and management of drug-resistant epilepsy, with a view to possible surgery. A total of 75 children were investigated; they were of mean age nine years five months

(range 10 months to 17 years 10 months). All 75 had been tried on at least two anticonvulsant medications; all had full clinical evaluation, interictal EEG and magnetic resonance imaging as preliminary investigation. A subgroup had more detailed magnetic resonance investigation; 55 had T2 relaxometry of the hippocampi and 29 underwent <sup>1</sup>H MRS of the mesial temporal lobes. Sixty three children also underwent interictal SPECT examination and 51 ictal SPECT, with video-EEG telemetry in 49.

In the majority, evaluation was performed with a view to epilepsy surgery, with a clinical suggestion of focal epilepsy (whether from seizure semiology or clinical examination) at the outset. In three children evaluation was pursued in the absence of clinical features but on the basis of a structural lesion on MRI. A total of 47 children have undergone surgery (30 temporal lobectomy, 15 hemispherectomy and two extratemporal resection). A further two children have been offered surgery but have declined.

## ***2.5 Clinical localisation***

### ***2.5.1 Methods***

All children underwent full clinical evaluation for history of seizure disorder and seizure semiology. In 49 children, the description could be compared with video documentation of the seizures from video EEG telemetry. Clinical localisation to the temporal lobe was accepted if there was any one of the following: behavioural arrest, oro-alimentary automatisms (Jayakar and Duchowny, 1990), stereotyped complex automatisms with postictal confusion, psychic aura such as fear or *deja vu*, an aura of a formed auditory or visual hallucination, a distinct epigastric aura, speech impairment prior to or immediately following the seizure, or non-specific aura or automatisms followed by confusion post-

ictally (Duchowny *et al.*, 1994; French *et al.*, 1993). Localisation to the frontal lobe was considered if seizures were brief, there was rapid onset or offset to the seizure, a nocturnal bias, a prepondancy to clusters, bizarre behaviour, or vocalisation (Jayakar *et al.*, 1992; Stores *et al.*, 1991; Williamson, Spencer, 1986). An occipital origin was suggested if there were elemental visual hallucinations, contralateral eye deviation or ictal blindness (Williamson and Spencer, 1986). Lateralisation was based on lateralised motor phenomena (eg limb jerking or dystonia) or lack of speech disturbance during or speech disturbance immediately following the seizure (Gabr *et al.*, 1989).

### ***2.5.2 Results***

Of the 75 children involved in this study, 65 could be localised on the basis of clinical seizure semiology. Thirty six children were thought to have a temporal lobe onset. Sixteen children had evidence of a hemiplegia on examination, and were thought to have seizures arising from the abnormal hemisphere. Clinically, 16 children had an extratemporal onset to their seizures; in 13 it was thought likely to be a frontal onset. Six children were felt to have seizures of focal origin which could not be localised on clinical evidence alone.

#### ***i. Temporal lobe epilepsy.***

A summary of the seizure patterns of the 36 patients included in this group is given in Table 2.1. In all children, the beginning of all seizures was consistently reported as the same; it was taken therefore that all had a single seizure type with evidence of secondary spread forming a second seizure type in 12 of the children.

Twenty three children had evidence of an aura; this could be described by the child in 16 cases. Headache or dizziness as the preceding event was described by six children (associated with a complex visual aura in one). Epigastric discomfort was described in five and a profound feeling of fear was apparent in three. In two children there was evidence of an olfactory aura, with complaints of abnormal smell in one and 'funny nose' in another.

In the remaining seven children, there was evidence of a warning to the seizure but the child was unable to describe its nature. In five, this was made apparent by their putting themselves in safety, either by sitting down or by seeking the attention of an adult immediately prior to any seizure. Two appeared fearful immediately before the clinically obvious phase.

Twenty-two children had complex automatisms associated with the seizure; these were either oromotor (lip smacking, swallowing) (nine patients), gestural (hand movements, finger picking, finger observation) (six patients) or both (seven patients). Eighteen children had behavioural arrest or psychoparesis as a prominent feature to the seizure; in nine this was the first feature and was not preceded by an aura. Colour change was described in six children. Four were described as having a look of fear during the seizure. Vomiting was a feature in two children and nausea in one. Ictal confusion was reported in two children and postictal confusion in one.

**Table 2.1****Clinical features of seizures in children classified as having temporal lobe epilepsy**

<b>Clinical features</b>	<b>Number of children</b>
<b>Aura</b>	<b>23</b>
<i>Headache/dizziness</i>	6
<i>Abdominal</i>	5
<i>Olfactory</i>	2
<i>Fear</i>	3
<i>Other</i>	7
<b>Behavioural arrest</b>	<b>10</b>
<b>Stare</b>	<b>7</b>
<b>Automatisms</b>	
<i>Gestural</i>	13
<i>Oromotor</i>	16
<b>Lateralising motor features</b>	<b>15</b>
<i>Dystonic posturing</i>	8
<i>Focal motor</i>	4
<i>Head deviation</i>	3
<b>Language</b>	
<i>Ictal</i> <i>Nonidentifiable</i>	7
<i>Arrest</i>	4
<i>Dysarthria</i>	3
<i>Postictal</i> <i>Dysphasia</i>	2
<b>Confusion</b>	
<i>Ictal</i>	1
<i>Postictal</i>	1
<b>Colour change</b>	<b>5</b>
<b>Fear</b>	<b>4</b>
<b>Vomiting/nausea</b>	<b>3</b>

Lateralising motor features were reported in 15 children. Dystonic posturing of one arm was seen in eight, focal motor jerking in four and head deviation in three (with dystonic posturing and head deviation in two). Abnormalities in speech were a feature in 16 children; abnormal speech during the seizure was reported in 10 (nonidentifiable speech

in seven and dysarthria in three) and speech arrest in four. Two children had postictal dysphasia. On the basis of the features described, seizures could be lateralised in 16 of the 36 children clinically allocated as temporal lobe epilepsy. This was predominantly on the basis of lateralised motor phenomena (N=15). Seizures were thought to arise from the left temporal lobe in 12 cases and from the right temporal lobe in four.

## *ii. Extratemporal epilepsy*

Sixteen children had clinical seizure semiology consistent with an extratemporal origin. These were suggestive of a frontal origin in 13; clinical localisation could not be taken further in the remaining three children. All had a single seizure type, and three had a tendency to secondary generalisation.

The key features seen within the seizures of the children in this group are summarised in Table 2.2. Of the 13 thought to have a frontal origin, five had bizarre behaviour as part of the seizure pattern, with vocalisation in four (including recognisable speech in one). Four of the 13 children had seizures that were predominantly nocturnal, two had seizures of short duration and two tended to have clusters of seizures. Only two of the group had an aura; one had a gustatory aura with a bad taste in her mouth and rapidly proceeded to bizarre behaviour that could be aggressive. The other child had a history of prolonged periods of agitation preceding a seizure, which was then described as a short lived (5 second) asymmetric tonic neck reflex posture. The latter was witnessed during telemetry and was suggestive of a supplementary motor area seizure.



Motor features suggesting lateralisation were reported in nine children of the whole extratemporal group; epilepsy partialis continua was a feature in two of these and in one there was a progressive monoparesis of one arm during seizure exacerbation that resolved on treatment.

**Table 2.2**

**Clinical features of seizures in children classified as having extratemporal epilepsy**

	<b>Number of children</b>
<b>Stare</b>	<b>3</b>
<b>Short (&lt;30s)</b>	<b>2</b>
<b>Cluster</b>	<b>2</b>
<b>Nocturnal</b>	<b>3</b>
<b>Aura</b>	<b>1</b>
<b>Motor</b>	<b>7</b>
<i>EPC</i>	<b>2</b>
<i>Head deviation</i>	<b>1</b>
<b>Abnormal behaviour</b>	<b>2</b>
<b>Speech arrest</b>	<b>1</b>
<b>Vocalisation</b>	<b>3 (inc normal speech in one)</b>
<b>2° generalisation</b>	<b>4</b>

**iii. Hemisyndromes**

Sixteen children had clinical evidence of a longstanding or progressive hemiparesis which affected the right side of the body in 10. This group had a tendency to multiple seizure types; nine had a single seizure types ( including four with secondary spread), five had two seizure types and four had three seizure types. Thirteen children had a focal motor component to their seizures involving the hemiparetic side; this was focal motor jerking

in nine (epilepsia partialis continua in two) and dystonic posturing in four. Other seizure types included absence episodes (six patients), asymmetric tonic seizures (three patients), drop attacks (two patients) and startle seizures (two patients).

#### *iv. Unlocalised*

In seven of the children, a clinical description of the seizures did not suggest a focal origin to the seizures; in five the seizures were also reviewed on video after video-EEG telemetry. Four had a history of two seizure types, although in all cases the second seizure type appeared to be a prolongation of the first, probable focal seizure; two had a single seizure type and one three seizure types.

During the seizures, five children had associated psychoparesis, six had motor features (dystonic posturing 3, head deviation 2, facial asymmetry 1) and three eyelid flickering. One had a regular history of secondary generalisation.

## **2.6 EEG localisation**

### **2.6.1 Methods**

Interictal EEG was performed on 73 of the 75 children within the study by 8 or 16 channel recording on a Grass EEG machine as previously described (Pampiglione, 1977).

In two children with EPC, an interictal recording could not be obtained. A total of 54 children underwent ictal EEG recordings. This was during video EEG telemetry in 47 and by chance during the conventional recording in seven.

For the purpose of video-EEG telemetry, the children were admitted two days prior to the planned investigation. Seizure frequency was reviewed and if the frequency was less frequent than one seizure every three days, medication was halved or withdrawn. The timing of withdrawal was related to the half-life of the medication; drugs with a longer half-life (eg carbamazepine, sodium valproate, lamotrigine, phenytoin) were discontinued on admission, whereas drugs with a shorter half-life (vigabatrin, gabapentin) were withdrawn the day prior to the investigation. No medication was withdrawn prior to admission to hospital. In the majority of cases, video-EEG telemetry was commenced on day three of admission to coincide with the day of the ictal SPECT examination (see Chapter 7); in children prone to nocturnal seizures, overnight EEG telemetry was performed and the child was sleep-deprived in order to induce sleep the following day. If no seizure was recorded on the day of investigation, medication was not reintroduced and EEG telemetry was continued for a further two days.

Time locked video/digital EEG recording ('telemetry') was carried out at the bedside using, initially, a 16-channel Grass EEG machine linked to a video tape system developed in-house (Lester, 1993) (18 patients) and latterly, a 32-channel cable system connected through an A/D card to a PC for display and storage of the signals (Stellate Systems Ltd, 29 patients). Remontaging was carried out off-line in the latter group. Videos were reviewed for seizure semiology and checked for agreement with the regular seizure type with a reliable witness, usually a parent.

All EEG's were reviewed for normal rhythms for the age of the child, with documentation of any abnormal rhythms including slow and rhythmic activity, as well as the presence or

absence of spikes and spike wave activity, with particular emphasis on any evidence of lateralisation and localisation.

### **2.6.2 Results**

*i. Interictal* Of the 73 interictal EEG recordings that were available for review, 63 were abnormal and 10 were normal. Interictal recordings were not available in two children with EPC. Of the 62 children who had an abnormal EEG, the abnormalities were lateralised in 45. In 25 (34%) of the children, they were also localising whereas in 20 (27%) there were only lateralising features (including 10 in children with hemisyndromes). There were no localising or lateralising features on the EEG of 14 children. Four children had localising features that were seen on both sides (three temporal and one temporoparietal).

*ii. Ictal* For the purpose of video-EEG telemetry, 27 of 46 children had medication reduced or withdrawn (see Table 2.3). Seven children required video telemetry with withdrawal of medication on two occasions in order to document at least one seizure. One further child required withdrawal of medication on three occasions. In five children there was atypical secondary generalisation of a habitual complex partial seizure, and in one child there was a prolonged seizure, requiring intravenous diazepam. In all six patients diazepam was given with good effect. Status epilepticus was not induced on any occasion. Six children had seizures induced by hyperventilation (five temporal lobe seizures and one extratemporal). Only one seizure was recorded in view of limited availability of EEG telemetry and subsequent requirements for the ictal SPECT (see Chapter 6).

**Table 2.3 Details of the medications withdrawn**

	Number of children
<b>Carbamazepine</b>	<b>16</b>
<b>Phenytoin</b>	<b>6</b>
<b>Lamotrigine</b>	<b>6</b>
<b>Vigabatrin</b>	<b>7</b>
<b>Other</b>	<b>11</b>
<i>Gabapentin</i>	2
<i>Sodium valproate</i>	2
<i>Clobazam</i>	3
<i>Acetazolamide</i>	2
<i>Ethosuximide</i>	1
<i>Clonazepam</i>	1

**Table 2.4. Interictal and ictal EEG localisation in the 75 children within the study**

EEG	Number of children	
	Interictal (N=73)	Ictal (N=54)
<b>Localising and lateralising</b>	<b>25</b>	<b>25</b>
<i>Temporal</i>	20	18
<i>Extratemporal</i>	3	4
<i>Hemisyndromes</i>	2	3
<b>Localising not lateralising</b>	<b>4</b>	<b>1</b>
<i>Temporal</i>	3	1
<i>Extratemporal</i>	1	0
<i>Hemisyndromes</i>	0	0
<b>Lateralising not localising</b>	<b>20</b>	<b>14</b>
<i>Hemisyndromes</i>	10	6
<b>Unlocalised</b>	<b>14</b>	<b>4</b>
<b>Normal</b>	<b>10</b>	<b>1</b>
<b>Uninterpretable</b>	<b>0</b>	<b>9</b>
<i>Temporal</i>	0	1
<i>Extratemporal</i>	0	4
<i>Hemisyndromes</i>	0	3
<i>Unlocalised</i>	0	1

Ictal EEG recordings were technically satisfactory in 45 of the 54 children where a recording was obtained (Table 2.4). Of the nine that were not satisfactory, four were in children with probable extratemporal epilepsy, three in hemisindrome, and one each in temporal and unlocalised epilepsy. Of the 45 where there was a satisfactory recording, the EEG was localising in 26 (58%) children, and also lateralising in 25 (56%). In a further 14 children the ictal EEG was lateralising but not localising. Four children had no localising features to their ictal EEG. In one child with EPC, the surface EEG recording was repeatedly normal.

### ***2.7 Clinical and EEG localisation***

The seizure focus thought to be responsible for the seizures in this group of 75 children could be localised on the basis of clinical and EEG evidence in 72 cases. Forty children had seizures localised to the temporal region; in 34 this could also be lateralised (24 left and 10 right). Sixteen children had clinical and/or EEG evidence of an extratemporal focus; in 14 this could be lateralised. In 13 children the seizures were of frontal origin, in one parietal and in one temporoparietal. Sixteen children had seizures as part of their hemiplegic syndrome, and in all cases the seizures could be lateralised on the basis of clinical and/or EEG data. Only three children had seizures suggestive of a focal origin that could not be localised on the basis of clinical and/or EEG evidence.

---

**Table 2.5 Overall clinical and EEG localisation in the 75 children**

<b>Temporal</b>	<b>40</b>	<i>lateralised</i>	<i>34</i>
<b>Extratemporal</b>	<b>16</b>	<i>frontal</i>	<i>13</i>
		<i>lateralised</i>	<i>14</i>
<b>Hemisyndromes</b>	<b>16</b>		
<b>Unlocalised</b>	<b>3</b>		

## ***2.8 Clinical features of the patient population***

### ***2.8.1 Temporal***

There were a total of 40 children allocated to this group on the basis of clinical and EEG data as described in Section 2.6; 24 with left temporal lobe epilepsy (TLE), 10 with right TLE and six with unlocalised TLE. They were of age range 10 months to 17 years 9 months (mean 10 years 4 months). Fifteen had a history of an early febrile convulsion; in 12 this was prolonged (>30 minutes). A further seven children had a history of status epilepticus. The mean age of the first afebrile seizure in this group was 3 years 9 months (range 4 months to 12 years 6 months). Thirty six children had normal early development (in the first two years of life); of the remaining four, three had a history of language delay and one had global delay at 12 months. Thirty two had neuropsychological testing at the time of assessment; performance IQ was in the range 50-133 (mean 91) and verbal IQ 50-118 (mean 83). Eight had a developmental age inappropriate for testing (chronological age range 13 months to 10 years 11 months), but all were delayed. Twelve children had a documented behaviour disorder.

### ***2.8.2 Extratemporal***

A total of 16 children were allocated to this group as outlined in Section 2.6; 13 had frontal lobe epilepsy (nine right and four left). The age range of children with extratemporal epilepsy was 1 year 3 months to 15 years 6 months (mean 10 years 3 months). The mean age of onset of afebrile seizures was 4 years 2 months (range 6 months to 12 years 4 months). No child in this group had a history of an early febrile convulsion; five had a history of status epilepticus (two with frontal lobe epilepsy). Twelve had neuropsychological testing; performance IQ was in the range 57-105 (mean 75) and verbal IQ 50-90 (mean 82). Three children were not at a developmental age appropriate for testing, two of whom (with unlocalised extratemporal epilepsy) were delayed.

### ***2.8.3 Hemisindrome***

There were 16 children in this group as described in Section 2.6, 10 with a right hemiplegia and six with a left hemiplegia. The age range of the children in this group was 5 months to 13 years 11 months (mean 7 years 6 months). One had a history of an early febrile convulsion at age nine months; this lasted 20 minutes. The hemiplegia was noted prior to that time. The mean age of onset of afebrile seizures was 2 years 2 months (range 1 month to 8 years). Seven had neuropsychological testing; they had a mean performance IQ of 57 (range 45-77) and a mean verbal IQ of 65 (range 46-96). Of the remaining eight children, seven were developmentally delayed and one too young for full neuropsychological assessment. Of the seven that were delayed, five were in the severe range and two moderate.



#### **2.8.4 Unlocalised**

Three children (4%) could not be localised on the basis of clinical or EEG findings. The children were aged 4-6 years at the time of assessment. All children had had early onset of epilepsy (ages 5 weeks, 6 months and 11 months) and had severe cognitive delay, with a profound communication disorder.

#### **2.9 Discussion**

The purpose of this part of the thesis has been to outline the patient population under study, and to describe the use of clinical and electrophysiological data for the localisation of seizure onset. A clinical suspicion of focal epilepsy was by definition the primary inclusion criterion for entry into this study. This would inevitably have led to a highly selected population and probably accounts for the relatively high number of cases that could apparently be localised on the basis of clinical semiology and EEG (72 of 75 children). Concern about clinical semiology in young children has primarily been in children under two years (Duchowny, 1987; Wyllie *et al.*, 1996); only three children in this study were under this age and only 13 were under five years.

The high rate of localisation/lateralisation could also be viewed as the result of a combined clinical and EEG assessment. Previous EEG studies suggest lower figures, particularly in extratemporal epilepsy (Quesney *et al.*, 1993; Spencer *et al.*, 1985; Swartz *et al.*, 1991). If EEG localisation is reviewed alone within our study, localisation and lateralisation was achieved in 34% of interictal studies and 46% of ictal studies, the majority of which are within the temporal group with only a small number seen within the extratemporal group. This is comparable with the above studies (Quesney *et al.*, 1993;

Spencer *et al.*, 1985; Swartz *et al.*, 1991) all of which have also shown ictal and interictal EEG to be more useful in temporal rather than extratemporal lobe epilepsy.

A high proportion of children within the hemisindrome group within this study had EEG abnormalities that were lateralising rather than localising. This would be expected in a group where the majority have major dysfunction of one hemisphere. Even in the presence of a localising/lobar abnormality, in the presence of a dense hemiplegia the operation of choice remains hemispherectomy (or equivalent) in view of the poorer outcome from subtotal procedures (Rasmussen, 1983a).

Obtaining an ictal EEG in the young active child is not without its difficulties. This can be seen from the 10 EEG recordings that were not available for use in view of movement artifact or electrode displacement. Review of the results shows that the majority were within the extratemporal and hemisindrome group, where seizures could be assumed to involve more in the way of movement than temporal lobe seizures.

Twenty-seven children in this study underwent drug reduction and/or withdrawal in an attempt to provoke seizures. This resulted in an apparent habitual seizure in all 27, with atypical secondary generalisation in five, a prolonged seizure in one and no episodes of status epilepticus. This would suggest that drug withdrawal is safe and reliable within a hospital setting, as previously detailed in adults (Bromfield *et al.*, 1989; Duncan *et al.*, 1990; Marciani *et al.*, 1985; Marciani and Gotman, 1986; Marks *et al.*, 1991; Spencer *et al.*, 1981). To ensure that the seizure recorded was a habitual seizure, we relied on viewing of the video by a reliable witness, usually a parent. There remains the possibility

of false localisation, but from adult data the possibility of this is likely to be small in the absence of multifocal disease.

It is difficult to assess the reliability of the clinical/EEG localisation that has been performed here, particularly as in some children we had to rely on seizure description and interictal EEG. The only test as to whether assumptions made about seizure localisation are correct would be assessment of postsurgical outcome following full assessment. Not all children within this study proceeded to surgery, but the overall purpose of the study was to assess the role of neuroimaging techniques in determining techniques concordant abnormalities and their relative power in decision making. The clinical/EEG tools described in this chapter are consequently used as a starting point.

# CHAPTER 3

## MAGNETIC RESONANCE IMAGING

---

### Contents

- 3.1 *Pathological substrates in epilepsy*
    - 3.1.1 *Cortical development and implications of its disruption*
    - 3.1.2 *Tumours*
    - 3.1.3 *The hippocampus and its role in epilepsy*
    - 3.1.4 *Progressive disorders*
    - 3.1.5 *Ischaemic lesions*
  - 3.2 *Magnetic resonance imaging in epilepsy*
  - 3.3 *Methods*
  - 3.4 *Results*
    - 3.4.1 *Temporal lobe epilepsy*
    - 3.4.2 *Extratemporal epilepsy*
    - 3.4.3 *Hemisyndromes*
    - 3.4.4 *Unlocalised epilepsy*
  - 3.5 *Discussion*
- 

### 3.1 Pathological substrates in epilepsy

‘Symptomatic localisation related epilepsy’ (see Classification of the Epilepsies, Table 1.2) is by definition assumed to arise as a result of a structural abnormality of the brain.

This is supported by postoperative data showing that seizure outcome following epilepsy surgery is improved if pathology is detected in the surgical specimen (Kuzniecky *et al.*,

1983; Fish *et al.*, 1993). The pathology responsible for seizures has been determined

from both surgical series and postmortem studies. Traditionally imaging has not provided

information of sufficient detail preoperatively. However, more recently, detailed

information about the underlying pathology has become available preoperatively with

magnetic resonance imaging.

There is no pathology that is common to all patients with focal epilepsy, and although some overlap may be seen, there is a difference in emphasis on the relevance of certain pathologies in temporal as opposed to extratemporal epilepsy, and focal as opposed to hemiepilepsy. Cortical malformations are seen as a significant cause of all types of focal and generalised symptomatic epilepsy, depending on the extent of the abnormality. In the following sections, a discussion is given of the major types of pathology that are associated with epilepsy.

### ***3.1.1. Cortical development and implications of its disruption***

The major stages of central nervous system development are summarised in Table 3.1. During the course of brain development, neurons migrate from the subependymal layer of the walls of the lateral ventricles to their final destination of cortical layers within the cerebral cortex (Caviness *et al.*, 1995). The neurons initially undergo several mitotic divisions, migration commencing after the final division. Migration occurs in a radial fashion along microglial extensions that extend from the ventricular ependyma to the pial surface of the neural tube and resulting structures, and occurs in an 'inside-out' sequence; neurons destined for the deepest cortical layer migrate first (layer 6) followed by those destined for layers 5,4,3, and 2. Neurons destined for layers 1 and 7 behave differently; those for the former are generated and arrive first whereas those for layer 7 are second. When migration is complete, there is subsequent cortical organisation with the formation of discrete laminae, and synaptic connections are established.

**Table 3.1 Key stages in normal cerebral development**

Stage of development	Time complete (gestation)
Neurulation	3-7 weeks
<i>Primary</i>	3-4 weeks
<i>Secondary</i>	4-7 weeks
Prosencephalic development	1-2 months
Proliferation	2-4 months
Migration	3-5 months
Organisation	5 months – postnatal
Myelination	14 weeks - 2 years postnatal

In the normal course of development, cellular proliferation occurs between the 10th and the 18th weeks of gestation, with the full neuronal complement achieved by 20 weeks (Friede, 1989). The brain increases in surface area over the next 20 weeks, with the occurrence of sulcation to accommodate this. Migration continues throughout pregnancy and lamination is complete at term. The cortical surface continues to increase in size postnatally, with an associated increase in size and number of gyri, and the adult cortical surface is achieved by the second year of life. Myelination is also incomplete at birth, occurring in a caudocranial order beginning in the spinal cord; myelination of the hemispheric white matter occurs predominantly postnatally, mostly within the first two years.

Developmental abnormalities of the cerebral cortex may be seen as a result in interruption of any part of this process, whether neuronal and glial proliferation (ranging from focal

cortical dysplasia (Taylor *et al.*, 1971) to hemimegalencephaly (Brodtkorb *et al.*, 1992; Vigevano *et al.*, 1989)), neuronal migration (pachygyria, heterotopia) or cortical organisation (polymicrogyria, schizencephaly) (Kuzniecky and Barkovich, 1996). The association between these developmental anomalies and epilepsy appears high (Meencke and Veith, 1992; Veith and Wicke, 1968), with a low incidence of such lesions seen in normal brains both from MRI (Raymond *et al.*, 1994a) and pathological (Kaufmann and Galaburda, 1989a; Kaufmann and Galaburda, 1989b; Meencke and Veith, 1992) studies. In what way such lesions may be epileptogenic, however, remains unclear (Walsh, 1995).

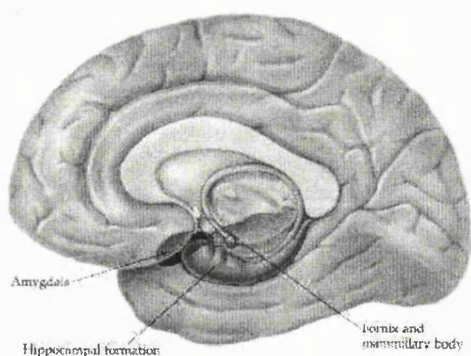
### **3.1.2 Tumours**

The majority of tumours (or 'foreign tissue lesions') presenting with epilepsy as a sole presenting symptom are low grade intrinsic lesions, with low grade gliomas, gangliogliomas and dysembryoplastic neuroepithelial tumours (DNET) those most frequently seen. Although most commonly seen within the temporal lobe, they may be seen anywhere within the cerebral cortex (Daumas-Duport *et al.*, 1988; Smith *et al.*, 1992; Zentner *et al.*, 1994). DNET was first reported as a possible separate tumour entity responsible for epilepsy by Daumas-Duport *et al.* in 1988 (Daumas-Duport *et al.*, 1988), although similar lesions had been described by Cavanagh (Cavanagh, 1958). It is likely that such lesions were previously diagnosed as low grade gliomas. The implications are that these are a benign entity, usually well circumscribed and that they are in the majority surgically remediable. Although the timing of development of such lesions is unknown, the foci of cortical dysplasia seen in association with DNET (Daumas-Duport *et al.*, 1988) imply that these lesions probably lie at one end of the spectrum of disorders of cortical development. Although pathologically gangliogliomas and DNETS are distinct lesions, a

definitive separation on the basis of features on MRI is not possible. For the purpose of this study, such lesions demonstrated on MRI will be referred to as foreign tissue lesions (FTL).

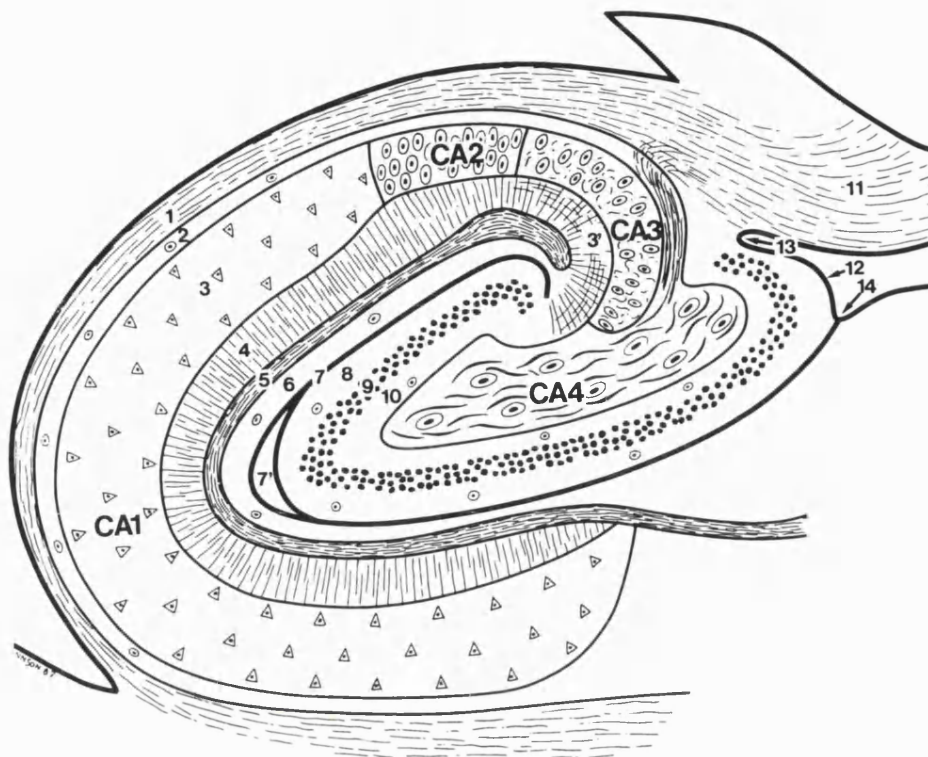
### ***3.1.3 The hippocampus and its role in epilepsy***

As mentioned in Section 1.2.4, the role of the hippocampus in epilepsy has been recognised for over 100 years (Sommer, 1880), although the aetiology of hippocampal sclerosis and its relationship to early seizures continues to cause discussion. The hippocampus is a longitudinal structure that lies along the mesial surface of the temporal lobe (Fig 3.1), divisible into three segments, head or anterior segment, body or middle segment, and tail or posterior segment. It is a bilaminar structure comprised of the cornu



**Figure 3.1: The position of the hippocampus along the mesial surface of the temporal lobe**





- |                       |                       |                        |                           |
|-----------------------|-----------------------|------------------------|---------------------------|
| <b>Cornu ammonis:</b> | 1. Alveus             | <b>Gyrus dentatus:</b> | 8. Stratum moleculare     |
|                       | 2. Stratum oriens     |                        | 9. Stratum granulosum     |
|                       | 3. Stratum pyramidale |                        | 10. Polymorphic layer     |
|                       | 4. Stratum radiatum   |                        | 11. Fimbria               |
|                       | 5. Stratum lacunosum  |                        | 12. Margo denticulatus    |
|                       | 6. Stratum moleculare |                        | 13. Fimbriodentate sulcus |
|                       | 7. Hippocampal sulcus |                        | 14. Hippocampal sulcus    |

CA1, CA2, CA3, CA4: Fields of the cornu ammonis

**Figure 3.2: Diagram of the transverse section of the hippocampal body** *From Duvernoy, 1988.*

ammonis (hippocampus proper) and the gyrus dentatus (fascia dentata). These structures are the simplest parts of the cortex, referred to as allocortex, and are divided into three layers; cornu ammonis is divided into stratum oriens, stratum pyramidale and molecular zone, and gyrus dentatus into polymorphic layer, stratum granulosum and stratum moleculare (Duvernoy, 1988). However, the cornu ammonis has also been subdivided into fields within the stratum pyramidale, in general according to the appearance of the

pyramidal neurons; these fields are known as CA1, CA2, CA3 and CA4 (also known as the hilus) (Fig 3.2). CA1 continues from the subiculum with typically triangular and generally small pyramidal cells, whereas the cells of CA2 are large, ovoid and densely packed. The cells of CA3 are like those in CA2 but less densely packed; the field of CA3 corresponds to the curve entering the dentate gyrus. CA4 is within the dentate gyrus, its pyramidal cells being large, ovoid and few in number, interspersed among mossy and large myelinated fibres.

The histological features now recognised as characteristic of 'hippocampal sclerosis' associated with temporal lobe epilepsy were first described by Sommer in 1880 (Sommer, 1880). He recognised that pyramidal cell loss was not diffuse, and was greater in CA1 (subsequently called Sommer's sector) than in the end folium (CA3-4) and the dentate gyrus. Margerison and Corsellis in a postmortem study later described two types of hippocampal sclerosis (Margerison and Corsellis, 1966); 'Classical' Ammon's horn sclerosis defined as atrophy of the hippocampal formation associated with loss of neurons and gliosis in CA1-CA4 and the dentate gyrus, and 'end folium sclerosis' confined to CA3-4. The term 'mesial temporal sclerosis' was later used by Falconer and Taylor (Falconer and Taylor, 1968) to describe the changes frequently seen in the amygdala, uncus and temporal lobe as well as the hippocampus.

Although classic hippocampal sclerosis is well recognised as the most common pathology responsible for temporal lobe epilepsy in adults, paediatric surgical series have suggested this to be a rare cause in childhood (Duchowny *et al.*, 1992; Hopkins and Klug, 1991; Wyllie *et al.*, 1993). Much discussion has been undertaken as to the aetiology of

hippocampal sclerosis, and the possible relationship to febrile convulsions in early childhood. The apparently low incidence of hippocampal sclerosis as a cause of TLE in childhood has been attributed to the so called 'latent period' between the initial insult responsible for the lesion and presentation with habitual epilepsy (Mathern *et al.*, 1995b). However, many of the adults attending for temporal lobe surgery have had a history of epilepsy since childhood (Cross *et al.*, 1996; Wyllie *et al.*, 1988), and such a group is highly selective, suggesting a higher prevalence among the more general epilepsy population. If aetiology is related to an early insult, it would be expected that changes in the hippocampus might be seen from an early age.

#### **3.1.4 Progressive disorders**

Progressive disorders are those where an underlying neuropathological process causes epilepsy associated with cognitive decline, in some cases associated with a progressive hemiparesis. Two disorders fall within this category. Firstly, there is Sturge Weber syndrome, where angiomas of the leptomeninges is associated with ipsilateral facial angiomas, ipsilateral gyriform calcification of the cerebral cortex, seizures, mental retardation and hemiplegia. This is specified as a progressive disorder as there is evidence that neurological deterioration is associated with poor control of seizures with a probable vascular aetiology (Arzimanoglou and Aicardi, 1992; Okudaira *et al.*, 1997). Secondly, there is Rasmussen's encephalitis, which presents with focal epilepsy, usually focal motor (epilepsia partialis continua in 50-60% (Oguni *et al.*, 1992)), which becomes difficult to treat with cognitive decline and, where motor cortex is involved, progressive hemiparesis. (Oguni *et al.*, 1992; Rasmussen and McCann, 1968). Diagnosis is usually suspected clinically, with EEG demonstrating focal epileptiform changes, and no specific features

except possibly progressive atrophy suggestive of the diagnosis on neuroimaging (Tampieri *et al.*, 1991). Brain biopsy provides the definitive diagnosis, with changes seen of chronic encephalitis (Anonymous 1997).

### ***3.1.5 Ischaemic lesions***

Typically these are seen as porencephalic cysts in a particular vascular distribution, causing the respective contralateral hemiplegia. These and developmental anomalies represent the largest aetiological groups amongst children with epilepsy associated with hemiplegia. The majority of such lesions are likely to be antenatal or perinatal in origin, and as such may therefore have also caused disruption of cortical development (Sarnat, 1992). This is reflected in the prevalence of epilepsy in those with congenital hemiplegia, quoted at 44% (Goutieres *et al.*, 1972), and those with postnatally acquired lesions, quoted at slightly less (20-30%) (Lanska *et al.*, 1991; Yang *et al.*, 1995). For the purpose of this study, children with epilepsy associated with hemiplegia will be classified as those with a hemisindrome.

### ***3.2 Magnetic resonance imaging in epilepsy***

As highlighted at the outset, information about the pathological substrates of epilepsy has largely been determined from postsurgical and postmortem studies. The preoperative detection of such pathology could be anticipated to improve presurgical decision making, and from outcome studies so far, possibly improve postoperative outcome (Fish *et al.*, 1993). The advent of magnetic resonance imaging has enabled the preoperative detection of such pathology, as discussed above (Cascino *et al.*, 1992; Cross *et al.*, 1993). The yield obtained from such scans, however, will depend on the way in which the scans are

acquired, in particular on the pulse sequences and slice orientations used. Previous studies have shown that by optimising the pulse sequences and slice orientation, the preoperative detection of abnormalities, particularly of the mesial temporal structures, has been increased (Cross *et al.*, 1993; Jackson *et al.*, 1990). This chapter reviews the abnormalities seen on MRI in the current group of children under study, and the relationship of such abnormalities to the clinical/EEG seizure focus.

### **3.3 Methods**

Magnetic resonance imaging is based on the detection of signals from  $^1\text{H}$  nuclei (ie protons) in water and fats when placed within a magnetic field. These nuclei possess a property known as 'spin', and as a consequence have magnetic properties. For studies to be performed in the clinical context, a subject is placed within a static magnetic field, usually of strength 0.2-2 tesla. This field orientates the nuclear spins in such a way that a net nuclear magnetisation is generated in the direction of the field. The spins of individual nuclei are then perturbed by an applied radiofrequency magnetic field. The resulting signal is detected and analysed in terms of frequency by Fourier transformation. Spatial information is achieved by application of pulsed magnetic field gradients, which make the frequency of the resonant nuclei dependent on spatial position.

The simplest type of image is a proton density image, in which the signal intensity is dependent predominantly on the relative distribution of protons through a tissue.

However, proton density images do not generally provide very good contrast. Contrast can be greatly increased by exploiting the differences in T1 and T2 relaxation times in different tissues. These relaxation times characterise the return of the nuclear spins to

their equilibrium state, after perturbation by a radiofrequency excitation pulse. To acquire a T1 weighted image, radiofrequency pulses are given in sequence at time interval TR (repetition time), similar to or shorter than the T1 of the tissues of interest. Such a time interval is insufficient to achieve complete T1 relaxation, so the signal intensity is reduced to varying degrees according to the T1 of the water protons in each type of tissue. Signal attenuation will be maximal for tissues in which T1 is long. A short TE (echo time) is used to minimise T2 effects. Greater contrast can be achieved by using different pulse sequences exploiting this principle, such as inversion recovery. This involves the application of an initial 180° radiofrequency pulse to invert the nuclear magnetisation, and this results in twice the dynamic range of signal intensity that can be manipulated. Although this technique proportionately involves a greater length of time compared to others in view of the long delay time required between consecutive acquisitions, it can provide better T1-weighted contrast.

T2 weighted images are also produced from signals generated by a spin-echo sequence, but with a long TR to minimise the effects of T1, and a long TE to increase the contrast produced by T2 weighting. An initial 90° pulse is applied, a further 180° pulse at time interval TE/2 and the echo signal recorded at time TE. The amount of signal decay during the time TE will depend on the T2 of different tissues, those with a longer T2 having a lesser degree of signal loss during a set echo time and therefore producing a higher signal. The amplitude of the signal is related to the T2 of the tissue, and therefore T2 can be calculated from measurements of the echo intensities obtained at a range of echo times (see Chapter 4).

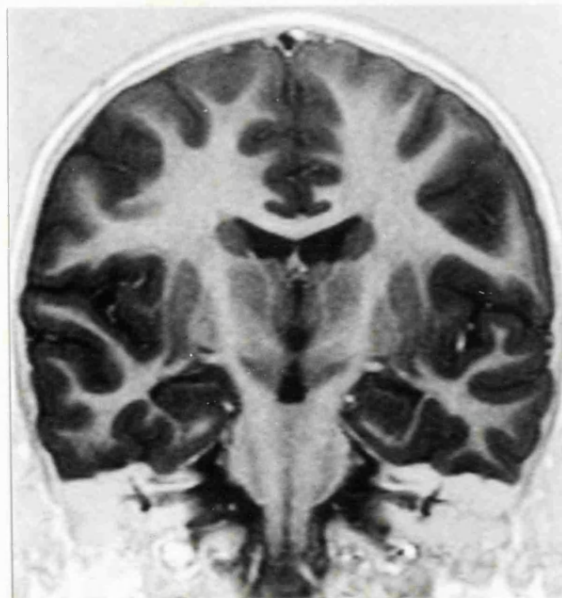
Optimised magnetic resonance imaging refers not only to the pulse sequences used to achieve maximal grey-white matter contrast, but also to the angles used for slice acquisition. For optimal views of the mesial temporal structures, Jackson et al demonstrated that slices were required parallel and perpendicular to the main axis of the hippocampus (Jackson *et al.*, 1990) (Fig 3.3). For the detection of hippocampal abnormalities a set of criteria have been defined, referring to both hippocampal asymmetry and signal change on T1 and T2 weighted sequences. Hippocampal sclerosis as seen in pathological specimens has been correlated with MRI changes, consistent with these criteria. These four criteria are hippocampal atrophy, disruption of the internal hippocampal structure, low signal from within the hippocampus on inversion recovery T1 weighted images, and high signal as determined on T2 weighted sequence (Fig 3.4).

With appropriate pulse sequences, abnormalities of cortical structure can also be determined elsewhere in the brain. Acquisition of a 3D data set covering the whole brain ensures that images can be reconstructed in any plane, with minimal slice thickness to reduce the possibility of partial volume effects. Use of the 3D MP-RAGE (Magnetization Prepared Rapid-Acquisition-Gradient-Echo) sequence (Mugler and Brookeman, 1990) enables this while retaining good contrast.

**Figure 3.3: Optimised magnetic resonance imaging**



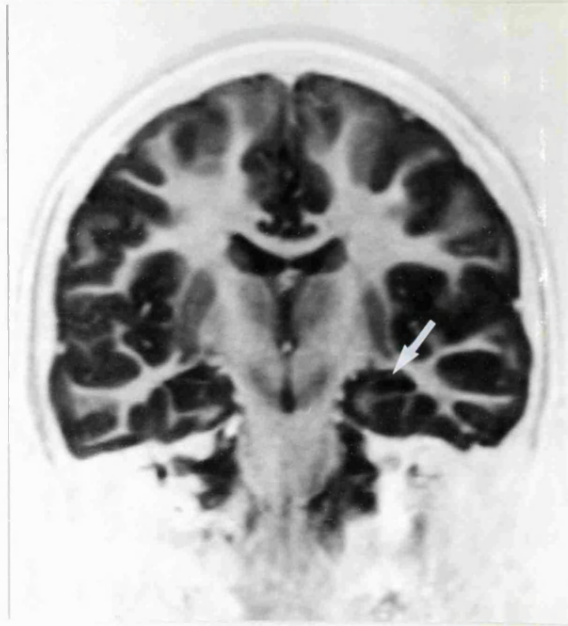
**Figure 3.3a: Magnetic resonance image, saggital view, to show the orientation of slices taken for optimal views of the mesial temporal structures**



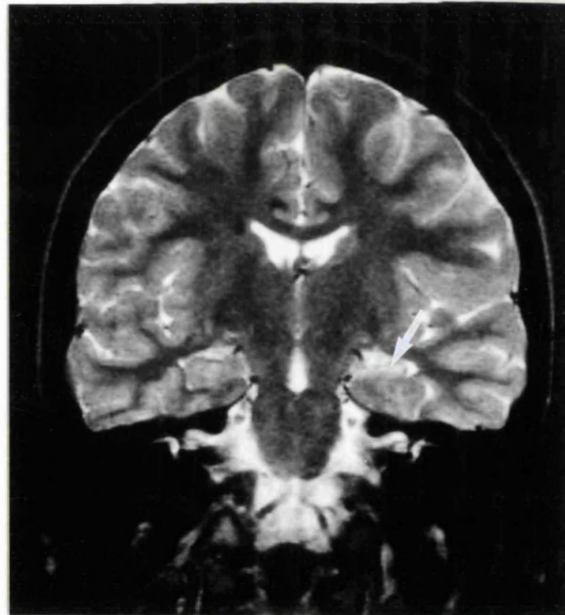
**Figure 3.3b: Tilted coronal inversion recovery view (TR=3500ms, TI=300ms, TE=26ms) of a normal child showing symmetry of the hippocampi**



A



B



**Figure 3.4: Tilted coronal slices through the hippocampus of patient T1 showing changes consistent with hippocampal sclerosis; inversion recovery sequence (A, TR=3500ms, TI=300ms, TE=26ms) shows left hippocampal atrophy with loss of signal and internal structure (arrow), whilst T2 weighted sequence (B, TR=4600ms, TE=90ms) shows high signal from within the left hippocampus (arrow).**

For the purposes of this study magnetic resonance imaging was performed on all 75 children using a 1.5T Siemens whole body system with a standard quadrature head coil. Where necessary the children were sedated or underwent a general anaesthetic. In the majority of patients, images were obtained using an inversion recovery sequence (TR=3500ms, TI=300ms, TE=26ms) in oblique axial and coronal orientations, parallel and perpendicular to the long axis of the hippocampus . In the remaining children, the oblique axial images were not acquired but were instead reconstructed from a 3D MP-RAGE data set (TR=10ms, TI=200ms, TE=4ms, flip angle=12°). In all children, T2 weighted images were also acquired in the oblique coronal plane (TR=4600ms, TE=90ms).

Magnetic resonance imaging was reviewed by an independent observer, blind to clinical and EEG data. For the purpose of reporting the abnormalities detected, children were reviewed according to the clinical/EEG 'seizure focus', as outlined in Section 2.6. MRI findings in some children could be compared to histopathology following surgery. Frequently only the hippocampus and a portion of the lateral temporal lobe were available for histological examination following temporal lobectomy. The amygdala was in the majority left in situ; therefore the term 'Ammon's horn sclerosis' or 'hippocampal sclerosis' is used as opposed to 'mesial temporal sclerosis', as no particular comment could be made to histology much outside the hippocampus. Where changes in the temporal lobe were seen, these are commented on specifically.

### **3.4 Results**

#### **3.4.1 Temporal lobe epilepsy**

Of the 40 children with TLE, 37 had abnormalities on magnetic resonance imaging and three were normal (see Table 3.2). In all 37 with abnormalities, this was of one or both temporal lobes. Twenty children had unilateral hippocampal abnormalities, thirteen children had a foreign tissue lesion of one temporal lobe, and four a neocortical abnormality of one temporal lobe. Where clinical/EEG lateralisation was possible (34 children), an abnormality of the temporal lobe was seen on MRI in 31 and was concordant with the clinical/EEG seizure focus in all.

Seventeen of the 20 children with a hippocampal abnormality on one side had imaging changes consistent with hippocampal sclerosis (HS) (as defined in Section 3.2) (see Fig 3.3), while three had unilateral hippocampal atrophy (HA) with no associated signal change. Of the 17 with HS, 10 had this in isolation with no other abnormality, five had evidence of a temporal neocortical abnormality ipsilateral to the HS, one child had ipsilateral temporal gliosis with atrophy of the whole hemisphere, and one had ipsilateral occipital gliosis. Of the three children with unilateral HA, two had this in isolation with no other abnormality and one had bilateral gliotic occipital damage with unilateral temporal involvement, ipsilateral to the HA.

Eleven of these 20 children have undergone temporal lobectomy as part of the management of their epilepsy. In 10 of the 11 who had HS on preoperative MRI, HS has

been confirmed histologically. The remaining child had HA on MRI with no signal change, but was found to have HS in association with Rasmussen's encephalitis at

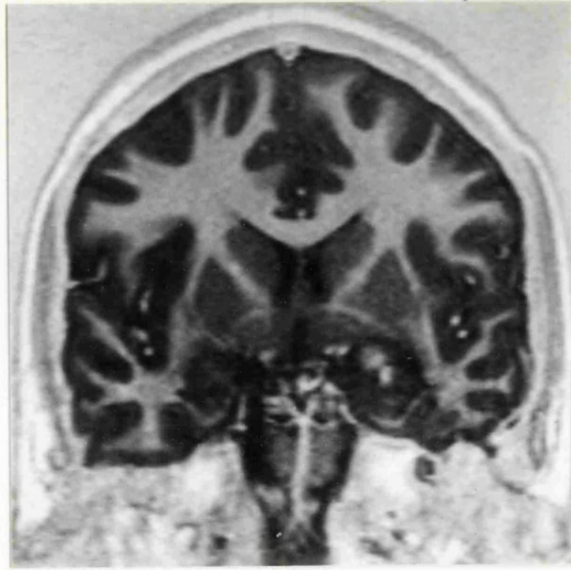
**Table 3.2**

**MRI findings in children with a clinical diagnosis of temporal lobe epilepsy**

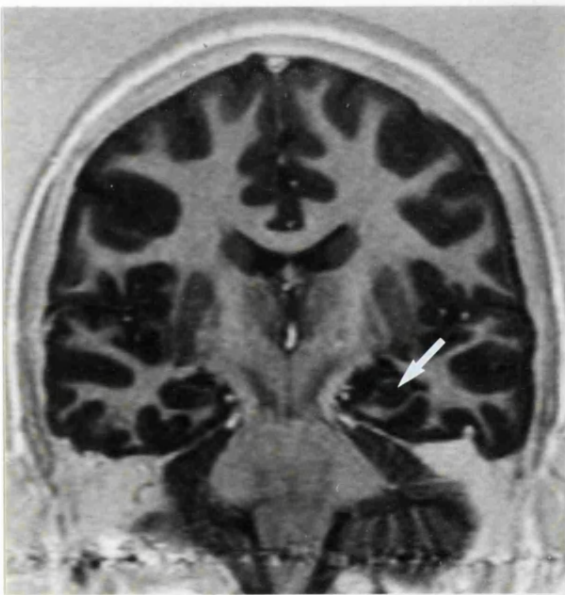
		%
<b>Foreign tissue lesion</b>	<b>13</b>	<b>32</b>
<i>with hippocampal sclerosis</i>	<i>4</i>	
<b>Hippocampal abnormality</b>	<b>20</b>	<b>50</b>
<i>HS alone</i>	<i>10</i>	
+ <i>Extratemporal</i>	<i>1</i>	
<i>HS with temporal neocortica</i>	<i>5</i>	
+ <i>Extratemporal</i>	<i>1</i>	
<i>HA alone</i>		
+ <i>Temporal + extratemporal</i>	<i>1</i>	
<b>Temporal neocortical abnormality</b>	<b>4</b>	<b>10</b>
+ <i>Extratemporal</i>	<i>2</i>	
<b>Normal</b>	<b>3</b>	<b>8</b>
<b>General cytoarchitectural change</b>	<b>0</b>	
<b>TOTAL</b>	<b>40</b>	<b>100</b>

histopathology. Two of the three children with no visual abnormality on MRI have had surgery; both had endplate gliosis of the hippocampus (one with widespread cortical dysplasia) on histopathology.

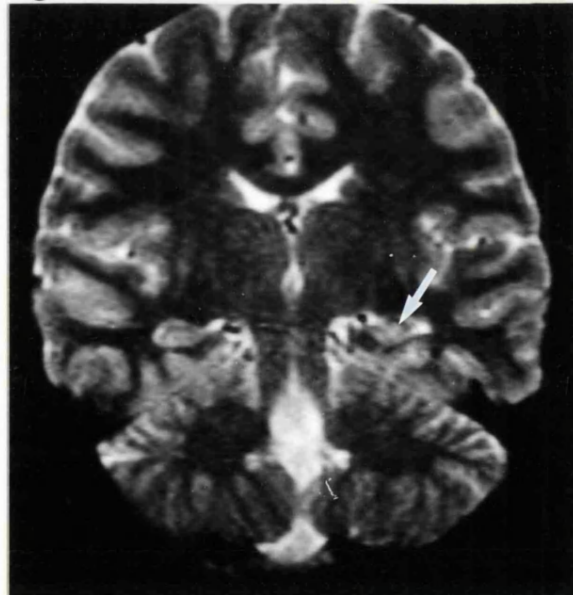
A



B



C



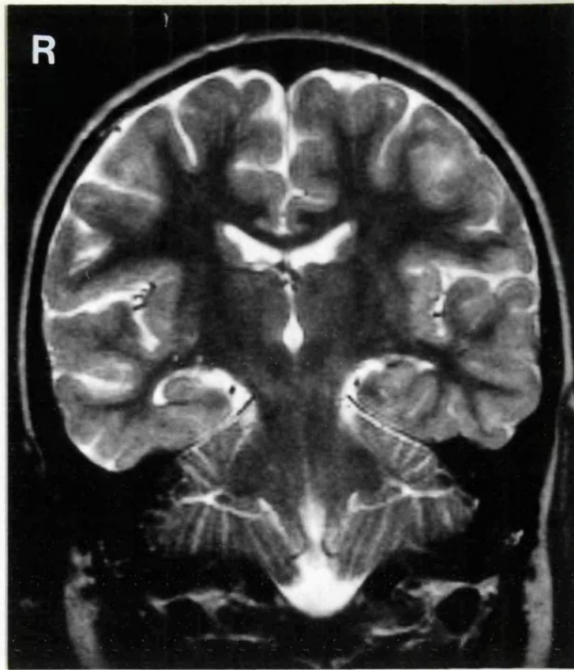
**Figure 3.5: Tilted coronal sections through the temporal lobes of patient T32, inversion recovery sequence showing a foreign tissue lesion of the left temporal lobe (A), with a small hippocampus posteriorly (B, arrow), with high signal from the hippocampus seen on T2 weighted sequence (C, arrow), confirmed at histology to be a DNET with hippocampal sclerosis.**

Thirteen children (32%) had a foreign tissue lesion (FTL, as defined in Section 3.1.2) involving one or both temporal lobes; in eleven this was confined to one temporal lobe and in two it extended into midline structures including the brain stem. Ten were thought to be consistent with a dysembryoplastic epithelial tumour, one a lesion in association with tuberose sclerosis, one a low grade glioma and one an extensive epidermoid cyst involving the posterior aspect of the corpus callosum, the central and cortical grey matter of both hemispheres and the mesial portion of the right temporal lobe. Four children also had changes consistent with HS on one side; three had HS ipsilateral to the temporal tumour (Fig 3.5) and the child with the extensive epidermoid had right hippocampal sclerosis. All thirteen children with a foreign tissue lesion have undergone surgery. All three with ipsilateral HS on MRI in addition to the lesion have been confirmed on histology.

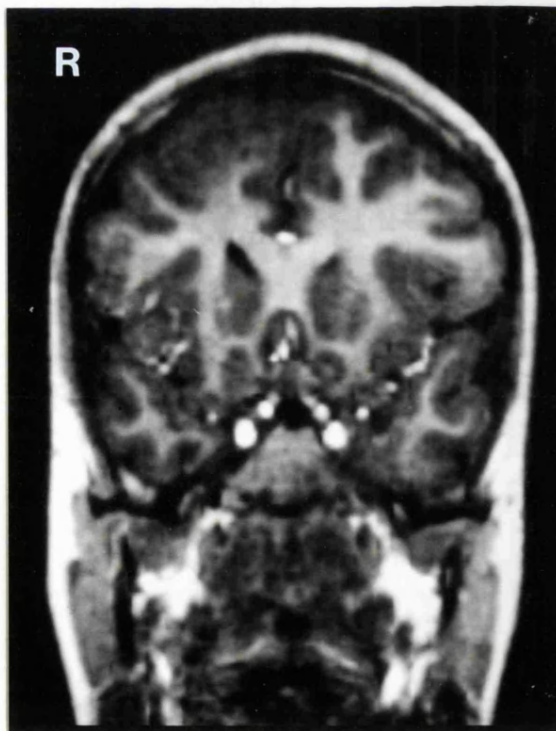
Four children had an abnormality of one temporal lobe with no evidence of a foreign tissue lesion and no hippocampal change. Three had unilateral temporal atrophy (one with occipital heterotopia on that side) and one signal abnormality in the white matter of one temporal lobe consistent with gliosis (Fig 3.6). One child with temporal atrophy has undergone surgery; she had Ammon's horn sclerosis with dentate dispersion and microdysgenesis.

### ***3.4.2 Extratemporal epilepsy***

Ten children within this group (63%) had an abnormality on MRI and six were normal. Of those with an abnormal scan, seven children had a focal extratemporal abnormality; three had unilateral frontal dysplasia (see Fig 3.7), two had focal atrophy of one cerebral



**Figure 3.6:** Tilted coronal section, T2 weighted sequence, through the temporal lobes, of patient T13 showing signal change in the right temporal lobe suggestive of gliosis. The hippocampi are symmetrical.



**Figure 3.7:** Tilted coronal section, reconstructed from a 3D MP-RAGE data set, through the frontal lobes of patient E2 demonstrating thickened cortex in the right frontal lobe, consistent with cortical dysplasia

**Table 3.3: MRI findings in children with a diagnosis of extratemporal epilepsy**

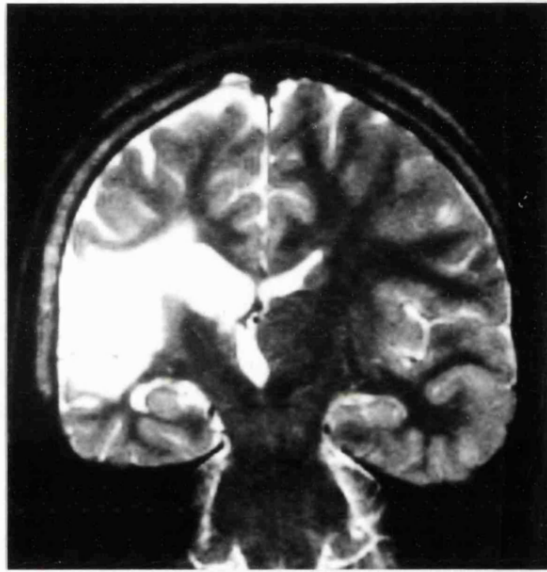
		%
<b>Focal extratemporal abnormality</b>	<b>7</b>	<b>44</b>
<i>Foreign tissue lesion</i>	<i>1</i>	
+ <i>hippocampal sclerosis</i>	<i>1</i>	
<b>Generalised cytoarchitectural change</b>	<b>2</b>	<b>12.5</b>
<b>Hippocampal abnormality alone</b>	<b>1</b>	<b>6</b>
<b>Normal</b>	<b>6</b>	<b>37.5</b>
<b>TOTAL</b>	<b>16</b>	<b>100</b>

hemisphere (one of whom had hippocampal sclerosis on that side), one had frontal FTL (probable DNET), and one had a gyral abnormality of both frontal lobes. Two children had generalised cytoarchitectural change of the grey matter. One child had definite unilateral hippocampal sclerosis with a small contralateral hippocampus but no extratemporal abnormality.

### **3.4.3 Hemisyndromes**

All 16 children with a clinical hemisindrome had a unilateral abnormality on MRI. Seven children showed cystic change of one hemisphere; in four this was consistent with an infarct of the middle cerebral artery, two had extensive encephalomalacia, and one had an extradural cyst with a dysplastic hemisphere. Six children had changes consistent with a developmental anomaly of one hemisphere with no definite involvement of the contralateral hemisphere; in four this involved at least three lobes but not the whole cerebral hemisphere and in two the involved hemisphere was larger than the other side and the diagnosis consistent with hemimegalencephaly. Two children showed atrophy of





**Figure 3.8: Tilted coronal section, T2 weighted sequence of patient H7, showing a porencephalic cyst in the right middle artery territory, and a small hippocampus on that side.**

one cerebral hemisphere. The final child showed focal high T2-weighted signal from the left posterior frontal cortex suggestive of an inflammatory process. No child demonstrated an abnormality of the contralateral cerebral hemisphere. No child with Sturge Weber Syndrome was included within this study.

**Table 3.4 MRI findings in children with hemisyndromes**

		%
<b>Developmental anomaly</b>	<b>6</b>	<b>37.5</b>
+ <i>hippocampal sclerosis</i>	<i>0</i>	
<b>Porencephaly</b>	<b>7</b>	<b>44</b>
+ <i>hippocampal sclerosis</i>	<i>2</i>	
<b>Atrophy of one cerebral hemisphere</b>	<b>2</b>	<b>12.5</b>
+ <i>hippocampal sclerosis</i>	<i>1</i>	
<b>Focal extratemporal abnormality</b>	<b>1</b>	<b>6</b>
+ <i>hippocampal sclerosis</i>	<i>1</i>	
<b>TOTAL</b>	<b>16</b>	<b>100</b>

Four children in this group also had unilateral hippocampal sclerosis on the side of the cerebral abnormality; one MCA infarct (Fig 3.8), one encephalomalacia, one focal high signal and one hemiatrophy.

#### **3.4.4 Unlocalised epilepsy**

All three children with epilepsy that could not be clinically localised had an abnormality of one temporal lobe on visual analysis of their MRI; one a probable DNET (confirmed on pathology), one an arachnoid cyst with temporal lobe hypoplasia and hippocampal sclerosis, and one temporal lobe atrophy (found to show changes consistent with cortical dysplasia at histopathology).

### 3.5 Discussion

Magnetic resonance imaging detected a high rate of abnormality in this group of children with difficult focal epilepsy, with no detectable abnormality in only eight children (three with temporal and five with extratemporal pilepsy) on visual analysis alone. Furthermore, in the children with clinical temporal lobe epilepsy, 92% of children had an abnormality of one or both temporal lobes, whereas this was seen in only one child with extratemporal epilepsy; nine of the extratemporal group (57%) had a focal extratemporal abnormality or general cytoarchitectural change. All three children with clinically unlocalised epilepsy had abnormalities of one temporal lobe; all three had a severe seizure disorder with onset in the first year of life and a marked developmental and communication disorder.

It is notable that there is a higher rate of abnormality seen in children with temporal lobe epilepsy (92%) as compared to extratemporal epilepsy (63%). The hippocampus and surrounding temporal lobe structures are well defined structures, and there has been much discussion regarding their role in focal epilepsy; focal abnormalities in extratemporal epilepsy have been traditionally more difficult to define. It is likely that the relative lack of knowledge of the gyral patterns in children inhibits the determination of subtle abnormalities of cerebral development by visual analysis alone; this is illustrated in part by the reporting of 'general cytoarchitectural change' in two children. Such abnormalities are probably developmental abnormalities not yet fully elucidated by current magnetic resonance techniques. More recent MRI studies using mathematical analysis of gyral patterns have shown abnormalities in 'cryptogenic' epilepsy (Sisodiya *et al.*, 1996), and have demonstrated further abnormalities in individuals with easily recognised focal

cortical dysplasia (Sisodiya *et al.*, 1995). Such abnormalities are not seen in normal controls (Sisodiya *et al.*, 1995; Sisodiya *et al.*, 1996) and have a much higher frequency in pathology studies in the brains of individuals with epilepsy than normal controls (Meencke and Veith, 1992). This may have implications not only for postsurgical outcome after focal resection (Sisodiya *et al.*, 1997), but in determining abnormalities in those patients with no apparent abnormality on visual inspection of MRI (Sisodiya *et al.*, 1995). A possible example of this is seen in the current study in the case of one child with temporal lobe epilepsy and normal MRI where histopathology demonstrated cortical dysplasia.

There was a particularly high rate of hippocampal abnormality seen in children with nonlesional TLE; 63% had changes consistent with unilateral hippocampal sclerosis whether in isolation or coexistent with other temporal or extratemporal abnormalities. This was confirmed histologically in all 11 children who have proceeded to temporal lobectomy for the treatment of their epilepsy. This figure is comparable to that reported in adult surgical series (Babb and Brown, 1987; Bruton, 1988; Mathieson, 1975), but is much higher than that seen previously in paediatric temporal lobectomy series (Duchowny *et al.*, 1992; Hopkins and Klug, 1991). However other recent MRI studies of children with intractable temporal lobe epilepsy (Harvey *et al.*, 1995; Grattan Smith *et al.*, 1993) have also reported a high incidence (60%) of HS, seen as early as age two years in one study (Harvey *et al.*, 1995). Although the relationship between HS and epilepsy has been known for a long time, the aetiology of HS continues to cause debate. The relationship between hippocampal abnormality and a history of early childhood seizures will be discussed in detail in the context of quantitative analysis in Chapter 4.

Hippocampal abnormalities were also seen in two of ten children with extratemporal epilepsy and four of 15 children with hemisyndromes. In five of these six children with hippocampal abnormalities, these were seen in addition to a further focal brain abnormality likely to be responsible for the seizures, and in only one was hippocampal pathology seen in isolation with no other focal brain abnormality. The role and aetiology of hippocampal sclerosis in these children raises the question as to whether this is secondary to repeated seizures rather than primary hippocampal damage seen as part of the underlying aetiology: this issue will be discussed further in the context of quantitative analysis in the following chapters.

All the children with hemisyndromes had an abnormality on MRI; in 15 this involved a substantial portion of one hemisphere. A developmental abnormality was described in six; five of the six had had an inaccurate assessment on a previous CT examination, the probable dysplasia only becoming apparent on MRI. In all of these children, surgery in the form of hemispherectomy that had not previously been considered was then felt to have a place in the management of their epilepsy.

This part of the study has demonstrated structural abnormalities in a high proportion of children undergoing evaluation for epilepsy surgery. These abnormalities appear to correlate well with the predetermined clinical/EEG focus. However, further functional information is required to relate seizure activity to these structural abnormalities and to provide further support for surgical intervention.

## CHAPTER 4

### QUANTITATIVE T2 RELAXOMETRY IN FOCAL EPILEPSY

---

#### Contents

#### *4.1 Introduction*

#### *4.2 Methods*

#### *4.3 Control data*

#### *4.4 Patient population*

#### *4.5 Data analysis*

#### *4.6 Results*

##### *4.6.1 Temporal lobe epilepsy*

##### *4.6.2 Extratemporal epilepsy*

##### *4.6.3 Hemisyndromes*

#### *4.7 Summary of results*

#### *4.8 Relationship between T2 relaxometry, a history of early childhood convulsions and status epilepticus*

#### *4.9 Discussion*

---

#### *4.1 Introduction*

Hippocampal sclerosis is now well recognised as the most common cause of TLE in adults, and can be reliably detected on visual analysis on MRI. Although this pathology has not been common amongst surgical series of children with TLE, the study described in Chapter 3 has shown hippocampal abnormalities to be common not only in children with seizures thought to arise from the temporal lobe, but also in association with other abnormalities. The high incidence of hippocampal sclerosis in childhood TLE is in keeping with other paediatric MR series (Grattan Smith *et al.*, 1993). However several questions remain that cannot be answered by visual inspection of images alone.

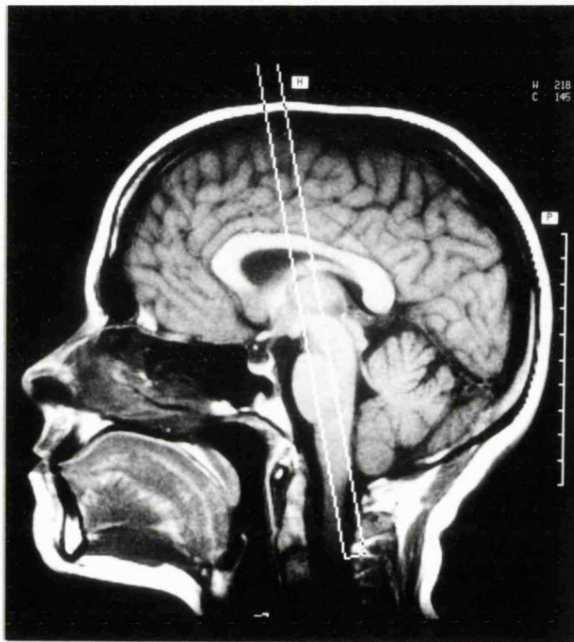
The features recognisable on MRI as indicative of hippocampal sclerosis appear reliable, but as seen in the previous chapter are not 100% sensitive. One child who underwent temporal lobectomy had hippocampal sclerosis at pathology with only temporal lobe atrophy seen on visual inspection of the MRI. Two further children with no abnormality on MRI had end plate gliosis at pathology. Therefore the question is raised as to whether all hippocampal pathology is being detected by visual analysis alone. This is also pertinent in the detection of 'dual pathology'. The TLE group in this study demonstrated a high incidence of hippocampal pathology in addition to extrahippocampal abnormality. Dual pathology has been suggested to be more common in children with TLE who present for surgery than isolated hippocampal sclerosis (Jay *et al.*, 1993), and this could have implications for the procedure undertaken. Pathological studies also suggest that hippocampal abnormalities seen in addition to extrahippocampal pathology may be qualitatively different from classical HS (Babb and Brown, 1987; Lévesque *et al.*, 1991), and may therefore not demonstrate all the characteristic features of HS on MRI. The detection of such abnormalities may have relevance to the decision as to whether mesial temporal structures need to be included in the surgical excision. Finally, visual inspection alone may not detect bilateral pathology. One feature of HS is atrophy. Visual assessment of this may rely on side to side asymmetry and therefore bilateral damage, if present, may be difficult to determine. Similarly, hyperintensity on T2 weighted imaging is more difficult to detect if both hippocampi show similar high signal, particularly in relatively subtle cases. Postmortem studies of individuals with chronic epilepsy suggest a high incidence of bilateral hippocampal damage (Margerison and Corsellis, 1966), although the relevance to postsurgical outcome is unknown. Quantitative assessment in these circumstances could be considered as more reliable.

Magnetic resonance methods for quantitative assessment of the hippocampus have been developed, in particular volumetric analysis and T2 relaxometry. Hippocampal volumetry has been shown to reliably detect hippocampal atrophy, both unilateral and bilateral, with a greater sensitivity than visual analysis, and a significantly smaller hippocampus on one side has been correlated with seizure origin in TLE (Cendes *et al.*, 1993a; Cook *et al.*, 1992; Jack, Jr. *et al.*, 1990). The process of data analysis, however, is subjective and requires a high degree of expertise for accurate and reproducible analysis. T2 relaxometry is a further means of identifying hippocampal abnormality. It provides a means of quantifying the T2 relaxation changes that form the basis of contrast in T2-weighted MRI. As outlined in Section 3.3, T2 weighted images show high signal in tissues with a long T2 relaxation time. Although helpful in the evaluation of the hippocampus, increased signal on T2-weighted imaging has been variably reported, from 8% to 70% in adult studies (Convers *et al.*, 1990; Kuzniecky *et al.*, 1987; Sperling *et al.*, 1986; Dowd *et al.*, 1991; Jackson *et al.*, 1990; Bronen *et al.*, 1991). Quantitative T2 relaxation mapping has been shown not only to detect unilateral hippocampal pathology with greater sensitivity than visual inspection of T2 weighted images, but also to detect subtle bilateral abnormalities not obvious from visual inspection alone (Jackson *et al.*, 1993a; Jackson *et al.*, 1993b). It has also been shown to be reproducible, and to be stable over a period of time (Grunewald *et al.*, 1994). The aims of this part of the study were to investigate the role of T2 relaxometry in i) the detection of hippocampal abnormality in children, ii) lateralisation of brain abnormality, iii) the detection of bilateral pathology and iv) the detection of dual pathology.



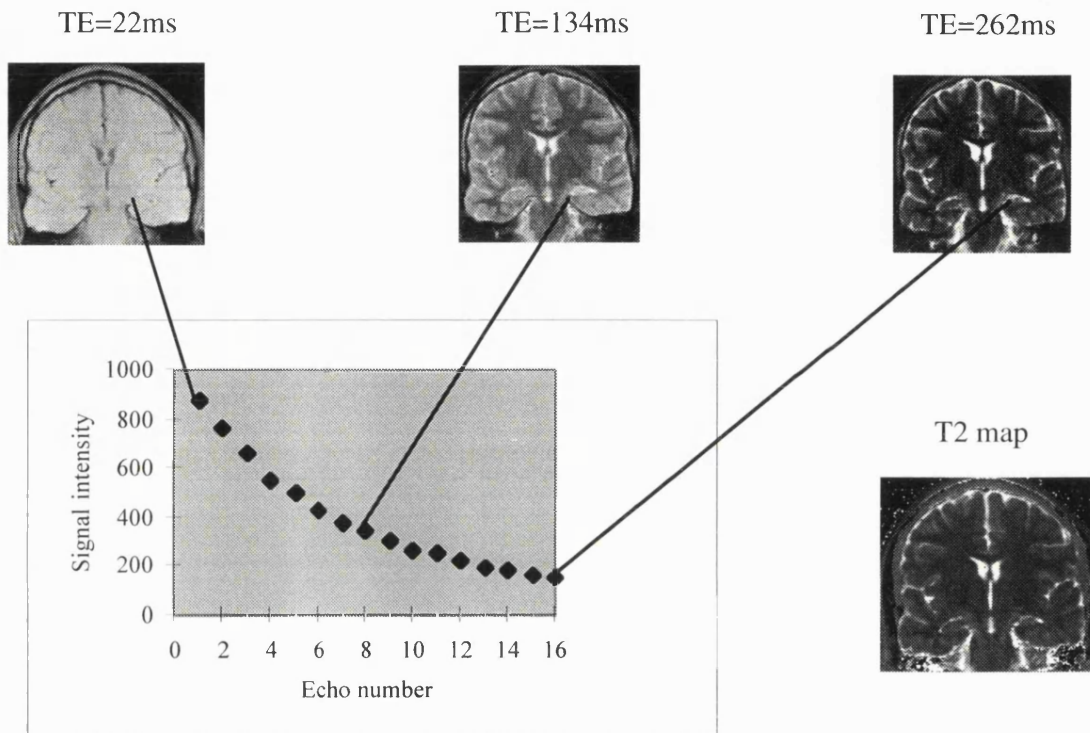
## 4.2 Methods

T2 maps were calculated from 16 images obtained at echo times 22ms to 262 ms using a Carr-Purcell-Meiboom-Gill sequence in a tilted coronal slice through the body of the hippocampus. The slice was oriented on a line that crossed the pons on the anterior border of the brain stem of the sagittal scout image (Fig 4.1). The slice thickness was 8mm.

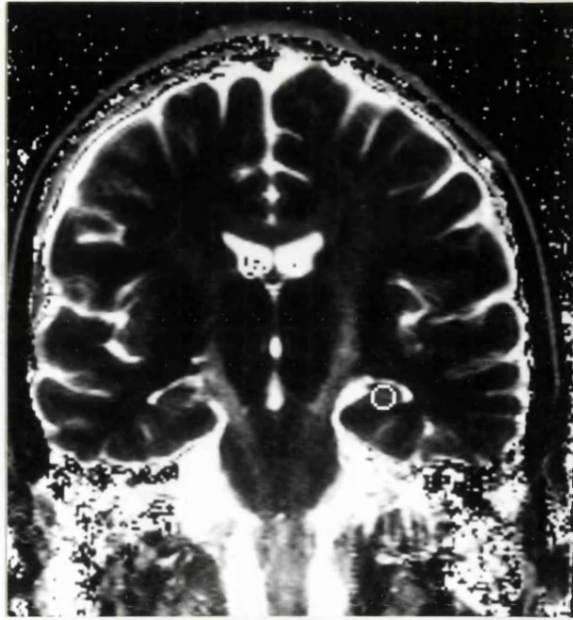


**Figure 4.1: Sagittal scout image to show angle of slice orientation for acquisition of images for T2 relaxometry**

T2 maps were generated by fitting single exponentials to the image data of corresponding pixels from all 16 echoes. In this way a T2 relaxation time was calculated for each pixel, and an image was then constructed in which pixel intensity corresponded to the calculated T2 relaxation time (Fig 4.2). After identification of the anatomical boundaries of the hippocampus, mean T2 hippocampal relaxation times were measured by two independent



**Figure 4.2:** Diagram to illustrate methodology for calculation of a T2 map (see Section 4.2). Sixteen images are obtained at echo times 22-262ms, and a single exponential fitted to the image data of corresponding pixels from all 16 echoes. A T2 relaxation time is calculated for each pixel and an image constructed in which pixel intensity corresponds to the calculated T2 relaxation time.



**Figure 4.3: T2 map with the position of the region of interest within the left hippocampus from which a mean T2 value is taken.**

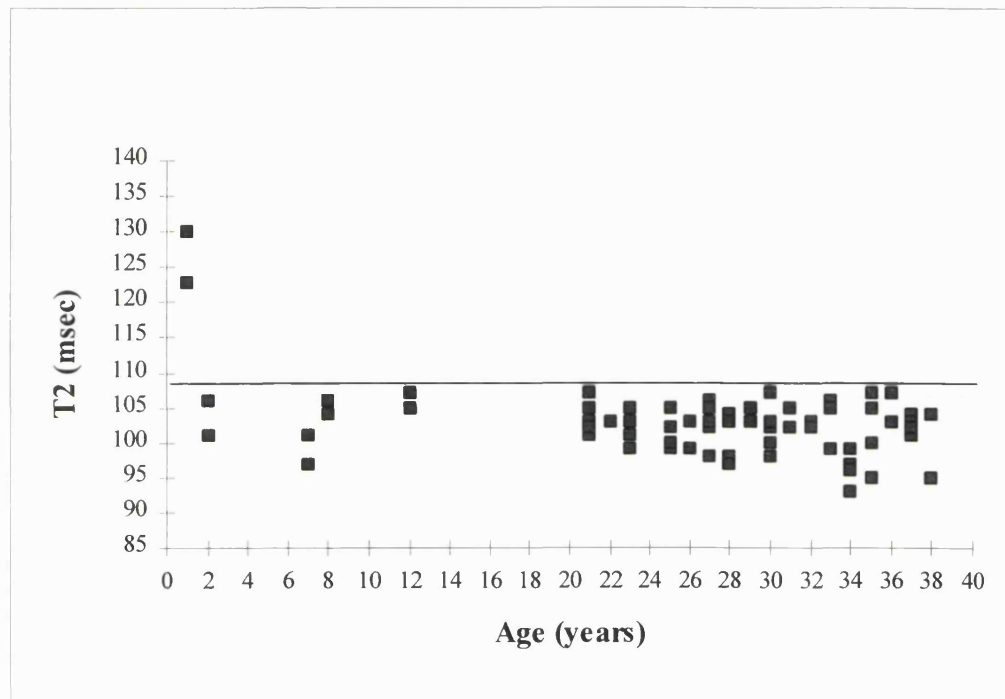
observers. Each placed a region of interest in the largest possible area within the hippocampus while avoiding boundaries where partial volume effects may occur, and the mean T2 value was noted (Fig 4.3).

#### ***4.3 Control data***

The results of T2 relaxometry of the right and left hippocampi were available from 33 normal adults. Obtaining control data from young children is difficult in view of the need to lie still in the MR machine and therefore the need for sedation. However, data were also obtained from four children who had no clinical evidence of cerebral disease, and who had normal MR imaging. These children were of age range 2 years -12 years. The range of T2 values in the 66 normal hippocampi of adults was 93-107 ms, mean 102 ms with a standard deviation of 3.13 ms (Fig 4.4). The maximum T2 within the normal

population was 107 ms and maximum side to side difference 8 ms. The upper limit of the normal range was therefore taken as the mean + two standard deviations; ie 108 ms.

**Figure 4.4 : T2 relaxometry in a control population**



The exact pathological correlates of T2 abnormalities have yet to be determined, although one study has shown hippocampal T2 to be related inversely to neuronal density (Van Paesschen *et al.*, 1997c). High signal as determined by T2 weighted imaging is related to water mobility. Postmortem brain studies suggest that brain water content decreases with age, but attains adult levels by the age of two years (Fig 4.5) (Dobbing and Sands, 1973).

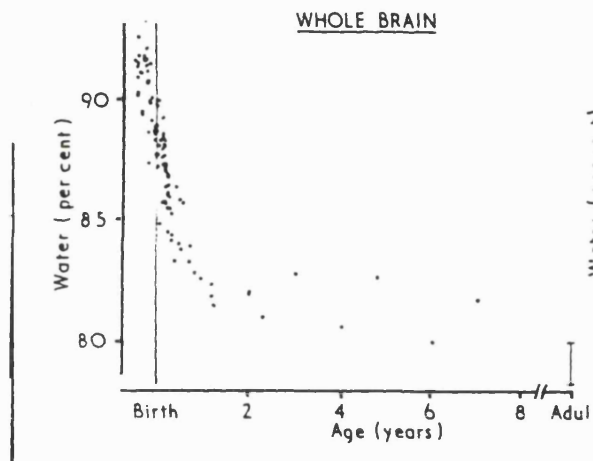


Figure 4.5 Percentage of water in whole brain by age as determined at postmortem (Dobbing, Sands, 1973)

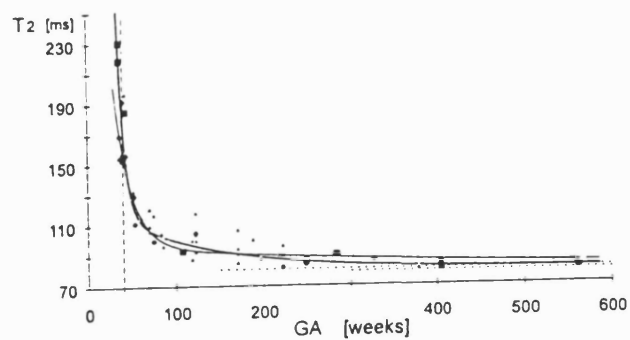


Figure 4.6: T2 relaxation of water in cerebral tissue as a function of gestational age (Kreis *et al.*, 1993)

Developmental changes also occur within the hippocampus with age, but most occur in the first two-three years of life, especially in the first six months (Mathern *et al.*, 1996). The eight T2 values obtained from the four normal children over two years of age were in the range 97-107ms (see Fig 4.4); one further child age 14 months with no evidence of cerebral disease had hippocampal T2 values of 130ms and 123ms, outside the taken normal range. These data would be consistent with the developmental changes reported above, and would also be consistent with those reported by Kreis *et al.* (Fig 4.6) (Kreis *et al.*, 1993), who demonstrate reduction of water T2 with age, predominantly over the first two years. The normal range in our control population was therefore suitable to apply to children over the age of two years, and for the purpose of this current analysis children under the age of two years were excluded.

#### **4.4 Patient population**

Fifty five children within the overall study (see Section 2.3) had T2 relaxometry of the hippocampi as part of their MR examination; 32 had a likely seizure focus within the temporal lobe (29 that could be lateralised), 11 a likely extratemporal focus, nine had a hemisynndrome, and three were unlocalised (who had a focal abnormality of one temporal lobe on MRI). Three patients under the age of two years (two hemisyndromes, one TLE) were excluded from analysis for reasons detailed in Section 4.3. Furthermore, the three further children with TLE that could not be clinically lateralised were also excluded. The 49 children therefore studied were in the age range 3 years to 17 years 10 months (mean 10 years) with a mean age of first seizure 3 years 6 months (range 21 days to 12 years 6 months).

#### **4.5 Data analysis**

Control data demonstrated a normal distribution, whereas patient data did not. In view of this, coupled with small numbers of patients in some groups, nonparametric tests of statistical analysis were used. Wilcoxon matched pair tests were used for side to side comparison of T2 data, and the Mann Whitney U test for intergroup comparison and comparison of patient data with controls. Pearson correlation and multiple regression analysis was used to examine the relationship of patient variables with T2 data.

In order to assess the value of T2 relaxometry in lateralisation of the seizure focus in children with TLE, T2 was considered to be lateralising if it was i) abnormally low and also ii) lower than on the contralateral side by more than 6ms (2 standard deviations from the control data).

#### **4.6 Results**

##### **4.5.1 Temporal lobe epilepsy**

Of the 28 children with TLE, 21 (75%) had an abnormality of one or both hippocampi on T2 relaxometry. In 11 (38%) this was unilateral and 10 (36%) bilateral. The mean T2 values ipsilateral and contralateral to the seizure focus were 115ms  $\pm$  9 ms and 108ms  $\pm$  4ms respectively.

T2 values of the hippocampus ipsilateral to the clinical/EEG seizure focus compared to visual analysis of MRI are shown in the Appendix (Tables A4.1 & A4.2). All 12 children

with visual changes consistent with unilateral hippocampal sclerosis had T2 values  $\geq 116$ ms on that side. Ten of these 12 have undergone temporal lobectomy and hippocampal sclerosis has been confirmed in all. Six of the nine children with foreign tissue lesion of one temporal lobe had an abnormal T2 value on that side. Two of the three children with a visually normal MRI also had normal T2 values; one has had surgery and found to have cortical dysplasia of the temporal lobe. The third child had a moderately abnormal ipsilateral T2 (110ms) and was found to have end plate gliosis on pathology.

**Table 4.1**  
**Comparison of visual analysis of MR images and quantitative T2 measurements of the hippocampus**

Ipsilateral pathology	Ipsilateral T2 (ms)		
	$\geq 108$	109-115	$\geq 116$
Foreign tissue lesion N=9	3	4	2
Hippocampal sclerosis N=12	0	0	12
Hippocampal atrophy N=2	1	0	1
Temporal lobe gliosis N=1	1	0	0
Temporal lobe atrophy N=1	1	0	0
Normal N=3	2	1	0

One child has been shown to have hippocampal sclerosis on pathology, with normal T2 relaxometry of the hippocampus (104ms) and evidence only of temporal lobe atrophy on visual inspection. One of the two children with hippocampal atrophy but no signal change apparent visually had an ipsilateral T2 of 125ms; she had changes consistent with Rasmussen's encephalitis at pathology but also had severe neuronal depletion in all



regions of the hippocampus. The other child had ipsilateral T2 values within the normal range and has not undergone surgery.

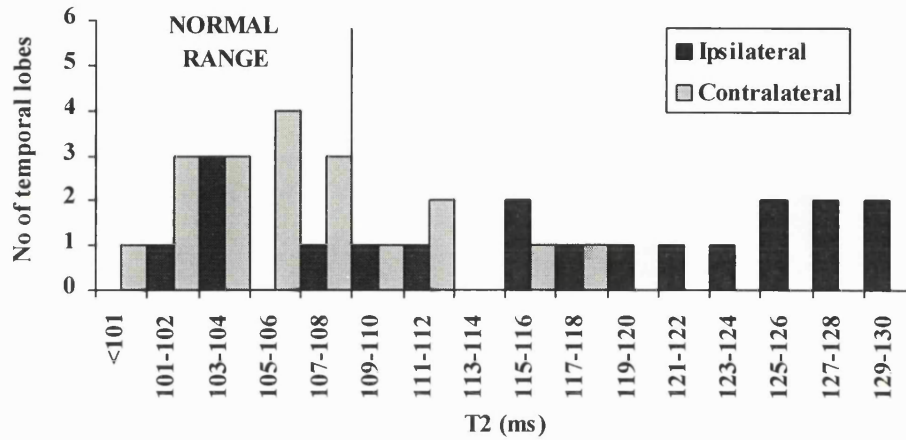
For further analysis the group was divided on the basis of results of MRI; those who did not have a foreign tissue lesion on MRI (nonlesional, N=19) and those who did (lesional, N=9)

### **i. Nonlesional TLE**

Of the 19 children with nonlesional TLE, 14 (74%) had a T2 value for one or both hippocampi outside the normal range (see Fig 4.7). In nine, T2 relaxometry was unilaterally abnormal, and in five it was bilaterally abnormal. The mean T2 values for the hippocampi ipsilateral and contralateral to the seizure focus were  $117\text{ms}\pm 10\text{ms}$  and  $107\text{ms}\pm 5\text{ms}$  respectively; in 12 of the 14 patients who showed T2 abnormalities, at least one hippocampus had a T2 value  $\geq 116\text{ms}$  (10 unilateral and two bilateral). Group data demonstrated that there was a significant difference between ipsilateral and contralateral sides ( $p<0.0001$ ) as well as between the ipsilateral side and controls ( $p<0.0001$ ), and between the contralateral side and controls ( $p<0.0001$ ).

In all those with T2 abnormalities, the value was higher on the side ipsilateral to the seizure focus. On the basis of the criteria for lateralisation outlined in Section 4.5, T2 values were lateralising in 11 (58%). This was ipsilateral to the seizure focus in all 11 cases and was therefore incorrectly lateralising in none.

**Figure 4.7: T2 relaxometry in nonlesional TLE**

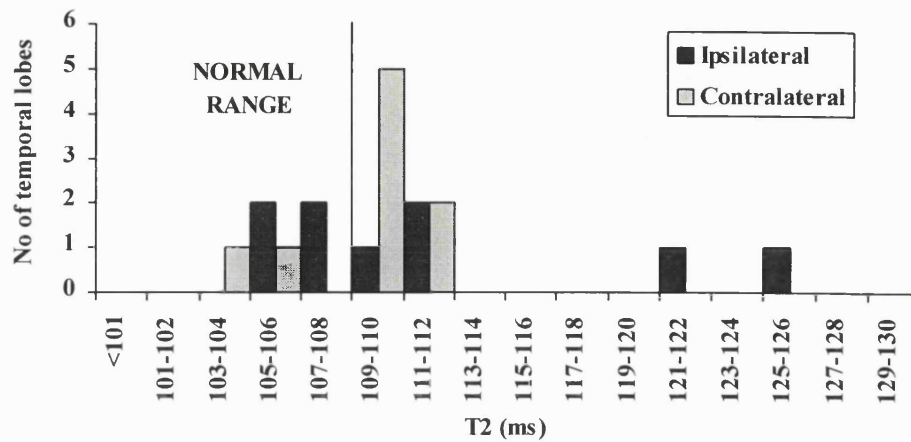


**ii. Lesional TLE**

Seven of the nine children with lesional TLE had abnormal T2 values (78%); in five this was bilateral and in two it was unilateral (Fig 4.8). The mean values for the hippocampi ipsilateral and contralateral to a FTL were 112ms±2.2ms and 109ms±1ms respectively; in only two was at least one value of T2 ≥116ms. There was a significant difference between ipsilateral T2 values and controls (p<0.0001) as well as between contralateral T2 values and controls (p<0.0001), but no difference between the two sides (p=0.3).

Of the seven children where clinical seizure lateralisation was possible on the basis of lateralisation criteria described in Section 4.5, T2 values were lateralising in four of the children; correctly lateralising in two, and incorrectly lateralising in two. In the two that were incorrectly lateralising, both had a foreign tissue lesion of the temporal lobe thought to be the source of seizures (one in the context of tuberosc sclerosis); in both the T2 value ipsilateral to the tumour was within the normal range, and the contralateral values were 112ms and 110ms.

**Figure 4.8: T2 relaxometry in lesional TLE**



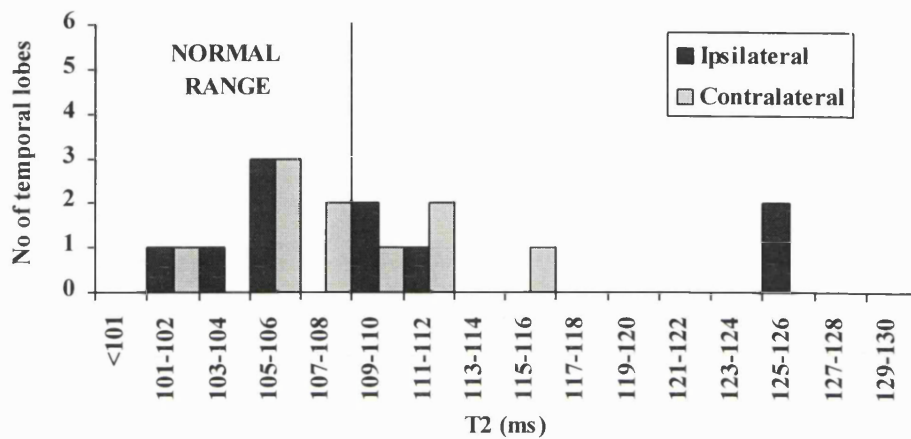
Three further children with clinically unlocalised epilepsy had a visually abnormal temporal lobe on MRI. In all three children T2 maps were bilaterally abnormal, in one nonlateralising and two lateralising with the higher value on the side of the MR abnormality.

#### **4.5.2 Extratemporal epilepsy**

Of the 11 children within this group, five (45%) had T2 abnormalities. Where lateralisation could be achieved (N=10), the mean T2 values ipsilateral and contralateral to the seizure focus were 110 ms±8ms and 108±4ms respectively. As with the lesional TLE group, there was a significant difference between ipsilateral T2 values and controls ( $p<0.0001$ ), as well as between contralateral data and controls ( $p<0.0001$ ) but no difference between the two sides ( $p=0.8$ ). In three children the values were bilaterally abnormal and in two they were unilaterally abnormal. In only two children had hippocampal abnormalities ipsilateral to the seizure focus been suspected on visual analysis of MRI scans; in one, hippocampal sclerosis was seen in isolation (T2 ipsilateral

to the seizure focus 125ms, contralateral 112ms), and in the other it was seen in addition to focal atrophy of the frontoparietal region on that side (ipsilateral T2 125ms, contralateral T2 112ms).

**Figure 4.9: T2 relaxometry in extratemporal epilepsy**



#### 4.5.3 Hemisyndromes

Five of the seven (71%) children in this group had T2 abnormalities of the hippocampi. The mean values ipsilateral and contralateral to the seizure focus were  $111\text{ms}\pm 7\text{ms}$  and  $107\text{ms}\pm 6\text{ms}$  respectively. There was a significant difference between ipsilateral T2 and controls ( $p=0.001$ ) but no difference between contralateral T2 and controls ( $p=0.08$ ) or between the two sides in patients ( $p=0.07$ ). In three children there were bilateral abnormalities and in two there were unilateral abnormalities. Four children had hippocampal sclerosis ipsilateral to the hemisphere abnormality reported on MRI. T2 values in the range 110-115ms were seen in three; in two this was bilateral. Although all

seven have undergone hemispherectomy, the hippocampus on that side was available for histological examination in only two. One showed hippocampal sclerosis (T2=98ms), and one had cortical dysplasia that involved the hippocampus as well as the whole hemisphere (T2 115ms).

#### ***4.7 Summary of results***

This study has demonstrated a high rate of abnormality of the hippocampi in a group of children with drug-resistant focal epilepsy, with abnormalities of at least one hippocampus seen in 32 (57%), and bilateral abnormalities seen in 16 (29%). When subgroups were examined, children with nonlesional TLE demonstrated a significant difference in T2 between hippocampi ipsilateral and contralateral to the seizure focus, with lateralisation in 58%, and also between ipsilateral hippocampi and controls as well as contralateral hippocampi and controls.

Children with lesional TLE and extratemporal epilepsy had T2 values ipsilateral and contralateral to the seizure focus significantly different from controls, but to a similar degree with no significant difference as a group between the two sides.

#### ***4.8 Relationship between T2 relaxometry, a history of early childhood convulsions and status epilepticus***

Table 4.2 shows the results of T2 relaxometry related to history of early convulsions in children with nonlesional TLE. Fourteen of the 19 children in this group had a history of early febrile convulsions or status epilepticus; 10 febrile convulsions (seven prolonged) and four status epilepticus. A history of a febrile convulsion was associated with significantly higher T2 values than those without a such a history ( $p < 0.0001$ ) whereas a

history of status epilepticus was not ( $p=0.7$ ). All children with a history of a prolonged febrile convulsion (seven children) had a T2 value ipsilateral to the seizure focus  $> 116$ ms. Of the three children with a history of a simple febrile convulsion, two ipsilateral values were abnormal with only one in the severely abnormal range ( $\geq 116$ ms); and of the four patients with a history of status, three ipsilateral T2 values were abnormal, two greater than 116ms. This is in contrast to the five children with no history of status or febrile convulsion where only two children had an abnormal T2 value, both ipsilateral to the seizure focus.

**Table 4.2**  
**T2 relaxometry of the hippocampi in nonlesional TLE in relation to early convulsions**

	Ipsilateral T2 (ms)			Contralateral T2 (ms)		
	$\leq 108$	109-115	$\geq 116$	$\leq 108$	109-115	$\geq 116$
Febrile convulsion	1	1	8	6	3	1
<i>Simple</i>	1	1	1	3	0	0
<i>Prolonged</i>	0	0	7	3	3	1
Status epilepticus	1	1	2	3	0	1
No history	3	1	1	5	0	0

Two children with lesional TLE had a history of a prolonged febrile convulsion or status epilepticus. One child had a history of a prolonged febrile convulsion and had T2 relaxation times of 108ms ipsilateral to the lesion and 104ms contralateral.

Histopathology revealed hippocampal sclerosis ipsilateral to the lesion. The child with a history of status epilepticus had T2 values of 112ms ipsilateral to the lesion and 109ms contralateral.

None of the 11 children with extratemporal epilepsy had a history of a febrile convulsion in early childhood. Five children had a history of one or more episodes of status epilepticus and/or epilepsia partialis continua. Four of the five children with abnormalities on T2 had a history of status or EPC. Of the four children who had a history of status, three had at least one abnormal T2 (two bilateral and one unilateral). Two children had epilepsia partialis continua at the time of investigation; both had abnormalities of at least one T2 value of the hippocampus, one unilateral and one bilateral.

For the whole group of children, no correlation was found between T2 and age of initial insult, age of onset of seizures, duration of epilepsy or seizure frequency. A relationship was seen between T2 and a history of early febrile convulsions (febrile convulsions vs no history  $p=0.008$ ) whereas there was no relationship between T2 and a history of status epilepticus (history vs no history  $p=0.46$ ).

#### ***4.9 Discussion***

T2 relaxometry provides a quantitative means of defining hippocampal abnormalities. In this group of children a high rate of abnormality was seen, particularly in those with nonlesional TLE (74%). In all children with nonlesional TLE where at least one T2 value was abnormal, the value was higher ipsilateral to the seizure focus. Using the lateralisation criteria described earlier, T2 was correctly lateralising in 58% and incorrectly lateralising in none. This technique therefore appears reliable in lateralisation of hippocampal abnormality in TLE of childhood.

T2 relaxometry has been shown in adults to detect hippocampal abnormality reliably with low interobserver variability (Jackson *et al.*, 1993a; Grunewald *et al.*, 1994). The technique allows an absolute value for each individual hippocampus to be obtained, and does not necessitate side to side comparison since data can be compared to a control reference range. It therefore provides additional information to visual analysis by reducing subjectivity and increasing sensitivity. This study has shown a good correlation between severely abnormal values and the finding of hippocampal sclerosis at pathology in children, as in adults (Jackson *et al.*, 1993a). Furthermore, the finding of a moderately abnormal T2 was also associated with pathology at surgery. Only one child who went on to surgery with a normal hippocampal T2 value had hippocampal sclerosis at pathology, and one further child with a normal T2 value had end plate gliosis. It has to be accepted that there are limitations to the technique; the slice as described was taken through the body of the hippocampus providing a single mean value, and may not demonstrate pathology if this is limited to the head. However the otherwise good correlation of T2 abnormality with hippocampal pathology would suggest that T2 relaxometry is reliable at the detection of hippocampal abnormality in children, with no false positives, and a useful tool in the preoperative evaluation of children with TLE.

Bilateral abnormalities of T2 were seen in 26% of children with nonlesional TLE. This is similar to findings in adult studies (29%) (Jackson *et al.*, 1993b) and confirms the presence of such abnormalities from an early age. None of the contralateral T2 values were in the severely abnormal range (>116ms). Bilateral HS has been seen in up to 30% of adults with epilepsy coming to post mortem (Margerison and Corsellis, 1966), although it was seldom symmetrical. Children in this study with ipsilateral T2 values in the range 110-



and Brown reported hippocampal cell loss in addition to foreign tissue lesions, but found it to be much less than that in true hippocampal sclerosis, and felt such degrees of cell loss would be difficult to detect without cell counts (Babb and Brown, 1987). Levesque et al found 54 of 178 patients (30.3%) who had undergone temporal lobectomy had extrahippocampal lesions in addition to neuronal loss within the hippocampus, with a greater severity of cell loss seen in those associated with heterotopia than those associated with tumours (Lévesque *et al.*, 1991). More recently, Mathern et al (Mathern *et al.*, 1996) measured neuronal densities in the hippocampi of children who had undergone surgery and showed the largest deficiency in those with seizures arising from the hippocampus. However, the abnormality was not so severe in temporal lobe epilepsy arising from outside the hippocampus, which was qualitatively different again from that seen in extratemporal epilepsy. These studies consistently suggest that hippocampal pathology is seen in association with extrahippocampal lesions, but that it is qualitatively different from hippocampal sclerosis seen in mesial temporal epilepsy. The data from this study of T2 relaxometry are in agreement with this. Pathologically a greater degree of hippocampal abnormality has been reported in association with dysplasia than tumours, but our results do not demonstrate a distinction between different pathologies. This may reflect the position of the slice along the hippocampus from which the T2 map is taken.

The aetiology of hippocampal sclerosis continues to cause debate. Initial reports suggested that hippocampal sclerosis was the result of hypoxic ischaemic injury, possibly perinatal (Cavanagh and Meyer, 1956; Meyer *et al.*, 1954). Falconer however recognised the high incidence of febrile convulsions in TLE patients coming to surgery (Falconer and Taylor, 1968). Meldrum later reproduced the pathology in baboons after 30 minutes status

115ms were demonstrated at pathology to have hippocampal sclerosis. Contralateral T2 values were also seen in this range. It is clearly not possible to obtain pathological correlates for contralateral hippocampi; however postoperative follow-up data should clarify the relationship of these contralateral abnormalities to outcome following surgery. Studies of adults following amygdalohippocampectomy have suggested that abnormality of the contralateral hippocampus as determined by T2 relaxometry is not related to outcome with regard to seizure freedom, but is related to cognitive function (Incisa della Rocchetta *et al.*, 1995)

A high rate of abnormality of T2 values of the hippocampus was also seen in lesional TLE, where the hippocampus is not assumed to be primarily involved in seizure onset. Seven of nine children (78%) had abnormal T2 values; these were lateralising in six with correct lateralisation in four and incorrect lateralisation in two. Where abnormality was seen it was not in the severely abnormal range. Furthermore, there was a tendency for abnormalities to be bilateral. This latter finding was also seen in the children with extratemporal epilepsy and, to a lesser extent, those with hemisyndromes. Several writers have commented on the existence of hippocampal changes in addition to extrahippocampal pathology both from MR (Raymond *et al.*, 1994a) and pathological studies (Babb and Brown, 1987; Fried *et al.*, 1992; Jay *et al.*, 1993; Lévesque *et al.*, 1991; Mathern *et al.*, 1996). Fried *et al.* reported on neuronal densities within the hippocampus in 17 patients who underwent temporal lobectomy for foreign tissue lesions (Fried *et al.*, 1992) and found significantly lower densities in all hippocampal fields compared to autopsy controls. Moreover, lower neuronal cell counts in all fields except CA2 were significantly related to younger age of seizure onset and medial extent of the lesion. Babb

epilepticus, and determined that it arose even when systemic factors such as acidosis, hypotension and hypoglycaemia were controlled for (Meldrum *et al.*, 1973). Despite the high frequency of febrile convulsions in adults coming to temporal lobe surgery, epidemiological studies initially suggested that there is no increased risk of having epilepsy following a simple febrile convulsion, but if prolonged (>30 minutes) then the risk rises to around 20% (Verity *et al.*, 1993). The data in this study demonstrate that a higher T2 value on one or both sides is associated with a history of febrile convulsions. The numbers are too small to isolate and analyse data separately in those with simple and those with prolonged febrile convulsions. However all children with nonlesional TLE with a history of prolonged febrile convulsions had a T2 value ipsilateral to the seizure focus of at least 116ms, whereas this was seen in only one of the three with a history of a simple febrile convulsion. Pathological studies have shown that more severe abnormality is seen where there is a history of an initial precipitating event (Mathern *et al.*, 1995a). Further work has suggested that the age of the initial insult is highly relevant with more severe hippocampal damage in those who had their first event under five years (Mathern *et al.*, 1995b). This current study found no such correlation, although numbers are small. It also showed no correlation with duration of epilepsy; this may be a reflection of the age of children under study as Mathern *et al.* found duration of epilepsy greater than 22 years to be associated with more severe neuronal loss (Mathern *et al.*, 1995b).

The findings of T2 relaxometry in extratemporal epilepsy in this study also raise further questions as to the aetiology of hippocampal abnormality associated with extrahippocampal pathology. It is not possible to determine from these studies whether such damage is primary (as part of more widespread disease) or secondary, but the T2

findings raise the possibility of the latter, perhaps as a result of continuing seizures arising from elsewhere in the brain other than the hippocampus. The low incidence of febrile seizures in subjects with extratemporal epilepsy within this and other studies (Van Paesschen *et al.*, 1997b) implies that a predisposition to prolonged febrile seizures from associated extrahippocampal lesions seems unlikely. The lack of correlation between grade of extratemporal cortical dysplasia and hippocampal pathology would argue against the latter being part of a developmental syndrome (Mathern *et al.*, 1996), as would the low incidence of HS amongst adults with newly diagnosed partial epilepsy (Van Paesschen *et al.*, 1997b). The qualitative difference between primary hippocampal sclerosis and hippocampal damage in association with other pathology suggests different aetiological factors (Babb and Brown, 1987; Mathern *et al.*, 1996). The question therefore remains as to whether the lesions are congenital or acquired postnatally.

The findings of hippocampal damage in association with other lesions and extratemporal epilepsy, and of bilateral hippocampal damage in temporal lobe epilepsy, are relevant in discussions about postoperative outcome. However, as yet follow-up is too short and numbers too small to draw any conclusions about this from current data. Nevertheless, the presence of hippocampal pathology in addition to the primary pathology, if associated with an increase in the risk of seizures postoperatively, could have a bearing on such arguments as lesionectomy vs temporal lobectomy (including mesial structures) with regard to temporal tumours.

## APPENDIX

**Table A4.1 Clinical details, MRI and results of T2 relaxometry in children with nonlesional temporal lobe epilepsy**

Patient	FC(P) (Age, months)/SE	Age first seizure	Age at scan	Duration of epilepsy	Seizure frequency (/month)	Clinical/ EEG focus	MRI	T2 (ms)		Pathology (if surgery)
								Ipsi	Contra	
T1	N	1yr 6m	16yr 5m	15yr	1	L TLE	LHS	120	105	Ammon's horn sclerosis
T2	SE	6yr 10m	7yr 11m	1yr 1m	60	L TLE	LHA	125	106	Rasmussens
T3	SE	3m	10yr 5m	10yr 2m	30	L TLE	LHS + signal change L temporal lobe	121	116	Ammon's horn sclerosis
T4	PFC (13)	2yr	13yr	12yr 8m	30	L TLE	LHS + signal change L temporal lobe	123	111	Ammon's horn sclerosis
T5	FC (10)	2yr	16yr	14yr	4	L TLE	LHS + signal change L temporal lobe	111	99	Ammon's horn sclerosis
T6	PFC (10)	9yr	17yr 9m	8yr 9m	8	L TLE	LHS	128	106	Ammon's horn sclerosis
T7	FC (12)	9yr 5m	16yr 1m	6yr 7m	0	R TLE	Normal	108	108	
T8	N	5yr	9yr 7m	4yr 7m	2	L TLE	Normal	110	107	End plate gliosis
T9	N	2yr 4m	11yr 8m	9yr 4m	60	L TLE	LHA	103	103	
T10	PFC (10)	7yr 3m	14yr	6yr 9m	5	R TLE	RHS	130	106	Ammon's horn sclerosis
T11	PFC (13)	1yr 6m	10yr	9yr 6m	12	L TLE	LHS + signal change L temporal lobe	128	108	
T12	FC (10)	1yr 6m	10yr 7m	9yr 1m	10	L TLE	LHS + signal change L temporal lobe	125	102	Ammon's horn sclerosis
T13	N	1yr	9yr 7m	8yr 7m	60	R TLE	R temporal gliosis	103	104	
T14	N	5m	8yr 2m	7yr 9m	30	L TLE	Thickened parietal cortex & L temporal atrophy	104	104	Ammon's horn sclerosis + microdysgenesis
T15	PFC (6)	1yr	12yr 8m	11yr 8m	9	L TLE	LHS	116	112	
T16	PFC (7)	7m	11yr	10yr 5m	10	R TLE	RHS + R hemiatrophy	129	110	Ammon's horn sclerosis
T17	PFC(24)	2yr 6m	9yr 1m	6yr 7m	2	L TLE	LHS + L temporal atrophy	118	117	
T18	SE	6m	4yr 11m	4yr 5m	20	R TLE	Normal	101	101	Cortical dysplasia
T19	SE	8yr 9m	12yr 8m	3yr 11m	5	L TLE	LHS	115	104	Ammon's horn sclerosis

**Table A4.2: Clinical details, MRI and results of T2 relaxometry in children with lesional temporal lobe epilepsy**

Patient	FC(P) (Age, months)/SE	Age first seizure	Age at scan	Duration of epilepsy	Seizure frequency (/month)	Clinical/ EEG focus	MRI	T2 (ms)		Pathology (if surgery)
								Ipsi	Contra	
T26	N	12yr 6m	15yr 9m	3yr 3m	150	L TLE	FTL L middle temporal gyrus	107	106	Low grade gliom
T27	N	5yr 9m	6yr 8m	11m	16	R TLE	R temporal FTL +RHS	125	110	Hamartoma + AHS
T28	N	3yr	9yr 9m	6yr 9m	2	L TLE	L temporal FTL	106	110	DNET
T29	N	6yr	15yr 4m	9yr 3m	6	L TLE	L mesial temporal FTL	111	110	DNET
T30	N	3wks	3yr	2yr 11m	150	L TLE	FTL L ant/inf temporal lobe	105	112	Glial hamartoma
T31	N	6yr 8m	7yr 8m	1yr	250	R TLE	FTL both hemispheres +RHS	121	112	DNET
T32	PFC (12)	7yr	12yr 8m	5yr 8m	30	L TLE	L mesial temporal FTL +LHS	108	104	DNET + AHS
T33	N	5yr	10yr 7m	5yr 7m	2	TLE	L mesial temporal FTL	110	110	DNET
T34	SE	3m	4yr 8m	4yr 5m	180	TLE	FTL R temporal lobe + RHS	112	109	Microdysgenesis + AHS

**Table A4.3 : Clinical details, MRI and results of T2 relaxometry in children with extratemporal epilepsy**

Patient	FC(P)/SE	Age first seizure	Age at scan	Duration of epilepsy	Seizure frequency (/month)	Clinical/ EEG focus	MRI	T2 (ms)		Pathology (if surgery)
								Ipsi	Contra	
E1	N	3yr	15yr 7m	12yr 6m	8	R frontal	Normal	109	106	
E2	SE	11m	8yr 4m	7yr 5m	4	R frontal	R frontal cortical dysplasia	110	115	Frontal cortical dysplasia
E3	N	2yr	12yr 7m	10yr 7m	12	R frontal	General cytoarchitectural change	103	102	
E4	N	8m	3yr 5m	2yr 9m	300	R frontal	Normal	111	108	
E5	N	7yr 10m	8yr 4m	6m	120	R frontal	Normal	105	107	
E6	EPC	4yr	8yr 11m	4yr 11m	EPC	R frontal	R parieto-occipital atrophy & signal change	105	109	
E7	N	5yr	12yr 4m	7yr 4m	30	L frontal	L frontal FTL	101	105	Frontal DNET
E8	SE	6m	4yr 4m	3yr 10m	100	L parietal	LHS	125	112	
E9	SE	8yr	14yr 10m	7yr 10m	6	R frontoparietal	General cytoarchitectural change	106	106	
E10	EPC	4yr	12yr 6m	8yr 6m	EPC	R frontal	Atrophy/signal change R occipitoparietal junction+RHS	125	112	

**Table A4.4 : Clinical details, MRI and results of T2 relaxometry in children with hemisindrome epilepsy**

Patient	FC(P)/SE	Age first seizure	Age at scan	Duration of epilepsy	Seizure frequency (/month)	Clinical/ EEG focus	MRI	T2 (ms)		Pathology (if surgery)
								Ipsi	Contra	
H1	EPC	3yr 7m	3yr 11m	4m	EPC	L frontocentral	L parietal signal + LHS	115	115	Rasmussens encephalitis
H2	SE	8yr	13yr 1m	6yr 1m	60	Right	R hemiatrophy + RHS	98	100	Rasmussens encephalitis + AHS
H3	N	2yr	8yr 9m	6yr 9m	35	Left	L MCA infarct + L hemiatrophy	121	110	MCA infarct
H4	N	3yr 4m	7yr 9m	4yr 3m	210	Left	Encephalomalacia + LHS	110	108	Infarct
H5	SE	3d	4yr 3m	4yr 3m	150	Right	R hemimegalencephaly	115	100	Hemimegalencephaly inv hippocampus
H6	N	1yr 9m	4yr 11m	3yr 2m	60	Left	L hemiatrophy with signal change	107	102	
H7	SE	2yr 6m	13yr 10m	7yr 10m	170	Right	R MCA infarct + RHS	113	111	Infarct

**Table A4.5: Clinical details, MRI and results of T2 relaxometry in children with clinically unlocalised epilepsy**

Patient	FC(P) (Age, months)/SE	Age first seizure	Age at scan	Duration of epilepsy	Seizure frequency (/month)	Clinical/ EEG focus	MRI	T2 (ms)		Pathology (if surgery)
								Ipsi	Contra	
U1	N	5wks	5yr 8m	5yr 6m	150	Unlocalised	R temporal atrophy	118	112	Cortical dysplasia, hippocampus normal
U2	PFC (8)	6m	5yr 5m	4yr 11m	150	Unlocalised	L temporal arachnoid cyst + hypoplasia	121	117	Arachnoid cyst + AHS
U3	N	11m	5yr 6m	4yr 7m	90	Unlocalised	R temporal FTL	118	111	DNET, no hippocampus



# CHAPTER 5

## PROTON MAGNETIC RESONANCE SPECTROSCOPY

---

### Contents

#### *5.1 Introduction*

#### *5.2 Methods*

#### *5.3 Control data*

#### *5.4 Patient population*

#### *5.5 Data analysis*

#### *5.6 Results*

##### *5.6.1 Temporal lobe epilepsy*

##### *5.6.2 Repeated studies*

##### *5.6.3 Extratemporal epilepsy*

#### *5.7 Comparison of $^1\text{H}$ MRS and T2 relaxometry*

##### *5.7.1 Temporal lobe epilepsy*

##### *5.7.2 Extratemporal epilepsy*

#### *5.8 Discussion*

---

### *5.1 Introduction*

In magnetic resonance, the resonance frequency of any nucleus is proportional to the local magnetic field that it experiences. The local field is influenced by the electrons within the vicinity of a nucleus, and therefore the resonance frequencies of individual nuclei depend on their chemical environment. The relative shift of resonance frequencies in different chemical environments is termed chemical shift and is expressed as dimensionless units of parts per million. Magnetic resonance spectroscopy (MRS) enables the detection of signals from nuclei within different compounds, and therefore provides a means of detecting chemical abnormalities in tissue.  $^{31}\text{P}$  and  $^1\text{H}$  are the nuclei that have been most

widely used in clinical studies in view of their high natural abundance and relatively high sensitivity.

Phosphorus magnetic resonance spectroscopy ( $^{31}\text{P}$  MRS) was originally of particular interest in view of its ability to monitor energy metabolism, by detection of signals from ATP, phosphocreatine (PCr) and inorganic phosphate (Pi). Studies initially concentrated on muscle, but later it was evident that useful cerebral changes could be seen in hypoxic ischaemic encephalopathy in neonates (Cady *et al.*, 1983; Hope *et al.*, 1984; Younkin *et al.*, 1994). A fall in energy status can be demonstrated in the brain of affected infants, seen predominantly as a fall in the PCr/Pi ratio. This has been correlated with neuro-developmental outcome (Roth *et al.*, 1992).  $^{31}\text{P}$  MRS studies have also been performed in a small number of adults with temporal (Hugg *et al.*, 1992; Kuzniecky *et al.*, 1992) and frontal lobe (Garcia *et al.*, 1994; Laxer *et al.*, 1992) epilepsy, but results have been inconsistent. An increased inorganic phosphate has been demonstrated on the side of the seizure focus in TLE (Hugg *et al.*, 1992; Kuzniecky *et al.*, 1992), but no such change has been found in frontal lobe epilepsy (Garcia *et al.*, 1994). Furthermore, one group has demonstrated an increase in pH and decreased phosphomonoester ipsilateral to the seizure focus in temporal and frontal lobe epilepsy (Garcia *et al.*, 1994; Hugg *et al.*, 1992) but this was not confirmed in TLE by a second group (Kuzniecky *et al.*, 1992).

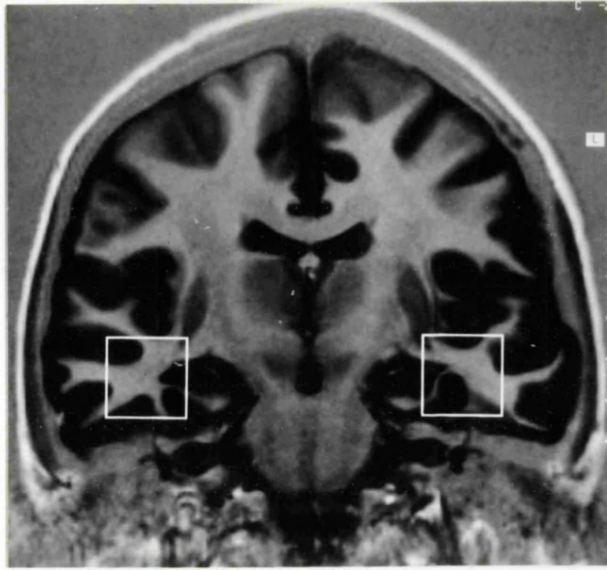
Although it initially posed more technical difficulties than  $^{31}\text{P}$  MRS, proton magnetic resonance spectroscopy ( $^1\text{H}$  MRS) is now used extensively for the study of brain tissue.  $^1\text{H}$  MRS has higher sensitivity than  $^{31}\text{P}$ , and this higher sensitivity is exploited to obtain spectra from smaller volumes. The metabolites of interest are present at very much lower

concentrations than water, and for this reason the water, and (to a much lesser degree in the brain) fat, need to be suppressed in order to be able to detect the metabolites of signals.

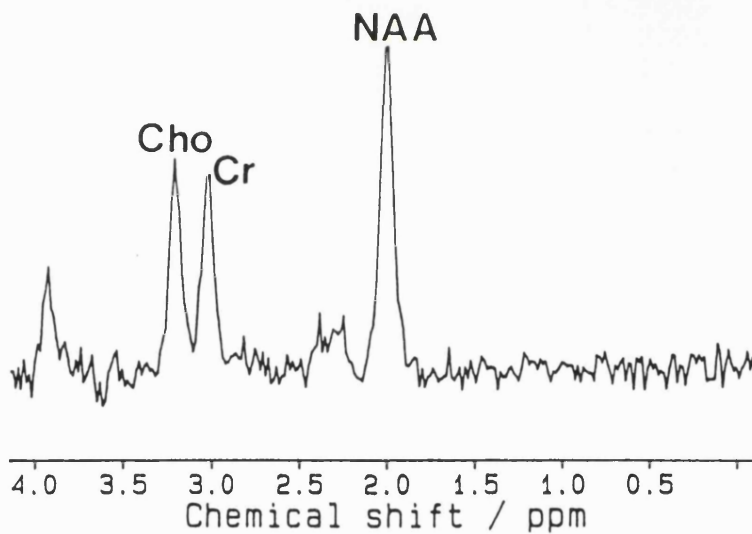
An example of a  $^1\text{H}$  MR spectrum from the brain is shown in Fig. 5.1. The dominant contributions to the spectrum are from N-acetylaspartate (NAA) at 2.0ppm, creatine + phosphocreatine (Cr) at 3.0ppm and choline-containing compounds (Cho), phosphoryl- and glycerophosphorylcholine seen at 3.2ppm. NAA has been shown from lesional (Koller *et al.*, 1984), tumour (Sutton *et al.*, 1992) and cell culture (Urenjak *et al.*, 1992; Urenjak *et al.*, 1993) studies to be located primarily in neurons, and although also found in high quantities in oligodendrocyte type II astrocyte progenitor cells, it is thought to be a marker of neuronal integrity (Urenjak *et al.*, 1992; Urenjak *et al.*, 1993). Cr and Cho are found both in neurons and astrocytes, although cell studies suggest that they are present in higher concentrations in astrocytes (Urenjak *et al.*, 1993).

Proton MRS has been investigated in adults with temporal and frontal lobe epilepsy (Cendes *et al.*, 1994; Connelly *et al.*, 1994; Cook *et al.*, 1991; Gadian *et al.*, 1994; Garcia *et al.*, 1995; Hugg *et al.*, 1993; Ng *et al.*, 1994; Ende *et al.*, 1997). Frontal lobe studies have been performed on a small number of patients; single voxel techniques detected no significant abnormalities (Cook *et al.*, 1991) whereas chemical shift imaging (CSI), recording data from multiple voxels within a slab of tissue in eight patients, demonstrated a reduction in the NAA/Cr ratio of between 5-30% ipsilateral to the seizure focus (Garcia *et al.*, 1995).

A



B



**Figure 5.1: Coronal magnetic resonance image (A) and a  $^1\text{H}$  spectrum (B) from a normal subject. The boxes indicate the position of the 8ml cubic volume of interest from which spectra were obtained. The dominant contributions to the spectrum are from N-acetylaspartate (NAA), creatine plus phosphocreatine (Cr), and choline containing compounds (Cho). The  $\text{NAA}/(\text{Cho}+\text{Cr})$  ratio was 0.91.**

In adults with TLE, a reduction in NAA ipsilateral to the seizure focus, suggestive of neuronal loss or dysfunction, has been shown to aid in lateralisation. In addition, some studies have shown a high frequency of bitemporal abnormalities (Connelly *et al.*, 1994; Ng *et al.*, 1994). The single voxel technique used for the studies described in this chapter uses 2x2x2cm regions that include a substantial portion of the mesial temporal regions with only a minor contribution from the hippocampus (Fig 5.1). It may be considered therefore to complement focal information obtained about the hippocampus from T2 relaxometry. The purpose of the part of this study described in this chapter was to determine the incidence of abnormalities as detected by single voxel <sup>1</sup>H MRS of the mesial temporal lobes in children with nonlesional TLE (as defined in Section 4.5.1), to determine whether a similar degree of abnormality was found to that reported in adults, and to investigate the role of <sup>1</sup>H MRS data in lateralisation. The study was extended to address the question of whether abnormalities of <sup>1</sup>H MRS of the mesial temporal regions were seen in extratemporal epilepsy.

## **5.2 Methods**

Spectra were obtained from 2x2x2cm cubes centred on the medial portions of the right and left temporal lobes, as shown in Fig. 5.1. Spatial localisation was achieved using a 90°-180°-180° spin echo technique, with three selective radiofrequency pulses applied in the presence of orthogonal gradients of 2mT/m. Water suppression was achieved by pre-irradiation of the water resonance using a 90° Gaussian pulse with a 60Hz bandwidth, followed by a spoiler gradient. TR was 1600ms and TE 135ms. After global and local shimming, and optimization of the water suppression pulse, data were collected in 2-4 blocks of 128 scans. The time domain data were corrected for eddy-current induced phase

modulation using non-water-suppressed data as a reference (Klose, 1990). Exponential multiplication corresponding to 1-Hz line broadening was carried out prior to Fourier transformation, and a cubic spline baseline correction was performed.

Signal intensities for each of the relevant compounds demonstrated in Fig. 5.1 were measured from the peak areas by integration. The effects of T1 and T2 relaxation were not determined, and therefore it was not possible to convert these intensities to concentration measurements. However, by multiplying the observed signal intensities by the 90° pulse voltage, it was possible to compensate for differences in radiofrequency coil loading (Austin *et al.*, 1991; Hoult and Richards, 1976) and thereby to compare absolute signal intensities between different subjects. The intensity ratio is dimensionless by definition, while the absolute intensities are given in arbitrary units that reflect the settings of the magnetic resonance system used. Data are presented in the form of these corrected signal intensities, and also in terms of the intensity ratio  $NAA/(Cho+Cr)$ . Choice of this particular ratio is based partly on the observation that the group data show a significant mean decrease in NAA and increases in the Cr and Cho signals. In addition, in the temporal lobe it is difficult in some cases to achieve full spectral separation of the Cr and Cho signals due to particular problems with magnetic field inhomogeneity in this region. The  $NAA/(Cho+Cr)$  ratio is unaffected by this latter problem.

### **5.3 Control data**

The 95% reference range for the  $NAA/(Cho+Cr)$  ratio was determined using log transformed data from 13 normal subjects (age range 19 - 42 years, mean 30 years) (Connelly *et al.*, 1994). For the determination of the reference range, one data point was

used for each control subject, calculated as the mean of the ratios obtained from the two temporal lobes. This avoided the assumption that the temporal lobes in each control subject provided independent data. The lowest value of NAA/(Cho+Cr) seen in any of the controls was 0.72 and this was also the lower limit of the 95% reference range derived from the control data. Values below 0.72 were therefore considered to be abnormally low.

As highlighted in Section 4.3, magnetic resonance control data are difficult to obtain in children. However, spectra were obtained from the mesial temporal lobes of one normal eight year old girl whose values for NAA/(Cho+Cr) are 0.74 and 0.87, and children of age five years with conditions including epilepsy have been demonstrated to have NAA/(Cho+Cr) ratios from the mesial temporal lobes within the adult range. Studies of basal ganglia and occipital white matter have demonstrated NAA/Cho and NAA/Cr to increase with age, while Cho/Cr decreases, primarily as a result of an increase in NAA and decrease in Cho. Most of these changes appear to have been complete by three years of age (Connelly *et al.*, 1990; Connelly *et al.*, 1991; Kreis *et al.*, 1993; van der Knaap *et al.*, 1990). As age-related changes are predominantly complete by the age of three years, in conjunction with the results in the few normal individuals quoted above, it was felt appropriate in this study to apply the adult control data to children over the age of five years.

#### **5.4 Patient population**

Twenty nine children (16 female) were included in this part of the study, 20 with nonlesional TLE and nine with extratemporal epilepsy (as defined in Section 2.4.1 ). The children were of mean age 11 years 5 months (range 4 years 11 months -to-17 years 8

months) with a mean age of onset of epilepsy of 4 years 1 month (range 3m to 14 years). Eleven of the 20 children with TLE had repeat  $^1\text{H}$  MRS of the contralateral temporal lobe 6 to 12 months after temporal lobectomy

### **5.5 Data analysis**

Multiple Student's t tests (two tailed) were used for comparisons between patients and normal subjects, and between ipsilateral and contralateral data. Paired Student's t tests were used for analysis of pre- and post- surgical repeat data. In the children with TLE, the NAA/(Cho+Cr) ratio was considered to be lateralising only if it was i) abnormally low, and also ii) lower than on the contralateral side by more than 0.05. Although this latter value is somewhat arbitrary, used on an adult group of patients it was felt that these two criteria provided a reasonable basis for assessing abnormalities and for lateralisation (Connelly *et al.*, 1994).

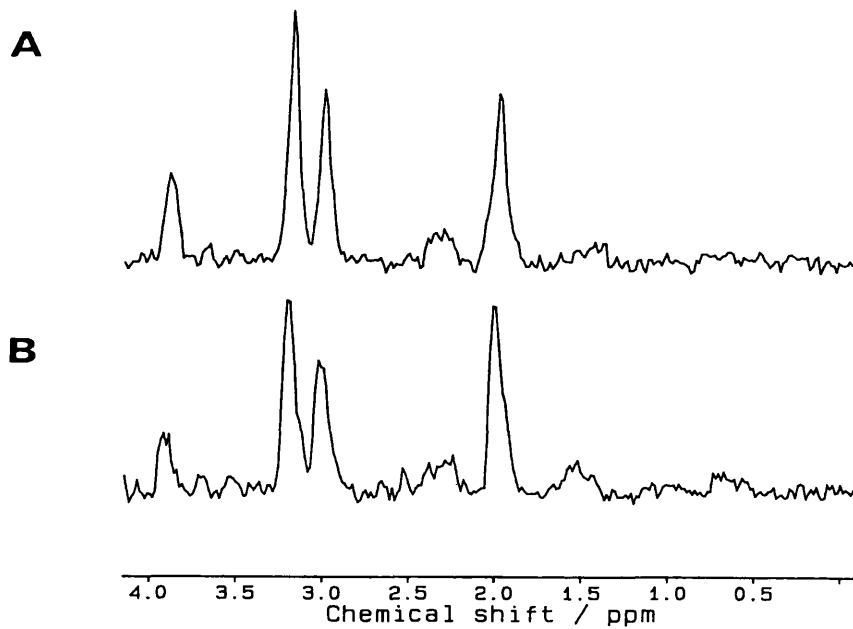
### **5.6 Results**

#### **5.6.1. Temporal lobe epilepsy**

$^1\text{H}$  spectra were obtained from 40 temporal lobes of 20 study patients (see Appendix) (Fig 5.2) and the results compared with those obtained from 13 normal adults. Mean values for the signal intensities NAA, Cho and Cr were obtained from the control data as well as a mean value for NAA/(Cho+Cr) (Table 5.1). The absolute signal intensity data from the patient studies indicated that NAA was significantly reduced on the ipsilateral side compared to both the contralateral side ( $p=0.02$ ) and normals ( $p=0.001$ ). Overall there was a mean decrease of 19% on the ipsilateral side and a mean decrease of 5% on the



contralateral side ( $p=0.31$ ) when compared to the normal data. Cho and Cr were significantly increased bilaterally when compared to control data with a mean increase of 20% ( $p=0.03$ ) and 16% ( $p=0.05$ ) respectively ipsilateral to the seizure focus and 18% ( $p=0.002$ ) and 18% ( $p=0.04$ ) on the contralateral side (Table 5.1).



**Figure 5.2:**  $^1\text{H}$  spectra from patient T24 who had a clinical right temporal lobe focus. The NAA/(Cho+Cr) ratio on the right (A) was 0.44 and on the left 0.52 (B).

**Table 5.1: Relative mean percentage change in absolute intensity data.**

	Ipsilateral vs Control	Contralateral vs Control
NAA decreased	19%	5%
Cho increased	20%	18%
Cr increased	16%	18%

**Table 5.2: Mean signal intensities for 13 controls and 20 patients. The number in brackets refers to the standard deviation. Patient data are grouped with respect to the clinical/EEG seizure focus.**

	Control	Ipsilateral	Contralateral
NAA	18.4 (2.6)	14.6 (3.8)	17.3 (3.2)
Cho	10.6 (1.6)	12.8 (3.7)	12.6 (2.1)
Cr	9.7 (1.7)	11.1 (3.1)	10.9 (2.5)
NAA/Cho+Cr	0.92 (0.16)	0.62 (0.12)	0.74 (0.14)

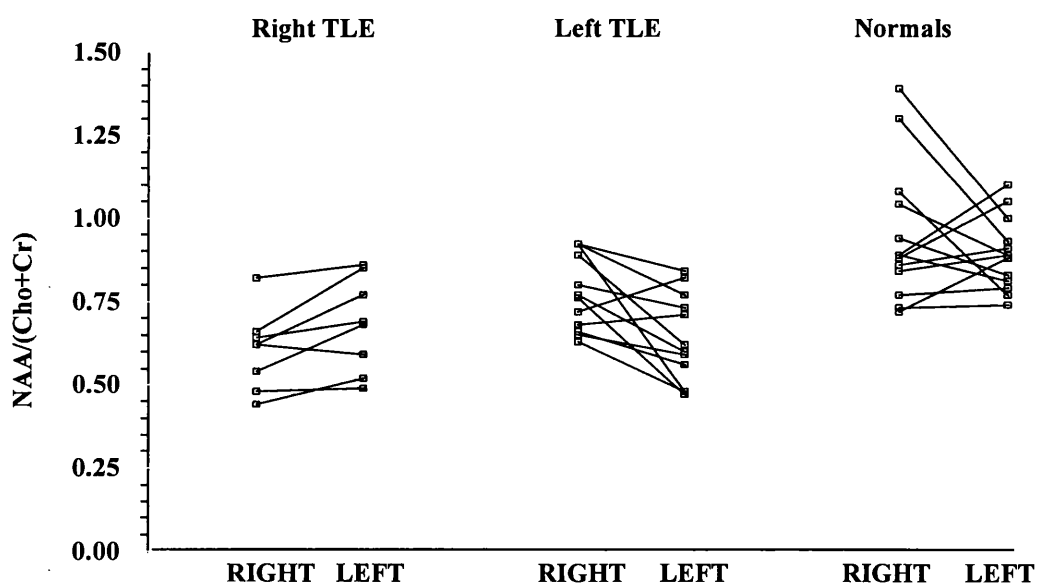
In addition, the group data indicated that NAA/(Cho+Cr) was significantly reduced on the side ipsilateral to the seizure focus when compared to the contralateral side, but both sides were significantly reduced when compared to control data (see Table 5.2).

**Table 5.3: Lateralisation of the seizure focus**

NAA/(Cho+Cr)	N	Correctly Lateralising	Incorrectly Lateralising	Not Lateralising
Unilaterally low	6	6	0	0
Bilaterally low	9	5	0	4
Bilaterally normal	5	0	0	5

The NAA/(Cho+Cr) data from individual patients were also analysed with respect to the normal data, in particular to determine the contribution of such data to lateralisation of the seizure focus (Fig. 5.3 and Table 5.3). Abnormalities of NAA/(Cho+Cr) ratio were seen in 15 of the children in this study; bilateral abnormalities were seen in nine and unilateral abnormalities in six. Using the criteria described in Section 5.5 the NAA/(Cho+Cr) was

lateralising in 11 cases; this was ipsilateral to the clinical seizure focus in all cases. In one child, magnetic resonance imaging appeared normal. Of the remaining nine children, NAA/(Cho+Cr) was bilaterally normal in five. Four of these children showed unilateral hippocampal sclerosis and one child had normal MRI. Four children had bilaterally abnormal values for NAA/(Cho+Cr) but with  $<0.05$  difference between the two sides. All four of these children showed unilateral hippocampal sclerosis on MRI.



**Figure 5.3: Individual right and left NAA/(Cho+Cr) ratios in children with right TLE and left TLE compared to normal subjects**

### 5.6.2. Repeated studies

Three children with TLE had repeat  $^1\text{H}$  MRS of the mesial temporal regions two years after the first study; two as part of re-evaluation for surgery and one after a two year period seizure free (Table 5.4). The former two on initial examination had bilaterally abnormal values that were nonlateralising. On repeat examination, both had values that were unilaterally abnormal and correctly lateralising. The third child on first and second examination had unilaterally low NAA/(Cho+Cr) that was correctly lateralising on both occasions.

**Table 5.4:  $^1\text{H}$  MRS data on three children who underwent repeat studies two years apart**

	NAA/(Cho+Cr) First examination		NAA/(Cho+Cr) Second examination	
	Right	Left	Right	Left
<b>Case T10</b>	0.64	0.69	0.71	0.83
<b>Case T11</b>	0.76	0.47	0.84	0.67
<b>Case T25</b>	0.62	0.59	0.6	0.88

**Table 5.5: Results of  $^1\text{H}$  MRS of mesial temporal regions contralateral to the seizure focus pre and post-operatively in eleven patients who underwent surgery.**

	Control	Preoperative	Postoperative
<b>NAA</b>	18.4 (2.6)	17.5 (3.4)	20.1 (4.5)
<b>Cho</b>	10.6 (1.6)	12.6 (2.5)	12.9 (3.0)
<b>Cr</b>	9.7 (1.7)	10.9 (2.6)	11.1 (3.2)
<b>NAA/(Cho+Cr)</b>	0.92 (0.16)	0.73 (0.11)	0.8 (0.15)

Eleven children underwent repeat  $^1\text{H}$  MRS of the side contralateral to the seizure focus between six and twelve months after temporal lobectomy (Table 5.5). Reviewing the group data, there was no significant difference in absolute intensity data of Cho, Cr or NAA, or in  $\text{NAA}/(\text{Cho}+\text{Cr})$  ( $p=0.06$ ) before and after surgery over this period of time. On review of the individual signal intensity data, Cho and Cr were increased preoperatively above the mean in five and three children respectively, and reduced postoperatively in two each. Seven children had an NAA signal intensity below the mean preoperatively, which increased postoperatively in six. These six remain seizure free at present, 2 years 5 months to 4 years 11 months (mean 3 years 6 months) post surgery whereas the seventh child with no increase continues to have seizures.

### ***5.6.3. Extratemporal epilepsy***

$^1\text{H}$  spectra were obtained from 18 temporal lobes of 9 patients with extratemporal epilepsy and the results compared with those obtained from 26 temporal lobes from 13 normal adults (Table 5.6). Group data showed no significant increase or decrease in NAA, Cho, Cr or  $\text{NAA}/(\text{Cho}+\text{Cr})$  ipsilateral or contralateral to the seizure focus compared to controls, with no significant difference between the two sides. However, abnormally low  $\text{NAA}/(\text{Cho}+\text{Cr})$  ratios were seen in three of the nine children; they were unilaterally abnormal in all, ipsilateral to the seizure focus in two and contralateral in one. Two of these three children (one with an ipsilateral and one a contralateral low ratio) had *epilepsia partialis continua* at the time of examination, with presumed Rasmussen's encephalitis, a progressive inflammatory condition, as the underlying aetiology. The third child had a clinical right frontal focus with normal magnetic resonance imaging.

**Table 5.6 :Absolute intensity data for NAA, Cho and Cr ipsilateral and contralateral to the seizure focus in extratemporal epilepsy compared to controls.**

	<b>Control</b>	<b>Ipsilateral</b>	<b>Contralateral</b>
<b>NAA</b>	18.4 (2.6)	17.3 (4.1)	17.6 (3.2)
<b>Cho</b>	10.6 (1.6)	11.1 (2.5)	11.4 (2.4)
<b>Cr</b>	9.7 (1.7)	9.8 (2.6)	10.4 (3.2)
<b>NAA/Cho+Cr</b>	0.92 (0.16)	0.84 (0.2)	0.83 (0.2)

### **5.7 Comparison of <sup>1</sup>H MRS with T2 relaxometry**

#### **5.7.1 Temporal lobe epilepsy**

T2 relaxometry and <sup>1</sup>H MRS as described above provide information from different anatomical regions; T2 relaxometry specifically about the hippocampus and <sup>1</sup>H MRS a wider area of the mesial temporal lobe. Fourteen children with nonlesional TLE underwent T2 relaxometry as well as <sup>1</sup>H MRS of the mesial temporal regions ; seven had bilaterally abnormal NAA/(Cho+Cr) ratios, four had unilaterally abnormal ratios and three were normal (see Table 5.7). Of the seven who had bilaterally abnormal values, three had unilaterally high T2 values, three bilateral abnormalities (with none of these six showing discordant lateralisation) and one bilaterally normal T2 values. Of the four who had unilaterally low NAA/(Cho+Cr), three had unilaterally high T2 of the hippocampus and one bilaterally abnormal T2. Of the three with bilaterally normal <sup>1</sup>H MRS, two had unilaterally abnormal T2 relaxometry of the hippocampus (110ms and 111ms) and one bilaterally normal T2 values. Therefore only in a very small number of children was abnormality localised to the hippocampus, more commonly it was seen over a wider area of the temporal lobe.

**Table 5.7: Comparison of <sup>1</sup>H MRS and T2 relaxometry in temporal lobe epilepsy**

<sup>1</sup> H MRS	T2 relaxometry			Total
	Bilaterally normal	Unilaterally abnormal	Bilaterally abnormal	
Bilaterally normal	1	2	0	3
Unilaterally abnormal	0	3	1	4
Bilaterally abnormal	1	3	3	7
<b>Total</b>	<b>2</b>	<b>8</b>	<b>4</b>	<b>14</b>

**5.7.2 Extratemporal epilepsy**

<sup>1</sup> H MRS	T2 relaxometry			Total
	Bilaterally normal	Unilaterally abnormal	Bilaterally abnormal	
Bilaterally normal	4	0	1	5
Unilaterally abnormal	0	2	1	3
Bilaterally abnormal	0	0	0	0
<b>Total</b>	<b>4</b>	<b>2</b>	<b>2</b>	<b>8</b>

**Table 5.8: Comparison of <sup>1</sup>H MRS and T2 relaxometry in extratemporal epilepsy**

Eight children with extratemporal epilepsy underwent both T2 relaxometry of the hippocampi and <sup>1</sup>H MRS of the mesial temporal regions (Table 5.8). <sup>1</sup>H MRS was bilaterally normal in five children, and unilaterally abnormal in three. T2 relaxometry was normal in four and abnormal in four (two bilateral, two unilateral). Of the five with bilaterally normal <sup>1</sup>H MRS, four had bilaterally normal T2 of the hippocampi and one bilaterally abnormal values. Of the three with unilateral abnormalities of <sup>1</sup>H MRS, two

had unilaterally abnormal T2 on the same side as the abnormal  $^1\text{H}$  MRS, and one bilaterally abnormal T2, lateralising to the same side as the  $^1\text{H}$  MRS abnormality.

### **5.8 Discussion**

In the 20 children with temporal lobe epilepsy, abnormalities were seen in the absolute intensities of the NAA, Cho and Cr signals, as well as in the signal intensity ratio NAA/(Cho+Cr). There was a 19% reduction in the NAA signal intensity ipsilateral to the seizure focus compared to normal data, with no significant reduction on the contralateral side. Animal and cell culture studies suggest that N-acetylaspartate is present predominantly in neurons (Koller *et al.*, 1984; Urenjak *et al.*, 1992). Therefore these results suggest neuronal loss or dysfunction, particularly on the ipsilateral side.

The NAA/(Cho+Cr) ratio was chosen as a simple index of spectral abnormality and of lateralisation. This ratio showed abnormalities in 15/20 (75%) children with temporal lobe epilepsy with correct lateralisation of the seizure focus in 55% of the children and incorrect lateralisation in none. This suggests that  $^1\text{H}$  MRS could provide additional information about mesial temporal abnormality to that obtained from visual inspection of images and T2 relaxometry. One child in this study had abnormal  $^1\text{H}$  MRS ratios that were lateralising in the absence of any imaging abnormality. Furthermore, comparison of  $^1\text{H}$  MRS and T2 relaxometry in children who underwent both studies revealed only two children where the abnormality was localised to the hippocampus alone. The hippocampus occupies only a small proportion of the 8ml region of interest used in this study (see Fig 5.2), which includes a substantial proportion of neocortex and white matter.  $^1\text{H}$  MRS is therefore providing evidence of more diffuse abnormalities which extend beyond



the focal lesions demonstrated on MRI. The term 'mesial temporal sclerosis' was originally employed as it was recognised that changes were consistently seen in nonlesional TLE of mesial temporal structures outside the hippocampus, and this has been confirmed by this study. In addition, this suggests evidence of the so-called 'dual pathology' advocated to be common in children (Jay *et al.*, 1993).

Bilateral abnormalities were shown in 45% of the children with TLE. This is a similar percentage to that found in adult studies (40%, (Connelly *et al.*, 1994); 42%, (Ng *et al.*, 1994)) and emphasises the early presence of such abnormalities. The rate was also higher than that found on T2 relaxometry (26%), suggesting changes to the temporal neocortex and white matter rather than to the hippocampus. As a group a significant increase was seen in both Cho and Cr bilaterally, whereas a decrease in NAA was only seen ipsilateral to the seizure focus. The concentrations of creatine + phosphocreatine and of choline-containing compounds are higher in astrocyte and oligodendrocyte cell preparations than in cerebellar granule neurons (Urenjak *et al.*, 1993). It is therefore possible that any increase in Cho and Cr may reflect reactive astrocytosis. The relationship of contralateral pathology to postoperative outcome is not clear. However, a group of 34 adults who had undergone temporal resection demonstrated an incidence of abnormality on <sup>1</sup>H MRS on the unoperated side (50%) (Incisa della Rocchetta *et al.*, 1995) similar to that (40-45%) of bilateral pathology shown both here and in adult <sup>1</sup>H MRS studies performed preoperatively (Connelly *et al.*, 1994; Ng *et al.*, 1994). In the post-operative study (Incisa della Rocchetta *et al.*, 1995) no relationship was seen between the abnormalities on the unoperated side and seizure outcome, although there was a relationship to cognitive outcome. The high rate of bilateral abnormalities and the good seizure outcome in many

such patients following surgery suggest that spectral abnormalities occur frequently in nonepileptogenic mesial temporal structures; their exact relationship to epileptogenesis remains unclear. This emphasises the importance of obtaining some form of functional ictal information, as will be discussed in later sections.

A small number of children underwent repeat  $^1\text{H}$  MRS of the mesial temporal regions; eleven underwent MRS of the temporal lobe contralateral to the seizure focus following ipsilateral temporal lobe surgery, and three had MRS of both temporal lobes two years following the first examination. Although numbers are small, the data from the three children with repeat bilateral studies showed change over time. Furthermore, although the group data a short time after surgery do not show a significant change, review of individual signal intensities suggest that there may be a 'recovery', most likely in NAA. Hugg *et al.* (Hugg *et al.*, 1996) repeated spectroscopic imaging in five patients of the contralateral hippocampus 12 months following surgery and concluded that two showed 'recovery'. The lack of correlation of spectroscopic abnormalities with volume loss of the hippocampus (and therefore atrophy) in some studies (Ende *et al.*, 1997) would suggest that NAA may be a marker of neuronal dysfunction rather than neuronal loss, and that such a 'recovery' may be possible. Within our own study, the numbers are small, and the length of time between surgery and repeat examination short, with inadequate time to make comment about outcome with regard to seizures. Followup studies with clinical review at least two years following surgery should be performed to make further comment about this. Furthermore, comparison with neuropsychological data would also be invaluable.

The data from children with extratemporal epilepsy suggest a low rate of abnormality of the mesial temporal regions; two of the three children showing abnormalities had a progressive inflammatory condition as the underlying aetiology. Of the seven children who underwent both examinations, both <sup>1</sup>H MRS and T2 relaxometry were bilaterally normal in three, and unilaterally abnormal ipsilateral to the seizure focus in two. In two children however, T2 values were bilaterally abnormal but <sup>1</sup>H MRS normal on at least one side (unilateral in one and bilateral in one). The numbers are extremely small and therefore it is difficult to draw specific conclusions. However, these data suggest that any temporal lobe damage in extratemporal epilepsy may be more localised to the hippocampus than a wider area of the temporal lobe.

The well defined anatomical boundaries of the mesial temporal lobe enable reproducibility of reliable localisation of a region of interest. Other areas of the brain, eg frontal and parietal lobe do not provide such boundaries and therefore reliable placement of a consistent region of interest, small enough to consider in surgery would be more difficult. The development of chemical shift imaging (CSI) has enabled wider review of other areas of the brain. Other centres have reported on CSI in adults in TLE (Hugg *et al.*, 1993; Cendes *et al.*, 1994; Ng *et al.*, 1994; Ende *et al.*, 1997), and also in frontal lobe epilepsy (Garcia *et al.*, 1995). This technique theoretically has an advantage over single voxel techniques as it enables collection of individual spectra from many single voxels over a slice of tissue. Such studies have demonstrated a correlation between abnormal signal intensity ratios and the side of the seizure focus in TLE in adults (Cendes *et al.*, 1995; Ende *et al.*, 1997; Hugg *et al.*, 1993), and have also demonstrated bilateral abnormalities (Ng *et al.*, 1994; Hugg *et al.*, 1993) as in our and other single voxel studies

(Connelly *et al.*, 1994). However, there remain limitations to the technique at present. In the case of TLE studies, field inhomogeneities generally limit the acquisition of hippocampal data to the mid and posterior portions of the hippocampus. Some studies also summate the data from each hippocampus to provide average signal intensity data (Cendes *et al.*, 1995). In addition, signal bleeding between voxels can lead to contamination of individual spectra. This is particularly true of the high signal intensities obtained from the cerebellar vermis. Single voxel spectroscopy therefore provides a reliable method of producing consistent information in TLE, although CSI techniques may well play an increasingly important role in the evaluation of extratemporal epilepsy.

In conclusion, single voxel <sup>1</sup>H MRS of the mesial temporal lobes has demonstrated abnormalities in children with TLE that have proved reliable in the lateralisation of brain abnormality for use in the presurgical evaluation. Such data appear to complement quantitative hippocampal measures of abnormality such as T2 relaxometry. The consequence of abnormalities seen contralateral to the seizure focus remains to be evaluated.

***Publication arising from this work:***

**Cross JH, Connelly A, Jackson GD, Johnson CL, Neville BGR, Gadian DG (1996)**  
Proton magnetic resonance spectroscopy in children with temporal lobe epilepsy  
*Ann. Neurol.* **39**, 107-113 (I)

## APPENDIX

**Table A5.1: <sup>1</sup>H MRS in relation to clinical, EEG, MRI and pathology data in children with TLE.**

PATIENT	AGE	CLINICAL	INTERICTAL EEG	ICTAL EEG	MRI (Visual analysis)	<sup>1</sup> H MRS (NAA/(Cho+Cr))		T2 relaxometry (ms)		PATHOLOGY (if surgery)
						Ipsi	Contra	Ipsi	Contra	
T1	14y4m	LTLE	No abnormality	L temporal	LHS	0.48	0.63	120	105	Ammon's Horn sclerosis
T2	7y11m	LTLE	L frontotemporal	L temporal	LHA	0.48	0.92	125	106	Rasmussens encephalitis
T3	9y9m	LTLE	L mid temporal	L temporal	LHS+L temporal signal change	0.59	0.65	121	116	Ammon's Horn sclerosis
T4	11y8m	LTLE	Bilateral	L temporal	LHS+L temporal signal change	0.6	0.77	123	111	Ammon's Horn Sclerosis
T5	13y4m	LTLE	L temporal	L temporal	LHS+L temporal signal change	0.82	0.72	111	99	Ammon's Horn sclerosis
T6	17y9m	LTLE	Bitemporal	L anterior temporal	LHS	0.62	0.89	128	106	Ammon's Horn sclerosis
T7	16y	TLE	R temporal	N/A	Normal	0.82	0.86	108	108	
T8	10y	TLE	Bitemporal	L temporal	Normal	0.84	0.92	110	107	End plate gliosis
T10	14y	RTLE	No abnormality	R centrottemporal	RHS	0.64	0.69	130	106	Ammon's Horn sclerosis
T11	9y10m	LTLE	L centrottemporal	L centrottemporal	LHS+L temporal signal change	0.47	0.76	128	108	
T12	10y7m	LTLE	Bitemporal	L anterior temporal	LHS	0.56	0.66	125	102	Ammon's Horn sclerosis
T16	9y3m	RTLE	No abnormality	N/A	RHS+R hemiatrophy	0.48	0.49	129	110	
T17	9y 1M	TLE	L temporal	N/A	LHS+L temporal lobe atrophy	0.71	0.68	118	117	
T18	5y8m	TLE	R posterior temporal	R temporal	Normal	0.54	0.68	101	101	
T20	13y	LTLE	L temporal	N/A	LHS	0.73	0.8			
T21	11y9m	LTLE	No abnormality	N/A	LHS	0.77	0.92			
T22	10y	RTLE	R temporal	N/A	RHS	0.66	0.85			Ammon's Horn sclerosis
T23	8y	RTLE	Bilateral	N/A	RHS	0.62	0.77			
T24	5y	RTLE	R temporal	R temporal	RHS	0.44	0.52			
T25	16y11m	TLE	R temporal	N/A	RHS	0.62	0.59			

## CHAPTER 6

### REGIONAL CEREBRAL BLOOD FLOW IN LOCALISATION OF THE SEIZURE FOCUS

---

#### Contents

- 6.1 *Introduction*
  - 6.2 *Single photon emission computed tomography*
  - 6.3 *SPECT in epilepsy*
  - 6.4 *Methods*
    - 6.4.1 *Definitions*
    - 6.4.2 *Radioisotope injection*
    - 6.4.3 *Scan acquisition*
    - 6.4.4 *Data reconstruction and interpretation*
  - 6.5 *Results*
    - 6.5.1 *Scans performed*
    - 6.5.2 *Limited frame acquisition*
    - 6.5.3 *Asymmetry of perfusion*
    - 6.5.4 *Ictal scans*
    - 6.5.5 *Postictal scans*
    - 6.5.6 *Interictal scans*
    - 6.5.7 *Ictal/postictal vs interictal scans*
  - 6.6 *Ictal/postictal rCBF in special situations*
    - 6.6.1 *Secondary generalisation*
    - 6.6.2 *Hyperventilation*
    - 6.6.3 *Ictal/postictal scans in unlocalised epilepsy*
  - 6.7 *Discussion*
- 

#### 6.1 Introduction

The results of the studies reported in the previous three chapters have described a high rate of structural brain abnormality as ascertained by magnetic resonance techniques in a group of children with intractable focal epilepsy. Such brain abnormalities also appear to be concordant in a high proportion of cases with the apparent clinical/EEG focus as

defined in Chapter 2. However, there does appear to be a high incidence of so-called ‘dual pathology’. In addition, structural abnormality may or may not appear to be related to functional abnormality as seen on the EEG. For example, although the clinical impression may be one of a ‘frontal lobe epilepsy’, an EEG may be unhelpful by demonstrating widespread and/or nonlocalising information. In the light of this, to reduce the need for or guide invasive electrophysiological investigation, further functional tools giving information about events within the brain at the time of seizure onset would be desirable.

The possibility of cerebrovascular changes occurring during epileptic seizures was first speculated upon by Hughlings Jackson (Jackson, 1869). Initial studies reported an overall increase in rCBF during generalised seizures, and this was attributed to an increase in blood pressure or pCO<sub>2</sub> (Gibbs *et al.*, 1934). Penfield later observed the cerebral cortex during focal seizures following direct intraoperative stimulation in humans and animals (Penfield, 1933; Penfield *et al.*, 1939). In his first description, arterial vasoconstriction at the site of seizure origin was observed during focal seizures following intraoperative stimulation of that area in humans. At this time he proposed a vascular sequence that involved capillary dilatation during the seizure and cortical anaemia due to vasoconstriction following the seizure, although the latter could appear during the seizure. Later, in experiments measuring local CBF using a thermocouple in monkeys and humans, he detected increases local to the region of seizure onset (Penfield *et al.*, 1939).

Following these early findings a regional increase in cerebral blood flow was confirmed during focal seizures in animals (Heiss *et al.*, 1979; Udvarhalyi, Walker, 1965; Ueno *et al.*, 1975). Studies using cerebral angiography (Yarnell *et al.*, 1974) and <sup>133</sup>Xenon

tomography (Hougaard *et al.*, 1976) have subsequently confirmed such a regional increase in humans. Studies have also suggested changes in rCBF at the seizure focus in between seizures. Early human studies using  $^{133}\text{Xenon}$  indicated both an increase or a decrease in rCBF, and suggested a likely variability between studies depending on the functional status of the brain (Lavy *et al.*, 1976; Hougaard *et al.*, 1977; Hougaard *et al.*, 1976; Touchon *et al.*, 1986).

## ***6.2 Single photon emission computed tomography***

Although such changes in rCBF, whether in the ictal or interictal state, could provide further information as to where a seizure may be arising from, the problem remains as to how such changes may clinically be detected in a practical and efficient manner. Single photon emission computed tomography (SPECT), using ligands such as N-isopropyl-(iodine 123) p iodoamphetamine ( $^{123}\text{IMP}$ ) and  $^{99}\text{Tc}^{\text{m}}$  hexamethylpropylene amine oxime (HMPAO), has been shown to be a possible solution to this.

SPECT is a means by which the distribution of a  $\gamma$  emitting tracer is determined by acquisition and subsequent analysis of a 3D data set using a gamma camera.  $^{99}\text{Tc}^{\text{m}}$  is the radioisotope most commonly used. It is easily produced, has a suitable emission pattern ( $\gamma$  but no  $\beta$  radiation), has low energy (140KeV), and has a short half life (6 hours).

Hexamethylpropylene amine oxime (HMPAO) is a ligand that has been shown to be suitable for the assessment of cerebral blood flow. HMPAO is a lipophilic compound, easily labelled with  $^{99}\text{Tc}^{\text{m}}$ , that is taken across the blood brain barrier and converted to a hydrophilic compound and retained for long enough to enable suitable imaging (Neirinckx *et al.*, 1987; Sharp *et al.*, 1994). The uptake pattern of  $^{99}\text{Tc}^{\text{m}}$  HMPAO has been



shown in normal volunteer studies to be equivalent to regional cerebral blood flow (Costa *et al.*, 1986). Animal studies using radioactive microspheres have also confirmed this (Costa *et al.*, 1987). Autoradiographic studies using a model of acute ischaemia in rat brains have shown good correlation of HMPAO uptake in disease states with  $^{14}\text{C}$  iodoantipyrine - derived cerebral blood flow (Bullock *et al.*, 1991). Comparative studies with other techniques of cerebral blood flow measurement in humans, both in normal individuals and those with neurological disease, have shown correlations with  $^{133}\text{Xe}$  (Andersen *et al.*, 1987) and  $\text{C}^{15}\text{O}_2$  positron emission tomography (Gemmell *et al.*, 1990; Inugami *et al.*, 1988; Yonekura *et al.*, 1988). Consistently, however, it has been shown in all studies that although a linear relationship may be seen between rCBF and HMPAO uptake at normal flow rates, the relationship becomes nonlinear at high flow rates. Absolute quantitation of cerebral blood flow using this technique is therefore currently not possible.

### ***6.3 SPECT in epilepsy***

Initial studies using SPECT in epilepsy reported its use following an interictal injection of the ligand (Rowe *et al.*, 1991b; Stefan *et al.*, 1987b; Rowe *et al.*, 1991a; Rowe *et al.*, 1989), that is an injection in between seizures. Adult studies, predominantly in temporal lobe epilepsy, suggested that areas of hypoperfusion seen after an interictal injection were predictive of the area of the seizure focus in 40-75% of cases. (Hajek *et al.*, 1991; Jack, Jr. *et al.*, 1994; Rowe *et al.*, 1991b; Suess *et al.*, 1991). From the limited data available in children there is some suggestion that the predictive yield may be higher in this age group (Denays *et al.*, 1988; Harvey *et al.*, 1993a). An immediate postictal injection, that is as soon after seizure offset as possible, has been shown in adult TLE to increase the

predictive yield to around 70-80% (Rowe *et al.*, 1991a; Rowe *et al.*, 1989).

Injection of the radioisotope during the clinical seizure (an ictal injection) in TLE has been demonstrated to increase the rate of prediction of the seizure focus by detection of focal hyperperfusion of the anterior temporal lobe responsible for seizure onset (Berkovic *et al.*, 1993; Harvey *et al.*, 1993a; Newton *et al.*, 1992a; Newton *et al.*, 1992b).

Furthermore a particular change in pattern of blood flow has been described depending on whether the injection is ictal, postictal or interictal (Newton *et al.*, 1992b). Following on from this, it has been postulated that a change in cerebral perfusion may be seen in TLE depending on the timing of injection relative to the seizure (Duncan *et al.*, 1993; Newton *et al.*, 1992b), an observation originally described after direct cortical stimulation by Penfield (Penfield, 1933).

Studies in extratemporal epilepsy have been less convincing. The largest series reported has been in children with frontal lobe epilepsy where focal frontal hyperperfusion following ictal injection of  $^{99}\text{Tc}^m$  HMPAO was seen in 20/22 cases (Harvey *et al.*, 1993b). Interictal studies, however, are reported as disappointing in this group (Harvey *et al.*, 1993b; Marks *et al.*, 1992) with only 2/22 demonstrating focal hypoperfusion in the study of children with FLE (Harvey *et al.*, 1993b). Limited adult data in ETE involve ictal studies, predominantly with focal motor and supplementary area seizures, showing hyperperfusion of the relevant cortex in a proportion of cases (Marks *et al.*, 1992; Lee *et al.*, 1988; Laich *et al.*, 1997).

SPECT is therefore a relatively noninvasive technique that appears to be able to

demonstrate changes in regional cerebral perfusion at the seizure focus, whether an injection is made during a seizure (ictal), immediately following a seizure (postictal) or in between seizures (interictal). Such a technique, to be used in conjunction with clinical, EEG and MR data, would be attractive in children, if it can indeed provide additional functional information about the seizure focus. The aims of this part of the study were i) to determine whether it is possible to use ictal SPECT as a clinical tool in children, ii) to evaluate the technique in a group of nonselected children with focal epilepsy undergoing evaluation for possible epilepsy surgery, iii) to determine whether SPECT, ictal/postictal or interictal does provide further localising data that is concordant with the clinical/EEG and MR data, and iv) whether similar patterns of rCBF in the ictal and interictal states are seen to that previously described, predominantly in adults.

## **6.4 Methods**

### **6.4.1 Definitions**

There appears to be confusion among different series examining the role of SPECT in focal epilepsy in the definition of what is meant by an ictal, a postictal and an interictal injection. For the purpose of this current study, an ictal injection was defined as one where the HMPAO was given during the clinical seizure, and a postictal injection where the ligand was given as soon after seizure onset as possible but where clinical seizure activity had ceased. Many studies define 'ictal' as an injection made during the seizure or up to 30 seconds from the end of the seizure (Harvey *et al.*, 1993a; Harvey *et al.*, 1993b; Newton *et al.*, 1993; Newton *et al.*, 1992a) as changes in rCBF, particularly in TLE have been shown when the injection has been given within this time. Others, however, have shown that only true ictal injections reliably show hyperperfusion at the seizure focus

(Duncan *et al.*, 1993). A change in the pattern of perfusion in the temporal lobe has been reported, dependent on the timing of the injection relative to the seizure offset, with an interictal pattern seen as early as thirty seconds postictally (Duncan *et al.*, 1993) and certainly by 15-30 minutes (Duncan *et al.*, 1993; Rowe *et al.*, 1989). In view of the high seizure frequency of the majority of children within the current study, an interictal injection was defined as one given when no seizure had occurred for 30 minutes.

#### **6.4.2 Radioisotope injection**

HMPAO is available as a kit known as *ceretec*, produced by Amersham, UK. Each vial of *ceretec* contains a freeze dried mixture of 0.5mg HMPAO, 7.6µg stannous chloride dihydrate and 4.5mg sodium chloride. The vial is filled with inert nitrogen to a pressure just below atmospheric and can be reconstituted with 5mls of fresh <sup>99</sup>Tc<sup>m</sup> generator eluate containing up to 1110 Bq of <sup>99</sup>Tc<sup>m</sup>. When pertechnetate is added to the HMPAO, in the presence of the stannous reducing agent, a neutral, lipophilic complex of low molecular weight is formed. Clinical studies have shown uptake of 4% in the brain which remains constant over 8 hours (Sharp *et al.*, 1994), and about 86% of this activity remains 24 hours after injection.

Certain conditions are specified in the use of the *ceretec* preparation, however, to ensure a radiochemical purity specification of at least 80% primary complex; these include use within 30 minutes of reconstitution (to minimise degradation to the secondary complex) with use of eluate less than two hours old, from a generator that has been eluted in the previous 24 hours (to limit the formation of free pertechnetate in the vial) (Bayne *et al.*, 1989). Although mixing of <sup>99</sup>Tc<sup>m</sup> and HMPAO immediately prior to injection may slow

injection times with regard to an ictal injection, it is necessary to retain an appropriate proportion of primary complex of the ligand, and mixing is possible at the bedside.

However the use of fresh eluate provides a specific problem with regard to ictal injections. A solution to this problem was suggested by Bayne *et al* (Bayne *et al.*, 1989). Sodium iodide added on elution has been shown to stabilise the pertechnetate over a six hour period, providing a larger time window within which a seizure can occur.

In order to achieve an ictal injection of radioisotope, the children were admitted to the ward at least two days prior to the examination for video-EEG telemetry, and medication was withdrawn if necessary, as described in Section 2.5.1. An intravenous cannula was inserted on the morning of the examination. An individual, trained in the technique of isotope handling and injection, remained in attendance throughout the test, and, when a typical seizure started, mixed and injected the  $^{99}\text{Tc}^m$  HMPAO as soon after the seizure onset as possible. Sodium iodide had been added to the pertechnetate on elution. A dose/volume chart was held with the patient to indicate the volume to be given depending on the time of day, the dose being calculated according to a suggested schedule based on surface area (Paediatric Task Group, 1990).

For an interictal injection, an intravenous cannula was again inserted on the morning of the examination. Children were allowed to play and were kept in as normal an environment as possible. Where possible, injection was made at least 30 minutes following the last seizure. In patients with epilepsy partialis continua, 'interictal' scans were performed 30 minutes after injection with intravenous benzodiazepine which was given to terminate seizure activity. This decision was based on previous adult data

showing that in temporal lobe epilepsy baseline perfusion had returned to interictal state by this time (Duncan *et al.*, 1993; Rowe *et al.*, 1991a). To minimise distress,  $^{99}\text{Tc}^{\text{m}}$  HMPAO was injected through the cannula while the child was on the ward. As with ictal studies, the dose was calculated based on surface area.

Ethical approval for SPECT studies was obtained from the Great Ormond Street Hospital for Children NHS Trust and Institute of Child Health Research Ethics Committee.

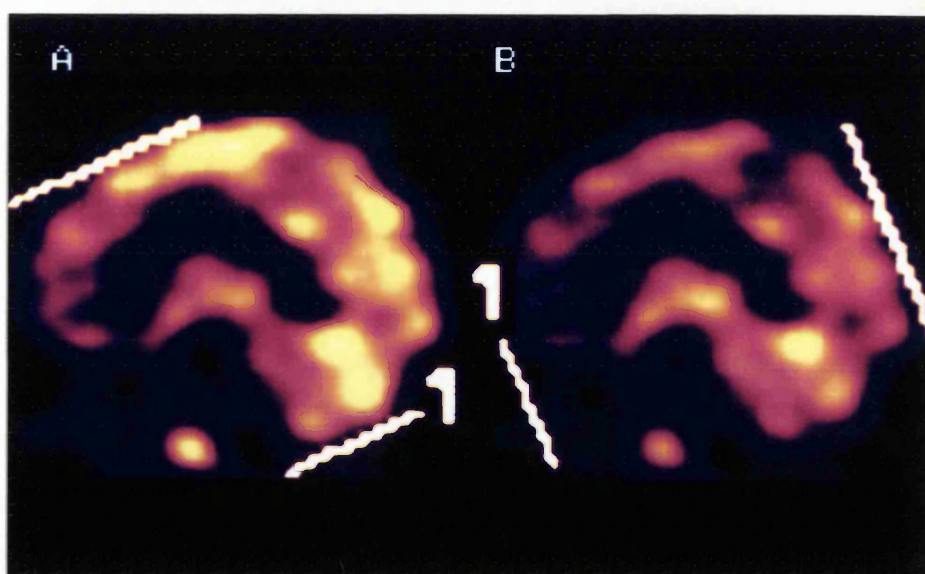
#### **6.4.3 Scan acquisition**

For ictal and interictal studies, children were scanned within three hours of injection, having been sedated using intravenous midazolam (0.5mg/kg) immediately prior to the scan. Adult studies have shown that scanning within four hours of injection is adequate for a satisfactory study (Costa *et al.*, 1986). Data were acquired using an Elscint SP6 single headed rotating gamma camera (full width half maximum of the system is 10-15mm). This involved stepwise progression of the camera head, with acquisition of data every 6° for 360°, 40 seconds each acquisition, and data were acquired in a 64x64 matrix. Scans were sensitivity corrected and data stored to optical disk.

#### **6.4.4 Data reconstruction and interpretation**

At the end of the period of data collection, all scans were reprocessed over a three week period using the Elscint reconstruction programme. Reconstruction was performed by filtered back projection in conjunction with a Metz filter. After reconstruction second order Chang attenuation was performed with linear attenuation coefficient of 0.12. Reconstruction of each 3D data set was performed parallel and perpendicular to the

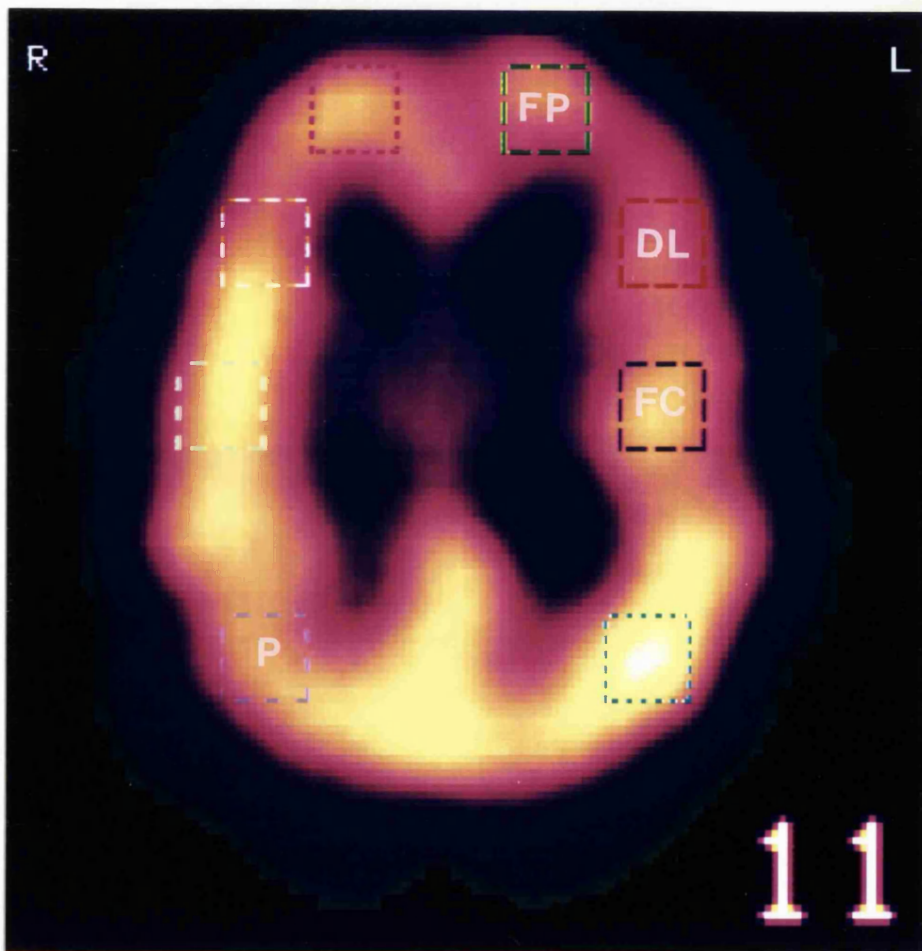
temporal lobe (6.1), as well as parallel and perpendicular to the orbitomeatal line, and subsequently reviewed for asymmetry of perfusion between matched regions across the midline. For ictal/postictal scans, an area of increased uptake was regarded as abnormal, as opposed to an area of low uptake in the case of interictal scans. Finally, ictal/postictal scans were compared to the interictal scan from the same patient to determine whether there had been a change in perfusion.



**Figure 6.1 Angle of slice for semiquantitative analysis of SPECT scans; parallel (A) and perpendicular (B) to the axis of the temporal lobes**

Semiquantitative analysis was also performed and results evaluated according to 5%, 7.5%, 10%, 12.5% or 15% side to side asymmetry in preallocated matched regions within each lobe (Figs. 6.2-6.4) based on a semiquantitative colour scale. This scale was based on total radioactivity count in each pixel relative to other pixels within each slice. In addition to assessing side to side lobar perfusion asymmetry, the temporal lobe was further subdivided into anteromedial, anterolateral, mid and posterior temporal regions, and the frontal lobe into frontocentral, dorsolateral, frontopolar, orbitofrontal and medial

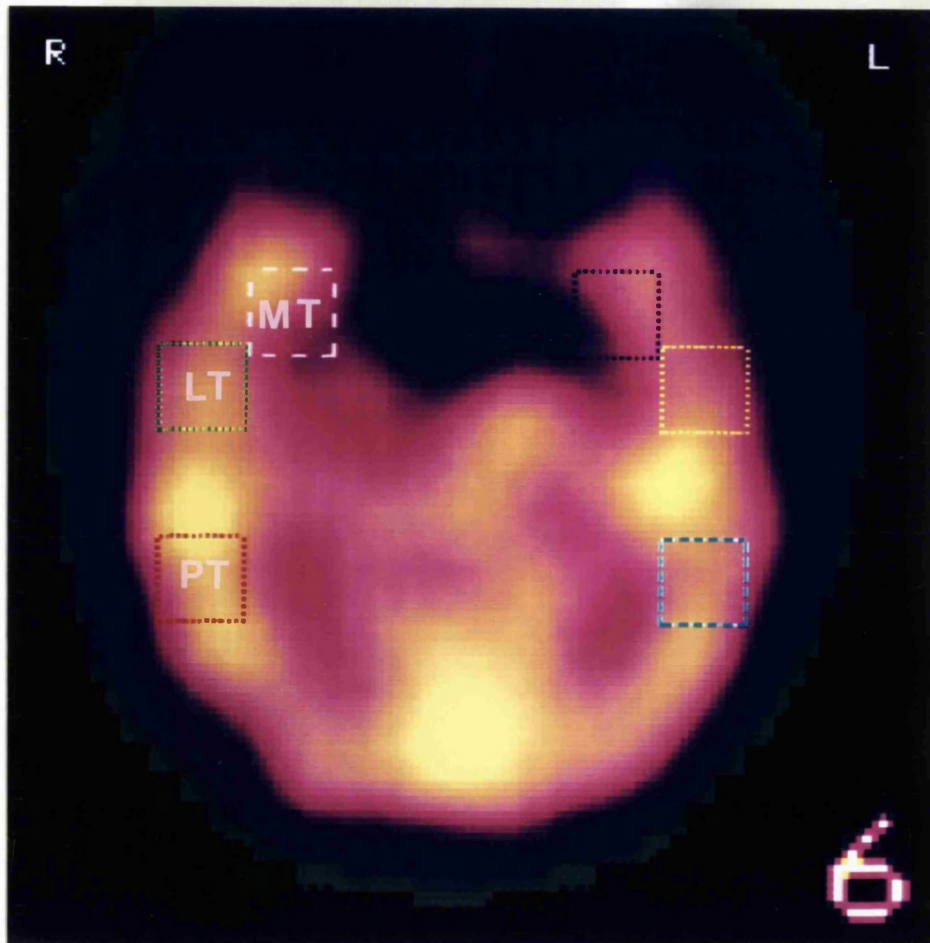
frontal regions. Asymmetry of perfusion of subcortical structures, namely the cerebellar hemispheres and the basal ganglia, was also documented during this analysis.



**Figure 6.2:**  $^{99m}\text{Tc}$  HMPAO SPECT scan, transverse section showing regions of interest in the frontal and parietal lobes for semiquantitative analysis; frontopolar (FP), dorsolateral (DL), frontocentral (FC) and parietal (P).

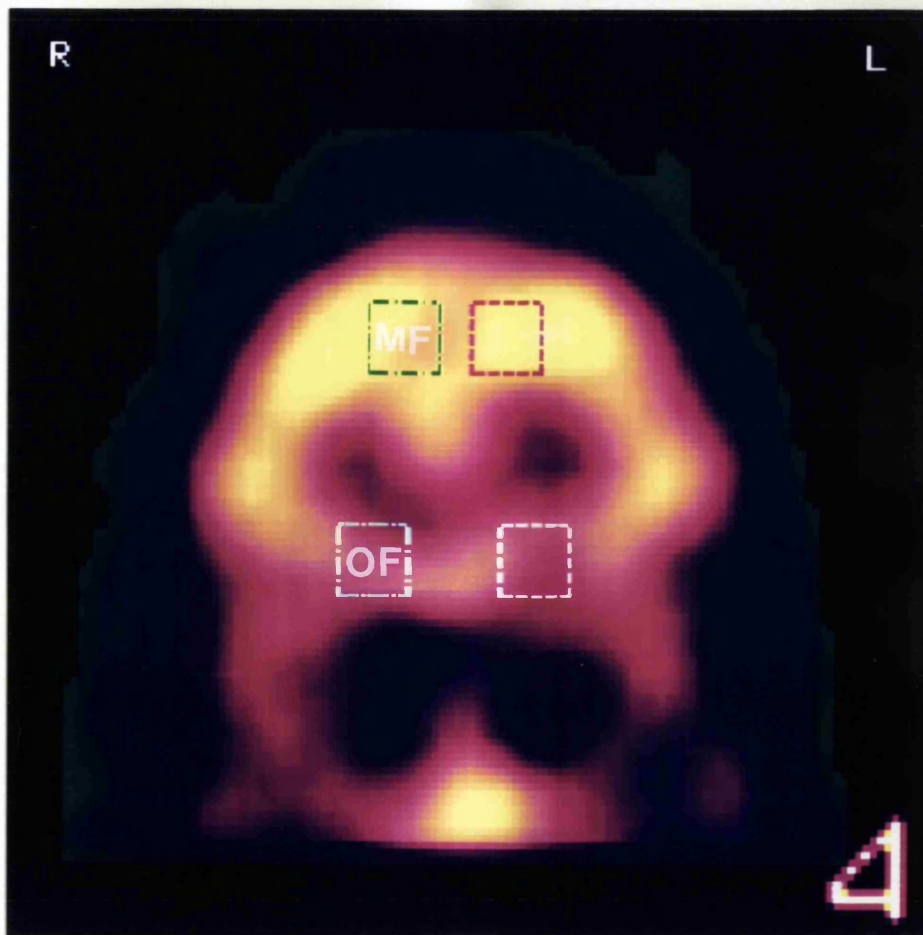
*Adapted from Harvey et al, 1993b*





**Figure 6.3:**  $^{99}\text{Tc}^{\text{m}}$  HMPAO SPECT scan, transverse section through the temporal lobes showing regions of interest for semiquantitative analysis; medial temporal (MT), lateral temporal (LT) and posterior temporal (PT).

*Adapted from Harvey et al, 1993b*



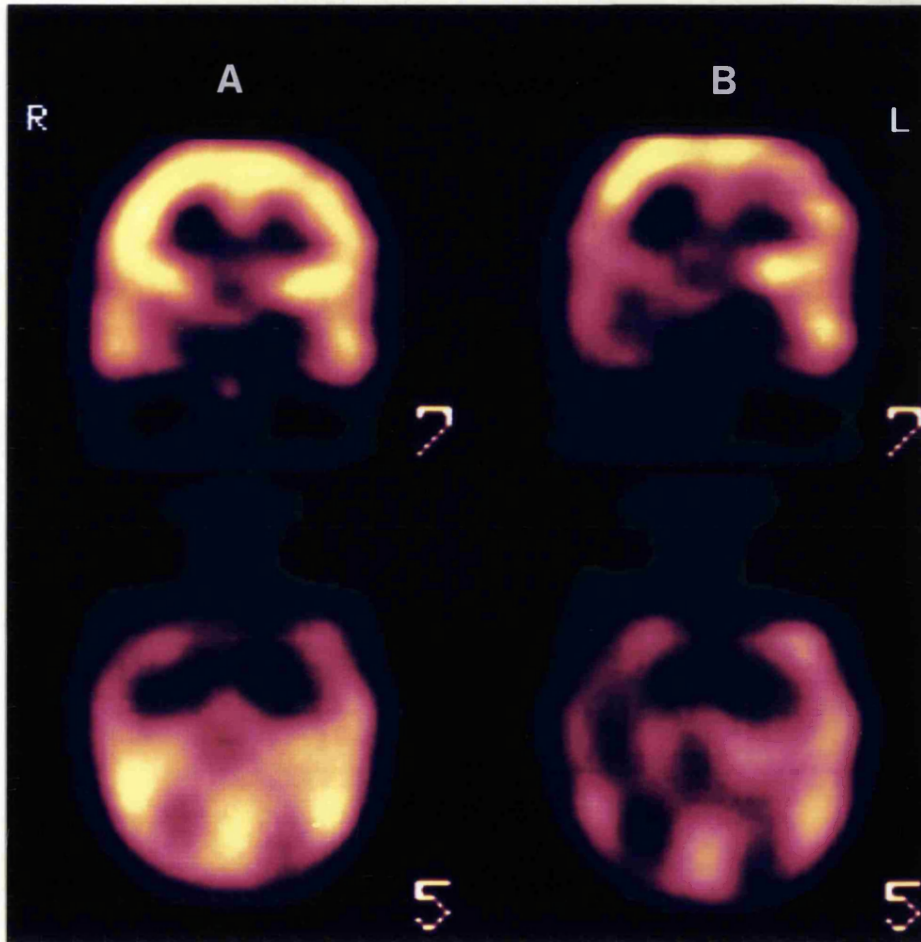
**Figure 6.4:**  $^{99}\text{Tc}^{\text{m}}$  HMPAO SPECT scan, coronal section through the frontal lobes to showing the regions of interest used for semiquantitative analysis; medial frontal (MF) and orbitofrontal (OF). *Adapted from Harvey et al, 1993b*

## **6.5 Results**

### **6.5.1. Scans performed**

A total of 37 ictal scans and 18 immediate postictal scans in 51 children, age range 9 months to 18 years 2 months (mean 9 years 10 months), were performed in the study period. In 49 children, the probable seizure focus could be defined by clinical and EEG data as outlined in Chapter 2 as temporal (22), extratemporal (14) or hemisindrome (13) epilepsy. In two, the seizure focus could not be localised, but both these children had a focal structural abnormality on MRI. Two children underwent both an ictal and a postictal scan, whereas one child had two ictal scans over a period of six months and one child two postictal scans. The mean injection time after the onset of the seizure in those who underwent an ictal injection was 51 seconds (range 7-136 seconds) with a seizure duration 23-900 seconds (mean 120 seconds). In those who underwent an immediate postictal injection, the mean injection time was 49 seconds after the onset of the seizure (range 24-69) and mean duration of seizure 30 seconds (range 5-57 seconds).

An interictal scan was performed in all the children who underwent ictal and/or postictal studies (51 children), as well as in a further 12 children where an ictal study was not achieved. A total of 71 interictal scans were performed in 63 children, age range 9 months to 18 years 3 months (mean 10 years one month). Eight children underwent two interictal studies, four 2 years apart and four 6 months apart. One interictal study could not be processed in view of insufficient isotope activity within the brain.



**Figure 6.5:**  $^{99m}\text{Tc}$  HMPAO SPECT scans showing analysis of the same data set using  $360^\circ$  data (A) and limited acquisition of data (B) from patient E2. Scan A shows no asymmetry of perfusion whereas scan B shows hypoperfusion of the right temporoparietal region (see Section 6.5.2).

### ***6.5.2 Limited frame acquisition***

In routine data processing the Elscint software specifies the data to be analysed as if a 360° data set has been acquired. However in some cases, data were acquired from a limited number of frames (ie they were not acquired from a full 360° rotation), usually because the child moved prior to the end of the scan; see Section 6.5.1. At the outset of this study, it was unknown whether this affected interpretation of scans. Fifteen children within this study did not undergo a full 360° acquisition of data on at least one scan because of movement during acquisition of data; either in an ictal/postictal scan (ten children), interictal scan (three children) or both interictal and ictal scans (two children). To determine whether this affected interpretation, in the children where either the ictal or interictal scan was of limited frames (13 children), the other scan was limited on processing to the same number of frames and reanalysed; ie both the interictal and ictal scans were processed with the limited number of frames, and results of the limited frame and the 360° acquisition data sets compared for the one scan type where 360° data were acquired.

In eight of the 13 children who had one limited study, data processed on the limited data set led to a different result when compared to the full 360° data set. In six children, although there were minor differences in the degree of asymmetry between the two sides seen between the two data sets, this would not have led to a change in the report. However, in five children, analysis of the 360° data set showed no asymmetry of perfusion, whereas that of the limited data set demonstrated significant asymmetry (Fig. 6.5). In two children focal asymmetry was seen on the 360° data set, but this extended

over a wider area on analysis of a limited data set.

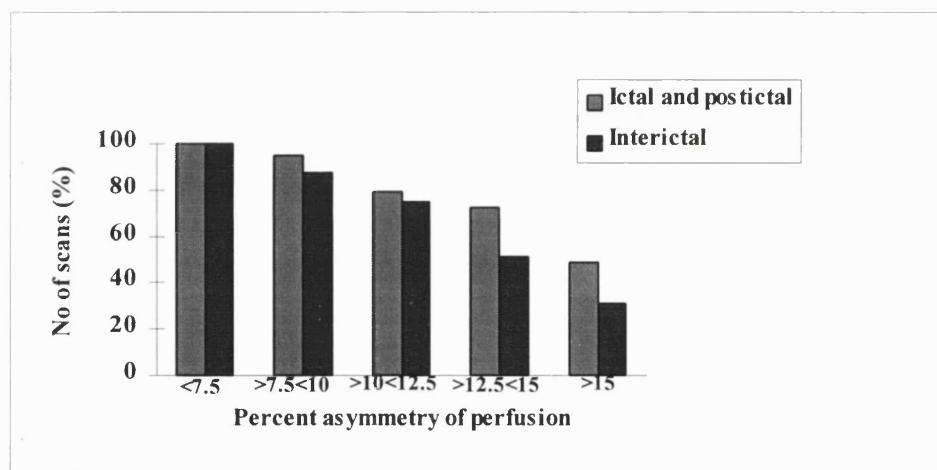
Conclusions drawn from this subanalysis were that where a limited data set was obtained on acquisition, absolute results from a single scan were unreliable as asymmetry of perfusion could be exaggerated. However such data could be compared and interpreted with a second data set where a similar limited frame acquisition had been obtained in different circumstances (ie interictal vs ictal analysis). The implications of this were that 28 ictal, 13 postictal and 64 interictal scans could be reviewed for abnormality alone, whereas 36 ictal scans and 17 postictal scans could be compared with the respective interictal scans of individual patients.

### ***6.5.3 Asymmetry of perfusion***

Interpretation of results requires some consideration in view of the fact that absolute quantitation of cerebral blood flow using the technique of  $^{99}\text{Tc}^{\text{m}}$  HMPAO SPECT is not available in the clinical setting. Previous studies have used semiquantitation of data to verify first line double blind reporting by experienced nuclear medicine physicians (Duncan *et al.*, 1993; Harvey *et al.*, 1993a; Newton *et al.*, 1992b; Rowe *et al.*, 1991b; Rowe *et al.*, 1989). Such methods involve selecting regions of interest and comparing them to a constant region of the brain or the whole brain as a 'perfusion index'. Either this has been compared to data obtained on normal controls (normal temporal lobe asymmetry quoted as 2.5-3.5%, (Rowe *et al.*, 1991b)), or side to side asymmetry of matched regions reported as abnormal if greater than 7% (Duncan *et al.*, 1993). The greatest degree of side to side asymmetry reported of visually reported 'normal' scans in other studies has been quoted at 12-15% (Duncan *et al.*, 1996; Podreka *et al.*, 1987). Some groups have based

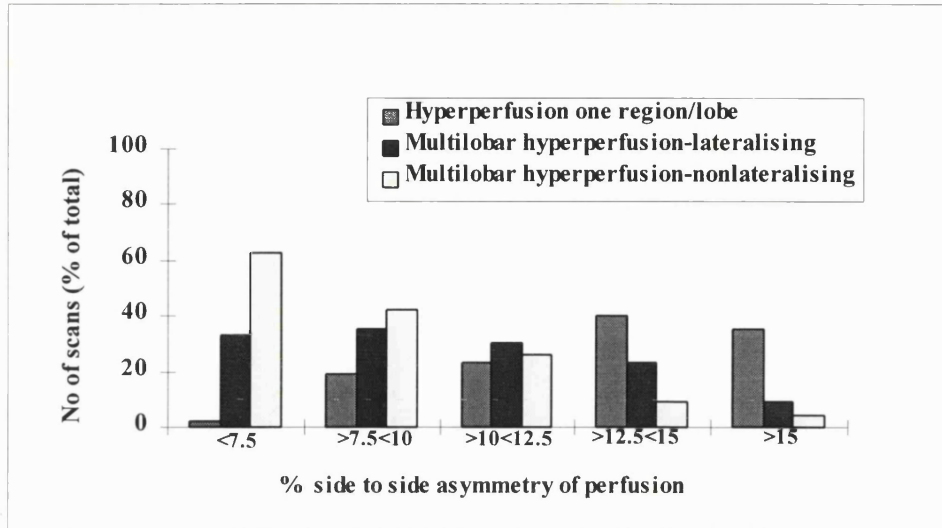
reporting of scans obtained in disease states on reference scans obtained from a pool of normal individuals (Houston *et al.*, 1994). Ethical issues in children, however, preclude acquisition of such data. Side to side asymmetry of matched regions was therefore used as an index of abnormality within this study. In practice the area of most asymmetry was examined and reported as the likely area of abnormality, with semiquantitation used as in previous studies to verify the report (see Table A6.1)

**Figure 6.6: Total number of interictal and ictal/postictal scans demonstrating abnormality according to percentage asymmetry used.**

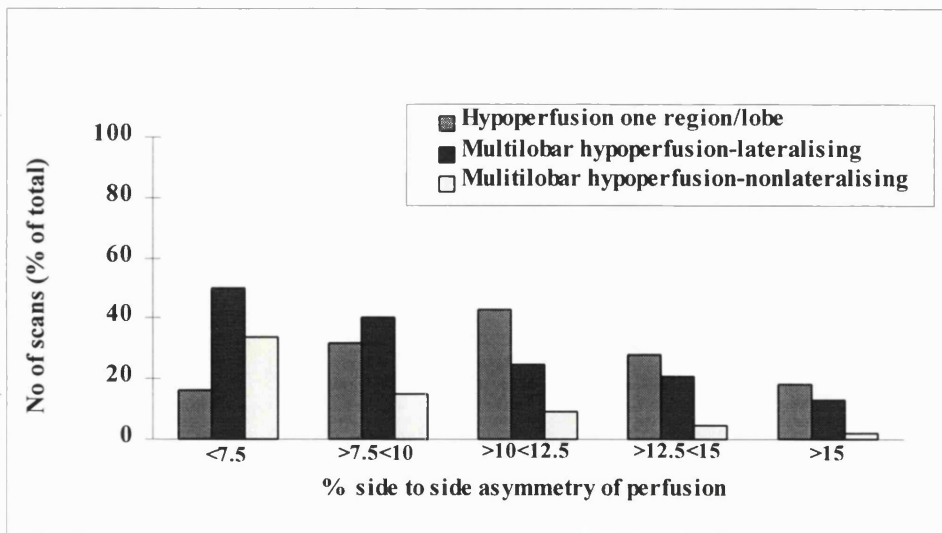


In all cases where 360° data were acquired (see Section 6.5.2), scans were reviewed for 5%, 7.5%, 10%, 12.5% and 15% asymmetry of perfusion between matched regions of the brain across the midline (see Fig. 6.1-6.4). All children demonstrated asymmetry of at least one region between the two hemispheres at the 5% level on ictal/postictal or interictal scan. The percentage of scans reported as abnormal decreased with increasing percent asymmetry used as would be expected (see Fig. 6.6), with only 51% demonstrating abnormalities at a 15% level on ictal/postictal scans, and 32% at this level

**Figure 6.7: Proportion of ictal/postictal scans demonstrating asymmetry of perfusion according to percentage asymmetry used.**



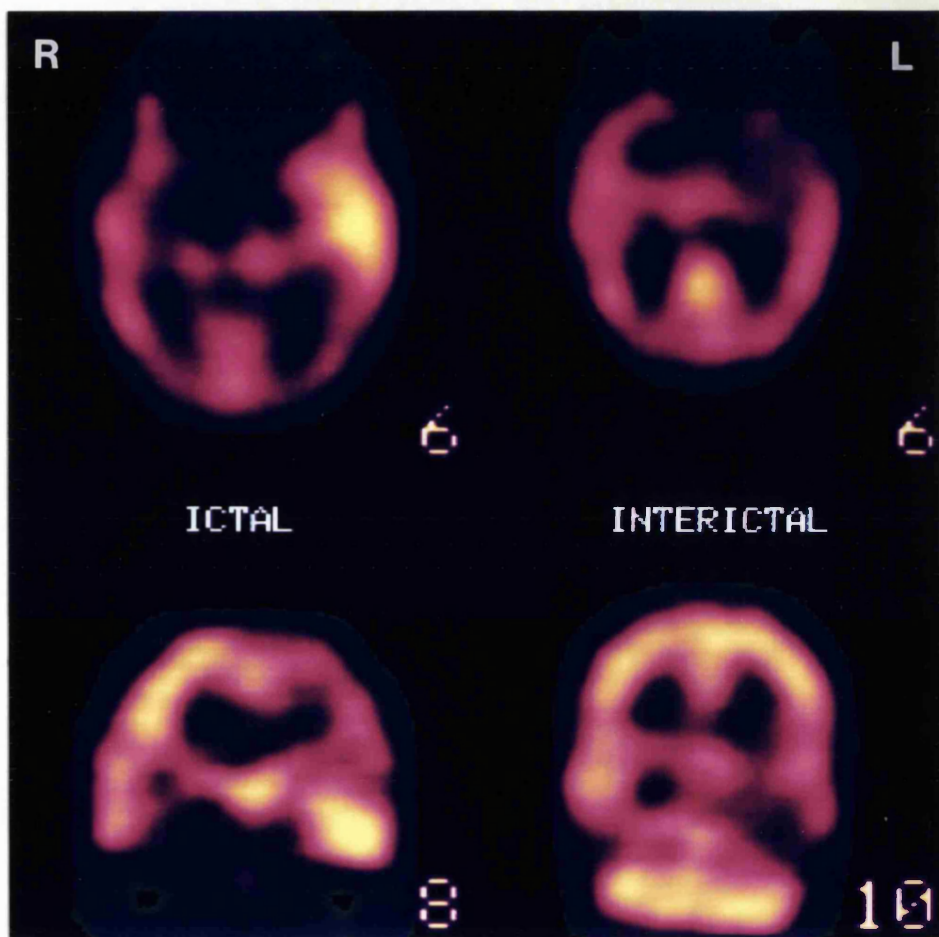
**Figure 6.8: Proportion of interictal scans demonstrating asymmetry of perfusion according to percentage asymmetry used.**



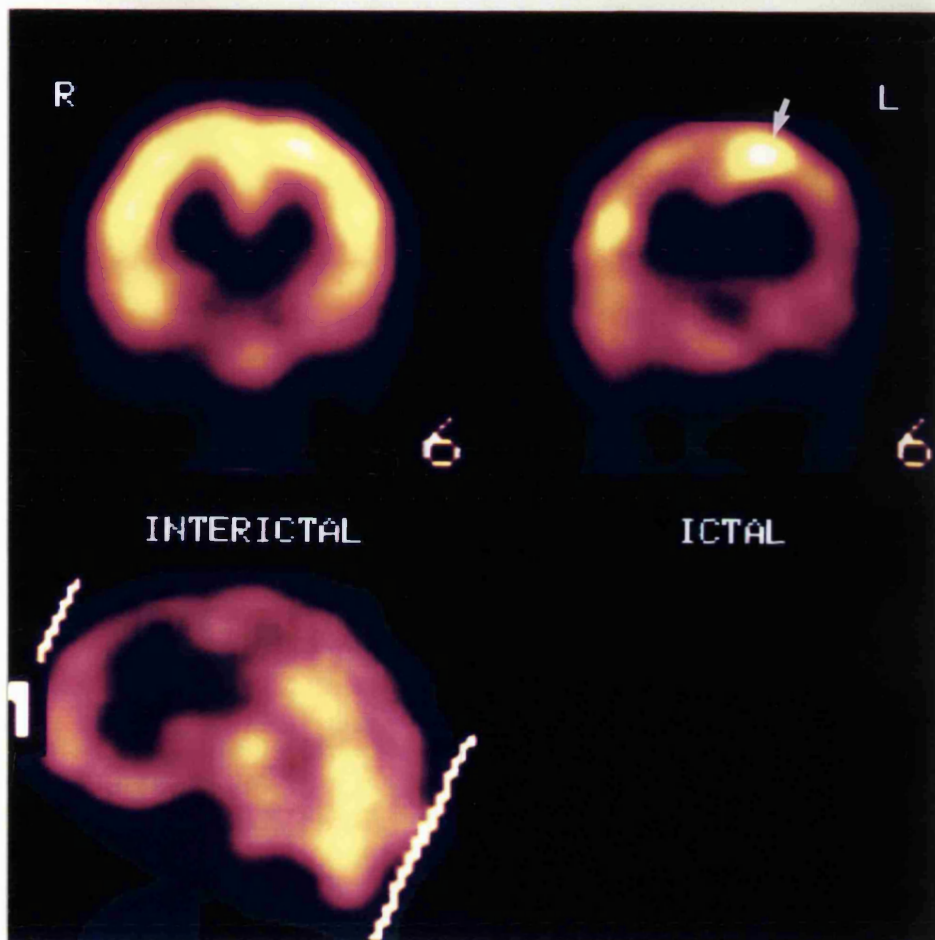


on interictal scans. For ictal/postictal scans, the most marked decrease in the number showing abnormality was between 12.5% and 15%, whereas for interictal scans this lay between 10% and 12.5% (Figs. 6.7, 6.8). The proportion demonstrating focal/lobar abnormalities as opposed to multilobar abnormalities also increased with increasing percent asymmetry used. Only 2% demonstrated focal regional or lobar abnormality on ictal/postictal scans at 5% asymmetry, with 63% showing multifocal nonlateralising hyperperfusion, whereas the number showing focal abnormality rose to a maximum of 40% at 12.5% asymmetry with 9% that were multilobar and nonlateralising. On interictal scans the maximum number of scans demonstrating focal regional or lobar hypoperfusion was seen using 10% asymmetry (43%), also with only 9% showing multilobar nonlateralising abnormalities.

On review of ictal and postictal scans, therefore, 12.5% asymmetry appeared to produce the maximal number of scans showing focal hyperperfusion, with a small number of nonlateralising scans (Fig. 6.7). On the interictal scans the maximum number of scans showing focal hypoperfusion was seen using 10% (Fig. 6.8), with less than 10% of scans nonlateralising. In practice, on review of reports (see Appendix), in the majority of cases an asymmetry of at least 12.5% was seen as verification on ictal/postictal scans and 10% on interictal scans. It would seem therefore that semiquantitation is used as a verification rather than justification of a clinical report. The implications of this will be discussed in later sections.



**Figure 6.9:**  $^{99}\text{Tc}^{\text{m}}$  HMPAO SPECT scans from patient T6. The ictal scan demonstrates hyperperfusion of the left anterior temporal lobe, whilst the interictal scan shows hypoperfusion over a similar, slightly wider area.



**Figure 6.10:**  $^{99}\text{Tc}^{\text{m}}$  HMPAO SPECT scans from patient E11. The interictal scan showed no asymmetry of perfusion, whereas the ictal scan demonstrated a localised area of hyperperfusion in the left medial frontal region (arrow). The abnormality was best seen along the axis perpendicular to the orbitomeatal line.

#### **6.5.4 Ictal scans**

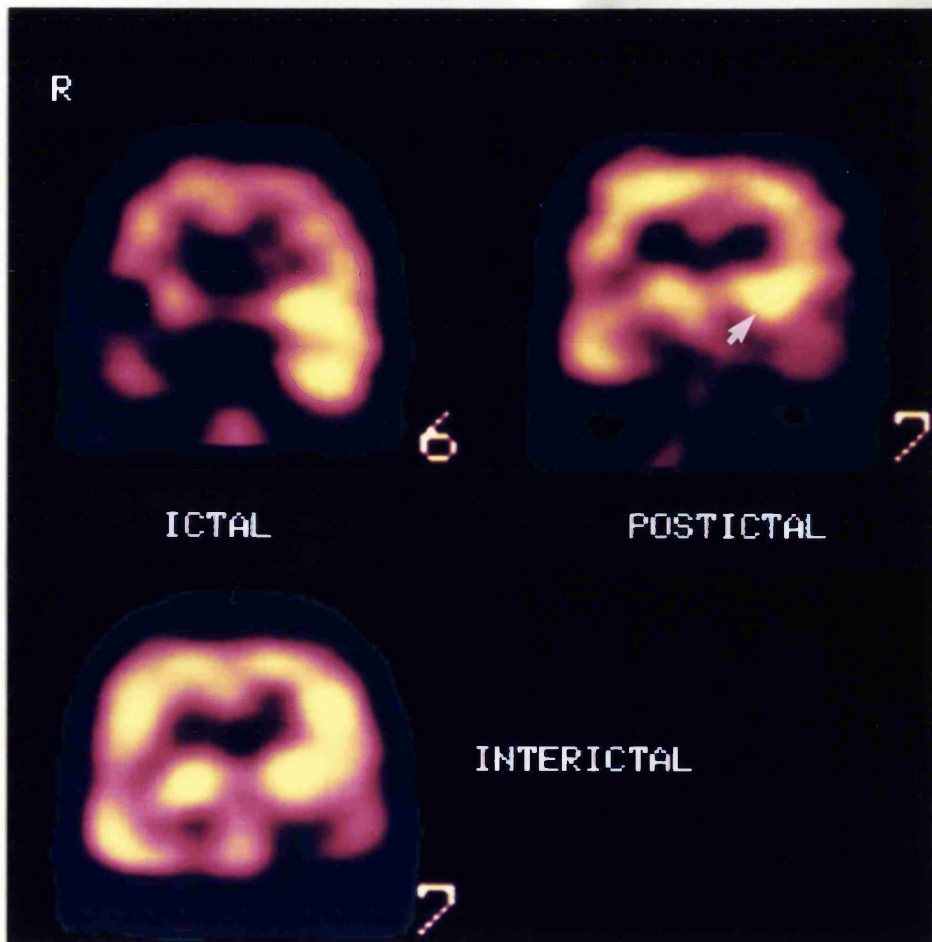
Nineteen scans of the 28 that could be reviewed (68%) showed hyperperfusion of an area concordant with the seizure focus; in 15 this was focal (over part of or no more than one lobe) ( 7 temporal (Fig 6.9), four extratemporal (Fig 6.10), including one in addition to an area of absence of activity, and three hemisindrome) and four multifocal (three hemisindrome and one temporal). Five showed hyperperfusion of the lobe contralateral to the assigned seizure focus; in three this was of one region and two of more than one region on one side. Two showed absence of activity in the area concordant with the seizure focus and two showed no asymmetry of perfusion.

Seven scans demonstrated focal hyperperfusion with relative hypoperfusion of the ipsilateral cerebral hemisphere. This was seen in four children with temporal lobe epilepsy, two with hemisindromes and one with extratemporal epilepsy.

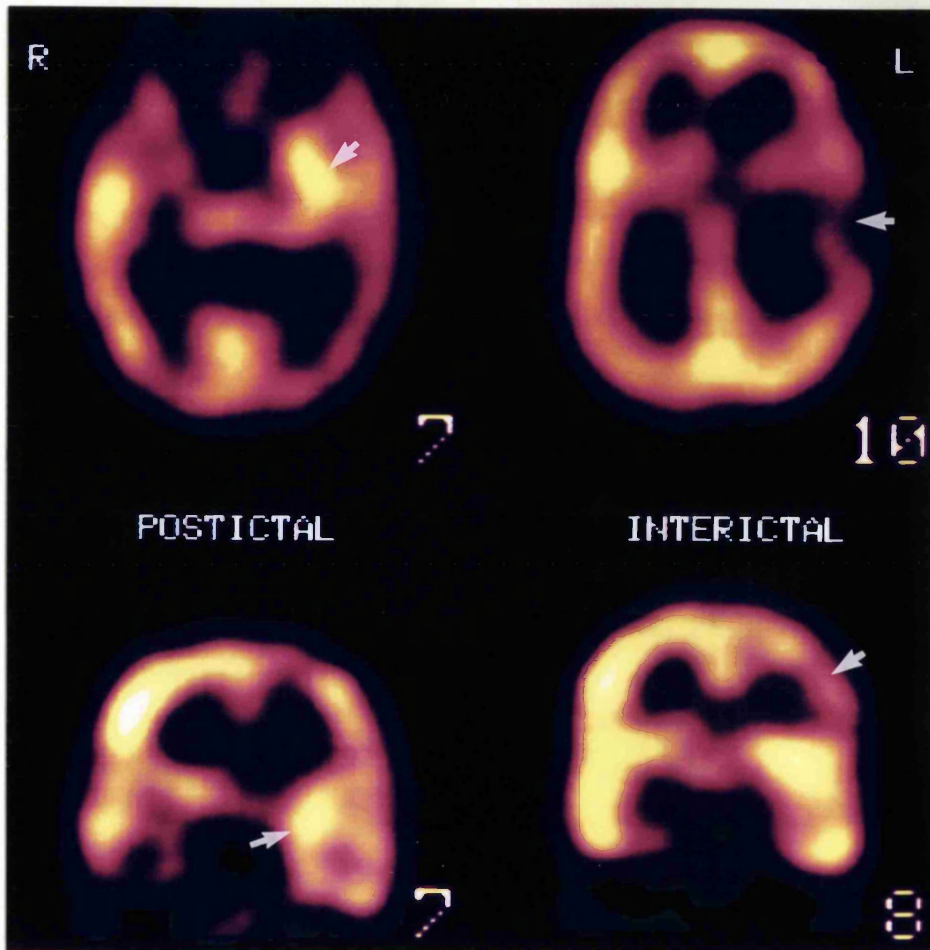
#### **6.5.5 Postictal scans**

Seven of the 13 postictal scans that could be reviewed (54%) showed focal hyperperfusion concordant with the seizure focus, and two showed absence of activity with no additional area of hyperperfusion. Two showed focal hyperperfusion of the lobe contralateral to the seizure focus, one showed lateralised multifocal hyperperfusion nonconcordant with the seizure focus and one showed no asymmetry of perfusion.

Two children with temporal lobe epilepsy (patients T2 and T10) underwent ictal and postictal scans on separate occasions in relation to similar seizure types (Fig 6.11). After ictal injection, both children showed hyperperfusion of the whole temporal lobe ipsilateral



**Figure 6.11:**  $^{99}\text{Tc}^m$  HMPAO SPECT scans from patient T2. The ictal scan demonstrated hyperperfusion of the whole anterior left temporal region (although a limited data set, this was also seen on comparison with the interictal scan), postictal scan showed left mesial temporal hyperperfusion (arrowed) with lateral temporal hypoperfusion, and the interictal scan showed left temporal hypoperfusion



**Figure 6.12:**  $^{99m}\text{Tc}$ -HMPAO SPECT scans from patient T12. The postictal scan shows left medial temporal hyperperfusion (arrow) with relative hypoperfusion of the temporoparietal region; the interictal scan shows hyperperfusion of the left frontoparietal region (arrow).

to the seizure focus; after a postictal injection (one 43 seconds after seizure cessation and one an unknown time after seizure cessation, but less than 60 seconds) both showed changes of medial temporal hyperperfusion and lateral hypoperfusion, a phenomenon reported in mesial temporal lobe epilepsy in adults (Newton *et al.*, 1992b) (Fig. 6.6)

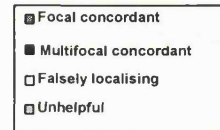Focal hyperperfusion with relative hypoperfusion of the ipsilateral cerebral hemisphere was more striking in postictal scans than ictal scans where focal hyperperfusion was demonstrated (Fig 6.12). It was seen in five out of six scans on children with temporal lobe epilepsy, and was also seen in three of the five postictal scans of children with extratemporal epilepsy.

#### **6.5.6. Interictal scans**

Forty two of the of the 64 scans reviewed (66%) were found to have an abnormality concordant with the seizure focus; in 29 (45%) this was an area of focal hypoperfusion or absence of activity (19 temporal, two extratemporal and eight hemisynndrome) and in 13 (20%) an area of hypoperfusion extending over more than one lobe (five temporal, six hemisynndrome and two extratemporal). Fifteen scans were determined as having no asymmetry of perfusion. Seven scans showed focal hypoperfusion of one area nonconcordant with the seizure focus; in three this was correctly localising but incorrectly lateralising, and in one the same side as the seizure focus.

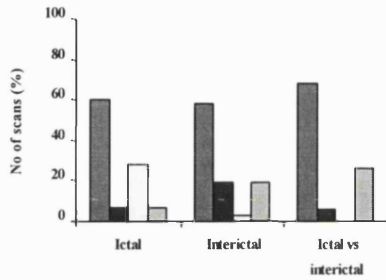
**Figure 6.13: Overall results of ictal, immediate postictal and interictal SPECT scans in temporal, extratemporal and hemisindrome epilepsy**

Legend for figures

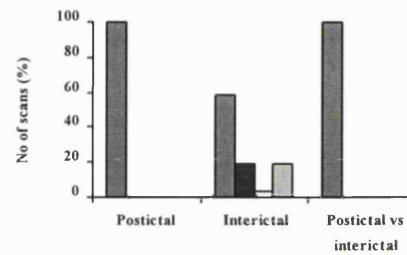


**Temporal lobe epilepsy**

**a) Ictal**

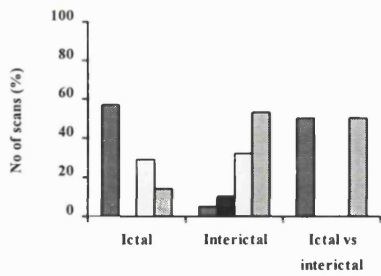


**b) Postictal**

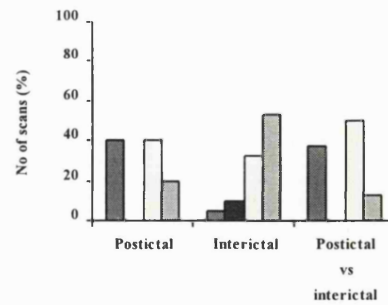


**Extratemporal epilepsy**

**a) Ictal**

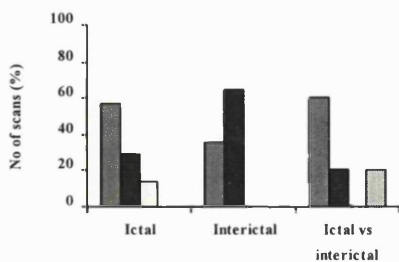


**b) Postictal**

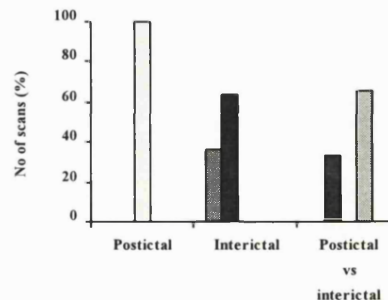


**Hemisyndromes**

**a) Ictal**



**b) Postictal**





### ***6.5.7 Ictal vs interictal scans***

Twenty six of the 36 ictal scans (72%) showed an area of hyperperfusion concordant with the seizure focus when compared to interictal scans; in 22 this was focal and four multifocal. In ten cases no difference was seen between ictal and interictal scans; in eight of these ten (five temporal, one extratemporal and two hemisyndrome) a focal area of hypoperfusion concordant with the seizure focus was seen on interictal scan, with the same findings on ictal scan with no additional area of hyperperfusion (Section 7.4).

Nine of the 17 (53%) postictal scans showed an area of focal hyperperfusion when compared to the interictal scans, concordant with the seizure focus. In five scans (28%) the difference suggested an area of abnormality nonconcordant with the seizure focus, and were therefore termed as 'falsely localising'.

## ***6.6 Ictal/postictal rCBF in special situations***

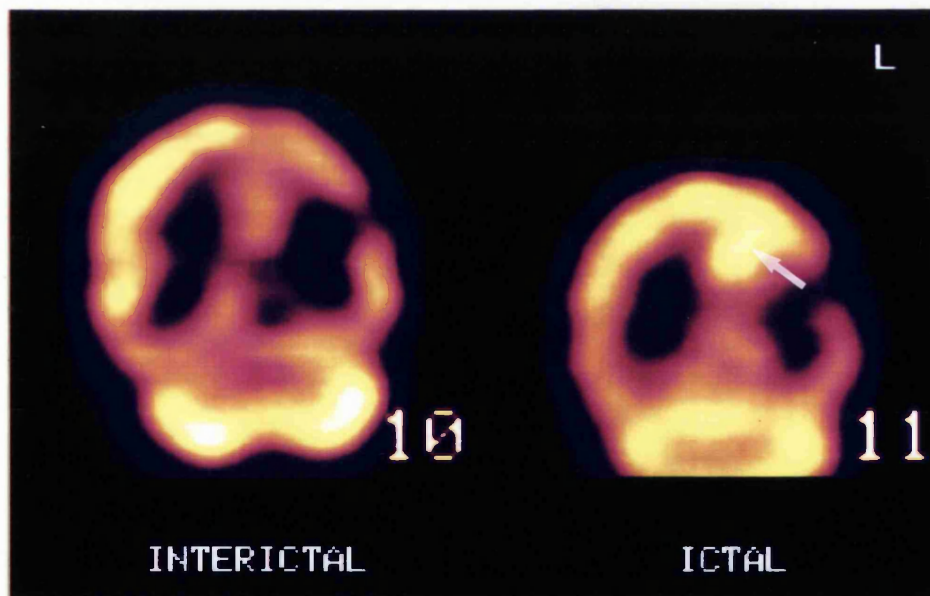
### ***6.6.1 Secondary generalisation***

Six children underwent ictal injection of HMPAO during a seizure that secondarily generalised (see Table 6.1). The timing of injection ranged from 0-39 seconds into the secondary generalisation. Four children showed hyperperfusion concordant with the seizure focus (focal in three); injection was 0-28 seconds into the secondary generalisation, with secondary generalisation 26-45 seconds into a seizure of 60-103 seconds duration. One of these (patient H3) demonstrated persistent focal clinical features at the time of injection (Fig 6.14).

**Table 6.1: Details of six children who underwent injection during secondary generalisation**

Patient	Focus	MRI	Seizure duration (secs)	Injection time (secs)	2° generalisation (from seizure onset)	Ictal scan	Interictal scan	Ictal vs interictal
T15	LTLE	LHS	109	85	46	180	L temporo-parietal hypoperfusion	No difference
T18	RTLE	Normal	60	33	26	R temporal hyperperfusion	R temporo-parietal hypoperfusion	R temporal
T26	LTLE	L temporal FTL	77	35	35	R temporal hyperperfusion	Left temporal hypoperfusion	No difference
T29	LTLE	L temporal DNET	98	36	36	180	180	Left temporal
E2	RF	R frontal cortical dysplasia	103	47	45	180	No asymmetry	R frontal
H3	L (R hemi)	L MCA infarct	72	54	26	Inc perfusion adjacent to area of absence	Absence of perfusion L frontocentral	L parietal

*180° refers to limited data set available for review (see section 6.5.2)*



**Figure 6.14:  $^{99m}\text{Tc}$  HMPAO SPECT scans, coronal section perpendicular to the temporal lobes from patient H3. The interictal scan showed absence of activity in the left frontocentral region, concordant with the left MCA infarct on MRI. The ictal scan showed a similar area of absence of activity, but in addition showed an area of hyperperfusion in the parietal area, immediately adjacent to the absence (arrow).**

The timing of injection relative to secondary spread in the remaining two of the six children was 0 and 39 seconds, with secondary generalisation at 35 and 46 seconds into a 77 and 109 seconds seizure respectively, both of assumed temporal lobe origin. The former showed no difference in perfusion on ictal scan when compared to the interictal scan, ie there was unilateral temporal hypoperfusion concordant with the seizure focus. The second showed possible unilateral temporal hypoperfusion concordant with the focus, when compared to the interictal scan. Neither of these children showed persistent focal clinical features during the secondary generalisation.

#### ***6.6.2. Hyperventilation***

Only four children in the current study (all with temporal lobe epilepsy) underwent injection of HMPAO in relation to a seizure that occurred following a period of hyperventilation. In three this was an ictal injection and one an immediate postictal injection. In scans following two of the three ictal injections, focal hyperperfusion was seen of one temporal lobe ipsilateral to the seizure focus; in the third child and the child where a postictal injection was obtained, there was no difference between ictal and interictal scans with hypoperfusion of the ipsilateral temporal lobe.

#### ***6.6.3 Ictal/postictal scans in unlocalised epilepsy***

Two children in this study underwent investigation in the absence of any clinical features suggestive of focal epilepsy; both had focal abnormalities on MRI, one unilateral temporal lobe atrophy and one an arachnoid cyst with hypoplasia of that temporal lobe. The first child underwent an ictal and an interictal scan; the ictal scan showed focal

hyperperfusion of the mid portion of the temporal lobe in question and the interictal scan showed hypoperfusion of a similar but wider area of the temporal lobe (Chapter 7, Fig 7.2). The second child underwent an immediate postictal and an interictal scan; the interictal scan demonstrated absence of activity in the area of the arachnoid cyst. The postictal scan showed a similar area of absence of activity but in addition, an area of focal hyperperfusion anterior to this in the orbitofrontal region.

### **6.7 Discussion**

Previous reports of ictal  $^{99}\text{Tc}^{\text{m}}$  HMPAO SPECT have suggested a high rate of hyperperfusion concordant with the seizure focus in temporal and extratemporal epilepsy, both in adults and children (Berkovic *et al.*, 1993; Harvey *et al.*, 1993a; Harvey *et al.*, 1993b; Marks *et al.*, 1992; Newton *et al.*, 1992a; Newton *et al.*, 1992b; Stefan *et al.*, 1987a). The results of the current study demonstrate a high rate of perfusion abnormalities in a group of children presenting with focal epilepsy for presurgical evaluation, but the overall yield of ictal focal hyperperfusion concordant with the seizure focus (68%) is much lower than that reported in the majority of the above studies (91-99%).

The children within this study are a consecutive group presenting for presurgical assessment with a clinical/EEG suggestion of focal epilepsy, and as outlined in Chapter 2, I have taken the standard of the clinical/EEG focus with which to compare results of other investigations. This is a fairly broad assumption and will inevitably lead to error as the only proof that this is correct is seizure freedom following surgical resection. Only a proportion of the patients within this study have gone on to surgical resection, the

majority within the temporal lobe epilepsy and hemisindrome groups. One previous study of 28 subjects with temporal lobe epilepsy who underwent ictal and postictal studies reported that for analysis of results only those with a localised MRI abnormality were included, SPECT in these patients giving correct localisation of the focus in 93%, but in their overall series only 75% showed localising changes (Duncan *et al.*, 1993), a figure comparable with this study.

For reporting of results in this study, I have relied on visual assessment of the scans. This was verified using a semiquantitative colour scale with documentation of the percentage asymmetry. Problems have arisen with regard to quantitation as it is not possible to quantify absolute rCBF using HMPAO. Clinically useful and reproducible methods of quantitation have not been possible in view of the spontaneous conversion of the primary to secondary complex and the kinetics between this, the first pass uptake and back-diffusion. Methods useful for research purposes have been reported, including the application of kinetic models (Murase *et al.*, 1992), arterial blood sampling (Pupi *et al.*, 1991) and the use of intravenous radionuclide angiography (Matsuda *et al.*, 1992; Matsuda *et al.*, 1993). Clinical studies have used semiquantitation of data to verify first line double blind reporting by experienced nuclear medicine physicians (Duncan *et al.*, 1993; Harvey *et al.*, 1993a; Newton *et al.*, 1992b; Rowe *et al.*, 1991b; Rowe *et al.*, 1989). The semiquantitative methods reported involve selecting regions of interest and comparing them to a constant region of the brain or the whole brain as a 'perfusion index' (Hooper *et al.*, 1990; Mountz *et al.*, 1994)

Several problems arise when considering the use of regions of interest (ROI's) in

assessing SPECT scans. Interobserver error is more likely where there has been manual selection of a slice angle, or when the ROI is manually placed, particularly for a technique with poor anatomical spatial resolution such as SPECT (Neirinckx *et al.*, 1988; Syed *et al.*, 1992). It is important also that the size of ROI used is not smaller than the spatial resolution of the system used, for significant partial volume effects may then occur. Absolute values of activity cannot be used in view of the variation in dose, decay and washout of the tracer at the time of data acquisition. For the purpose of this study side to side asymmetry of perfusion, with comparison of mirror image regions, was used for interpretation of data looking for an area of hyperperfusion in an ictal/postictal study and an area of hypoperfusion in an interictal study. Semiquantitative analysis of the data revealed 12.5% asymmetry as that maximising the number demonstrating focal abnormality, and minimising those showing multifocal asymmetry, with 10% in interictal studies. Side to side asymmetries reported in other groups in scans of normal individuals have been between 7% (Duncan *et al.*, 1993) and 15% (Duncan *et al.*, 1996), and as can be seen from the results here, in the majority where asymmetry on visual inspection is obvious, the asymmetry is markedly greater than this value. Care is required, however, on interpretation of asymmetry close to this percentage, and on repeat analysis. Of more significance is that the majority of children within this study underwent two scans, with an injection made in one of two clinical states, and the scans compared to each other looking for a difference in rCBF. In essence therefore each who that underwent both ictal/postictal and interictal scans acted as his/her own control. Not only did such a comparison verify a suspected change in perfusion between states where asymmetry was not marked and increase the predictive yield of ictal scans in TLE and ETE, but more importantly it appeared to reduce or indeed abolish the rate of false localisation.

The results of the current study demonstrate a change in cerebral perfusion pattern, dependent on the timing of injection in relation to the seizure, which is similar to that reported in previous studies in both adults and children (Duncan *et al.*, 1993; Hajek *et al.*, 1991; Newton *et al.*, 1992b; Rowe *et al.*, 1991b; Rowe *et al.*, 1989). The lowest yield of abnormality concordant with the seizure focus was noted following an interictal injection. In temporal lobe epilepsy, the rate of abnormality (58%) was higher than adult studies (39%; Rowe *et al.*, 1991b, 48%; Hajek *et al.* 1991), although there was a further 16% where a perfusion defect was noted over more than one lobe, including the assumed seizure focus, a finding seen elsewhere (Hajek *et al.*, 1991).

Ictal and immediate postictal injections in temporal lobe epilepsy gave similar yields, although far higher than interictal injections. Although numbers are small, the postictal scans in children with TLE showed concordant focal hyperperfusion in 100% of cases. Of particular note was the change in pattern of rCBF seen in two patients who had scans following both an ictal and an immediate postictal injection, a change from unilateral temporal hyperperfusion seen following an ictal injection to medial hyperperfusion and lateral hypoperfusion seen after a postictal injection, a finding reported in adults with TLE (Duncan *et al.*, 1993; Newton *et al.*, 1992b). This pattern was seen in four of the total six postictal scans in temporal lobe epilepsy. Whereas this change has been reported to occur when the injection has been made greater than 30 seconds after a seizure has ceased, at least one of the children in this study who showed these changes had the injection 13 seconds after seizure cessation. All four children in the current study were thought to have hippocampal seizures; the two children with a postictal injection

demonstrating lobar hyperperfusion had neocortical seizures. These factors demonstrate the need for an accurate knowledge of the timing of the injection relative to the onset and offset of the seizure prior to accurate interpretation of the SPECT scans.

The yield in extratemporal epilepsy from ictal, postictal and interictal scans was disappointingly low, although that from ictal/postictal scans was higher than from interictal scans. This was increased if the ictal scans were compared with interictal scans, and such a comparison, as indicated above, also reduced the rate of apparent false localisation of the seizure focus. However it was also seen that although focal hyperperfusion was seen in around 60% of children with ETE following an ictal injection, an immediate postictal injection gave a much lower yield (40%), even after comparison with interictal scans. This is disappointing in view of the difficulty in obtaining a true ictal injection in extratemporal epilepsy, as seizures are traditionally shorter than temporal lobe seizures, confirmed in this study. A short duration of seizure has been postulated as accounting for lack of perfusion change during extratemporal seizures, but hyperperfusion was seen in one child with a seizure duration of nine seconds. Whereas postictal injections appear to show a recognisable perfusion change in TLE, this does not appear to be the case in ETE. It is difficult to comment on whether the yield would be improved with a higher resolution scanner, although good results have been demonstrated elsewhere with a single headed camera (Harvey *et al.*, 1993). The results may be related to the type of patients selected; very few of this population have gone on to surgery and such patients have therefore presented problems in accurate seizure localisation. It is difficult to determine whether clinical/EEG localisation is indeed accurate, and in view of the known difficulty in localisation within this group, invasive recording could still hold some



answers. A number of children demonstrated hyperperfusion of the area contralateral to that thought on clinical/EEG data to be the focus. Review of EEG data did not reveal any evidence of intraictal spread, although ictal EEG data at the time of injection were only available in about half of this group (see Chapter 7). With the knowledge that difficulties can arise in localising and lateralising frontal lobe seizures, it may be that further investigation such as invasive monitoring would reveal SPECT to be more reliable than the current study suggests, by demonstrating the SPECT abnormalities rather than clinical suspicion to be correct.

One concern that could be expressed in the interpretation of ictal/postictal SPECT scans is that changes in perfusion may be influenced by activation phenomena known to influence CBF, that is overbreathing or hyperventilation. This is a technique known to provoke seizures in certain epilepsy syndromes, most commonly typical absence epilepsy. This technique is also recognised as increasing discharges on EEG, as well as provoking seizures, in focal and other forms of epilepsy (Miley and Forster, 1977). Hyperventilation may produce slowing of the EEG, which could be interpreted as an ischaemic effect, and has been demonstrated in association with a reduction in cerebral blood flow as determined by Doppler flowmetry of the common carotid artery (Yamatani *et al.*, 1995). Such a manoeuvre could therefore be postulated as having an effect on rCBF in focal epilepsy. Only a small number of children within this study had a seizure for study following such a manoeuvre. However, the demonstration of focal hyperperfusion of the ipsilateral temporal lobe in two of three children who underwent an ictal injection implies that hyperventilation is unlikely to affect results in such studies.

Another factor that could be assumed to influence whether focal hyperperfusion is seen after an ictal injection is if the injection is made at a time of known spread of the seizure, i.e. at a time of secondary generalisation. Six children in this study had injection of HMPAO during seizures that secondarily generalised. Scans of four of these children demonstrated focal hyperperfusion concordant with the seizure focus, one of whom had persisting clinical focal features during secondary generalisation. A small number of studies have been reported of SPECT obtained during secondarily generalised seizures; Lee *et al* reported three HIPDM ictal studies that had demonstrated focal hyperperfusion after injection during secondary generalised seizures (Lee *et al.*, 1987). Two were injected immediately prior to the tonic phase, and one 42 seconds after the onset of generalisation. There is no comment as to whether there were persisting focal features within this seizure. Others have reported a poor yield from such injections. Rowe *et al* reported ipsilateral temporal hyperperfusion in six of 11 postictal scans (Rowe *et al.*, 1991a), four of whom demonstrated persistent focal clinical features during secondary generalisation, and Harvey *et al* reported similar findings in two of three children with TLE, in both of whom the injection was made greater than 30 seconds prior to secondary generalisation (Harvey *et al.*, 1993a). Although numbers are small, these and our own results suggest that ictal SPECT may be localising when an injection is made during secondary generalisation, but may be dependent on the timing of the injection in relation to this or on whether there are other persisting localising features to the seizure.

This study has demonstrated that ictal/postictal and SPECT can be carried out in children with focal epilepsy in routine clinical practice, and that the results may contribute to the localisation of the seizure focus, particularly where ictal SPECT has been carried out.

However, care has to be taken in the interpretation of such scans, particularly with respect to the timing of the injection in relation to the seizure, and with respect to the likely seizure origin, whether temporal or extratemporal, although scans should also be interpreted in the light of other data available. Of particular relevance is the fact that focal hyperperfusion at the seizure focus may only be seen in around 70% of cases, and there appears to be a definite group where no perfusion change is seen between the ictal and interictal state. This will be discussed further in the following chapter.

***Publication arising from this work***

**Cross JH, Gordon I, Jackson GD, Boyd SG, Todd-Pokropek A, Anderson PJ, Neville BGR (1995)** Children with intractable focal epilepsy: ictal and interictal  $^{99}\text{Tc}^{\text{m}}$  HMPAO single photon emission computed tomography. *Dev. Med. Child Neurol.* **37**, 673-681 (II)

**Table A6.1: Results of ictal/interictal SPECT in children with temporal lobe epilepsy**

Patient	Clinical/EEG focus	MRI	Ictal	% asymmetry	Interictal	% asymmetry	Ictal vs interictal
T2	Left temporal	Left hippocampal atrophy	180°		No asymmetry	12.5	Left temporal
T3	Left temporal	LHS + L signal change L temporal lobe	Hyperperfusion left temporal lobe	>15	Left temporal hypoperfusion	12.5	Left temporal
T4	Left temporal	LHS + signal change L temporal lobe	Left anteromedial temporal hyperperfusion with posterior reduction	>15	Left temporal, frontoparietal hypoperfusion	10	Left temporal
T5	Left temporal	LHS + signal change L temporal lobe	Right temporal hyperperfusion	12.5	Left temporal hypoperfusion	12.5	No difference
T6	Left temporal	LHS	Hyperperfusion left anteromedial temporal region, with posterior reduction	>15	Left temporal hypoperfusion	12.5	Left temporal
T8	Left temporal	Normal	Left anterior temporal hyperperfusion	>15	Left anterior temporal hypoperfusion	7.5	Left anterior temporal
T10	Right temporal	RHS	Right mid/anterior temporal hyperperfusion	>15	Hypoperfusion right anterior temporal lobe	>15	Right anterior temporal
T14	Left temporal	Thickened parietal cortex, L temp atrophy	Hyperperfusion right temporo-occipital region	>15	Hypoperfusion left temporo-occipital lobes	12.5	No difference
T15	Left temporal	LHS	180°		Left temporoparietal hypoperfusion	10	No difference
T18	Right temporal	Normal	Hyperperfusion right mid/posterior temporal lobe	>15	Hypoperfusion right parietotemporal region	5	Right temporal
T19	Left temporal	LHS	Left temporal hyperperfusion	10	Hypoperfusion left temporal lobe	7.5	Left temporal
T26	Left temporal	FTL L middle temporal gyrus	Right temporal hyperperfusion	10	Left temporal hypoperfusion	12.5	No difference
T29	Left temporal	L mesial temporal FTL	180°		180°		Left temporal
T35	Left temporal	L posterior temporal FTL	Hyperperfusion right temporal lobe	>15	Hypoperfusion left temporal lobe	>15	No difference
T31	Right temporal	FTL both hemispheres + RHS	180°		Hypoperfusion right temporal lobe	12.5	Right temporal
T32	Left temporal	L mesial temporal FTL + LHS	Hyperperfusion left anterior temporal region, posterior reduction	>15	Left temporal hypoperfusion	10	Left temporal
T36	Temporal	Bilateral occipital gliosis, L temporal & L hippocampal atrophy	No asymmetry	10	Hypoperfusion left mid temporal lobe	>15	Left temporal
T37	Left temporal	FTL L temporal, frontal, parietal	Left frontotemporal hyperperfusion	>15	180°		Left frontotemporal

180° = limited data set, see section 6.5.2

**Table A6.2: Results of ictal/interictal SPECT in children with extratemporal and hemisindrome epilepsy**

Patient	Clinical/EEG focus	MRI	Ictal	% asymmetry	Interictal	% asymmetry	Ictal vs interictal
E2	Right frontal	R frontal cortical dysplasia	1. 180° 2. No asymmetry	10	1.No asymmetry 2. Left temporal hypoperfusion	10	1.Right frontocentral
E6	Right frontal	R parieto-occipital atrophy & signal change	Hyperperfusion right frontal dorsolateral region + absence R parieto-occipital*	10	1.Hypoperfusion right frontal dorsolateral region + absence * 2. As above		Right frontal dorsolateral
E7	Left frontal	L frontal FTL	Right frontal hyperperfusion	>15	Left frontal hypoperfusion	12.5	No difference
E8	Right parietal	LHS	Right parietal hyperperfusion	>15	Left parietal hypoperfusion	12.5	No difference
E9	Right frontoparietal	General cytoarchitectural change	Right parietal hyperperfusion	7.5	No asymmetry	10	Right parietal
E10	Right frontal	Atrophy/signal change R occipito-parietal junction + RHS	Left parietal hyperperfusion	>15	Hypoperfusion right parietal	>15	No difference
E11	Left frontal	L frontal cortical dysplasia	Left frontal hyperperfusion	12.5	No asymmetry	10	Left frontal
H1	Left frontocentral	L parietal high signal + LHS	180°		left parietal hypoperfusion	>15	Left parietal
H2	Right	R hemiatrophy + RHS	180°		Hypoperfusion right cerebral hemisphere	>15	Right frontoparietal
H3	Left	L MCA infarct + L hemiatrophy	Absence activity left frontocentral region, with increase left parietal	>15	Absence activity left frontocentral region		Left parietal
H4	Left	Encephalomalacia L hemisphere + LHS	Absence left hemisphere with increase left occipital	>15	Absence left cerebral hemisphere	>15	Left occipital
H7	Right	R MCA infarct +RHS	Absence right frontoparietal region	>15	Absence right frontoparietal region	>15	No difference
H8	Right	R hemisphere thickened cortex, high signal	Hyperperfusion right dorsolateral frontal region	7.5	Hypoperfusion right dorsolateral frontal region	7.5	Right dorsolateral frontal
H9	Left	L hemimegalencephaly	Left frontal hyperperfusion	10	Left cerebral hypoperfusion	>15	Left frontal
H10	Left temporo parietal	L parieto-occipito-temporal dysplasia	Hyperperfusion left temporo-occipital region	>15	Hypoperfusion left temporo-occipital region	>15	Left temporo-occipital
H11	Right	R cerebral dysplasia	Hyperperfusion right temporoparietal region	10	180°		No difference
H12	Left	L hemiatrophy	180°		180°		Left frontocentral and temporal
U1	Unlocalised	R temporal atrophy	Right temporal hyperperfusion	10	Right temporal hypoperfusion	12.5	R temporal

180° = limited data set, see section 6.5.2

**Table A6.3: Results of postictal/interictal SPECT**

Patient	Clinical/EEG focus	MRI	Postictal	% asymmetry	Interictal	% asymmetry	Postictal vs interictal
T2	Left temporal	LHA	Left medial temporal hyperperfusion	7.5	Left temporal hypoperfusion	12.5	Left medial temporal
T10	Right temporal	RHS	Right medial temporal hyperperfusion	10	L parietal hypoperfusion	>7.5	Right temporal
T11	Left temporal	LHS + signal change L temporal lobe	Left medial temporal hyperperfusion	>15	1. Left temporal hypoperfusion 2. No asymmetry	>15	Left temporal
T12	Left temporal	LHS + signal change L temporal lobe	Left medial temporal hyperperfusion	12.5	Left frontoparietal hypoperfusion	10	Left medial temporal
T30	Left temporal	FTL L ant/inf temporal lobe	180°		No asymmetry	>7.5	Left temporal
T34	Temporal	FTL R temporal lobe + RHS	Right temporal hyperperfusion	>15	Right temporal hypoperfusion	>15	Right temporal
E1	Right frontal	Normal	180°		No asymmetry	12.5	Left frontal
E3	Right frontal	General cytoarchitectural change	Left frontal dorsolateral hyperperfusion	10	No asymmetry	>12.5	Left dorsolateral
E4	Right frontal	Normal	Left frontal hyperperfusion	5	Left frontal hypoperfusion	5	Left frontal
E12	Right frontal	Normal	1. 180° 2. No asymmetry	10	1. No asymmetry 2. No asymmetry	10 12.5	Right mid temporal and insula
E13	Frontal	Normal	Left frontocentral	>15	No asymmetry	12.5	Left frontocentral
E14	Right frontal	Normal	180°		Right temporal hypoperfusion	7.5	Right temporal
E15	Right	R frontal thickened cortex	Right frontal hyperperfusion	10	No asymmetry	12.5	Right frontal
H13	Left (R hemi)	L MCA infarct + L hemiatrophy	Hyperperfusion right frontal dorsolateral/parietal region	>15	Hypoperfusion left frontal dorsolateral/parietal region	>15	No difference
H14	Left (R hemi)	Encephalomalacia L hemisphere	Hyperperfusion R hemisphere and absence of activity left parietal region	>15	Hypoperfusion L hemisphere and absence of activity left parietal region	>15	No difference
H15	Right (L hemi)	R MCA infarct	Absence of activity right parietal/frontocentral region	>15	Absence of activity right parietal/frontocentral region	>15	No difference
U2	Unlocalised	L temporal arachnoid cyst + hypoplasia	Absence activity left temporal region + hyperperfusion left orbitofrontal	5	Absence activity left temporal region + hypoperfusion left orbitofrontal	10	Left orbitofrontal

180° = limited data set, see section 6.5.2

**Table A6.4: Results of remaining interictal SPECT scans, where there was no ictal/postictal scan performed**

Patient	Clinical/EEG focus	MRI	Interictal SPECT	% asymmetry
T1	Left temporal	LHS	Left temporal hypoperfusion	>15
T9	Left temporal	LHA	Left temporal hypoperfusion	10
T16	Right temporal	RHS + R hemiatrophy	No asymmetry	
T22	Right temporal	RHS	Right temporal hypoperfusion	>15
T23	Right temporal	R temporal gliosis	Right temporal hypoperfusion	10
T25	Right temporal	RHS	1. No asymmetry 2. Right temporal hypoperfusion	1. 5 2. 12.5
T38	Right temporal	R temporal/amygdala FTL + RHS	Right temporal hypoperfusion	>15
T39	Temporal	Thickening temporal neocortex	Left temporoparietal hypoperfusion	10
E16	L frontal	Normal	1. Right parietal hypoperfusion 2. No asymmetry	10
H5	Right (L hemi)	Right hemimegalencephaly	Hypoperfusion right cerebral hemisphere	12.5
H6	Left (R hemi)	L cerebral atrophy & signal change	Hypoperfusion left cerebral hemisphere	>15
H16	Left (R hemi)	L porencephalic cyst	Hypoperfusion left hemisphere with absence of activity left frontoparietal region	>15

## CHAPTER 7

### SPECIFIC PATTERNS OF REGIONAL CEREBRAL BLOOD FLOW DURING SEIZURES

---

#### Contents

- 7.1 *Introduction*
  - 7.2 *Relationship of ictal/postictal rCBF to magnetic resonance imaging*
    - 7.2.1 *Patient population*
    - 7.2.2 *Results*
  - 7.3 *Regional cerebral blood flow in subcortical structures*
    - 7.3.1 *Basal ganglia*
    - 7.3.2 *Cerebellum*
  - 7.4 *Regional cerebral blood flow in relation to the 'seizure focus'*
    - 7.4.1 *Patient population*
    - 7.4.2 *Results*
  - 7.5 *Discussion*
    - 7.5.1 *Relationship*
    - 7.5.2 *Conclusions to ictal rCBF to pathology*
    - 7.5.3 *Ictal perfusion of subcortical structures*
    - 7.5.4 *Focal hypoperfusion in relation to the seizure focus*
- 

#### 7.1 Introduction

Although there have been many studies of rCBF during seizures, the underlying mechanisms responsible for the commonly reported increase remain poorly understood. It may be postulated that this increase is caused by increased metabolic demands, although the stimulus for, and control of, increased blood flow remains unclear. There have been relatively few studies investigating cerebral metabolism during focal seizures.

<sup>18</sup>Fluorodeoxyglucose positron emission tomography (<sup>18</sup>FDG PET) scans are difficult to obtain ictally, but those reported describe both an increase (Chugani *et al.*, 1994; Engel, Jr. *et al.*, 1983; Franck *et al.*, 1986; Kuhl *et al.*, 1980) and decrease (Engel, Jr. *et al.*,



1983) in cerebral glucose metabolism at the seizure focus and other structures. Where this has been compared to rCBF, a parallel increase in each has been demonstrated (Franck *et al.*, 1986; Kuhl *et al.*, 1980), with no increase in oxygen consumption (Franck *et al.*, 1986).

Animal studies have demonstrated a close correlation (or 'coupling') between cerebral blood flow and glucose metabolism in normal tissue (Kuschinsky *et al.*, 1981). There appear to be two components to this coupling; static coupling related to the local capillary density which is in turn closely related to the metabolic rate of a region (Klein *et al.*, 1986), and dynamic coupling dependent on the regulatory action on cerebral resistance vessels. There is evidence that cerebral autoregulation is abolished in generalised tonic clonic status epilepticus (Plum *et al.*, 1968); whether or not this occurs locally in focal seizures is not known but is unlikely to be an important mechanism in increasing rCBF as there is no evidence that the large increases in blood pressure seen in generalised tonic clonic status epilepticus occur in this situation. The moderate delay seen in the increase in blood flow following seizure onset would suggest a local metabolic change. In particular ion exchange may be responsible (Heiss *et al.*, 1979), for example potassium and hydrogen ions (the latter coupled with adenosine) are known to have a direct vasodilatory action on arterioles (Kuschinsky *et al.*, 1972; Kuschinsky and Wahl, 1978).

A vasodilatory response of the cerebral vasculature to acidosis (directed by hydrogen ions and adenosine) is only seen if there is a mismatch between oxygen/glucose demand and delivery (Shinozuka *et al.*, 1989). Studies of cerebral metabolism and blood flow in seizures demonstrate that there is no increase in oxygen consumption, that glucose

utilization exceeds that of oxygen, and oxygen delivery appears to exceed that required (Franck *et al.*, 1986). Neuronal excitation as manifest by an increased frequency of action potentials releases potassium ions from nerve cells into the extracellular space, which can then have a direct action on arterioles (Kuschinsky and Wahl, 1979). Extracellular concentrations of  $K^+$  returns to normal values faster than blood flow however (Plum and Duffy, 1975), and therefore a further mediator is likely to be involved in causing a sustained ictal increase in rCBF. Recent data suggests that intraendothelial and postsynaptic nitric oxide is the most likely candidate (Gally *et al.*, 1990; Iadecola *et al.*, 1994; Pearce and Harder, 1996). The overall mechanism is likely to be multifactorial, with focal seizure discharges causing an increase in local blood flow through release of metabolites, and such rCBF being enhanced by a higher capillary density at an active seizure focus. Animal studies have suggested capillary density is related to the number of synaptic structures rather than neuronal mass (Dunning and Wolff, 1937).

Although the elucidation of further evidence to support these theories lie beyond the remit of this study, correlation of the ictal/postictal SPECT findings with the other investigative techniques could not only help to explain their relative specificity in localisation of the seizure focus, but also provide further data as to the underlying pathophysiology of focal seizures.

## ***7.2 Relationship of ictal/postictal rCBF to magnetic resonance imaging***

It may be surmised that the pattern of regional cerebral blood flow seen during or immediately following a seizure may in part be determined by the underlying pathology. This could in turn be influenced by the extent of tissue involved in seizure onset. The

numbers in this study are small, in particular the responsible pathologies are diverse.

However, in order to examine whether there was any relationship between pathology and pattern of rCBF, ictal/postictal rCBF was reviewed according to MRI findings (see Table 7.1).

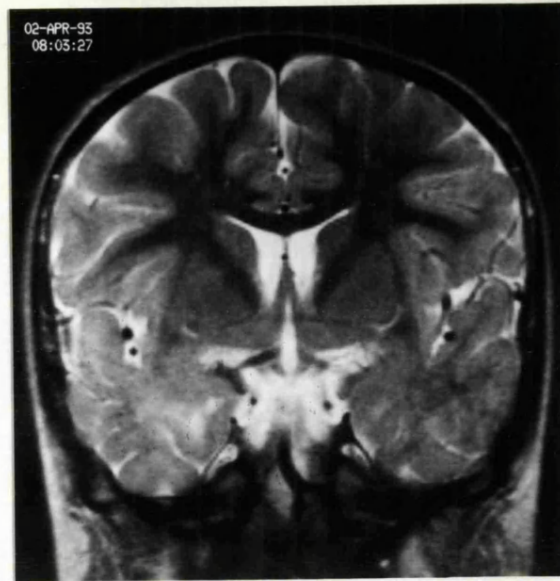
### ***7.2.1 Patient population***

For the purpose of this part of the study, the SPECT results as described in Section 6.5.8 were compared with the results of magnetic resonance imaging. This involved analysis of 55 ictal/postictal scans and corresponding interictal scans of 51 children described in Section 6.5.1, and their respective MRI scans (and where possible confirmed pathology) as described in Chapter 3. Complete data are documented in the Appendix of Chapter 6.

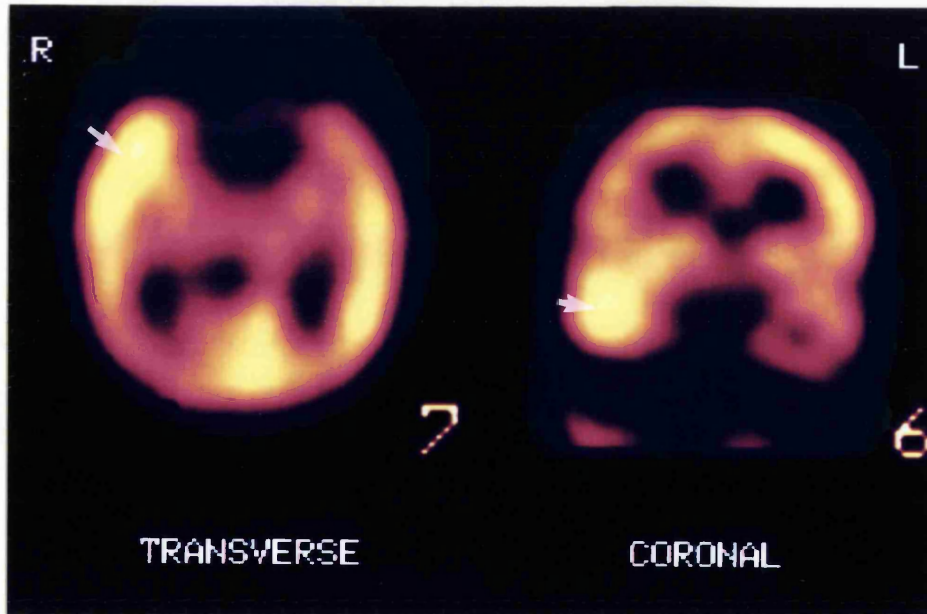
### ***7.2.2 Results***

In children with TLE who had hippocampal sclerosis on MRI (see Table 7.1) temporal lobe hyperperfusion was seen on nine of 12 ictal or postictal scans relative to interictal scans. This hyperperfusion was usually of the whole temporal lobe and was not restricted to the mesial temporal region, regardless of whether associated neocortical abnormalities (other than foreign tissue lesions) were seen. Five of seven children with a FTL of the temporal lobe demonstrated concordant temporal hyperperfusion; in the five concordant cases, the anterior temporal regions (mesial in four) were involved (Fig 7.1), whereas in the two where SPECT was unhelpful, both lesions were of the lateral and posterior temporal lobe and ictal/postictal SPECT demonstrated no change from the interictal SPECT (that is hypoperfusion of the respective area).

A

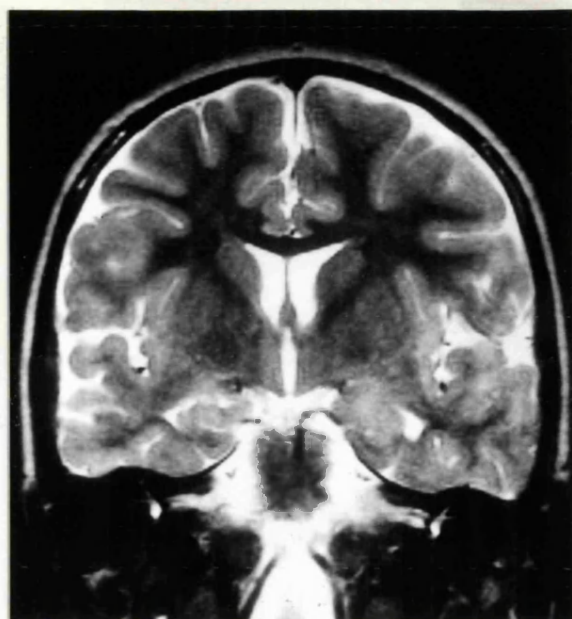


B

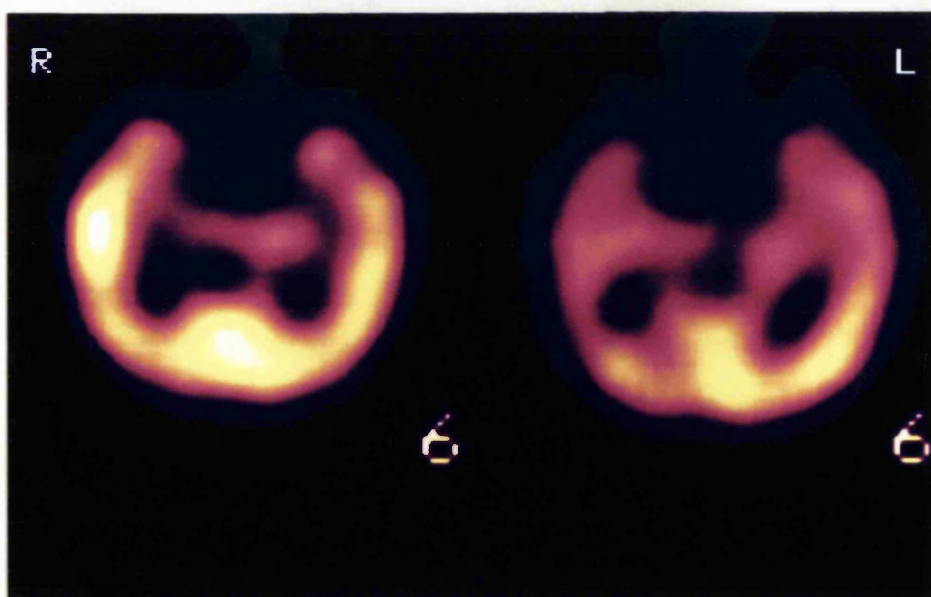


**Figure 7.1: Coronal sections perpendicular to the temporal lobe, T2 weighted sequence MRI (A), and  $^{99}\text{Tc}^{\text{m}}$  HMPAO SPECT scans (B) of patient T34. MRI shows foreign tissue lesion of the right mesial temporal region (microdysgenesis at pathology). Postictal SPECT shows hyperperfusion of the right temporal region.**

A



B



**Figure 7.2: Coronal sections perpendicular to the temporal lobes, T2 weighted sequence MRI (A) and <sup>99</sup>Tc<sup>m</sup> HMPAO SPECT scan (B) of patient U1. MRI shows atrophy of the right temporal lobe. Ictal SPECT shows hyperperfusion of the right mid temporal region, compared to a wide area of hypoperfusion of the right temporal lobe seen on interictal scan.**

**Table 7.1: Abnormality seen on the comparison of 55 ictal/postictal SPECT to respective interictal scans in 51 children related to MRI findings**

	Lobar increase		Multilobar increase		No asymmetry		Unhelpful	
	I	PI	I	PI	I	PI	I	PI
Hippocampal sclerosis <i>TLE (N=12)</i>	6	3	0	0	0	0	3	0
Developmental <i>TLE (N=1)</i>	0	1	0	0	0	0	0	0
<i>ETE (N=3)</i>	2	1	0	0	0	0	0	0
<i>Hemisyndromes (N=5)</i>	3	0	2	0	0	0	0	0
Tumour <i>TLE (N=7)</i>	4	1	0	0	0	0	2	0
<i>ETE (N=1)</i>	0	0	0	0	0	0	0	1
Porencephaly/cyst <i>TLE* (N=1)</i>	0	1	0	0	0	0	0	0
<i>Hemisyndromes (N=6)</i>	2	0	0	0	0	0	1	3
Rasmussens encephalitis <i>TLE (N=2)</i>	1	1	0	0	0	0	0	0
<i>Hemisyndromes (N=2)</i>	2	0	0	0	0	0	0	0
Focal atrophy <i>TLE (N=2)**</i>	1	0	0	0	0	0	1	0
<i>ETE (N=2)</i>	1	0	0	0	0	0	1	0
Normal/no focal lesion <i>TLE (N=2)</i>	1	0	1	0	0	0	0	0
<i>ETE (N=9)</i>	2	5	0	0	0	2	0	0

*I=ictal PI=postictal*

*\*includes two children with clinically nonlocalised epilepsy, but focal temporal lesion on MRI*

*\*\*includes one child with TLE who proved to have HS at pathology but wider changes were seen on MRI, and one child with unlocalised epilepsy, with temporal lobe atrophy on MRI proven to be dysplasia at pathology.*

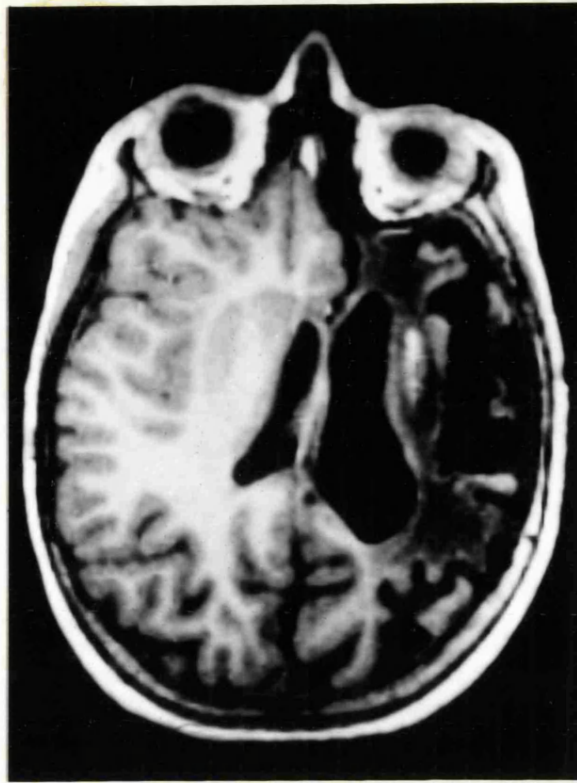All children with a developmental abnormality of the brain demonstrated lobar or multilobar hyperperfusion following ictal injection, concordant with the abnormality on MRI. These included two children proven to have cortical dysplasia at surgery, although the MRI had not been conclusive of this; one of these had unlocalised seizures and temporal lobe atrophy on MRI (patient U1, Fig 7.2) and one had TLE with a normal MRI (patient T18). In the hemisyndrome group the hyperperfusion was usually limited to one

or two lobes of the affected hemisphere, even though the lesion usually involved the whole hemisphere on MRI.

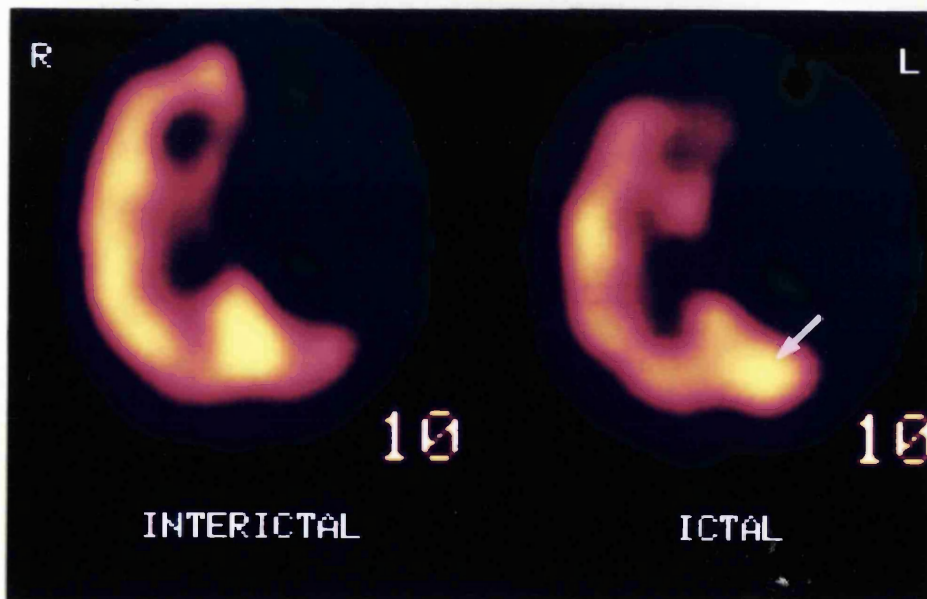
Of the nine scans in eight children with extratemporal epilepsy and no focal extratemporal lesion on MRI (including normal MRI (5), generalised cytoarchitectural change (2) and isolated hippocampal sclerosis (1)), six showed ictal focal hyperperfusion of an extratemporal region but this was only concordant with the lateralisation of the clinical/EEG focus in three. In the remaining three, focal hyperperfusion was seen in an extratemporal region, consistent with the seizure type but discordant with clinical/EEG lateralisation of the seizure focus. In view of the unhelpful structural localisation, this is an important group that as yet has not proceeded to surgical intervention. Of note is the one child with assumed ETE, and with HS as the only abnormality on MRI, who did not demonstrate hyperperfusion of the temporal lobe but of the right parietal region. Two children with TLE had normal MRI; one with proven dysplasia had temporal hyperperfusion (see Fig 7.1) and one with localised anteromedial temporal lobe hyperperfusion was later demonstrated on pathology to have end folium sclerosis.

Six children with hemisyndromes and one with unlocalised epilepsy had a porencephalic or arachnoid cyst demonstrable on MRI scan; all had an area of absence of activity in the region of the cyst but three demonstrated an additional area of adjacent hyperperfusion after ictal injection (Fig 7.3). Three children in the study had pathologically proven Rasmussen's encephalitis (two extratemporal and one temporal). All three demonstrated ictal or postictal focal hyperperfusion of the region believed to responsible for seizures.

A



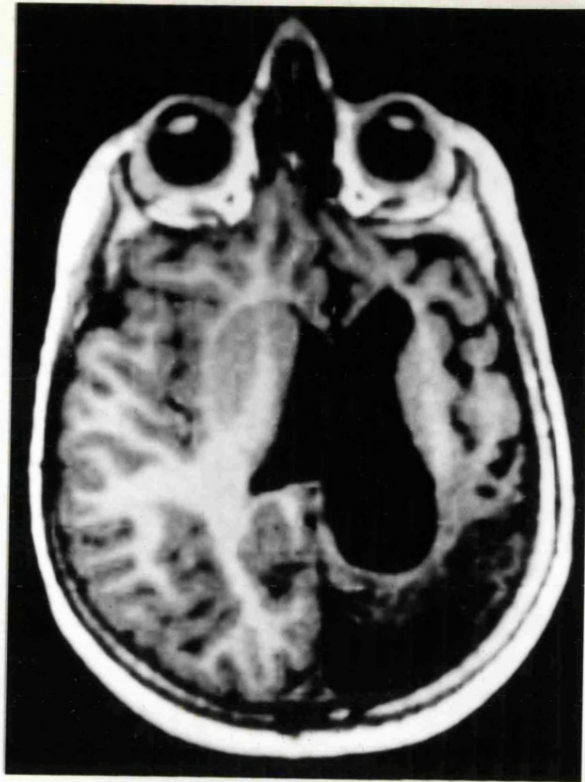B



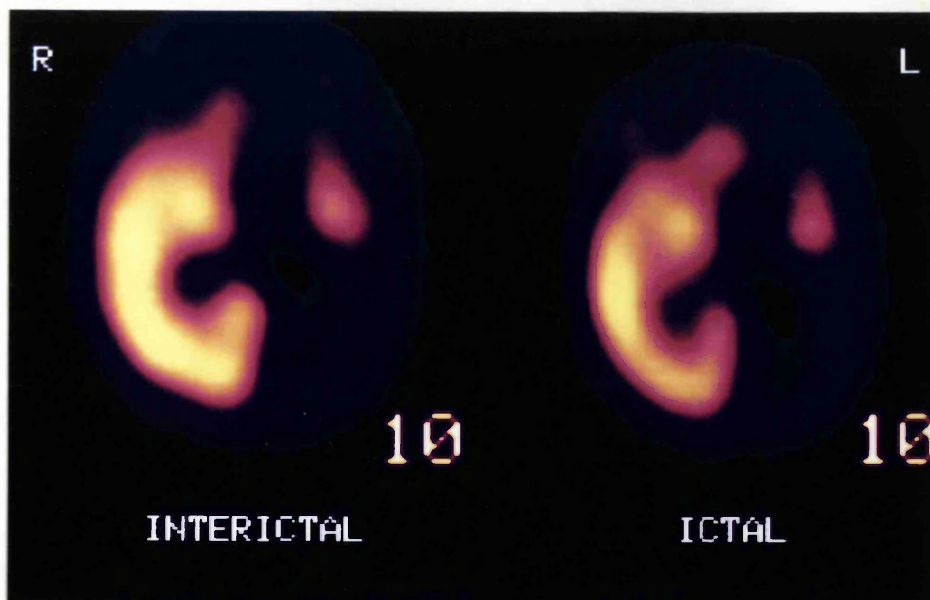
**Figure 7.3:** Transverse sections, MRI (reconstructed from a 3D MP-RAGE data set) parallel to the axis of the temporal lobes (A) and  $^{99}\text{Tc}^m$  HMPAO SPECT scans (B) of patient H4. MRI shows encephalomalacia of most of left hemisphere. Interictal SPECT demonstrates hypoperfusion of most of the left hemisphere; the ictal scan shows a similar picture with an additional area of hyperperfusion in the left occipital region (arrowed).



A



B



**Figure 7.4:** Transverse sections, MRI (reconstructed from a 3D MP-RAGE data set) parallel to the axis of the temporal lobe, (A) and  $^{99}\text{Tc}^{\text{m}}$  HMPAO SPECT scans (B) of patient H14. MRI shows encephalomalacia of most of the left hemisphere. No difference in perfusion is seen between the postictal and interictal SPECT scans. Both show hypoperfusion of the left hemisphere.

### **7.3 Regional cerebral blood flow in subcortical structures**

Changes in perfusion of subcortical structures have been reported during seizures in animals (Ueno *et al.*, 1975) and humans (Penfield *et al.*, 1939; Marks *et al.*, 1992; Newton *et al.*, 1992a; Harvey *et al.*, 1993b; Laich *et al.*, 1997). For this reason the 55 ictal/postictal scans were also reviewed for a change in perfusion in the basal ganglia and cerebellum between ictal/postictal and interictal scans.

#### **7.3.1 Basal ganglia**

Four ictal scans and one postictal scan demonstrated asymmetry of perfusion of the basal ganglia, and a change from the interictal scans; three of four TLE cases showed hyperperfusion of the basal ganglia ipsilateral to the seizure focus and one contralateral. None of these children had dystonia of either side of the body as part of their seizure semiology. One child with ETE demonstrated asymmetry on a postictal scan, with hyperperfusion contralateral to the focus. One child with a hemisindrome, with proven Rasmussen's encephalitis, showed hyperperfusion of the contralateral basal ganglia during the seizure, a switch from hypoperfusion in between seizures. Six further children with hemisindromes demonstrated asymmetry of perfusion of the basal ganglia on ictal/postictal and interictal scans but a similar pattern in the two states, ie there was no difference between the two scans. Five showed reduced or absent activity in the hemisphere ipsilateral to the pathology (four porencephalic cysts and one Rasmussen's encephalitis, this child having loss of the head of the caudate nucleus on MRI) and one contralateral (developmental abnormality).

### **7.3.2 Cerebellum**

Six children demonstrated a change in perfusion pattern of the cerebellar hemispheres when ictal/postictal scans were compared with interictal scans; two with TLE, one ETE and three hemisyndromes. Of the two with TLE, one showed hyperperfusion of the cerebellar hemisphere contralateral and one ipsilateral to the seizure focus. The one child with ETE had a postictal scan and showed hyperperfusion of the ipsilateral hemisphere. All three children with hemisyndromes showed hyperperfusion of the contralateral cerebellar hemisphere.

### **7.4 Regional cerebral blood flow in relation to the 'seizure focus'**

It is clear from the results reported in Chapter 6 that in the group of children investigated here, ictal focal hyperperfusion at the likely seizure focus is not a consistent finding, with focal hyperperfusion predictive of the seizure focus in only 68%, compared to the 91-99% reported in the literature to date (Harvey *et al.*, 1993a; Harvey *et al.*, 1993b; Marks *et al.*, 1992; Newton *et al.*, 1992a; Newton *et al.*, 1992b; Stefan *et al.*, 1987a;). There appears to be a definite group of children where hypoperfusion is seen at the seizure focus after an interictal injection of  $^{99}\text{Tc}^m$  HMPAO, but no change in perfusion is seen after an ictal injection. On review of the findings in this group none of the factors implicated in lack of ictal rCBF change, whether taken singly or in combination, can explain all the cases. The group includes examples of definitely ictal as well as post-ictal injections, and of temporal as well as extratemporal epilepsy. Furthermore, while it might be considered that the resolution of the scan would not be sufficient to detect a change in rCBF where there is extensive pathology of one cerebral hemisphere (see Fig. 7.4), changes were clearly demonstrated in another child with comparable pathology (Fig. 7.3).

To determine whether there were particular characteristics to the group of children demonstrating no ictal perfusion change when compared to an interictal scan, the EEG data were reviewed and compared to those obtained from a further group of children who did demonstrate a perfusion change.

#### ***7.4.1 Patient population***

Of the fifty-one children who were investigated with interictal and ictal rCBF SPECT, 31 had technically satisfactory ictal EEG recordings for the seizure in which  $^{99}\text{Tc}^{\text{m}}$  HMPAO was injected. Of these, seizures could be localised in 25 children on the basis of clinical, EEG and MRI data. Nineteen of these 25 children showed an area of hyperperfusion following the ictal injection of  $^{99}\text{Tc}^{\text{m}}$  HMPAO concordant with the seizure focus. In 17 of these 19, this was concordant with an area of hypoperfusion after the interictal injection; in one there was no asymmetry of perfusion on interictal scan and in one there was hypoperfusion of an area nonconcordant with the seizure focus. The remaining six children showed an area of hypoperfusion after interictal injection that was concordant with the seizure focus, but no perfusion change after ictal injection.

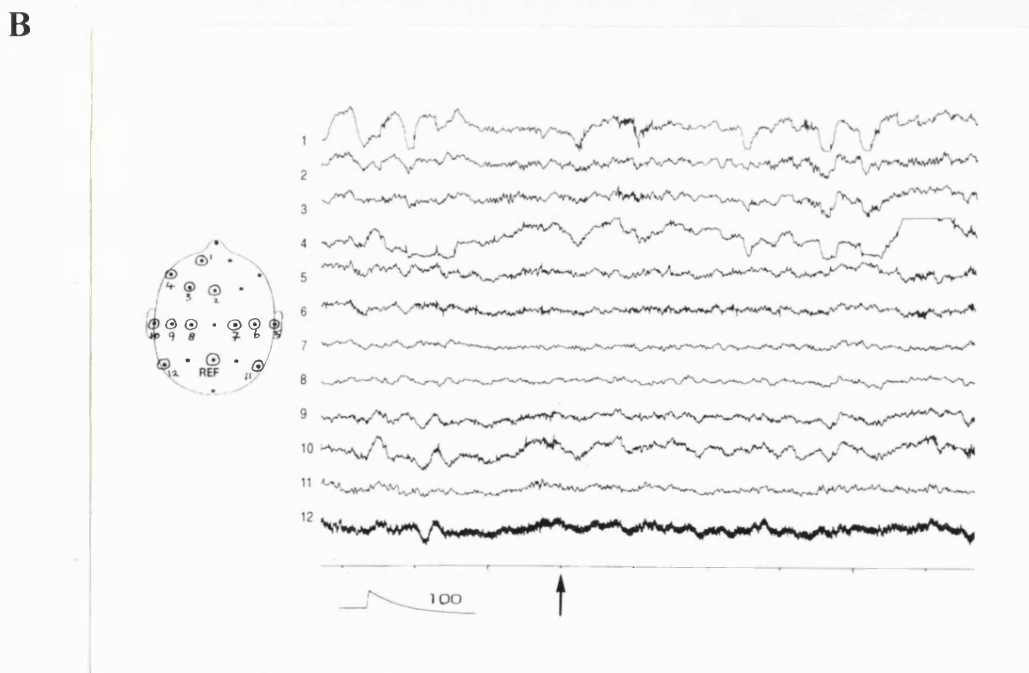
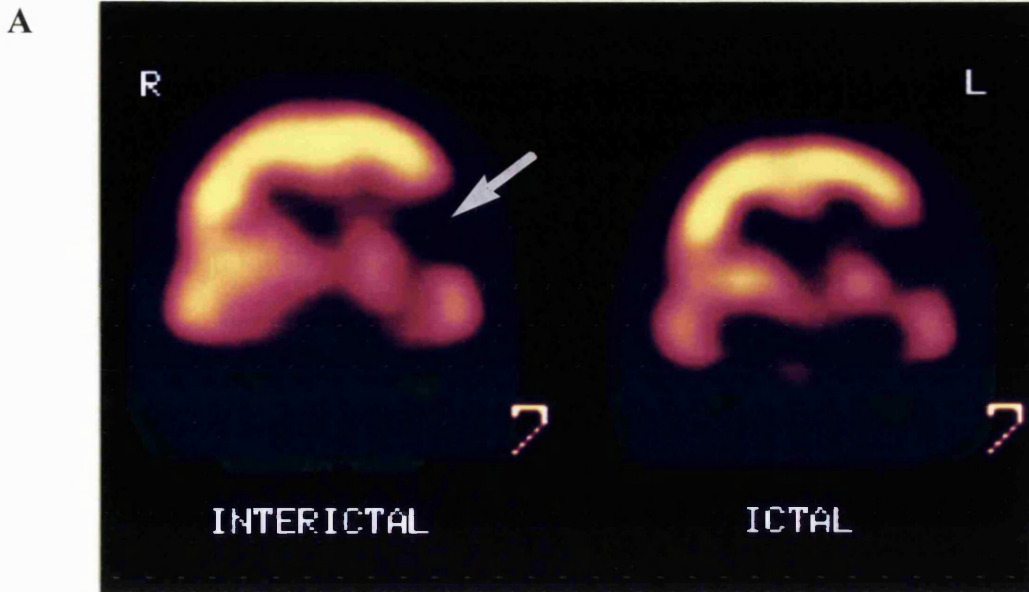
The six children who did not show a perfusion change formed Group 1 for this part of the study. They were then matched as closely as possible with regard to age, timing of  $^{99}\text{Tc}^{\text{m}}$  HMPAO injection, temporal vs extratemporal epilepsy and underlying pathology with a further group of six children (Group 2) who did demonstrate a focal area of hyperperfusion after ictal injection concordant with the seizure focus. The observations from these two groups were compared with those of the remaining 13 children (Group 3).

## 7.4.2 Results

### *i. Group 1*

The mean age of the six children who did not show a perfusion change following ictal injection of  $^{99}\text{Tc}^{\text{m}}$  HMPAO was 11 years 2 months (range 4 years 11 months to 16 years 1 month). Their mean age of onset of epilepsy was two years one month with a mean duration of epilepsy of nine years (Table 7.2). Three had temporal lobe epilepsy and three extratemporal epilepsy (two with hemisyndromes). The range of timing of injection of  $^{99}\text{Tc}^{\text{m}}$  HMPAO from the seizure onset was 24-85 seconds (mean 44 seconds), with a mean duration of seizure 78 seconds; five of the six injections were truly ictal (that is during the seizure) and one was soon after clinical cessation (immediate postictal). The underlying pathology as determined by magnetic resonance imaging was dysembryoplastic neuroepithelial tumour (DNET) in two, porencephalic cyst in two and hippocampal sclerosis in two (Table 7.3, Fig. 7.4).

Interictal and ictal EEG findings are detailed in Table 7.3. The EEG changes were lateralised in five children in this group, and also localised in four. In four children there was slowing of activity relative to the onset of the seizure at the time of  $^{99}\text{Tc}^{\text{m}}$  HMPAO injection (see Fig. 7.5). Two children had slow activity at the onset of the seizure; in one (patient T15) there was attenuation followed by slow activity, with subsequent secondary generalisation at the time of the injection.



**Figure 7.5:**  $^{99m}\text{Tc}$  HMPAO SPECT scans coronal section perpendicular to the temporal lobes (A), and (B) the EEG at the time of injection of  $^{99m}\text{Tc}$  HMPAO of patient E7 (Group 1). Both the interictal and the ictal scans show an area of absence of activity in the left frontoparietal region. EEG at the time of injection (arrow) shows irregular low activity at 2/s

**Table 7.2: MRI and SPECT data of Group 1**

Patient	Age (m)	Age first seizure (m)	MRI	Interictal rCBF SPECT	Length of seizure recorded (secs)	Time of injection of <sup>99</sup> Tc <sup>m</sup> HMPAO (secs)	Ictal rCBF SPECT
T5	193	24	L hippocampal sclerosis + signal change L temporal lobe	L temporal hypoperfusion	167	52	L temporal hypoperfusion
T15	155	12	L hippocampal sclerosis	L temporoparietal hypoperfusion	98 (2 <sup>o</sup> gen at 27s)	62	L temporoparietal hypoperfusion, on comparison interictal (180° acquisition))
T35	68	7	L posterior temporal FTL	Hypoperfusion L temporal region	80	36	Hypoperfusion L temporal region
E7	152	60	L frontoparietal FTL	Hypoperfusion L frontoparietal region	57	32	Hypoperfusion L frontoparietal region
H7	166	30	R MCA infarct	Absence activity R frontoparietal region	40	35	Absence activity R frontoparietal region
H14	59	18	Encephalomalacia L hemisphere	Decreased uptake through whole L hemisphere, absence L parietal region	14	24	Decreased uptake through whole L hemisphere, absence L parietal region

MCA = middle cerebral artery

**Table 7.3: EEG data of Group 1**

Patient	Interictal EEG	EEG at seizure onset	EEG at <sup>99</sup> Tc <sup>m</sup> HMPAO injection	EEG over next 30 seconds
T5	Slow activity L temporal	L anterior temporal 2-3/s, some sharp waves	Marked slowing 1.5-2/s	Returns to 4/s, later slows <2/s
T15	Slow activity 2-3/s, spike wave & spikes, often prominent upper frontal, R>L	Attenuation, then slow activity 1-2/s over both frontotemporal regions	2° generalised, 4-5/s	Generalised, 4-5/s
T35	Spike wave complexes 2/s, L sided	Spike wave 7/s before, then bilateral attenuation, L>R	Rhythmic 3-4/s L posterior temporal	Rhythmic activity 3-4/s L posterior temporal
E7	Irregular L temporal 4-5/s	Abrupt L centrottemporal slowing, 1-1.5/s	L sided 2/s at time of injection	Slowly fades, but 2/s for next 30 secs
H7	Occasional R centrottemporal sharp wave, irregular 4-5/s	Abrupt 10-12/s rhythmic activity R	Attenuation, isolated sharp wave, some slow	Gradually slow fades
H14	2/s spikes/sharp waves L frontal region	Attenuation followed by 10-12/s rhythmic activity over L	Activity slows to 4-5/s	As at injection



### *ii. Group 2*

The mean age of this group was 8 years 4 months (range 9 months to 12 years 5 months) with a mean age of onset of epilepsy of 2 years 5 months and mean duration of epilepsy of six years. Three had temporal lobe epilepsy and three extratemporal epilepsy (three with hemisyndromes). The range of timing of injection of  $^{99}\text{Tc}^{\text{m}}$  HMPAO from seizure onset was 39-78 seconds (mean 54 seconds) with five ictal and one immediate postictal injection. The mean duration of seizure recorded was 72 seconds (range 56-103). The underlying pathology as determined by magnetic resonance imaging was hippocampal sclerosis in two, porencephalic cyst in two, cortical dysplasia in one and DNET in one (Table 7.4, Fig. 7.3,).

Interictal and ictal EEG findings for this group are shown in Table 7.5. The EEG changes were lateralised in all children in this group and also localised in four. Five children had sharp waves and/or rhythmic activity of  $>4/\text{s}$  at the onset of the seizure and this was seen in all children at the time of  $^{99}\text{Tc}^{\text{m}}$  HMPAO injection (Fig 7.6). In only one child (patient H10) was there marginal slowing of  $6/\text{s}$  activity at seizure onset to  $4/\text{s}$  at the the time of injection; this activity was rhythmic throughout.

### *iii. Group 3*

This group of 13 children were those remaining in our series who demonstrated an area of hyperperfusion following ictal injection of  $^{99}\text{Tc}^{\text{m}}$  HMPAO, and who had EEG recordings at the time of injection available for review. Eight had temporal lobe epilepsy and five extratemporal epilepsy (two with a hemisynndrome). They were of mean age 8 years 6 months (range 2 years 6 months to 16 years 4 months) and had a mean duration of

**Table 7.4: MRI and SPECT data of Group 2**

Patient	Age (m)	Age first seizure (m)	MRI	Interictal rCBF SPECT	Length of seizure recorded (secs)	Time of injection of <sup>99</sup> Tc <sup>m</sup> HMPAO (secs)	Ictal rCBF SPECT
T3	116	3	L hippocampal sclerosis + signal change L temporal lobe	L temporal hypoperfusion	81	42	L temporal hyperperfusion
T12	129	18	L hippocampal sclerosis + signal change L temporal lobe	L frontoparietal hypoperfusion	56	69	L medial temporal hyperperfusion
T3a	149	84	L mesial temporal FTL + LHS	L temporal hypoperfusion	78	78	L temporal hyperperfusion with parietal hypoperfusion
H3	105	24	L MCA infarct + L hemiatrophy	Absence activity L frontocentral region	72 (2 <sup>o</sup> gen at 26 secs)	54	As interictal with area hyperperfusion L parietal region
H4	93	40	Encephalomalacia L cerebral hemisphere with atrophy L brain stem	Absence activity L frontal/parietal, with hypoperfusion temporal & occipital lobes	66	39	Hyperperfusion L posterior parietal & occipital
H10	9	0.3	L parieto temporal occipital cortical dysplasia	L temporo - occipital hypoperfusion	82	41	L temporo- occipital hyperperfusion

MCA = middle cerebral artery

**Table 7.5: EEG data of Group 2**

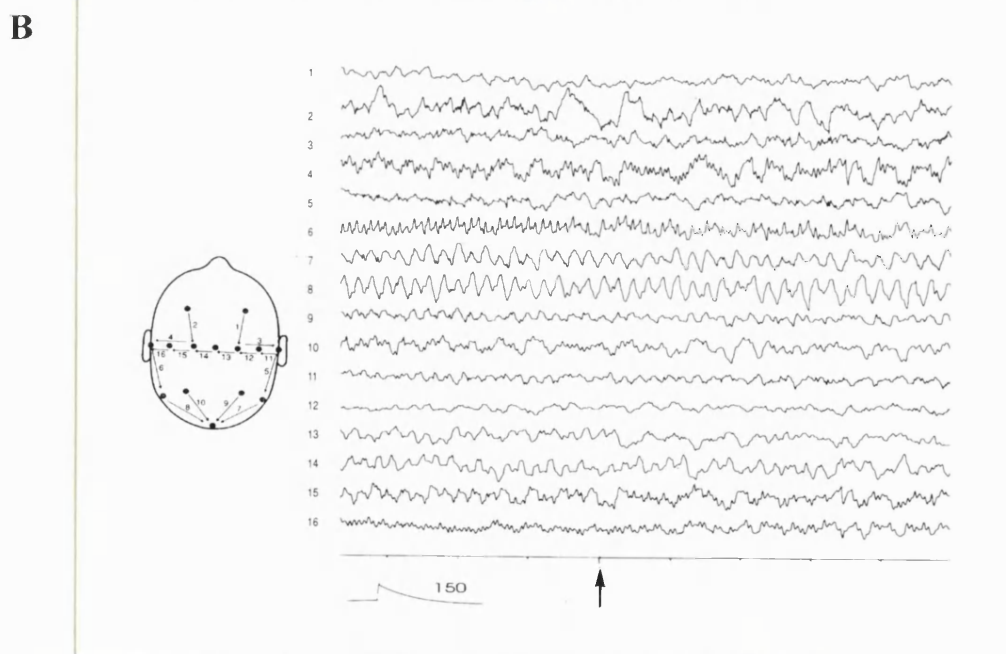
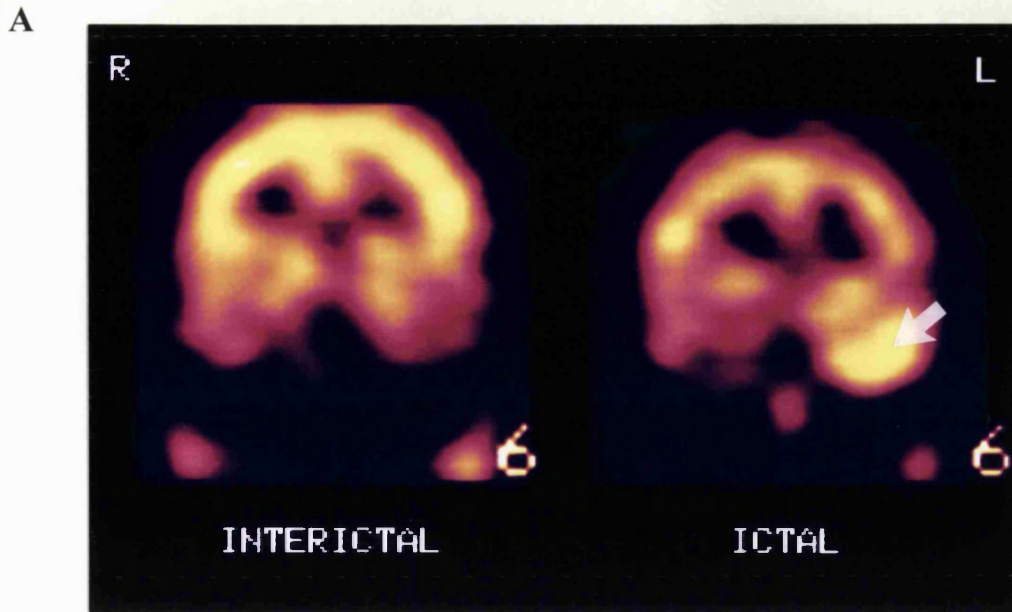
Patient	Interictal EEG	EEG at seizure onset	EEG at <sup>99</sup> Tc <sup>m</sup> HMPAO injection	EEG over next 30 seconds
T3	L mid temporal 2-5/s sharp waves & spikes	2/s sharp waves& runs 4-5/s rhythmic, L	Runs of L temporal spikes with rhythmic activity 4-5/s	Continues as at injection
T12	Frequent epileptiform phenomena bitemporally, L>R	Attenuation, followed by run 2-3/s L anterior temporal	L anterior temporal 6-7/s sharp wave activity	L anterior temporal sharp wave activity 4-5/s continues
T3&	L temporal sharp waves	L temporal rhythmic sharp waves, 3/s, soon increase to 6/s	L temporal rhythmic sharp waves 6-7/s	Stops abruptly 4-5 s after injection, postictal L sided slow 1-2/s
H3	2-3/s L temporal slow with sharp waves	Subtle increase in sharp, 6-7/s	Increase in sharp waves on L with rhythmic 12-14/s over R occipitotemporal	2/s activity, multiple spikes over R, later over L
H4	Intermittent spikes/sharp waves over L hemisphere	Rhythmic fast L anterior region, 10-12/s	Rhythmic sharp waves 4/s	Persists, particularly L temporal
H10	Repetitive L temporo -occipital sharp waves every 2s,	L temporoparietal rhythmic activity 6/s	L temporoparietal rhythmic 4/s	Persists as at injection

epilepsy of 5 years 5 months (range 1 year to 13 years 10 months). The ictal scans included ten where the injections were ictal and three immediately postictal. The MRI in this group demonstrated developmental anomalies in six (dysplasia in four, tuberoses sclerosis in one and DNET in one), hippocampal sclerosis in three, hemiatrophy in one, hippocampal atrophy in one, tumour in one and no abnormality in one.

The EEG data from these children are summarised in Table 7.6. The EEG was lateralising in 11, and also localising in eight. All children in this group showed sharp waves and or rhythmic activity at the onset of the seizure that was maintained at least until the time of  $^{99}\text{Tc}^{\text{m}}$  HMPAO injection: two children with temporal lobe epilepsy showed slowing at the time of injection relative to the onset of the seizure; spikes were also seen in one and a degree of slowing of rhythmic activity in the other (4/s to 2-3/s).

**Table 7.6: Summary of EEG findings in Group 3**

EEG abnormality	EEG at onset of seizure	EEG at time of $^{99}\text{Tc}^{\text{m}}$ HMPAO injection	EEG over next 30 seconds
Sharp waves	8	9	4
Rhythmic activity	5	4	4
Attenuation	0	0	0
Slow activity <4/s	0	0	4
Return to normal	0	0	1



**Figure 7.6:**  $^{99}\text{Tc}^{\text{m}}$  HMPAO SPECT scans, coronal section perpendicular to the temporal lobes (A) and EEG at the time of ictal injection of  $^{99}\text{Tc}^{\text{m}}$  HMPAO (B) of patient T32 (Group 2). Interictal SPECT shows hypoperfusion of the left temporal region, compared to hyperperfusion seen of a similar area on the ictal scan. EEG at the time of injection of  $^{99}\text{Tc}^{\text{m}}$  HMPAO shows rhythmic sharp waves at 6-7/s over the left temporal region (arrow).

## **7.5 Discussion**

### **7.5.1 Relationship of ictal rCBF to pathology**

Ho *et al* have recently correlated findings on ictal SPECT to underlying pathology as determined after surgical resection (Ho *et al.*, 1996). Our findings of temporal hyperperfusion in the majority of children with isolated HS and children with FTL involving the anterior temporal regions are in keeping with the findings in the adults with TLE in Ho's study. The current study, however, also demonstrates cerebral hyperperfusion concordant with the seizure focus in all those with developmental abnormalities on MRI and those confirmed at pathology, as well as those with pathologically proven Rasmussen's encephalitis, a chronic inflammatory condition. There is also a very high rate of focal hyperperfusion seen in those with normal MRI, but disagreement in a proportion, particularly ETE, with the clinical/EEG focus as defined in Chapter 2. It is difficult to know the reliability of the clinical/EEG localisation, and it could be speculated that a proportion may be secondary to underlying developmental abnormalities not seen on MRI.

Development of the cerebral vasculature occurs in parallel with cortical neuronal migration and organisation (Norman and O'Kusky, 1986). However, little is written on developmental anomalies of cerebrovascular architecture in the context of disorders of cerebral development. Radially orientated vessels across the cortex are evident from 15-16 weeks, whereas horizontal branches probably occur sometime after this (Norman and O'Kusky, 1986). The latter occur first in the lower layers of the cortex where neurons first migrate. There is a marked increase in horizontal branching of the vessels coinciding with the time when there is evidence of six neuronal layers

within the cortex at seven months. Abnormal cerebral cortical vessels have been seen to be associated with abnormal neuronal arrangement (Norman, 1980). It is likely therefore that abnormalities in cerebrovascular architecture coexist with abnormalities of cortical development. There may also be coexisting abnormalities in the response of the resistance vessels to metabolites. Such factors could therefore account for the consistent finding of ictal hyperperfusion in areas of cortical maldevelopment seen in this study.

### ***7.5.2 Ictal perfusion of subcortical structures***

A change in perfusion of subcortical structures has been reported in previous studies using ictal SPECT (Harvey *et al.*, 1993; Marks *et al.*, 1992; Newton *et al.*, 1992a; Laich *et al.*, 1997). A unilateral increase in basal ganglia perfusion has been reported ipsilateral to the seizure focus in frontal (associated with contralateral motor activity (Harvey *et al.*, 1993b; Marks *et al.*, 1992)) and temporal lobe (Newton *et al.*, 1992a) epilepsy. However, such abnormalities were seen much less frequently within the current study, and particularly in TLE hyperperfusion of the basal ganglia was not seen in children with dystonia of the contralateral limb as part of their seizure semiology, as has been reported in adults (Newton *et al.*, 1992a).

Of interest were the two children with hemisyndromes with pathologically proven Rasmussen's encephalitis. Although one child demonstrated apparent hyperperfusion of the contralateral basal ganglia structures, this could be interpreted as hypoperfusion of the ipsilateral structures. The second child, who had a much longer history (five years compared to five months for the first child) showed hypoperfusion of the

ipsilateral basal ganglia on ictal and interictal studies, with loss of the head of caudate on MRI. Pathological studies of changes in the cerebral tissue of animals secondary to epilepsy suggest that the caudate nucleus is spared during repeat seizures (Auer and Siesjo, 1988; Nevander *et al.*, 1985), although the globus pallidus is often affected. In rats with bicuculline induced generalised seizures, the globus pallidus demonstrates a high glucose consumption and rCBF early in the seizure that falls as the seizure progresses, whilst in the caudate both parameters continue to increase through the seizure (Ingvar and Siesjo, 1983). Therefore, it is difficult to explain the finding of a relative decrease in rCBF of the basal ganglia in these two children. Although the numbers are extremely small, the SPECT findings provide an aetiological hypothesis that repeated relative ischaemia, possibly related to the underlying disease process, may be responsible for the MRI findings in the child with the longer history.

The number of scans showing a perfusion change in the cerebellum between ictal/postictal states is also very small compared with previous studies (Harvey *et al.*, 1993b; Marks *et al.*, 1992; Laich *et al.*, 1997). However, all three children with hemisyndromes who demonstrated a change showed ictal hyperperfusion of the cerebellar hemisphere contralateral to the seizure focus. This has previously been demonstrated in animals where there is involvement of the sensorimotor cortex within the seizure (Udvarhalyi and Walker, 1965; Ueno *et al.*, 1975), and is probably the result of ictal activation of the known corticocerebellar tracts between sensorimotor cortex and the contralateral cerebellar hemisphere.



### ***7.5.3 Focal hypoperfusion in relation to the seizure focus***

There seems no doubt from results reported in this and the previous chapter that certain children demonstrate no perfusion change between the ictal/postictal and interictal state. To examine this further, we reviewed the EEG and SPECT findings in these children in more detail. This lack of perfusion change, with hypoperfusion of the seizure focus seen on both ictal/postictal and interictal scans, correlated with prominent slowing of the EEG at the time of the  $^{99}\text{Tc}^{\text{m}}$  HMPAO injection. By contrast, where ictal focal hyperperfusion was demonstrated in Groups 2 and 3, it was associated with rhythmic activity and/or sharp waves at that time.

Acute slowing of scalp recorded EEG activities may be ictal, especially where this is rhythmic (Rivello and Foley, 1992). This is usually interpreted as evidence that the seizure onset is relatively distant from the electrodes. However, focal ischaemic changes may also produce localised slow activity, which is often irregular. Such irregular slow activity was found consistently in those children in whom there was no change in an area of hypoperfusion between interictal and ictal scans. The notion that this area of hypoperfusion was concordant with the seizure focus was supported by the successful results of surgical resection in these patients.

Slowing of the EEG seen at the time of  $^{99}\text{Tc}^{\text{m}}$  HMPAO injection was a consistent finding in Group 1, and suggests ischaemia rather than hyperaemia may be occurring during the seizure. Rowe *et al* (Rowe *et al.*, 1991a) correlated EEG findings (depth or sphenoidal) with postictal rCBF SPECT and found that the degree of postictal slow activity at the time of injection of  $^{99}\text{Tc}^{\text{m}}$  HMPAO was significantly associated with the

presence of lateral temporal hypoperfusion, consistent with our data. Hyperventilation tends to produce slowing of the EEG, as discussed in Section 6.7, and has been demonstrated in association with a reduction in cerebral blood flow (Yamatani *et al.*, 1995). Three of the children under study here had seizures triggered by hyperventilation; one from Group 1 (patient T5) and two from Group 3. In view of the demonstration in the two from Group 3 of a clear area of temporal hyperperfusion concordant with the seizure focus, associated with rhythmic sharp waves at the onset of the seizure and at  $^{99}\text{Tc}^{\text{m}}$  HMPAO injection, it is unlikely that hyperventilation influenced the results in patient T5.

Although the EEG findings in this study suggest that there may be relative ischaemia, rather than hyperfusion, during focal seizures in some children, we were unable to determine whether there was further hypoperfusion on the ictal scan relative to the interictal scan as absolute quantitation of rCBF using  $^{99}\text{Tc}^{\text{m}}$  HMPAO was not possible. Penfield originally described 'cortical anaemia' from arterial vasoconstriction during focal seizures induced by intraoperative stimulation (Penfield, 1933). Following further observations Penfield suggested a sequence of events involving capillary dilatation during the seizure, and arterial vasoconstriction following the seizure, but still recognised that the latter could occur during the seizure. More recent studies using laser Doppler flowmetry during subdural monitoring of focal seizures in humans have also shown that a reduction in cerebral blood flow may occur in some cases (Ronne-Engstrom *et al.*, 1993). A decrease in rCBF may make tissue susceptible to further damage. However, the numbers of children involved in this study are small

and therefore it is not possible to comment on differences in clinical features between Groups 1 and 2 such as seizure semiology and cognitive function.

#### **7.5.4 Conclusions**

The results reported in this chapter are instructive both in terms of interpretation of ictal/postictal scans, as well as identifying possible factors in the underlying mechanisms involved in focal seizures. There does appear to be a correlation between ictal/postictal hyperperfusion and the underlying responsible pathology. A consistent ictal increase in perfusion is seen in association with developmental pathology, mesial/anterior temporal abnormalities and Rasmussen's encephalitis, and such findings may be instructive on reviewing the scans of children who have no abnormalities demonstrable on MRI. Ictal changes in the perfusion of the basal ganglia and cerebellar hemispheres were seen infrequently in this study. Changes in perfusion of the basal ganglia were not seen associated with dystonia of the contralateral upper limb as has previously been reported (Newton *et al.*, 1992a). However, if changes in perfusion of the cerebellar hemispheres are seen, they may be confirmative that two scans have been obtained from two different time scales in relation to the seizure, and may be suggestive as to the side seizures are arising from. Finally rCBF does not invariably increase at the seizure focus, and EEG changes in a group of such children support a hypothesis that a decrease in rCBF may occur in some cases. This is of practical importance when interpreting ictal and interictal rCBF <sup>99</sup>Tc<sup>m</sup> HMPAO SPECT studies and also emphasises the usefulness of concurrent EEG monitoring at the time of the ictal injection.

*Publication arising from this work*

**Cross JH, Boyd SG, Gordon I, Harper A, Neville BGR (1997)** Ictal cerebral perfusion related to EEG in drug resistant focal epilepsy of childhood *J. Neurol. Neurosurg. Psychiatry* **62**, 377-384. (III)

# CHAPTER 8

## THE PATHOLOGY UNDERLYING INTERICTAL SPECT

---

### Contents

- 8.1 *Introduction*
  - 8.2 *Relationship of interictal rCBF to MRI*
    - 8.2.1 *Patient population*
    - 8.2.2 *Results*
  - 8.3 *Repeat interictal studies*
  - 8.4 *Relationship of interictal hypoperfusion to neuronal loss or damage*
    - 8.4.1 *Patient population*
    - 8.4.2 *Results*
  - 8.5 *Discussion*
- 

### 8.1 Introduction

Early studies of cerebral blood flow in humans with focal epilepsy using  $^{133}\text{Xenon}$  demonstrated both an increase and a decrease in rCBF in between seizures, suggesting a likely variability between seizures depending on the functional status of the brain (Hougaard *et al.*, 1977; Hougaard *et al.*, 1976; Lavy *et al.*, 1976; Touchon *et al.*, 1986). Regional hypometabolism as detected by  $^{18}\text{F}$ FDG PET was later reported as being associated with the seizure focus in 65-80% of individuals with intractable TLE (Engel *et al.*, 1982; Henry *et al.*, 1991; Henry *et al.*, 1993). Studies have since correlated this regional hypometabolism with cerebral perfusion as determined by  $^{13}\text{NH}_3$  PET (Kuhl *et al.*, 1980) and  $\text{H}_2\text{O}^{15}$  PET (Franck *et al.*, 1986; Leiderman *et al.*, 1992), and also pathologically with neuronal loss (Engel *et al.*, 1982).

As discussed in Section 6.2, a SPECT scan following injection of  $^{99}\text{Tc}^m$  HMPAO produces an image that reflects cerebral blood flow. Following an interictal injection of

$^{99}\text{Tc}^{\text{m}}$  HMPAO, a region of low uptake, interpreted as hypoperfusion, has been assumed to be suggestive of the seizure focus in a proportion of cases, although not as reliable as an ictal injection. Comparative studies between  $^{18}\text{F}$ FDG PET and  $^{99}\text{Tc}^{\text{m}}$  HMPAO SPECT have shown that where abnormalities of perfusion are demonstrated by SPECT, they correlate with areas of hypometabolism as detected by PET, but that abnormalities are seen less frequently with SPECT than with PET (Ryvlin *et al.*, 1992; Stefan *et al.*, 1987b). The lack of exact correlation between PET and SPECT has been attributed to the poor spatial resolution of SPECT (Stefan *et al.*, 1987b). However, other factors may come into play involving uptake of HMPAO.

The exact mechanism for retention of  $^{99}\text{Tc}^{\text{m}}$  HMPAO within the brain remains under debate. Its retention has been attributed to an intracellular conversion to the secondary hydrophilic complex, which is consequently trapped. Subcellular fractionation studies have shown a higher uptake of  $^{99}\text{Tc}^{\text{m}}$  HMPAO by the nuclei of neurons than the nuclei of glial cells (Costa *et al.*, 1989). It has been postulated from this that the compound travels from glial cells to neurons and is then retained after conversion to the hydrophilic form (Ahn *et al.*, 1994). Animal and tumour experiments have suggested that glutathione plays a dominant role in the intracellular conversion of primary to secondary complex (Neirinckx *et al.*, 1988; Suess *et al.*, 1992; Suess *et al.*, 1991). Tissues in culture depleted of glutathione have demonstrated a reduced conversion of HMPAO to the hydrophilic form (Neirinckx *et al.*, 1988); a significant correlation has also been demonstrated between uptake of HMPAO and glutathione content within primary brain tumours (Suess *et al.*, 1991). Furthermore the glutathione content of plasma is low compared to intracellular levels and would account for the relatively low conversion rate in plasma

during transfer (Neirinckx *et al.*, 1988) However uptake has been demonstrated even in the complete absence of glutathione (Suess *et al.*, 1992), so it is likely that this is not the only factor influencing HMPAO uptake. It is likely that binding to nondiffusible cell components also plays a part; subcellular fractionation studies in rat brains have demonstrated a high uptake of HMPAO within cell organelles as opposed to its being free within the cytosol (Costa *et al.*, 1989).

An altered metabolic status of brain tissue can also influence uptake. The permeability of nerve cell membranes may be reduced if the phospholipids and other lipid contents are modified by changes in energy metabolism, for example uncoupling of oxidative phosphorylation (Ahn *et al.*, 1994). Changes in oxidative metabolism also affect levels of glutathione, and hence affect the conversion of lipophilic to hydrophilic forms of HMPAO. An increase in water content will also diminish the relative proportion of lipids in the brain tissue, and hence penetration of lipophilic compounds.

Correlative studies comparing each of the presurgical investigations may reveal further information as to the exact information that interictal SPECT is giving us, and hence allow accurate interpretation of the SPECT scans. The aims of this part of the study were i) to examine the relationship of hypoperfusion seen on interictal SPECT to abnormalities seen on MRI, and ii) to obtain further information about the underlying cause of hypoperfusion by comparison of interictal SPECT and <sup>1</sup>H MRS of the mesial temporal regions in children with TLE.

## ***8.2 Relationship of interictal rCBF to MRI***

### ***8.2.1 Patient population***

All interictal scans in which a full data set had been acquired (see Section 6.5.3) and subsequently analysed were reviewed for asymmetry of perfusion. Sixty four scans were therefore available for review and were compared to their respective MRI scans of the individual children (see Chapter 3).

### ***8.2.2 Results***

The findings on interictal SPECT in comparison to visual MRI abnormality are displayed in Tables 8.1-3. Overall, where there was a large structural defect on MRI, there was a corresponding area of hypoperfusion on interictal SPECT. In temporal lobe epilepsy, the area of hypoperfusion tended to be of a larger area than the abnormality on MRI; in children with hippocampal sclerosis, hypoperfusion of the whole anterior temporal region was seen rather than just of the mesial structures alone. However in this group hypoperfusion was either localised to the temporal lobe, or no asymmetry of perfusion was seen. In children with neocortical lesions, with or without hippocampal abnormality, hypoperfusion was more likely to extend beyond the responsible temporal lobe (Fig 8.1). Five of seven children with ETE had hypoperfusion associated with a focal lesion on MRI. In two this extended over a wider area.

The relationship of the extent of hypoperfusion seen on interictal SPECT to the MRI abnormality was particularly seen in hemisindrome epilepsy, where only one child demonstrated a focal area of hypoperfusion more localising than the abnormality on MRI;



in the majority the decrease in rCBF extended over more than one lobe, corresponding to the abnormality seen on MRI (Table 8.2.3).

**Table 8.1. Interictal SPECT compared to MRI in children with temporal lobe epilepsy.**

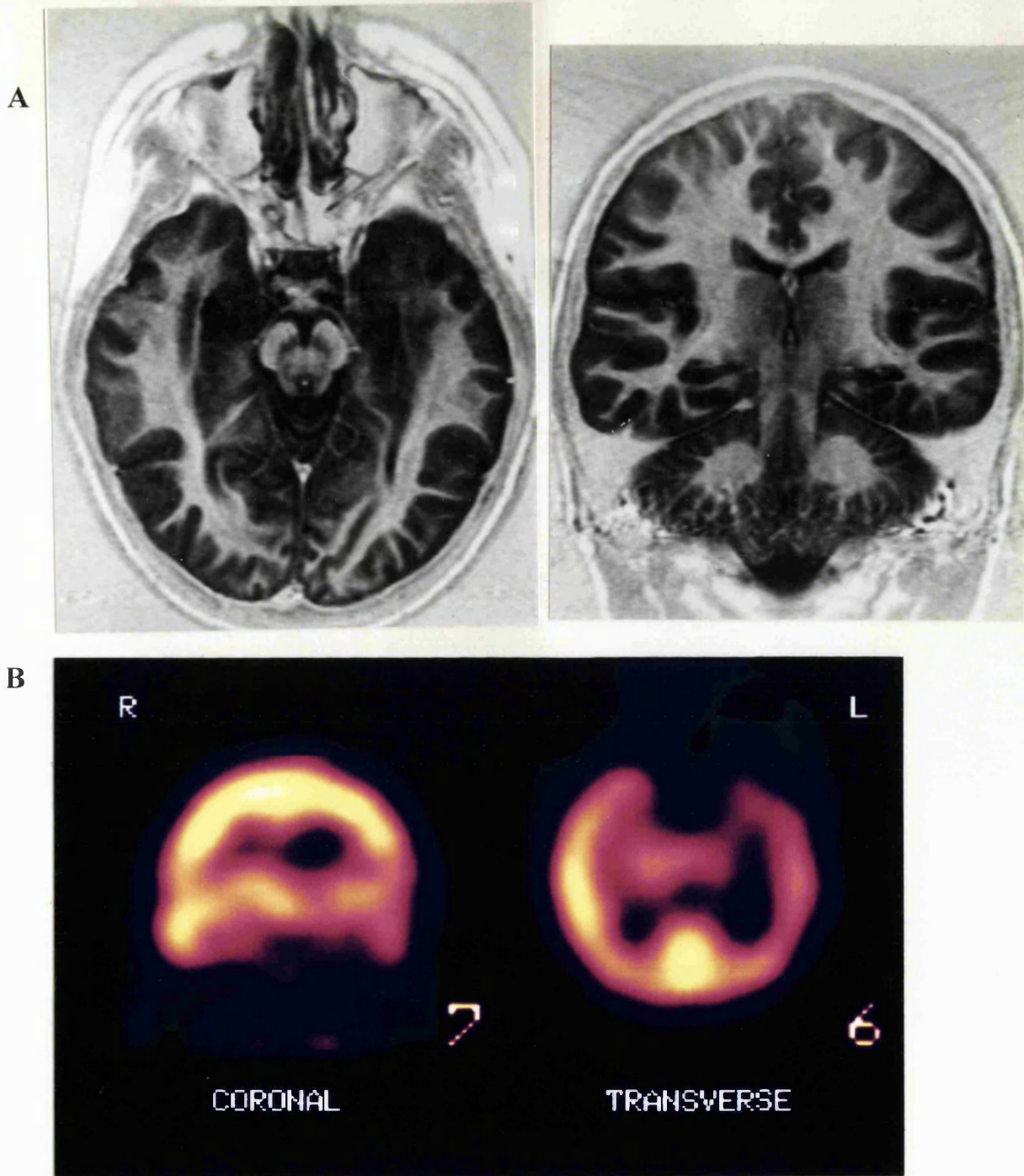
MRI* abnormality	SPECT abnormality			
	Lobar hypoperfusion	Multilobar hypoperfusion	No asymmetry	Discordant hypoperfusion
HS alone	6	0	3	0
HA	1	1	1	0
Hippocampal + other abnormality	5	4	2	1
Temporal abnormality alone	2	3	0	0
Normal	1	1	0	0

*\*see Section 3.4 for MRI definitions*

**Table 8.2: Interictal SPECT compared to MRI in children with extratemporal epilepsy**

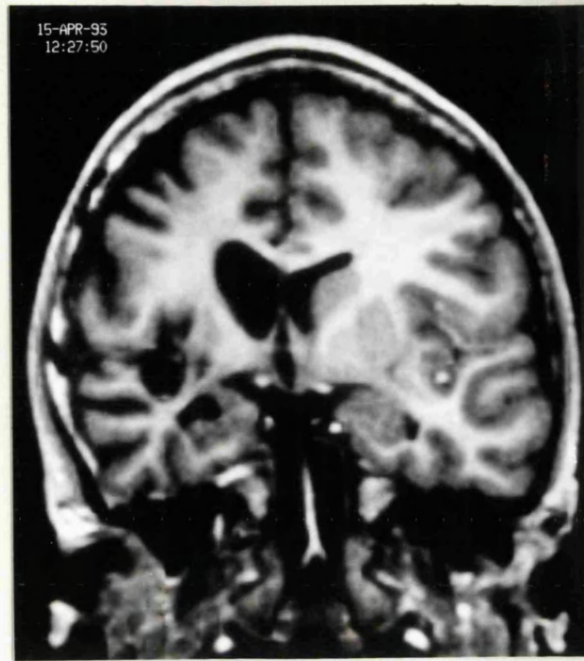
MRI abnormality*	SPECT abnormality			
	Lobar hypoperfusion	Multilobar hypoperfusion	No asymmetry	Unhelpful
Focal extratemporal abnormality	2	3	1	2
Normal	0	0	5	3
Generalised change	0	0	2	0
Hippocampal abnormality	0	0	0	1

*\*see Section 3.4 for MRI definitions*

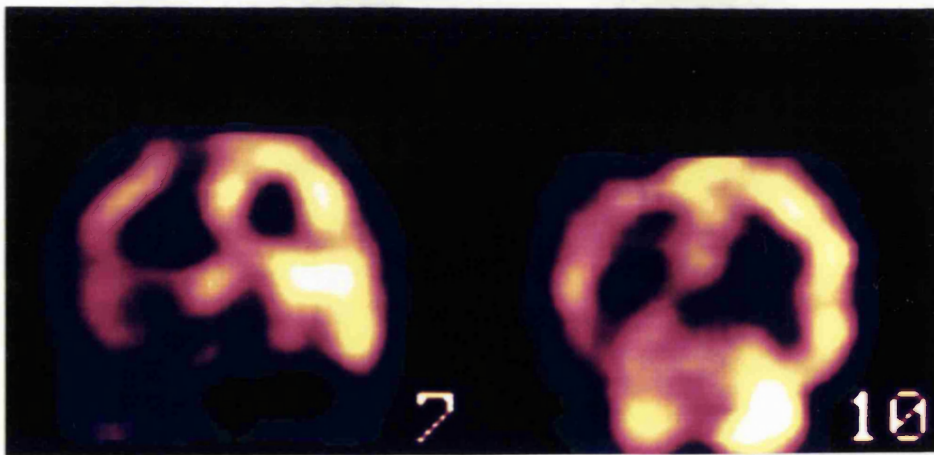


**Figure 8.1: MRI, inversion recovery, transverse and coronal sections (A) and interictal  $^{99}\text{Tc}^m$  HMPAO SPECT scan (B) from patient T4. The MRI shows left hippocampal sclerosis with signal change within the temporal lobe. Interictal SPECT shows hypoperfusion not only of the temporal lobe but also into the frontoparietal regions.**

A



B



**Figure 8.2: MRI, reconstructed from a 3D MP-RAGE data set, coronal section perpendicular to the temporal lobes (A) and interictal  $^{99}\text{Tc}^{\text{m}}$  HMPAO SPECT scan (B) from patient H2. MRI shows atrophy of the whole right hemisphere. Interictal SPECT shows hypoperfusion of the whole of this area.**

**Table 8.3 Interictal SPECT compared to MRI in children with hemisyndromes**

MRI abnormality*	SPECT abnormality			
	Lobar hypoperfusion	Multilobar hypoperfusion	No asymmetry	Unhelpful
Developmental anomaly	1	3	0	1
Porencephaly	2	4	0	0
Cerebral atrophy	0	2	0	0
Focal lesion	1	0	0	0

\*see section 3.4 for MRI definitions

In nine children where MRI was normal, lobar or lateralised multilobar hypoperfusion concordant with the seizure focus was only seen in two children, both of whom had TLE.

All eight interictal SPECT scans performed in the seven children with ETE either demonstrated no asymmetry (five of the scans) or hypoperfusion of an area discordant with the seizure focus (three scans, unhelpful). Children with ETE were more likely to demonstrate an abnormality on interictal SPECT if a lesion was demonstrable on MRI (Table 8.2).

### **8.3 Repeat interictal studies**

Eight children underwent two interictal studies at least six months apart. In three this was as a result of repeat ictal studies more than six months from the first interictal study; the other repeat studies were carried out in two cases for reassessment for epilepsy surgery two years after the first, in two after a two year seizure free period (with parental consent) and in one child with EPC due to concern about the first being entirely interictal.

Of the three children who had repeat scans to compare with ictal studies, only one showed consistent changes. This child was thought to have a right frontal focus, and on both scans showed widespread left cerebral hypoperfusion. One child with temporal lobe epilepsy showed initial left temporal hypoperfusion concordant with the seizure focus, but no asymmetry of perfusion on the second scan. There had been no change in seizure frequency or semiology. The final child had a right frontal focus, and showed hypoperfusion of the left temporal lobe on the initial scan and of the right temporal lobe on a further scan 12 months later.

Two children underwent further interictal studies two years after the first in reassessment for epilepsy surgery, with no change in seizure frequency. Both children on initial scan demonstrated no asymmetry of perfusion, but on the second study showed right temporal hypoperfusion concordant with the seizure focus. Two further children underwent repeat scans after a two year seizure free period; one child with temporal lobe epilepsy initially demonstrated left temporal hypoperfusion concordant with the seizure focus, but on the repeat scans although there was asymmetry of perfusion, this was not significant. The second child had extratemporal epilepsy and showed focal hypoperfusion on the initial scan which was not present on the repeat scan.

The final child, who had left sided EPC, underwent repeat interictal SPECT scan as there were concerns that the first was not truly interictal. A dose of intravenous diazepam was given to stop clinical seizure activity for 30 minutes in both instances. An area of hypoperfusion extending over two lobes including the likely seizure focus (right frontal) was seen on both scans.

#### ***8.4 Relationship of interictal hypoperfusion to neuronal loss or damage***

The results presented in Section 8.2 suggest a high correlation between abnormalities seen on MRI and interictal SPECT. However, repeat study of a small number of children suggest that interictal SPECT may be highly variable in the abnormalities shown. If abnormalities on SPECT were solely due to structural pathology as shown by MRI, it is difficult to explain changes over time, as discussed in Section 8.3. Furthermore, it is difficult to interpret the wide area of hypoperfusion on interictal SPECT scan in children with TLE who have only hippocampal or no abnormality on MRI, as well as the lack of perfusion asymmetry seen in three children with clear unilateral pathology on MRI.

As discussed in Section 6.3.2, SPECT is a semiquantitative technique, in which we rely on side to side asymmetry of perfusion in order to detect abnormality. It could therefore be postulated that if bilateral cerebral damage is present, a similar degree of hypoperfusion (or hypometabolism) may be present on both sides and no asymmetry of perfusion seen. As discussed in Chapter 5,  $^1\text{H}$  MRS of the mesial temporal regions detects abnormalities in TLE, with bilateral abnormalities seen in 45%. To examine the hypothesis that bilateral damage may preclude interictal perfusion asymmetry seen on SPECT, the interictal  $^{99}\text{Tc}^{\text{m}}$  HMPAO SPECT scans and  $^1\text{H}$  MRS of the mesial temporal regions of children with temporal lobe epilepsy within the study population were compared.

#### **8.4.1 Patient population**

This part of the study involved fourteen children with temporal lobe epilepsy who had undergone both interictal  $^{99}\text{Tc}^{\text{m}}$  HMPAO SPECT (as outlined in Section 6.2.3) and  $^1\text{H}$  MRS of the mesial temporal regions (see Section 5.2); children with a foreign tissue lesion seen on MRI were excluded. Clinical information on these 14 children is detailed in Table 8.4. This group of children had a duration of epilepsy from one year to 14 years 11 months (mean 8 years 7 months). Eight had a history of a febrile seizure in early childhood; in all eight this was prolonged. A further four had a history of status epilepticus. Three children in the whole group had their first afebrile seizure at age less than 12 months. All children had a single seizure type at the time of investigation. On the basis of the clinical and EEG criteria used throughout this study, nine children had evidence of a left temporal onset to their seizures and five a right temporal onset.

#### **8.4.2 Results**

##### ***i) Interictal $^{99}\text{Tc}^{\text{m}}$ HMPAO SPECT***

Ten of the 14 children showed hypoperfusion of one temporal lobe; in all ten this was ipsilateral to the clinical/EEG focus. Four children showed no asymmetry of perfusion of the anterior temporal lobes; of these, two showed hypoperfusion of one region outside the temporal lobe. In one, this hypoperfusion was on the same side as the clinical/EEG focus and in the other it was on the contralateral side. The remaining two children demonstrated no abnormality on interictal  $^{99}\text{Tc}^{\text{m}}$  HMPAO SPECT.

**Table 8.4: Details of 14 children with temporal lobe epilepsy who underwent both <sup>99</sup>Tc<sup>m</sup> HMPAO SPECT and <sup>1</sup>H MRS of the mesial temporal regions**

Patient	Age	Age of onset	Seizures/ month	Focus	MRI	<sup>1</sup> H MRS findings (NAA/(Cho+Cr))		<sup>1</sup> H MRS Lateralisation	Interictal <sup>99</sup> Tc <sup>m</sup> HMPAO SPECT
						Right	Left		
T1	14yr 4m	18m	1	Left temporal	Left hippocampal sclerosis	0.63	0.48	Left	Left temporal hypoperfusion
T2	7yr 11m	6yr 10m	60	Left temporal	Left hippocampal atrophy	0.92	0.48	Left	Left temporal hypoperfusion
T3	8yr 5m	3m	30	Left temporal	LHS + signal change L temporal lobe	0.65	0.58	Left	Left temporal hypoperfusion
T4	11yr 8m	2yr	30	Left temporal	LHS + signal change L temporal lobe	0.77	0.60	Left	Left temporo-fronto parietal hypoperfusion
T5	13yr 4m	15m	2	Left temporal	LHS + signal change L temporal lobe	0.72	0.82	None	Left temporal hypoperfusion
T6	17yr 10m	108m	8	Left temporal	Left hippocampal sclerosis	0.89	0.62	Left	Left temporal hypoperfusion
T8	10yr	5yr	4	Left temporal	Normal	0.92	0.84	None	Left anterior temporal hypoperfusion
T10	14 yr	7yr 8m	5	Right temporal	Right hippocampal sclerosis	1). 0.64	1). 0.69	None	1). Left parietal hypoperfusion, no temporal asymmetry 2). Right temporal hypoperfusion
						2). 0.71	2). 0.83	Right	
T11	9yr 10m	16m	12	Left temporal	LHS + signal change L temporal lobe	1). 0.76	1). 0.47	Left	1). Left temporal hypoperfusion 2). Marginal left temporal hypoperfusion
						2). 0.84	2). 0.67	Left	
T12	10yr 7m	15m	10	Left temporal	Left hippocampal sclerosis	0.66	0.56	Left	Left fronto parietal hypoperfusion, temporal lobes symmetrical
T16	9yr 3m	7m	4	Right temporal	Right hippocampal sclerosis	0.48	0.49	None	No asymmetry
T18	5 yr 8 m	6m	20	Right temporal	Normal	0.54	0.68	Right	Right parito-temporal hypoperfusion
T22	10 yr	14m	30	Right temporal	Right hippocampal sclerosis	0.66	0.85	Right	Right temporal hypoperfusion
T25	16yr 11m	2yr	240	Right temporal	Right hippocampal sclerosis	1). 0.62	1). 0.59	None	1). No asymmetry 2). Right temporal hypoperfusion
						2). 0.60	2). 0.88	Right	



The mean age of onset of epilepsy was the same (2 years 10 months) in both the group demonstrating ipsilateral hypoperfusion (range 3 months to 9 years), and the group with no asymmetry of perfusion (range 8 months to 14 years). The group who demonstrated asymmetry had a shorter mean duration of epilepsy (8 years 1 month, range 1 year to 12 years 10 months) compared to the no-asymmetry group (9 years 10 months, range 2 years 11 months to 14 years 11 months), but again there was not a significant difference ( $p=0.43$ ). Mean seizure frequency in the group demonstrating asymmetry was 20/month (range 1-60) compared to 65/month (range 2-240) in the group with no asymmetry ( $p=0.50$ ).

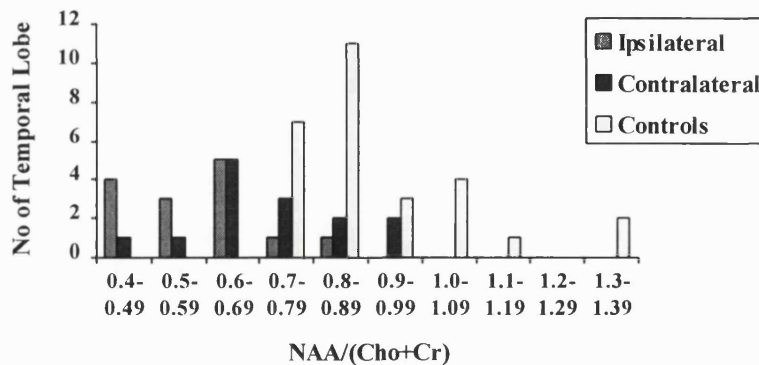
Three of the children who underwent repeat interictal SPECT examinations were included in this part of the study. All had repeat interictal SPECT two years after their first examination; two were undergoing reassessment for epilepsy surgery (Patients T10 and T25, Table 8.4) and one, patient T11, had been seizure free on medication for that period. Patients T10 and T25 on repeat examination had unilateral temporal hypoperfusion concordant with the seizure focus; neither patient had previously demonstrated temporal asymmetry. Patient T11 had only marginal unilateral temporal hypoperfusion that did not reach significance; she previously had demonstrated definite hypoperfusion of that temporal lobe concordant with the seizure focus.

#### ***ii) <sup>1</sup>H MRS***

The results from the mesial temporal lobes of the 14 children in this study are shown in Fig. 8.3 together with the results from the 13 normal subjects reported in Section 5.3. As a group, the subgroup of children in this part of the study showed mesial temporal

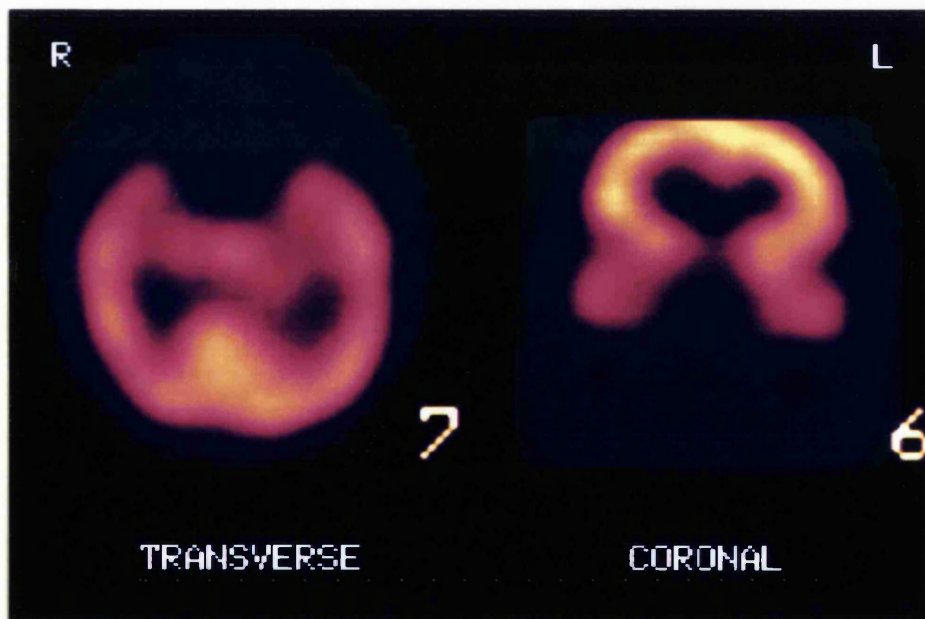
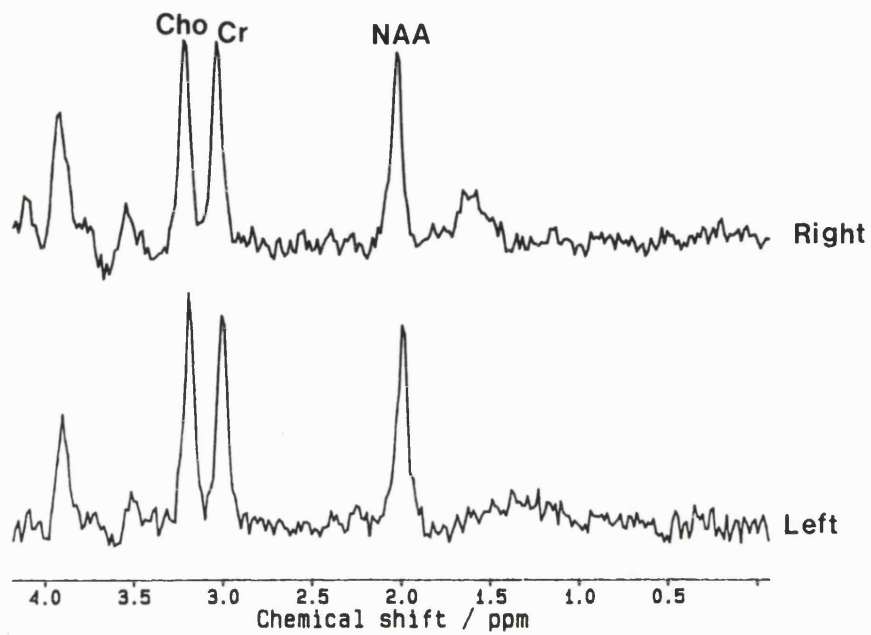
NAA/(Cho+Cr) signal intensity ratios that were lower than normals, and this was more marked in the temporal lobes ipsilateral to the seizure focus rather than contralateral. Five children had unilaterally abnormal ratios of NAA/(Cho+Cr); in all cases, this was on the side ipsilateral to the seizure focus. Seven children had bilaterally low values for NAA/(Cho+Cr); this was correctly lateralising in four of these cases and incorrectly lateralising in none. NAA/(Cho+Cr) ratios were normal on both sides in two children. Of the three children who had undergone repeat studies, patients T10 and 25 (Table 8.4) on the repeat examination had unilaterally low NAA/(Cho+Cr) that was correctly lateralising; previously they had been bilaterally low and nonlateralising. Patient T11 again had a unilaterally low NAA/(Cho+Cr) that was correctly lateralising as before.

**Figure 8.3: Results of <sup>1</sup>H MRS of the mesial temporal regions in the 14 children, ipsilateral and contralateral to the seizure focus, compared to the results from 13 control subjects.**



### *iii) Interictal SPECT vs <sup>1</sup>H MRS*

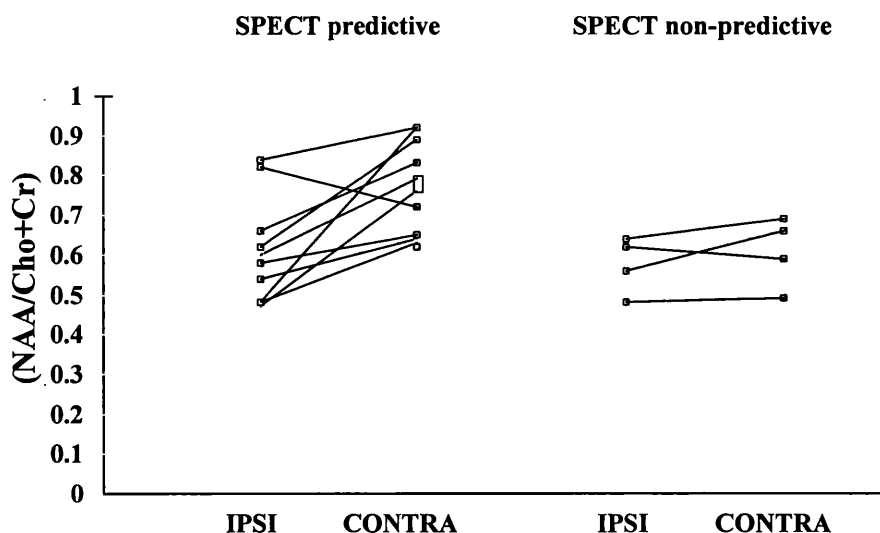
Figure 8.5 shows the individual <sup>1</sup>H MRS and SPECT data for the 14 children grouped according to whether SPECT showed hypoperfusion of one temporal lobe or no asymmetry of perfusion of the temporal lobes. In eight of the ten children showing



**Figure 8.4:**  $^1\text{H}$  MR spectra from the right and left temporal regions, and interictal  $^{99}\text{Tc}^{\text{m}}$  HMPAO SPECT scans from patient T16. The  $\text{NAA}/(\text{Cho}+\text{Cr})$  ratios were bilaterally abnormal and nonlateralising at 0.48 on the right and 0.49 on the left. Interictal SPECT showed no asymmetry of perfusion.

unilateral temporal hypoperfusion on interictal SPECT, the NAA/(Cho+Cr) was abnormally low on the ipsilateral side and lower than on the contralateral side by  $>0.05$ ; ie it was lateralising to the hypoperfused side. This included six children with a left temporal focus and two children with a right temporal focus. Two children who had unilateral temporal hypoperfusion (patients T5 and T8) had bilaterally normal NAA/(Cho+Cr) ratios. Of the four children who showed no asymmetry in perfusion between the temporal lobes, three had bilaterally abnormal NAA/(Cho+Cr) ratios that were not lateralising (Fig 8.5), and one bilaterally abnormal ratios that were correctly lateralising.

**Figure 8.5: Comparison of the NAA/(Cho+Cr) ratios from the temporal lobes ipsilateral and contralateral to the seizure focus of the 14 children with temporal lobe epilepsy, grouped according to whether the SPECT showed hypoperfusion of one temporal lobe (predictive) or no asymmetry of perfusion of the temporal lobes (non-predictive).**



In the three children who had undergone repeat examinations, the two who had previously demonstrated symmetrical perfusion of the temporal lobes, with bilaterally abnormal

NAA/(Cho+Cr) ratios, now showed unilateral  $^1\text{H}$  MRS abnormalities with concordant hypoperfusion of the temporal lobe on that side. The third child demonstrated clear perfusion asymmetry on an initial  $^{99\text{Tc}^{\text{m}}}$  HMPAO SPECT examination, but only marginal hypoperfusion of that temporal lobe on repeat scanning. There had been some recovery of NAA/(Cho+Cr) on that side; the ratio was 0.47 on the first occasion and 0.67 after a two year seizure free period.

### **8.5 Discussion**

In the group of children as a whole, interictal hypoperfusion as demonstrated by  $^{99\text{Tc}^{\text{m}}}$  HMPAO SPECT was seen to be related to structural abnormality as detected by MRI. However, the area of hypoperfusion seen was often greater than that attributable to the structural abnormality alone. This has been demonstrated in previous studies of SPECT (Hajek *et al.*, 1991), as well as in relation to hypometabolism demonstrated by  $^{18}\text{F}$ FDG PET (Engel *et al.*, 1982), and such areas of hypometabolism have also been shown to be more widespread than the area involved in electrical seizure onset (Engel, Jr. *et al.*, 1990b). These findings suggest that an area of functional abnormality exists that is more widespread than the 'epileptogenic lesion' (see Section 2.1). Animal data suggest that neurons within areas around those primarily responsible for seizure onset demonstrate prominent inhibitory potentials, 'surround inhibition' (Prince and Wilder, 1967). It is still difficult to determine, however, whether such areas detected on by SPECT or PET are functionally abnormal due such mechanisms as this, or due to damage not detectable by visual analysis of structural imaging.

The results from the small subpopulation of 14 children with temporal lobe epilepsy reviewed in this chapter demonstrated a good correlation between unilateral temporal abnormalities on  $^{99}\text{Tc}^{\text{m}}$  HMPAO SPECT and lateralising abnormalities in NAA/(Cho+Cr) on  $^1\text{H}$  MRS. Eight of the ten children with ipsilateral temporal hypoperfusion had an abnormally low NAA/(Cho+Cr) ratio that was lateralising to the same side. If it is accepted that a reduction in NAA reflects neuronal loss or damage, and the increase in the Cr and Cho signals that has also been observed may reflect gliosis, these results support the hypothesis that areas of hypoperfusion as detected by  $^{99}\text{Tc}^{\text{m}}$  HMPAO SPECT are associated with neuronal loss or dysfunction, and/or reactive astrocytosis. The fact that both techniques have fairly modest spatial resolution indicates that the abnormalities detected by the two techniques are widespread and not, for example, restricted specifically to the hippocampus.

Whereas absolute quantitation can be used in analysis of PET data, and bilateral abnormalities of the temporal lobe can be detected (Engel *et al.*, 1982), the SPECT studies performed here rely on side to side comparisons, and may therefore be expected to be insensitive to perfusion abnormalities when there is a similar degree of pathology in the two temporal lobes. The findings of this present study are consistent with this; none of the three children with NAA/(Cho+Cr) ratios that were bilaterally abnormal and non-lateralising showed unilateral temporal hypoperfusion on interictal SPECT.

Bilateral abnormalities in the hippocampus in individuals with TLE detected at post-mortem have shown that such abnormalities are associated with a longer duration of epilepsy (Margerison and Corsellis, 1966). It could be postulated that a longer duration of

epilepsy may lead to a greater incidence of bilateral damage, either neuronal loss or reactive astrocytosis, and that in these individuals lateralising hypoperfusion on  $^{99}\text{Tc}^{\text{m}}$  HMPAO SPECT may not be seen. Although studies using other modalities have not shown correlations between duration of epilepsy or seizure frequency and degree of abnormality (Cendes *et al.*, 1993b; Grunewald *et al.*, 1994), including our own data (Section 4.8), adult studies have shown the degree of asymmetry of perfusion as determined by SPECT to be correlated with age of seizure onset (Rowe *et al.*, 1991b). In our smaller study there was no significant difference in the mean duration of epilepsy, age of onset or seizure frequency between the group that did demonstrate ipsilateral hypoperfusion and those that did not, although the age span under consideration is relatively small. The distribution of unilateral and bilateral abnormalities seen on  $^1\text{H}$  MRS in this study reflects a similar percentage to that seen in adult series (Connelly *et al.*, 1994), and in the larger group described in Chapter 5 of this thesis.

It is of obvious interest to determine whether cases with bilateral abnormalities on  $^1\text{H}$  MRS also demonstrated bilateral temporal lobe hypoperfusion on  $^{99}\text{Tc}^{\text{m}}$  HMPAO SPECT. To this end, comparison of temporal lobe perfusion to that in other areas of the brain have been attempted. Comparisons with the cerebellum are unhelpful in epilepsy because of the well recognised changes in cerebellar perfusion which may be seen (Harvey *et al.*, 1993b; Marks *et al.*, 1992), although such cerebellar changes were only seen in a small number of children in this study. The calcarine cortex has also been suggested in adults for comparative measurements, but there is a lack of normative data in children. The only 'normative' data that compares perfusion of the temporal lobes with that in the rest of the brain have been obtained from children who presented with a neurological history,

although apparently normal at the time of the scans (Denays *et al.*, 1992). It was therefore not possible in this present study to determine whether there was relative bitemporal hypoperfusion in children with no side to side asymmetry of the anterior temporal regions on  $^{99}\text{Tc}^m$  HMPAO SPECT.

Reports in the literature about repeat interictal SPECT studies are few, but as in the current study suggest fluctuation in the area of abnormality demonstrated, despite no apparent change in clinical state (Jibiki *et al.*, 1990; Rowe *et al.*, 1991b). Repeat SPECT and  $^1\text{H}$  MRS examinations in three patients demonstrated changes over time but remained concordant. Two children underwent the studies in the process for reassessment for surgery. These two girls had shown no asymmetry in the temporal lobe perfusion on the first SPECT examination and bilaterally low NAA/(Cho+Cr) ratios that were nonlateralising. The repeat SPECT studies demonstrated unilateral hypoperfusion of the temporal lobe concordant with the seizure focus, and  $^1\text{H}$  MRS showed a unilaterally low NAA/(Cho+Cr) on that side. The ratio on the side contralateral to the seizure focus had normalised. In the child who had been seizure free for two years, the unilateral temporal hypoperfusion that had been clearly seen was not so striking, and there had been some recovery in the NAA/(Cho+Cr) on that side. One further child (E16) demonstrated resolution of perfusion asymmetry after a similar seizure free period. Data from the larger group of children with temporal lobe epilepsy have suggested that the changes seen in  $^1\text{H}$  MRS ipsilateral to the seizure focus involve a reduction in NAA and therefore neuronal loss or dysfunction, whereas the changes in the contralateral temporal lobe are predominantly due to an increase in Cho and Cr, possibly as a result of reactive gliosis. The number of children reported here who have undergone repeat examinations are too



small to make any comments on the signal intensities of individual compounds. However, although there is a theoretical possibility that recovery on the contralateral side may be due to a reduction in gliosis rather than neuronal/axonal recovery, the results of  $^1\text{H}$  MRS within our own (Section 5.6.2) and other studies (Hugg *et al.*, 1996) suggest normalisation of NAA rather than other compounds.

This part of the study has shown good correlation between interictal hypoperfusion as determined by interictal SPECT and structural abnormalities as determined by MRI. However, the area of hypoperfusion may extend beyond the boundaries of such a structural abnormality. Furthermore, areas of abnormality determined by interictal SPECT may vary over time within the same patient. Results of interictal SPECT alone in focal epilepsy need to be interpreted with caution in the light of these findings, and are unlikely to contribute further information to the presurgical evaluation of children with partial epilepsy in the absence of an ictal study, particularly if the MRI demonstrates focal pathology. Comparative studies in TLE shows a good correlation between abnormalities determined on  $^1\text{H}$  MRS and hypoperfusion seen on SPECT, and confirm that bilateral damage in these patients may preclude a predictive SPECT examination.

***Publication arising from this work:***

**Cross JH, Gordon I, Connelly A, Jackson GD, Johnson CL, Neville BGR, Gadian DG (1997) Interictal  $^{99}\text{Tc}^{\text{m}}$  HMPAO SPECT and  $^1\text{H}$  MRS in children with temporal lobe epilepsy. *Epilepsia* **38**, 338-345. (IV)**

## CHAPTER 9

### THE PRESURGICAL EVALUATION OF CHILDREN WITH DRUG RESISTANT FOCAL EPILEPSY: AN OPTIMISED STRATEGY

---

#### Contents

- 9.1 *The problem of the evaluation of outcome*
- 9.2 *Neuroimaging in the localisation of the seizure focus*
  - 9.2.1 *Magnetic resonance imaging*
  - 9.2.2 *Quantitative magnetic resonance*
  - 9.2.3 *Single photon emission computed tomography*
- 9.3 *The relative localising value of EEG,MR and SPECT*
- 9.4 *The presurgical evaluation of children with focal epilepsy- where are we at present?*
- 9.5 *The way forward*
  - 9.5.1 *Presurgical evaluation*
  - 9.5.2 *Postoperative outcome*
  - 9.5.3 *Underlying pathophysiology of focal seizures in childhood*

---

#### 9.1 *The problem of the evaluation of outcome*

This thesis has reviewed the power of new neuroimaging techniques in determining focal brain abnormalities in children with drug resistant partial epilepsy undergoing evaluation for surgery. There is evidence that if a focal area suitable for resection can be determined, early rather than later surgery should be considered (see Section 1.4). Many adults presenting for surgery, particularly for temporal resection, have had epilepsy since childhood (Cross *et al.*, 1996; Wyllie *et al.*, 1988). Moreover, it can be assumed that many patients with difficult epilepsy associated with a hemisindrome and developmental delay may have not survived to adult life, or are not evaluated in adulthood, as hemispherectomy makes up a relatively small proportion of adult epilepsy surgery practice. Discussion has also only recently been reopened into the role of surgery in adults

with learning disability (Duncan, 1997), in view of previous and current concerns about poor outcome in low IQ groups, low IQ being an indicator of diffuse cerebral dysfunction (Williamson, 1993).

Outcome from epilepsy surgery can be viewed in several ways. Ultimately we are seeking seizure freedom, although this may not be the primary goal in certain children.

Traditionally such outcome has been presented according to seizure frequency, eg the Engel classification, a grade given ranging from IA (complete seizure freedom) to IV (no improvement) (Engel, Jr. *et al.*, 1993) (Table 9.1). However there may be so many other considerations in the children. Developmental and neuropsychological outcome is particularly important, especially in the young child yet with developmental potential, and in the child where frequent seizures may have influenced developmental progress. Psychosocial outcome in terms of quality of life in a child with frequent hospital admissions or school absence may also be substantially altered.

There are many factors that have to be considered when evaluating postsurgical outcome with regard to seizure freedom; not only the degree with which localisation of seizure onset has been determined but also the aetiology of the lesion, its extent, and how much of the alleged epileptogenic lesion/area has been removed as well as at what stage postoperative outcome is measured. Most studies quote outcome at two years, but although there is little data on longer term outcome, evidence suggests possible seizure recurrence much later than this (Elwes *et al.*, 1991; Rougier *et al.*, 1992; Paillas *et al.*, 1983). The purpose of this study was to review the localising potential of various

**Table 9.1: Engel classification of outcome from epilepsy surgery**

**Class I: Free of disabling seizures**

- A: No seizures since surgery*
- B: Nondisabling partial seizures since surgery*
- C: Some disabling seizures since surgery, but none for two years*
- D: Generalised seizure with antiepileptic drug withdrawal only*

**Class II: Rare disabling seizures**

- A Initially free of disabling seizures but has rare seizures now*
- B: Rare disabling seizure since surgery*
- C: More than rare disabling seizures since surgery, but rare for two years*
- D: Nocturnal seizures only*

**Class III: Worthwhile improvement**

- A: Worthwhile seizure reduction*
- B: Prolonged seizure free intervals amounting to half the followup period, but not < two years*

**Class IV: No worthwhile improvement**

- A: Significant seizure reduction*
- B: No appreciable change*
- C: Seizures worse*

*Adapted from Surgical Treatment of the Epilepsies, 2nd ed.(Engel, Jr. et al., 1993)*

neuroimaging techniques. Only a proportion of children within this study proceeded to focal resection; inevitably in a prospective study not all children were considered to be surgical candidates following investigation. Numbers that have proceeded to surgery having undergone all investigations are therefore small. Forty seven children within this study have to date undergone surgery; 30 temporal lobectomy, 15 hemispherectomy and two extratemporal resections with follow-up ranging from 1 month to 5 years 7 months (median 3 years 6 months). Preliminary data reveal 31 (66%) children who are seizure free; 19 temporal (10 nonlesional, nine lesional), 11 hemisyndrome and one of two who underwent extratemporal resection. Of the group as a whole, 28 have undergone all the techniques described within this thesis; 14 temporal (10 nonlesional and four lesional), 12 hemisyndromes and the two who underwent extratemporal resection.

## **9.2 Neuroimaging in the localisation of the seizure focus**

### **9.2.1 Magnetic resonance imaging**

Visual analysis of magnetic resonance imaging in this group of children revealed focal brain abnormality in 80% of those with temporal and extratemporal epilepsy, and at least a lateralised abnormality in all those with hemisyndromes. There was also a high association with the likely area responsible for seizure onset, with no child in the temporal lobe group demonstrating an isolated or more generalised extratemporal lesion, and only one with extratemporal epilepsy showing isolated hippocampal sclerosis. The high incidence of hippocampal sclerosis within the temporal group is higher than previous surgical series in childhood (Duchowny *et al.*, 1992; Hopkins and Klug, 1991) but comparable with other MR series (Harvey *et al.*, 1995; Grattan Smith *et al.*, 1993). The duration of epilepsy in adults coming to surgery (Cross *et al.*, 1996; Wyllie *et al.*, 1988) and the presence of a similar rate of hippocampal sclerosis in this study to adult surgical series (Babb and Brown, 1987; Mathieson, 1975; Bruton, 1988) suggest that such changes are present from a young age, and that resection should be considered nearer to the time of presentation.

Magnetic resonance imaging greatly enhanced the presurgical evaluation of children with hemisyndromes. This was not only in the delineation of lateralised abnormality, both as to extent and aetiology with inaccurate previous interpretation of CT scan in a significant proportion, but also in the elimination of the possibility of abnormalities seen on the contralateral side.

### 9.2.2 Quantitative magnetic resonance

Several techniques have now been used by different adult epilepsy centres in quantitation of hippocampal and temporal lobe abnormality, including hippocampal volumetrics (Cendes *et al.*, 1993a; Cook *et al.*, 1992; Jack, Jr. *et al.*, 1990), T2 relaxometry (Jackson *et al.*, 1993a; Jackson *et al.*, 1993b; Van Paesschen *et al.*, 1997a) and proton magnetic resonance spectroscopy, both single voxel (Connelly *et al.*, 1994; Gadian *et al.*, 1994) and chemical shift imaging (Cendes *et al.*, 1994; Hugg *et al.*, 1992; Ng *et al.*, 1994; Ende *et al.* 1997). This study evaluated the role of T2 relaxometry of the hippocampus and single voxel <sup>1</sup>H MRS in children with focal epilepsy in presurgical evaluation. Both techniques lateralise brain abnormality in children with temporal lobe epilepsy with a high degree of reliability, errors in lateralisation only occurring in the presence of a foreign tissue lesion. Such errors were therefore easily suspected and ignored. The two techniques are complementary to each other with T2 relaxometry providing information specifically about the hippocampus, and <sup>1</sup>H MRS of a much wider area of the temporal lobe.

The use of T2 relaxation times enabled the detection of ‘dual pathology’ within the lesional TLE group and the extratemporal group. The implications of this finding at present remain unresolved; the relevance of hippocampal abnormality in extratemporal epilepsy and its aetiology has only been addressed in part by this study. Its relevance in the lesional temporal group, however, can be suspected in part from anecdotal evidence of two patients within this study (patients T27 and T3a) who at a first operation underwent lesionectomy. They subsequently underwent removal of mesial temporal structures on the same side in view of persistence of seizures and have since been seizure-free for 12 months following the second operation. Hippocampal T2 abnormalities within this group

may therefore suggest that the mesial temporal structures should be included in the surgical excision, but this requires further evaluation.

Whereas adult data show a high degree of correlation between the degree of abnormality as detected by T2 and pathology (Jackson *et al.*, 1993b), this does not appear to be the case in children, with at least two children in this series having histologically proven HS and yet T2 within the normal range. However, at the other end of the spectrum, all children with a hippocampal T2 value >116ms who went to surgery had HS at histology. The exact pathological correlate to abnormalities of <sup>1</sup>H MRS is yet to be determined, particularly as the voxel contains a substantial portion of white matter. The implications of abnormalities seen contralateral to the seizure focus, both on T2 and <sup>1</sup>H MRS are also yet to be elucidated, although adult data suggest this may influence postoperative cognitive outcome (Incisa della Rocchetta *et al.*, 1995)

### ***9.2.3 Single photon emission computed tomography***

Ictal <sup>99</sup>Tc<sup>m</sup> HMPAO single photon emission computed tomography can be used as a practical tool in the evaluation of children for epilepsy surgery. It is imperative to be aware of the timing of injection relative to the seizure, however, and to compare the ictal scan with one performed in the interictal state. With an awareness of perfusion patterns, and comparison with concurrent EEG at the time of ictal injection, ictal and postictal SPECT appear equally useful in temporal lobe epilepsy, and are particularly of value when ictal EEG is unhelpful or when structural MRI is normal. In children with extratemporal epilepsy, its role appears disappointing, particularly if an injection is not given during the clinical seizure. This has to be elucidated further, with review of

preoperative SPECT findings after some of these children have proceeded to invasive monitoring. The persistent finding of hyperperfusion after an ictal injection in children with an underlying developmental abnormality is of great interest. Failure to demonstrate hyperperfusion at the seizure focus in MRI-negative individuals may imply that a finding of underlying pathology at histology is unlikely in such individuals, and outcome following surgery therefore likely to be poor (Fish *et al.*, 1993).

Ictal and interictal SPECT add no further information in hemisindrome epilepsy to that acquired from EEG and structural imaging. Some children within this group who may demonstrate well localised lesions, isolated to one lobe, could be considered suitable for subtotal resection. However, postsurgical data to date suggests suboptimal outcome with regard to seizure freedom from such procedures (Rasmussen, 1983), and neuropsychological evidence suggests that early onset lesions result in relocation of function (Isaacs *et al.*, 1996), providing evidence that hemispherectomy should be the operation of choice.

### ***9.3 The relative localising value of EEG, MRI and SPECT***

The relative localising value of the various techniques can only be examined by reviewing results in those children who proceeded to surgery. Table 9.2 shows the relative localising value of the imaging techniques in temporal lobe epilepsy. This shows that no technique provided the absolute answer; each technique appeared equally contributory to the localisation of brain abnormality, considering also that T2 relaxometry and <sup>1</sup>H MRS only provide information with regard to lateralisation as the techniques are prelocalised. It is



important to consider each of the techniques as complementary. Magnetic resonance, including visual and quantitative analysis, provides structural information, whilst the EEG and ictal SPECT provides functional information about seizure onset. In addition, none of the children in the column pertaining to 'unhelpful' were identical for each of the techniques.

**Table 9.2: The relative localising value of each of the investigations used in this study in children who proceeded to temporal lobectomy**

<b>Temporal lobe epilepsy</b>		<b>Localising</b>	<b>Lateralising</b>	<b>Unhelpful</b>
<b>N=14</b>				
<b>MRI</b>		<b>10</b>	<b>1</b>	<b>3</b>
	<b>T2 relaxometry</b>	<b>0</b>	<b>8</b>	<b>6 (inc 4 lesional)</b>
	<b><sup>1</sup>H MRS (N=10)</b>	<b>0</b>	<b>7</b>	<b>3</b>
<b>EEG</b>	<b>Ictal</b>	<b>12</b>	<b>1</b>	<b>1</b>
	<b>Interictal</b>	<b>6</b>	<b>2</b>	<b>6</b>
<b>SPECT</b>	<b>Ictal</b>	<b>11</b>	<b>1</b>	<b>2</b>
	<b>Interictal</b>	<b>5</b>	<b>7</b>	<b>2</b>

Table 9.3 shows the relative localising value of the techniques within the hemisyndrome group. In this group the aim of the investigation was to achieve relative lateralisation rather than localisation; this was achieved in all children with magnetic resonance imaging. Interictal SPECT demonstrated hypoperfusion concordant with the structural abnormality on MRI. Interictal EEG was lateralising in all but two cases. Ictal EEG added no additional information; ictal SPECT added localising information in six cases which did not contribute to the decision on surgery. Therefore it is difficult to determine whether ictal EEG or interictal/ictal SPECT contributed to the decision process; this requires further examination, in a larger number of patients, of their relationship to measures of outcome.

**Table 9.3 The relative localising value of each of the investigations used in this study in children who proceeded to hemispherectomy**

<b>Hemisyndromes N=12</b>	<b>Localising</b>	<b>Lateralising</b>	<b>Unhelpful</b>
<b>MRI</b>	<b>1</b>	<b>11</b>	<b>0</b>
<b>EEG Ictal</b>	<b>4</b>	<b>4</b>	<b>4</b>
<b>EEG Interictal</b>	<b>0</b>	<b>10</b>	<b>2</b>
<b>SPECT Ictal</b>	<b>6</b>	<b>2</b>	<b>4</b>
<b>SPECT Interictal</b>	<b>1</b>	<b>9</b>	<b>2</b>

The relatively small number of children who proceeded to extratemporal resection reflects the poor degree of localisation even with the techniques under study. This group had the highest number with ‘normal’ magnetic resonance imaging compared to the other groups, and although SPECT was apparently localising in 57% if truly ictal, the spatial information with regard to seizure onset was insufficient to make a decision in the majority. With increased confidence, invasive monitoring may provide us with further insight into the relative power of functional techniques. Other techniques, namely those in magnetic resonance structural imaging as well as chemical shift imaging may provide further tools for detecting focal extratemporal brain abnormality. At present, we continue to rely on magnetic resonance imaging, with functional techniques to support localisation. In the absence of a structural brain abnormality, functional techniques (ictal and interictal EEG and SPECT) may provide a guide as to whether invasive monitoring may be appropriate.

#### ***9.4 The presurgical evaluation of children with drug resistant focal epilepsy - where are we at present?***

On the basis of the results of this study, the following protocols are suggested for noninvasive investigation of children with focal epilepsy. However, it should be emphasised that these protocols need to be constantly evaluated, particularly with regard to outcome, and results frequently audited.

##### ***Temporal lobe epilepsy: Clinical evaluation***

Optimised magnetic resonance imaging

*to include* 3D data set for volumetric and other analysis

*T2 relaxometry of the hippocampus*

*single voxel <sup>1</sup>H MRS of the mesial temporal regions*

Ictal and interictal EEG

Ictal and interictal SPECT *particularly where MRI normal*

##### ***Extratemporal epilepsy: Clinical evaluation***

Optimised MRI including 3D data set

Ictal and interictal EEG

Ictal and interictal SPECT

*Invasive subdural monitoring*

##### ***Hemispherectomy: Clinical evaluation***

Optimised magnetic resonance imaging

Interictal EEG - + *ictal if lateralisation uncertain*

Localisation of the seizure focus is not the sole aim of preoperative evaluation.

Localisation of function must also be achieved, in the majority using neuropsychological assessment so that the proposed surgical procedure is at low risk of causing functional deficit. Furthermore, it is becoming increasingly clear that outcome aims of the surgery must be reviewed with the family and child to ensure realistic expectations (Taylor *et al.*, 1997).

## ***9.5 The way forward***

### ***9.5.1 Presurgical evaluation***

Although the techniques evaluated within this thesis have enhanced the assessment of children with temporal lobe epilepsy, we still lack noninvasive tools that are reliable in the assessment of MRI-negative extratemporal epilepsy. If SPECT proves positive in these cases, invasive subdural monitoring is still likely to be required. It is for these children that further developments in structural and functional imaging need to be pursued. At present, single slice chemical shift imaging may add little advantage over single voxel spectroscopy in evaluation of brain abnormality outside the temporal lobe as the slice still requires positioning. However, developments in such a technique, with the ability to evaluate a greater area of tissue may provide further information. The assessment of gyral patterns has already been assessed to some degree in adults (Sisodiya *et al.*, 1995; Sisodiya *et al.*, 1996), and examination of these children may reveal subtle abnormalities, not necessarily widespread, that may be amenable to surgical resection. The link of such structural abnormalities to functional change may be enhanced by developments in SPECT. New ligands, particularly those that are more stable and may

provide a wider injection window (for example, ethyl cysteine dimer/bicusate) (Grünwald *et al.*, 1994; Kuikka *et al.*, 1994) may in combination with higher resolution scanners increase the yield of focal abnormality following ictal injection in extratemporal epilepsy. The reliability of such findings, in addition to those currently determined, will be made apparent as an increased number of such children are evaluated, in the first instance with invasive monitoring. A positive SPECT examination in the presence of normal magnetic resonance imaging has been shown in this study to be reliable in temporal lobe epilepsy. In addition focal hyperperfusion after ictal injection was seen consistently in those children with developmental brain abnormalities. Very few young children (< age five years) were included in this study. A very small number of children with clinically unlocalised epilepsy, but with a focal structural lesion on MRI, were demonstrated to have a focal onset with the aid of SPECT. Further study includes the need to evaluate a greater number of small children with recognised structural lesions on MRI using ictal and interictal SPECT. If these show consistent positive results, then this can be taken further to evaluate such an age group who have normal MRI, possibly using image registration of MRI and SPECT to help guide surgery.

### ***9.5.2 Postoperative outcome***

Although two thirds of children within this study underwent surgery, the number of children who underwent all of the investigations is small, and follow-up is too short to draw specific conclusions. However, the relevance of concordance or discordance of data from each of the respective investigations with regard to seizure freedom following surgery must be addressed. Furthermore, the presence of contralateral hippocampal and temporal lobe abnormalities as determined by hippocampal T2 relaxometry and <sup>1</sup>H MRS

of the mesial temporal regions in temporal lobe epilepsy, and the significance of these contralateral abnormalities in relation to seizure and neuropsychological outcome (Gadian *et al.*, 1996; Incisa della Rocchetta *et al.*, 1995) needs to be reviewed in this group of children. The determination of subtle abnormalities of cortical development in the long term will also need reviewing and will not necessarily preclude surgery in the first instance in the presence of a well defined area from which habitual seizures appear to arise.

### ***9.5.3 Underlying pathophysiology of focal seizures in childhood.***

The question remains as to whether abnormalities of the hippocampus and temporal lobe as seen on T2 relaxometry and <sup>1</sup>H MRS in nontemporal epilepsy are primary, that is part of the underlying aetiological disorder, or secondary, that is a consequence of repeated seizures. Studies evaluating children for surgery are unlikely to answer this question as the individuals are likely at the time of initial scan to have had a long history of repeated seizures. Studies of adults with newly diagnosed epilepsy suggest a low incidence of hippocampal sclerosis in this population (Van Paesschen *et al.*, 1997b), and where abnormalities of T2 relaxation are seen, they appear to correlate with poor prognosis with regard to seizure control (Kim *et al.*, 1997). Prospective study of children from initial antecedent event, and/or presentation with established epilepsy would help to answer this question.

The studies here of repeat <sup>1</sup>H MRS in three children over two years, and those post surgery suggest that there may be a possibility of neuronal 'recovery'. Again longer term follow up of such children, and greater numbers may help to resolve this question of

whether such 'recovery' does indeed occur, and whether it is related to seizure control. Pathological studies are also required to determine the exact correlate of  $^1\text{H}$  MRS, and whether such 'recovery', probably return of function rather than neuronal gain, is possible.

The SPECT studies performed here, when correlated with EEG, have suggested that some children may experience ischaemia at the seizure focus rather than hyperaemia. This is in a group of older children. Prospective studies of such children, or those demonstrating hyperaemia, to review whether ischaemia may occur over time would not be ethically possible unless the individuals required repeat examination for clinical purposes.

However, examination of a young population of children may help to answer this question, particularly if compared with an older group. Pathological changes in patterns of cerebral blood flow from hyperaemia to ischaemia in the affected hemisphere with age have already been demonstrated in Sturge Weber syndrome, providing confirmatory evidence that progressive ischaemia may play an important part in the progressive nature of the condition (Adamsbaum *et al.*, 1996). This may equally apply to a more subtle degree in children with other seizure disorders without evidence of a cerebrovascular anomaly. Other methods of determining cerebral blood flow, both noninvasive (transcranial Doppler) (Bode, 1992) and invasive (laser Doppler flowmetry) (Ronne-Engstrom *et al.*, 1993) may also help to answer some of these questions.

## BIBLIOGRAPHY

- Anonymous (1989) Proposal for revised classification of epilepsies and epileptic syndromes. Commission on Classification and Terminology of the International League Against Epilepsy. *Epilepsia*, **30**, 389-399.
- Anonymous (1992) Prognosis of epilepsy in newly referred patients: a multicenter prospective study of the effects of monotherapy on the long-term course of epilepsy. Collaborative Group for the Study of Epilepsy. *Epilepsia*, **33**, 45-51.
- Anonymous (1997) *Greenfields Pathology*. London: Arnold.
- ADAMS CB., BEARDSWORTH ED, OXBURY SM, OXBURY JM., FENWICK PB (1990) Temporal lobectomy in 44 children: outcome and neuropsychological follow-up. *J. Epilepsy* **3** (suppl), 157-168.
- ADAMSBAUM C, PINTON F, ROLLAND Y, CHIRON C, DULAC O, KALIFA G (1996) Accelerated myelination in early Sturge-Weber syndrome. *Pediatr.Radiol.*, **26**, 759-762.
- ADELSON PD, PEACOCK WJ, CHUGANI HT, COMAIR YG, VINTERS HV, SHIELDS WD, et al (1992) Temporal and extended temporal resections for the treatment of intractable seizures in early childhood. *Pediatr.Neurosurg.*, **18**, 169-178.
- AHN CS, TOW DE, YU CC, GREENE RW. (1994) Effect of metabolic alterations on the accumulation of technetium-99m-labeled *d,l*-HMPAO in slices of rat cerebral cortex. *J. Cerebr. Blood Flow Metab.* **14**, 324-331..
- AICARDI J (1994) *Epilepsy in children*. New York: Raven Press. 1-555.
- ANDERMANN F, OGUNI H (1990) Do epileptic foci in children migrate? The pros. *Electroencephalogr.Clin.Neurophysiol.*, **76**, 96-99.
- ANDERSEN AR, FRIBERG H, LASSEN NA, KRISTENSEN K, NEIRINCKX RD (1987) Serial studies of cerebral blood flow using <sup>99</sup>Tc<sup>m</sup> HMPAO: a comparison with <sup>133</sup>Xe. *Nucl.Med.Commun.*, **8**, 549-557.
- ANNEGERS JF, HAUSER WA, ELVEBACK LR (1979) Remission of seizures and relapse in patients with epilepsy. *Epilepsia*, **20**, 729-737.
- ARZIMANOGLU A, AICARDI J (1992) The epilepsy of Sturge-Weber syndrome: clinical features and treatment in 23 patients. *Acta Neurol.Scand.Suppl.*, **140**, 18-22.
- AUER RN, SIESJO BK (1988) Biological differences between ischemia, hypoglycemia, and epilepsy. *Ann.Neurol.*, **24**, 699-707.



- AUSTIN SJ, CONNELLY A, GADIAN DG, BENTON JS, BRETT EM (1991) Localized <sup>1</sup>H NMR spectroscopy in Canavan's disease: a report of two cases. *Magn. Reson. Med*, **19**, 439-445.
- BABB TL, BROWN WJ (1987) Pathological findings in epilepsy. In: *Surgical Treatment of the Epilepsies*. Edited by J Engel, Jr. New York: Raven Press. 511-539.
- BAYNE VJ, FORSTER AM, TYRELL DA (1989) Use of sodium iodide to overcome the eluate age restriction for Ceretec™ reconstitution. *Nucl. Med Commun.*, **10**, 29-33.
- BEARDSWORTH ED, ADAMS CB (1988) Modified hemispherectomy for epilepsy: early results in 10 cases. *Br.J.Neurosurg.*, **2**, 73-84.
- BERGEN D, BLECK T, RAMSEY R, CLASEN R, RISTANOVIC R, SMITH M, et al (1989) Magnetic resonance imaging as a sensitive and specific predictor of neoplasms removed for intractable epilepsy. *Epilepsia*, **30**, 318-321.
- BERGER H (1929) Uber das Electrenkephalogram des Menschen. *Arch Psychiatr Nervenkr*, **87**, 527
- BERKOVIC SF, NEWTON MR, CHIRON C, DULAC D. (1993) Single photon emission computed tomography. In *Surgical Treatment of the Epilepsies, second edition*. Edited by J Engel, Jr. Raven Press, New York. 233-243.
- BESAG FMC (1988) Cognitive deterioration in children with epilepsy. In: *Epilepsy, Behaviour and Cognitive Function*. Edited by MR Trimble, EH Reynolds. Wiley, J. & Sons Ltd. 113-127.
- BLUME WT (1978) Clinical and electroencephalographic correlates of the multiple independent spike foci pattern in children. *Ann.Neurol.*, **4**, 541-547.
- BLUME WT (1989) Clinical profile of partial seizures beginning at less than four years of age. *Epilepsia*, **30**, 813-819.
- BLUME WT (1990) Do epileptic foci in children migrate? The cons. *Electroencephalogr.Clin.Neurophysiol.*, **76**, 100-105.
- BODE H (1992) Intracranial blood flow velocities during seizures and generalized epileptic discharges. *Eur.J.Pediatr.*, **151**, 706-709.
- BOUCHET C, CAZAUVIEIL IH (1825) Epilepsie et l'aliénation mentale. *Arch.Gen.Med.*, **9**, 510-542.
- BREWIS M, POSKANZER D, ROLLAND C, MILLER H (1966) Neurological disease in an English city. *Acta Neurol.Scand.*, **42**, 1-89.
- BRODTKORB E, NILSEN G, SMEVIK O, RINCK PA (1992) Epilepsy and anomalies of neuronal migration: MRI and clinical aspects. *Acta Neurol.Scand.*, **86**, 24-32.
- BROMFIELD EB, DAMBROSIA J, DEVINSKY O, NICE FJ, THEODORE WH (1989) Phenytoin withdrawal and seizure frequency. *Neurology*, **39**, 905-909.

- BRONEN RA, CHEUNG G, CHARLES JT, KIM JH, SPENCER DD, SPENCER SS, et al (1991) Imaging findings in hippocampal sclerosis: Correlation with pathology. *AJNR*, **12**, 933-940.
- BRORSON LO, WRANNE L (1987) Long-term prognosis in childhood epilepsy: survival and seizure prognosis. *Epilepsia*, **28**, 324-330.
- BRUNEAU N, ROUX S, GUERIN P, BARTHELEMY C, LELORD G (1997) Temporal prominence of auditory evoked potential (N1 wave) in 4-8 year-old children. *Psychophysiology*, **34**, 32-38.
- BRUTON, C. J. *The neuropathology of temporal lobe epilepsy*. 1-158. 1988. Oxford: Oxford University Press.
- BULLOCK, R., PATTERSON, J., AND PARK, C. (1991) Evaluation of 99mTc-hexamethylpropyleneamine oxime cerebral blood flow mapping after acute focal ischemia in rats. *Stroke*, **22**, 1284-1290.
- BURNSTINE TH, VINING EP, UEMATSU S, LESSER RP (1991) Multifocal independent epileptiform discharges in children: ictal correlates and surgical therapy. *Neurology*, **41**, 1223-1228.
- CADY EB, COSTELLO AMd, DAWSON MJ, DELPY DT, HOPE PL, REYNOLDS EOR (1983) Non-invasive investigation of cerebral metabolism in newborn infants by phosphorus nuclear magnetic resonance spectroscopy. *Lancet* , **i**, 1062
- CASCINO GD, JACK CR, Jr., PARISI JE, MARSH WR, KELLY PJ, SHARBROUGH FW, et al (1992) MRI in the presurgical evaluation of patients with frontal lobe epilepsy and children with temporal lobe epilepsy: pathologic correlation and prognostic importance. *Epilepsy Res.*, **11**, 51-59.
- CAVANAGH JB (1958) On certain small tumours encountered in the temporal lobe. *Brain*, **81**, 389-405.
- CAVANAGH JB, MEYER A (1956) Aetiological aspects of Ammon's horn sclerosis associated with temporal lobe epilepsy. *Brit. Med. J.*, **2**, 1403-1407.
- CAVINESS VS, HATTEN ME, MCCONNELL SK, TAKAHASHI T (1995) Developmental neuropathology and childhood epilepsies. In: *Brain Development and Epilepsy*. Edited by PA Schwartzkroin, SL Moshe, JL Noebels, JW Swann. Oxford: 94-121.
- CENDES F, ANDERMANN F, DUBEAU F, ARNOLD DL (1995) Proton magnetic resonance spectroscopic images and MRI volumetric studies for lateralization of temporal lobe epilepsy. *Magn.Reson.Imaging*, **13**, 1187-1191.
- CENDES F, ANDERMANN F, GLOOR P, EVANS A, JONES GOTMAN M, WATSON C, et al (1993a) MRI volumetric measurement of amygdala and hippocampus in temporal lobe epilepsy. *Neurology*, **43**, 719-725.

- CENDES F, ANDERMANN F, GLOOR P, LOPES CENDES I, ANDERMANN E, MELANSON D, et al (1993b) Atrophy of mesial structures in patients with temporal lobe epilepsy: cause or consequence of repeated seizures? *Ann.Neurol.*, **34**, 795-801.
- CENDES F, ANDERMANN F, PREUL MC, ARNOLD DL (1994) Lateralization of temporal lobe epilepsy based on regional metabolic abnormalities in proton magnetic resonance spectroscopic images. *Ann.Neurol.*, **35**, 211-216.
- CHUGANI HT, RINTAHAKA PJ, SHEWMON DA. (1994) Ictal patterns of cerebral glucose utilization in children with epilepsy. *Epilepsia* 35(4), 813-822..
- CHUGANI HT, SHEWMON DA, SHIELDS WD, SANKAR R, COMAIR Y, VINTERS HV, et al (1993) Surgery for intractable infantile spasms: neuroimaging perspectives. *Epilepsia*, **34**, 764-771.
- CONNELLY A, AUSTIN SJ, GADIAN DG (1990) Localised <sup>1</sup>H NMR spectroscopy in post natal brain development: age and regional dependence. *Radiology*, 784
- CONNELLY A, AUSTIN SJ, GADIAN DG (1991) Localised <sup>1</sup>H MRS in the pediatric brain: age and regional dependence. *SMRM Tenth Annual Scientific Meeting*, **1**, 379
- CONNELLY A, JACKSON GD, DUNCAN JS, KING MD, GADIAN DG (1994) Magnetic resonance spectroscopy in temporal lobe epilepsy. *Neurology*, **44**, 1411-1417.
- COOK MJ, FISH DR, SHORVON SD, STRAUGHAN K, STEVENS JM (1992) Hippocampal volumetric and morphometric studies in frontal and temporal lobe epilepsy. *Brain*, **115**, 1001-1015.
- COOK MJ, MANFORD M, GADIAN DG, CONNELLY A, SHORVON SD, FISH DR (1991) Proton magnetic resonance spectroscopy in supplementary motor area seizures. *Epilepsia*, **32**, 78
- COSTA DC, ELL PJ, CULLUM ID, JARRITT PH (1986) The in vivo distribution of <sup>99</sup>Tcm-HMPAO in normal man. *Nucl.Med.Commun.*, **7**, 647-658.
- COSTA DC, JONES BE, STEINER TJ, ASPREY BS, ELL PJ, CULLUM ID, et al (1987) Relative <sup>99m</sup>Tc-HMPAO and <sup>113</sup>Sn-microspheres distribution in dog brain. *Nuklearmedizin.*, **suppl 23**, 489-500.
- COSTA, D. C., LUI, D., SINHA, A. K., JARRITT, P. H., AND ELL, P. J. (1989) Intracellular localisation of <sup>99</sup>Tc<sup>m</sup>-d,l-HMPAO and <sup>201</sup>Tl-DDC in rat brain. *Nucl.Med.Commun.* **10**, 459-466.
- CONVERS, Ph., BIERME, T., RYVLIN, Ph., REVOL, M., FISCHER, C., FROMENT J.C., MANGUIERE F (1990) Apport de l'imagerie par resonance magnetique dans 100 cas d'epilepsie partielle rebelle a scanner X normal. *Rev.Neurol.(Paris)* **146**, 330-337.

- CROSS JH, DUNCAN JS, FISH DR, HARKNESS W, HARPER A, NEVILLE BGR (1996) The range of presentation of drug-resistant temporal lobe epilepsy in adults and children. *Epilepsia*, **37s5**, 103
- CROSS JH, JACKSON GD, NEVILLE BGR, CONNELLY A, KIRKHAM FJ, BOYD SG, et al (1993) Early detection of abnormalities in partial epilepsy using magnetic resonance. *Arch Dis Child*, **69**, 104-109.
- CZOCHANSKA J, LANGNER TYSZKA B, LOSIOWSKI Z, SCHMIDT SIDOR B (1994) Children who develop epilepsy in the first year of life: a prospective study. *Dev. Med Child Neurol.*, **36**, 345-350.
- DAM M (1990) Children with epilepsy: the effect of seizures, syndromes, and etiological factors on cognitive functioning. *Epilepsia*, **31 Suppl 4**, S26-S29
- DAUMAS-DUPOINT C, SCHEITHAUER BW, CHODKIEWICZ JP, LAWS ER, Jr., VEDRENNE C (1988) Dysembryoplastic neuroepithelial tumor: a surgically curable tumor of young patients with intractable partial seizures. Report of thirty-nine cases. *Neurosurgery*, **23**, 545-556.
- DAVIDSON S, FALCONER MA (1975) Outcome of surgery in 40 children with temporal-lobe epilepsy. *Lancet*, **1**, 1260-1263.
- DENAYS R, HAM H, TONDEUR M, PIEPSZ A, NOEL P (1992) Detection of bilateral and symmetrical anomalies in Technetium-99m-HMPAO brain SPECT studies. *J. Nucl. Med.*, **33**, 485-490.
- DENAYS R, RUBINSTEIN M, HAM H, PIEPSZ A, NOEL P (1988) Single photon emission computed tomography in seizure disorders. *Arch. Dis. Child*, **63**, 1184-1188.
- DOBBING, J. AND SANDS, J. (1973) Quantitative growth and development of human brain. *Arch. Dis. Child.*, **48**, 757-767.
- DOWD, C.F., DILLON, W.P., BARBARO, N.M., LAXER, K.D. (1991) Magnetic resonance imaging of intractable complex partial seizures: pathologic and electroencephalographic correlation. *Epilepsia* **32**, 454-459.
- DUCHOWNY M, JAYAKAR P, RESNICK T, LEVIN B, ALVAREZ L (1994) Posterior temporal epilepsy: electroclinical features. *Ann. Neurol.*, **35**, 427-431.
- DUCHOWNY M, LEVIN B, JAYAKAR P, RESNICK T, ALVAREZ L, MORRISON G, et al (1992) Temporal lobectomy in early childhood. *Epilepsia*, **33**, 298-303.
- DUCHOWNY MS (1987) Complex partial seizures of infancy. *Arch. Neurol.*, **44**, 911-914.
- DUCHOWNY MS (1989) Surgery for intractable epilepsy: issues and outcome. *Pediatrics*, **84**, 886-894.

- DUNCAN JS, SHORVON SD, TRIMBLE MR (1990) Discontinuation of phenytoin, carbamazepine, and valproate in patients with active epilepsy. *Epilepsia*, **31**, 324-333.
- DUNCAN R (1997) Epilepsy surgery in the learning disabled. *Epilepsia*, **38**, 277
- DUNCAN R, PATTERSON J, HADLEY D, ROBERTS R, BONE I (1996) Interictal temporal hypoperfusion is related to early-onset temporal lobe epilepsy. *Epilepsia*, **37**, 134-140.
- DUNCAN R, PATTERSON J, ROBERTS R, HADLEY DM, BONE I (1993) Ictal/postictal SPECT in the pre-surgical localisation of complex partial seizures. *J Neurol. Neurosurg. Psychiatry*, **56**, 141-148.
- DUNNING HS, WOLFF HC (1937) The relative vascularity of various parts of the central and peripheral nervous system of the cat and its relation to function. *J. Compar. Neurol.* **67**, 433-450.
- DUVERNOY HM (1988) *The Human Hippocampus - An Atlas of Applied Anatomy*. Springer Verlag: New York.
- ELLENBERG JH, HIRTZ DG, NELSON KB (1986) Do seizures in children cause intellectual deterioration? *N.Engl.J.Med.*, **314**, 1085-1088.
- ELWES RDC, DUNN G, BINNIE CD, POLKEY CE (1991) Outcome following resective surgery for temporal lobe epilepsy: a prospective followup study of 102 consecutive cases. *J. Neurol. Neurosurg. Psychiatry* **54**, 949-952.
- EMERSON R, D'SOUZA BJ, VINING EP, HOLDEN KR, MELLITS ED, FREEMAN JM (1981) Stopping medication in children with epilepsy: predictors of outcome. *N.Engl.J.Med.*, **304**, 1125-1129.
- ENDE GR, LAXER KD, KNOWLTON RC, MATSON GB, SCHUFF N, FEIN G, et al (1997) Temporal lobe epilepsy: Bilateral hippocampal metabolite changes revealed at proton MR spectroscopic imaging. *Radiology*, **202**, 809-817.
- ENGEL J, Jr. (1990a) The Hans Berger lecture. Functional explorations of the human epileptic brain and their therapeutic implications. *Electroencephalogr. Clin. Neurophysiol.*, **76**, 296-316.
- ENGEL J, Jr., BROWN WJ, KUHL DE, PHELPS ME, MAZZIOTTA JC, CRANDALL PH (1982) Pathological findings underlying focal temporal lobe hypometabolism in partial epilepsy. *Ann. Neurol.* **12**, 518-528.
- ENGEL J, Jr., HENRY TR, RISINGER MW, MAZZIOTTA JC, SUTHERLING WW, LEVESQUE MF, et al (1990b) Presurgical evaluation for partial epilepsy: relative contributions of chronic depth-electrode recordings versus FDG- PET and scalp-sphenoidal ictal EEG. *Neurology*, **40**, 1670-1677.

- ENGEL J, Jr., KUHL DE, PHELPS ME, RAUSCH R, NUWER M (1983) Local cerebral metabolism during partial seizures. *Neurology*, **33**, 400-413.
- ENGEL J, Jr., VAN NESS PC, RASMUSSEN TB, OJEMANN LM (1993) Outcome with respect to epileptic seizures. In: *Surgical Treatment of the Epilepsies, second edition*. Edited by J Engel, Jr. New York: Raven Press Ltd. 609-621.
- FALCONER MA (1970) Significance of surgery for temporal lobe epilepsy in childhood and adolescence. *J.Neurosurg.*, **33**, 233-252.
- FALCONER MA (1971) Genetic and related aetiological factors in temporal lobe epilepsy. A review. *Epilepsia*, **12**, 13-31.
- FALCONER MA (1972a) Febrile convulsions in early childhood. *Br.Med.J.*, **3**, 292-292.
- FALCONER MA (1972b) Place of surgery for temporal lobe epilepsy during childhood. *Br.Med.J.*, **2**, 631-634.
- FALCONER MA (1972c) Temporal lobe epilepsy in children and its surgical treatment. *Med.J.Aust.*, **1**, 1117-1121.
- FALCONER MA (1972d) The place of surgery in epileptic children and adolescents with mesial temporal (Ammon's horn) sclerosis. *Ir.J.Med.Sci.*, **141**, 147-161.
- FALCONER MA, TAYLOR DC (1968) Surgical treatment of drug-resistant epilepsy due to mesial temporal sclerosis. Etiology and significance. *Arch.Neurol.*, **19**, 353-361.
- FALCONER MA, WILSON PJ (1969) Complications related to delayed hemorrhage after hemispherectomy. *J.Neurosurg.*, **30**, 413-426.
- FEINDEL W (1993) Toward a surgical cure for epilepsy. The work of Wilder Penfield and his school at the Montreal Neurological Institute. In: *Surgical Treatment of the Epilepsies., second edition*. Edited by J Engel, Jr. New York: Raven Press Ltd. 1-9.
- FISH DR, SMITH SJ, QUESNEY LF, ANDERMANN F, RASMUSSEN T (1993) Surgical treatment of children with medically intractable frontal or temporal lobe epilepsy: results and highlights of 40 years' experience. *Epilepsia*, **34**, 244-247.
- FORSGREN L (1996) Epidemiology: Incidence and prevalence. In: *Epilepsy in Children*. Edited by S Wallace. London: Chapman & Hall Medical. 27-37.
- FRANCK G, SADZOT B, SALMON E, DEPRESSEUX JC, GRISAR T, PETERS JM, et al (1986) Regional cerebral blood flow and metabolic rates in human focal epilepsy and status epilepticus. *Adv.Neurol.*, **44**, 935-948.
- FRENCH JA, WILLIAMSON PD, THADANI VM, DARCEY TM, MATTSON RH, SPENCER SS, et al (1993) Characteristics of medial temporal lobe epilepsy: I. Results of history and physical examination. *Ann.Neurol.*, **34**, 774-780.

- FRIED I, KIM JH, SPENCER DD (1992) Hippocampal pathology in patients with intractable seizures and temporal lobe masses. *J.Neurosurg.*, **76**, 735-740.
- FRIEDE RL (1989) *Developmental Neuropathology*. Berlin: Springer Verlag.
- GABR M, LUDERS H, DINNER D, MORRIS H, WYLLIE E (1989) Speech manifestations in lateralization of temporal lobe seizures. *Ann.Neurol.*, **25**, 82-87.
- GADIAN DG, CONNELLY A, DUNCAN JS, KIRKHAM FJ, JOHNSON CL, VARGHA-KHADEM F, et al (1994) <sup>1</sup>H magnetic resonance spectroscopy in the investigation of intractable epilepsy. *Acta Neurol.Scand.*, **Suppl 152**, 116-121.
- GADIAN DG, ISAACS EB, CROSS JH, CONNELLY A, JACKSON GD, KING MD, et al (1996) Lateralization of brain function in childhood revealed by magnetic resonance spectroscopy. *Neurology*, **46**, 974-977.
- GALLY JA, MONTAGUE PR, REEKE GNJ, EDELMAN GM (1990) The NO hypothesis: Possible effects of a short-lived, rapidly diffusible signal in the development and function of the nervous system. *Proc.Natl.Acad.Sci.U.S.A.*, **87**, 3547-3551.
- GARCIA PA, LAXER KD, VAN DER GROND J, HUGG JW, MATSON GB, WEINER MW (1994) Phosphorus magnetic resonance spectroscopic imaging in patients with frontal lobe epilepsy. *Ann.Neurol.*, **35**, 217-221.
- GARCIA PA, LAXER KD, VAN DER GROND J, HUGG JW, MATSON GB, WEINER MW (1995) Proton magnetic resonance spectroscopic imaging in patients with frontal lobe epilepsy. *Ann.Neurol.*, **37**, 279-281.
- GEMMELL HG, EVANS NTS, BESSON JAO, ROEDA D, DAVIDSON J, DODD MG, et al (1990) Regional Cerebral Blood Flow Imaging: A Quantitative Comparison of Technetium-99m-HMPAO SPECT with C<sup>15</sup>O<sub>2</sub>PET. *J Nucl Med*, **31**, 1595-1600.
- GIBBS EL, GIBBS FA (1960) Good prognosis of mid-temporal epilepsy. *Epilepsia*, **1**, 448-453.
- GIBBS EL, GILLEN HW, GIBBS FA (1954) Disappearance and migration of epileptic foci in childhood. *Am.J.Dis.Child*, **88**, 596-603.
- GIBBS FA, LENNON WG, GIBBS EL (1934) Cerebral blood flow preceding and accompanying epileptic seizures in man. *Arch.Neurol.Psychiatry*, **32**, 257-272.
- GOUTIERES F, CHALLAMEL MJ, AICARDI J, GILLY R (1972) Les hemiplegies congenitales semiologies, etiologie at prognostic. *Arch.Fr.Pediatr.*, **29**, 839-851.
- GRATTAN SMITH JD, HARVEY AS, DESMOND PM, CHOW CW (1993) Hippocampal sclerosis in children with intractable temporal lobe epilepsy: detection with MR imaging. *AJR.Am.J.Roentgenol.*, **161**, 1045-1048.

- GRUNEWALD, R. A., JACKSON, G. D., CONNELLY, A., AND DUNCAN, J. S.  
(1994) MR detection of hippocampal disease in epilepsy: Factors influencing T2 relaxation time. *AJNR.Am.J.Neuroradiol.* **15**, 1149-1156.
- GRÜNWARD F, MENZEL C, PAVICS L, BAUER J, HUFNAGEL A, REICHMANN K, et al (1994) Ictal and interictal brain SPECT imaging in epilepsy using technetium-99m-ECD. *J.Nucl.Med*, **35**, 1896-1901.
- GUERRINI R, DRAVET C, RAYBAUD C, ROGER J, BUREAU M, BATTAGLIA A, et al (1992) Epilepsy and focal gyral anomalies detected by MRI: electroclinico-morphological correlations and follow-up. *Dev.Med Child Neurol.*, **34**, 706-718.
- HAERER AF, ANDERSON DW, SCHOENBERG BS (1986) Prevalence and clinical features of epilepsy in a biracial United States population. *Epilepsia*, **27**, 66-75.
- HAJEK M, SIEGEL AM, HALDEMANN R, VON SCHULTHESS GK, WIESER HG (1991) Value of HM-PAO SPECT in selective temporal lobe surgery for epilepsy. *J Epilepsy*, **4**, 43-51.
- HARBORD MG, MANSON JI (1987) Temporal lobe epilepsy in childhood: reappraisal of etiology and outcome. *Pediatr.Neurol.*, **3**, 263-268.
- HARRISON RM, TAYLOR DC (1976) Childhood seizures: a 25-year follow up. Social and medical prognosis. *Lancet*, **1**, 948-951.
- HARVEY AS, BOWE JM, HOPKINS IJ, SHIELD LK, COOK DJ, BERKOVIC SF (1993a) Ictal 99mTc-HMPAO single photon emission computed tomography in children with temporal lobe epilepsy. *Epilepsia*, **34**, 869-877.
- HARVEY AS, GRATTAN-SMITH JD, DESMOND PM, CHOW CW, BERKOVIC SF (1995) Febrile seizures and hippocampal sclerosis: Frequent and related findings in intractable temporal lobe epilepsy of childhood. *Pediatr.Neurol.*, **12**, 201-206.
- HARVEY AS, HOPKINS IJ, BOWE JM, COOK DJ, SHIELD LK, BERKOVIC SF (1993b) Frontal lobe epilepsy: clinical seizure characteristics and localization with ictal 99mTc-HMPAO SPECT. *Neurology*, **43**, 1966-1980.
- HAUSER WA (1992) Seizure disorders: the changes with age. *Epilepsia*, **33 Suppl 4**, S6-14.
- HAUSER WA, ANNEGERS JF, KURLAND AH (1991) Prevalence of epilepsy in Rochester, Minnesota: 1940-1980. *Epilepsia*, **32**, 429-445.
- HEISS WD, TURNHEIM M, VOLLMER R, RAPPELSBERGER P (1979) Coupling between neuronal activity and focal blood flow in experimental seizures. *Electroencephalogr.Clin.Neurophysiol.*, **47**, 396-403.
- HENRY TR, MAZZIOTTA JC, ENGEL J,Jr. (1993) Interictal metabolic anatomy of mesial temporal lobe epilepsy *Arch.Neurol.* **50**,582-589.



- HENRY TR, SUTHERLING WW, ENGEL J,Jr., RISINGER MW, LEVESQUE MF, MAZZIOTTA JC, PHELPS ME (1991) Interictal cerebral metabolism in partial epilepsies of neocortical origin *Epilepsy Res.* **10**, 174-182.
- HO SS, BERKOVIC SF, MCKAY WJ, KALNINS RM, BLADIN PF (1996) Temporal lobe epilepsy subtypes: Differential patterns of cerebral perfusion on ictal SPECT. *Epilepsia*, **37**, 788-795.
- HOLMES GL (1984) Partial complex seizures in children: an analysis of 69 seizures in 24 patients using EEG FM radiotelemetry and videotape recording. *Electroencephalogr.Clin.Neurophysiol.*, **57**, 13-20.
- HOLMES GL (1986) Partial seizures in children. *Pediatrics*, **77**, 725-731.
- HOLTHAUSEN, H. (1994) Febrile convulsions, mesial temporal sclerosis and temporal lobe epilepsy. In: *Epileptic Seizures and Syndromes*. Edited by Raven Press: New York. 449-467..
- HOOPER, H. R., MCEWAN, A. J., LENTLE, B. C., KOTCHON, T. L., AND HOOPER, P. M. (1990) Interactive three-dimensional region of interest analysis of HMPAO SPECT brain studies. *J Nucl Med* **31**, 2046-2051.
- HOPE PL, CADY EB, TOFTS PS, HAMILTON PA, DE.L.COSTELLO AM, DELPY DT, et al (1984) Cerebral energy metabolism studied with phosphorus spectroscopy in normal and birth asphyxiated infants. *Lancet*, **I**, 366-369.
- HOPKINS IJ, KLUG GL (1991) Temporal lobectomy for the treatment of intractable complex partial seizures of temporal lobe origin in early childhood. *Dev.Med.Child Neurol.*, **33**, 26-31.
- HORSLEY V (1886) Brain surgery. *BMJ.*, **2**, 670-675.
- HOUGAARD K, LARSEN B, SKINHOJ E, LASSEN NA (1977) Focal cortical epilepsy, variability of interictal state studied by regional cerebral blood flow. *Acta Neurol.Scand.Suppl.*, **64**, 234-5, 285.
- HOUGAARD K, OIKAWA T, SVEINSDOTTIR E, SKINHOJ E, INGVAR DH, LASSEN NA (1976) Regional cerebral blood flow in focal cortical epilepsy. *Arch.Neurol.*, **33**, 527-535.
- HOULT DI, RICHARDS RE (1976) The signal-to-noise ratio of the nuclear magnetic resonance experiment. *J. of Magn. Reson.*, **24**, 71-85.
- HOUSTON AS, KEMP PM., MACLEOD MA. (1994) A method for assessing the significance of abnormalities in HMPAO brain SPECT images. *J Nucl Med* **35**, 239-244.
- HUGG JW, KUZNIECKY RI, GILLIAM FG, MORAWERZ RB, FAUGHT RE, HETHERINGTON HP (1996) Normalization of contralateral metabolic function

- following temporal lobectomy demonstrated by  $^1\text{H}$  magnetic resonance spectroscopic imaging. *Ann.Neurol.*, **40**, 236-239.
- HUGG JW, LAXER KD, MATSON GB, MAUDSLEY AA, HUSTED CA, WEINER MW (1992) Lateralization of human focal epilepsy by  $^{31}\text{P}$  magnetic resonance spectroscopic imaging. *Neurology*, **42**, 2011-2018.
- HUGG JW, LAXER KD, MATSON GB, MAUDSLEY AA, WEINER MW (1993) Neuron loss localizes human temporal lobe epilepsy by in vivo proton magnetic resonance spectroscopic imaging. *Ann.Neurol.*, **34**, 788-794.
- IADECOLA C, PELLIGRINO DA, MOSKOWITZ MA, LASSEN NA (1994) Nitric oxide synthase inhibition and cerebrovascular regulation. *J.Cerebr. Blood Flow Metab.*, **14**, 175-192.
- IGNELZI RJ, BUCY PC (1968) Cerebral hemidecortication in the treatment of infantile cerebral hemiatrophy. *J.Nerv.Ment.Dis.*, **147**, 14-30.
- INCISA DELLA ROCCHETTA A, GADIAN DG, CONNELLY A., POLKEY CE., JACKSON GD., WATKINS KE.*et al.* (1995) Verbal memory impairment after right temporal lobe surgery: role of contralateral damage as revealed by  $^1\text{H}$  magnetic resonance spectroscopy and  $T_2$  relaxometry. *Neurology* **45**, 797-802.
- INGVAR M, SIESJO BK (1983) Local blood flow and glucose consumption in the rat brain during sustained bicuculline-induced seizures. *Acta Neurol.Scand.*, **68**, 129-144.
- INUGAMI A, KANNO I, UEMURA K, SHISHIDO F, MURAKAMI M, TOMURA N, FUJITA H, HIGANO S. (1988) Linearization correction of  $^{99\text{m}}\text{Tc}$ -labeled hexamethyl-propylene amine oxime (HM-PAO) image in terms of regional CBF distribution: comparison to  $\text{C}^{15}\text{O}_2$  inhalation steady-state method measured by positron emission tomography. *J.Cereb.Blood Flow Metab.* **8**, S52-S60.
- ISAACS E, CHRISTIE D, VARGHA-KHADEM F, MISHKIN M (1996) Effects of hemispheric side of injury, age at injury, and presence of seizure disorder on functional ear and hand asymmetries in hemiplegic children. *Neuropsychologia.*, **334**, 127-137.
- JACK CR, Jr., MULLAN BP, SHARBROUGH FW, CASCINO GD, HAUSER MF, KRECKE KN, et al (1994) Intractable nonlesional epilepsy of temporal lobe origin: Lateralization by interictal SPECT vs MRI. *Neurology*, **44**, 829-836.
- JACK CR, Jr., SHARBROUGH FW, TWOMEY CK, CASCINO GD, HIRSCHORN KA, MARSH WR, et al (1990) Temporal lobe seizures: lateralization with MR volume measurements of the hippocampal formation. *Radiology*, **175**, 423-429.
- JACKSON GD, BERKOVIC SF, TRESS BM, KALNINS RM, FABINYI GC, BLADIN PF (1990) Hippocampal sclerosis can be reliably detected by magnetic resonance imaging. *Neurology*, **40**, 1869-1875.

- JACKSON GD, CONNELLY A, DUNCAN JS, GRUNEWALD RA, GADIAN DG.  
(1993a) Detection of hippocampal pathology in intractable partial epilepsy: Increased sensitivity with quantitative magnetic resonance T<sub>2</sub> relaxometry. *Neurology* **43**, 1793-1799.
- JACKSON GD, CONNELLY A, DUNCAN JS, GRUNEWALD RA, GADIAN DG  
(1993b) Detection of hippocampal pathology in intractable partial epilepsy: increased sensitivity with quantitative magnetic resonance T2 relaxometry. *Neurology*, **43**, 1793-1799.
- JACKSON JH (1896) In *John Hughlings Jackson: Selected Writings. Volume one, on epilepsy and epileptiform convulsions*. Edited by J Taylor, G Holmes, FWR Walshe. Nijmegen: Arts & Boeve.
- JAY V, BECKER LE, OTSUBO H, HWANG PA, HOFFMAN HJ, HARWOOD NASH D (1993) Pathology of temporal lobectomy for refractory seizures in children. Review of 20 cases including some unique malformative lesions. *J.Neurosurg.*, **79**, 53-61.
- JAYAKAR P, DUCHOWNY M, RESNICK T, ALVAREZ L (1992) Ictal head deviation: lateralizing significance of the pattern of head movement. *Neurology*, **42**, 1989-1992.
- JAYAKAR P, DUCHOWNY MS (1990) Complex partial seizures of temporal lobe origin in early childhood. *J.Epilepsy*, **3**, 41-45.
- JIBIKI I, YAMAGUCHI N, MATSUDA H, HISADA K (1990) Fluctuations of interictal brain imaging in repeated 123I-IMP SPECT scans in an epileptic patient. *J.Neurol.*, **237**, 372-375.
- KAUFMANN WE, GALABURDA AM (1989a) Cerebrocortical microdysgenesis in neurologically normal subjects. *Neurology*, **39**, 238-244.
- KAUFMANN WE, GALABURDA AM (1989b) Cerebrocortical microdysgenesis in neurologically normal subjects: A histopathologic study. *Clin.Neurosci*, **51**, 138-139.
- KIM SE, JACKSON GD, FITT G, MITCHELL A, SYNGNIOTIS A, BERKOVIC SF (1997) Hippocampal T2 relaxometry in patients with seizure: intractability correlates with T2 findings. *Epilepsia*, **38**, 51(Abstract)
- KLEIN B, KUSCHINSKY W, SCHROCK H (1986) Interdependency of local capillary density, blood flow and metabolism in rat brains. *Am.J.Physiol.*, **251**, H1333-H1340
- KLOSE U (1990) In vivo proton spectroscopy in presence of eddy currents *Magn.Reson.Med* **14**, 26-30.

- KOLLER KJ, ZACZEK R, COYLE JT (1984) N-acetyl-aspartyl-glutamate: regional levels in rat brain and the effects of brain lesions as determined by a new HPLC method. *J.Neurochem.*, **43**, 1136-1142.
- KOTAGAL P, ROTHNER AD, ERENBERG G, CRUSE RP, WYLLIE E (1987) Complex partial seizures of childhood onset. A five-year follow-up study. *Arch.Neurol.*, **44**, 1177-1180.
- KREIS R, ERNST T, ROSS BD (1993) Development of the human Brain: *in vivo* quantification of metabolite and water content with proton magnetic resonance spectroscopy. *Magn.Reson.Imaging*, **30**, 424-437.
- KRYNAUW RA (1950) Infantile hemiplegia treated by removing one cerebral hemisphere. *J.Neurol.Neurosurg.Psychiatry*, **13**, 243-267.
- KUHL DE, ENGEL J JR, PHELPS ME., SELIN C. (1980) Epileptic patterns of local cerebral metabolism and perfusion in humans determined by emission computed tomography of <sup>18</sup>FDG and <sup>13</sup>NH<sub>3</sub>. *Ann.Neurol.* **8**, 348-360.
- KUIKKA JT, MERVAALA E, VANNINEN E, KÄLVIÄINEN R (1994) Does technetium-99m bicsate image local brain metabolism in late ictal temporal lobe epilepsy? *Eur.J.Nucl.Med.*, **21**, 1247-1251.
- KUKS JB, COOK MJ, FISH DR, STEVENS JM, SHORVON SD (1993) Hippocampal sclerosis in epilepsy and childhood febrile seizures. *Lancet*, **342**, 1391-1394.
- KUSCHINSKY W, SUDA S, SOKOLOFF L (1981) Local cerebral glucose utilization and blood flow during metabolic acidosis. *Am.J.Physiol.*, **241**, H772-H777
- KUSCHINSKY W, WAHL M, BOSSE O, THURAU K. (1972) Perivascular potassium and pH as determinants of local pial arterial diameters in cats. *Circ. Res.* **31**, 240-247.
- KUSCHINSKY W, WAHL M. (1978) Local chemical and neurogenic regulation of cerebrovascular resistance. *Physiol.Rev.* **58**, 656-689.
- KUSCHINSKY W, WAHL M (1979) Perivascular pH and pial arterial diameter during bicuilline induced seizures in cats. *Pflugers Arch.*, **382**, 81-85.cited in Kuschinsky, W. Regulation of cerebral blood flow: an overview. In *Neurophysiological Basis of Cerebral Blood Flow: An Introduction*. Edited by S. Mraovitch and R Sercombe. London.: John Libbey & Co Ltd,
- KUZNIECKY R, BURGARD S, FAUGHT E, MORAWETZ R, BARTOLUCCI A (1993) Predictive value of magnetic resonance imaging in temporal lobe surgery *Arch.Neurol.* **50**, 65-69.
- KUZNIECKY R, ELGAVISH GA, HETHERINGTON HP, EVANOCHKO WT, POHOST GM (1992) In vivo <sup>31</sup>P nuclear magnetic resonance spectroscopy of human temporal lobe epilepsy. *Neurology*, **42**, 1586-1590.

- KUZNIECKY R, MURRO A, KING D, MORAWETZ R, SMITH J, POWERS R, et al (1993) Magnetic resonance imaging in childhood intractable partial epilepsies: Pathologic correlations. *Neurology*, **43**, 681-687.
- KUZNIECKY R, de la SAYETTE V, ETHIER R, MELANSON D, ANDERMANN F, BERKOVIC S, ROBITAILLE Y, OLIVIER A, PETERS T, FEINDEL W, (1987) Magnetic resonance imaging in temporal lobe epilepsy: pathological correlations. *Ann. Neurol.* **22**, 341-347.
- KUZNIECKY RI, BARKOVICH AJ (1996) Pathogenesis and pathology of focal malformations of cortical development and epilepsy. *J.Clin.Neurophysiol.*, **13**, 468-480.
- LAICH E, KUZNIECKY R, MOUNTZ J, LIU HG, GILLIAM F, BEBIN M, FAUGHT E, MORAWETZ R (1997) Supplementary sensorimotor area epilepsy. Seizure localization, cortical propagation and subcortical activation pathways using ictal SPECT. *Brain* **120**, 855-864.
- LANSKA MJ, LANSKA DJ, HORWITZ SJ, ARAM DM (1991) Presentation, clinical course, and outcome of childhood stroke. *Pediatr.Neurol.*, **7**, 333-341.
- LAVY S, MELAMED E, PORTNOY Z, CARMON A (1976) Interictal regional cerebral blood flow in patients with partial seizures. *Neurology*, **26**, 418-422.(Abstract)
- LAXER KD, HUBESCH B, SAPPEY-MARINIER D, WEINER MW (1992) Increased pH and inorganic phosphate in temporal seizure foci demonstrated by <sup>31</sup>P MRS. *Epilepsia*, **33**, 618-623.
- LEE BI, MARKAND ON, WELLMAN HN, SIDDIQUI AR, MOCK B, KREPSHAW J, et al (1987) HIPDM single photon emission computed tomography brain imaging in partial onset secondarily generalized tonic-clonic seizures. *Epilepsia*, **28**, 305-311.
- LEE BI, MARKAND ON, WELLMAN HN, SIDDIQUI AR, PARK HM, MOCK B, et al (1988) HIDPM-SPECT in patients with medically intractable complex partial seizures *Arch. Neurol.* **45**, 397-402.
- LEIDERMAN DB, BALISH M, SATO S, KUFTA C, REEVES P, GAILLARD WD, et al (1992) Comparison of PET measurements of cerebral blood flow and glucose metabolism for the localization of human epileptic foci. *Epilepsy Res.*, **13**, 153-157.
- LENCZ T, MCCARTHY G, BRONEN RA, SCOTT TM, INSERNI JA, SASS KJ, et al (1992) Quantitative magnetic resonance imaging in temporal lobe epilepsy: relationship to neuropathology and neuropsychological function. *Ann.Neurol.*, **31**, 629-637.
- LESTER M (1993) Capturing the image with the signal: a system developed in a paediatric neurophysiology department which changes a routine EEG into a video/EEG. *J.Electrophysiol.Technol.*, **19**, 121-128.

- LÉVESQUE MF, NAKASATO N, VINTERS HV, BABB TL (1991) Surgical treatment of limbic epilepsy associated with extrahippocampal lesions: the problem of dual pathology. *J.Neurosurg.*, **75**, 364-370.
- LINDSAY J, OUNSTED C, RICHARDS P (1979) Long-term outcome in children with temporal lobe seizures. I: Social outcome and childhood factors. *Dev.Med. Child Neurol.*, **21**, 285-298.
- LIU Z, MIKATI M, HOLMES GL. (1995) Mesial temporal sclerosis: pathogenesis and significance. *Pediatr.Neurol.* **12**(1), 5-16..
- LOISEAU P, DARTIGUES JF, PESTRE M (1983) Prognosis of partial epileptic seizures in the adolescent. *Epilepsia*, **24**, 472-481.
- MARCIANI MG, GOTMAN J, ANDERMANN F, OLIVIER A (1985) Patterns of seizure activation after withdrawal of antiepileptic medication *Neurology* **35**, 1537-1543.
- MARCIANI MG, GOTMAN J (1986) Effects of drug withdrawal on seizure onset *Epilepsia* **27** (4), 423-431.
- MARGERISON JH, CORSELLIS JA (1966) Epilepsy and the temporal lobes. A clinical, electroencephalographic and neuropathological study of the brain in epilepsy, with particular reference to the temporal lobes. *Brain*, **89**, 499-530.
- MARKS DA, KATZ A, HOFFER P, SPENCER SS (1992) Localization of extratemporal epileptic foci during ictal single photon emission computed tomography. *Ann.Neurol.*, **31**, 250-255.
- MARKS DA, KATZ A, SCHEYER R, SPENCER SS (1991) Clinical and electrographic effects of acute anticonvulsant withdrawal in epileptic patients. *Neurology*, **41**, 508-512.
- MATHERN GW, BABB TL, MISCHEL PS, VINTERS HV, PRETORIUS JK, LEITE JP, et al (1996) Childhood generalized and mesial temporal epilepsies demonstrate different amounts and patterns of hippocampal neuron loss and mossy fibre synaptic reorganization. *Brain*, **119**, 965-987.
- MATHERN GW, BABB TL, PRETORIUS JK, MELENDEZ M, LÉVESQUE MF (1995a) The pathophysiologic relationships between lesion pathology, intracranial ictal EEG onsets, and hippocampal neuron losses in temporal lobe epilepsy. *Epilepsy Res.*, **21**, 133-147.
- MATHERN GW, BABB TL, VICKREY BG, MELENDEZ M, PRETORIUS JK. (1995b) The clinical-pathogenic mechanisms of hippocampal neuron loss and surgical outcomes in temporal lobe epilepsy. *Brain* **118**, 105-118
- MATHERN GW, PRETORIUS JK, BABB TL (1995c) Influence of the type of initial precipitating injury and at what age it occurs on course and outcome in patients with temporal lobe seizures. *Journal of Neurosurgery*, **82**, 220-227.

- MATHIESON G (1975) Pathology of temporal lobe foci. *Adv.Neurol.*, **11**, 163-185.
- MATSUDA H, TSUJI S, SHUKE N, SUMIYA H, TONAMI N, HISADA K. (1992) A quantitative approach to technetium-99m hexamethylpropylene amine oxime. *Eur.J.Nucl.Med* **19**, 195-200..
- MATSUDA H, TSUJI S, SHUKE N, SUMIYA H, TONAMI N, HISADA K. (1993) Noninvasive measurements of regional cerebral blood flow using technetium-99m hexamethylprophylene amine oxime. *Eur.J.Nucl.Med* **20**(5), 391-401..
- MEENCKE H-J, VEITH G (1992) Migration disturbances in epilepsy. In: *Molecular Neurobiology of Epilepsy*. Edited by JJ Engel, CG Wasterain, EA Cavalheiro, U Heinemann. Amsterdam: Elsevier Science. 31-40.
- MELDRUM BS, VIGOUROUX RA, BRIERLEY JB (1973) Systemic factors and epileptic brain damage. Prolonged seizures in paralyzed, artificially ventilated baboons. *Arch.Neurol.*, **29**, 82-87.
- MEYER A, FALCONER MA, BECK E (1954) Pathological findings in temporal lobe epilepsy. *J. Neurol. Neurosurg. Psychiatry*, **17**, 276-285.
- MEYER FB, MARSH WR, LAWS ER, Jr., SHARBROUGH FW (1986) Temporal lobectomy in children with epilepsy. *J.Neurosurg.*, **64**, 371-376.
- MILEY CE, FORSTER FM (1977) Activation of partial complex seizures by hyperventilation. *Arch.Neurol.*, **34**, 371-373.
- MINFORD AM, FORSYTHE WI (1992) Computed tomography findings in partial seizures. *Arch.Dis.Child*, **67**, 693-696.
- MIZRAHI EM, KELLAWAY P, GROSSMAN RG, RUTECKI PA, ARMSTRONG D, RETTIG G, et al (1990) Anterior temporal lobectomy and medically refractory temporal lobe epilepsy of childhood. *Epilepsia*, **31**, 302-312.
- MOUNTZ JM, DEUTSCH G, KUZNIECKY R, ROSENFELD SS (1994) Brain SPECT: 1994 Update. In: *Nuclear Medicine Annual 1994*. Edited by LM Freeman. New York: Raven Press Ltd. 1-54.
- MUGLER JP, BROOKEMAN JR (1990) Three-dimensional magnetization-prepared rapid gradient-echo imaging (3-D MPRAGE). *Magn Reson Med* **15**,152-157
- MURASE K, TANADA S, FUJITA H, SAKAKI S, HAMAMOTO K. (1992) Kinetic behaviour of Technetium-99m-HMPAO in the human brain and quantification of cerebral blood flow using dynamic SPECT. *J. Nucl. Med.* **33**, 135-143.
- NASHEF L, FISH DR, GARNER S, SANDER JWAS, SHORVON SD (1995) Sudden death in epilepsy: A study of incidence in a young cohort with epilepsy and learning difficulty. *Epilepsia*, **36** , 1187-1194.

- NEIRINCKX RD, BURKE JF, HARRISON RC, FORSTER AM, ANDERSEN AR, LASSEN NA. (1988) The retention mechanism of technetium-99m-HM-PAO: intracellular reaction with glutathione. *J. Cerebr. Blood Flow Metab.* **8**, s4-s12..
- NEIRINCKX, R. D., CANNING, L. R., PIPER, I. M., NOWOTNIK, D. P., PICKETT, R. D., HOLMES, R. A., VOLKERT, W. A., FORSTER, A. M., WEISNER, P. S., MARRIOTT, J. A., AND CHAPLIN, S. B. (1987) Technetium-99m d,1-HM-PAO: a new radiopharmaceutical for SPECT imaging of regional cerebral blood perfusion. *J.Nucl.Med* **28**(2), 191-202..
- NEVANDER G, INGVAR M, AUER R, SIESJO BK (1985) Status epilepticus in well-oxygenated rats causes neuronal necrosis. *Ann.Neurol.*, **18**, 281-290.
- NEWTON MR, AUSTIN MC, CHAN JG, MCKAY WJ, ROWE CC, BERKOVIC SF (1993) Ictal SPECT using technetium-99m-HMPAO: methods for rapid preparation and optimal deployment of tracer during spontaneous seizures. *J.Nucl.Med*, **34**, 666-670.
- NEWTON MR, BERKOVIC SF, AUSTIN MC, REUTENS DC, MCKAY WJ, BLADIN PF (1992a) Dystonia, clinical lateralization, and regional blood flow changes in temporal lobe seizures. *Neurology*, **42**, 371-377.
- NEWTON MR, BERKOVIC SF, AUSTIN MC, ROWE CC, MCKAY WJ, BLADIN PF (1992b) Postictal switch in blood flow distribution and temporal lobe seizures. *J.Neurol.Neurosurg.Psychiatry*, **55**, 891-894.
- NG TC, COMAIR Y, XUE M, SO N, MAJORS A, KOLEM H, et al (1994) Temporal lobe epilepsy: presurgical localization with proton chemical shift imaging. *Radiology*, **193**, 463-472.
- NORMAN MG (1980) Bilateral encephaloclastic lesions in a 26 week gestation fetus: Effect of neuroblast migration. *Can.J.Neurol.Sci.*, **7**, 191-194.
- NORMAN MG, O'KUSKY JR (1986) The growth and development of microvasculature in human cerebral cortex. *J.Neuropathol.Exp.Neurol.*, **45**, 222-232.
- OGUNI H, ANDERMANN F, RASMUSSEN TB (1992) The syndrome of chronic encephalitis and epilepsy. A study based on the MNI series of 48 cases. *Adv.Neurol.*, **57**, 419-433.
- OKA E, YAMATOYI Y, OHTSUKA Y, OHTAHARA S (1989) Clinical course and prognosis of childhood epilepsy. *Acta Paediatr.Jpn.Overseas.Ed.*, **31**, 259-266.
- OKUDAIRA Y, ARAI H, SATO K (1997) Hemodynamic compromise as a factor in clinical progression of Sturge-Weber syndrome. *Child's Nerv.Syst*, **13**, 214-219.
- OPPENHEIMER DE, GRIFFITH HB (1966) Persistent intracranial bleeding as a complication of hemispherectomy. *J.Neurol.Neurosurg.Psychiatry*, **29**, 229-240.



- ORMSON MJ, KISPERS DB, SHARBROUGH FW, HOUSER OW, EARNEST F, SCHEITHAUER BW, et al (1986) Cryptic structural lesions in refractory partial epilepsy: MR imaging and CT studies. *Radiology*, **160**, 215-219.
- OTSUBO H, HWANG PA, HOFFMAN HJ, BECKER LE, GILDAY DL, CHUANG SH, et al (1995) Neuroimaging studies in children with temporal lobectomy. *Child's Nerv.Syst*, **11**, 281-287.
- OUNSTED, C., LINDSAY, J., AND RICHARDS, P. (1987) *Temporal Lobe Epilepsy 1948-1986: A Biographical Study*. 1-129. Oxford, MacKeith Press.
- OXBURY JM, ADAMS CB (1989) Neurosurgery for epilepsy. *Br.J.Hosp.Med.*, **41**, 372-377.
- PAEDIATRIC TASK GROUP EUROPEAN ASSOCIATION NUCLEAR MEDICINE MEMBERS., PIEPSZ A, HAHN K, ROCA I, CIOFETTA G, TOTTH G, et al (1990) A radiopharmaceuticals schedule for imaging in paediatrics. *Eur.J.Nucl.Med.*, **17**, 127-129.
- PAILLAS JE, GASTAUT H, SEDAN R, BUREAU M (1983) Long-term results of conventional surgical treatment for epilepsy. *Surg Neurol*. **20**, 189-93.
- PALMINI A, ANDERMANN F, AICARDI J, DULAC O, CHAVES F, PONSOT G, et al (1991a) Diffuse cortical dysplasia, or the 'double cortex' syndrome: the clinical and epileptic spectrum in 10 patients. *Neurology*, **41**, 1656-1662.
- PALMINI A, ANDERMANN F, OLIVIER A, TAMPIERI D, ROBITAILLE Y, ANDERMANN E, et al (1991b) Focal neuronal migration disorders and intractable partial epilepsy: a study of 30 patients. *Ann.Neurol.*, **30**, 741-749.
- PAMPIGLIONE G (1977) Development of rhythmic EEG activities in infancy (waking state). *Rev.Electroencephalogr.Neurophysiol.Clin.*, **7**, 327-324.
- PEARCE WJ, HARDER DR (1996) Cerebrovascular smooth muscle and endothelium. In: *Neurophysiological Basis of Cerebral Blood Flow Control: An Introduction*. Edited by S Mraovitch, R Sercombe. London: John Libbey & Co Ltd. 145-175.
- PENFIELD W (1933) The evidence for a cerebral vascular mechanism in epilepsy. *Ann.Intern.Med*, **7**, 303-310.
- PENFIELD W, VON SANTHA K, CIPRIANI A (1939) Cerebral blood flow during induced epileptiform seizures in animals and man. *Journal of Neurophysiology*, **2**, 257-267.
- PLUM F, DUFFY TE (1975) The couple between cerebral metabolism and blood flow during seizures.. In: *Brain work the coupling of function metabolism and blood flow in the brain* Edited by Ingvar DH, Lassen NA, Copenhagen: Munksgaard. 197-214.,

- PLUM F, POSNER JB, TROY B (1968) Cerebral metabolic and circulatory responses to induced convulsions in animals. *Arch.Neurol.*, **18**, 1-13.
- PODREKA I, SUESS E, GOLDENBERG G, STEINER M, BRUCKE T, MULLER C, et al (1987) Initial experience with technetium-99m HM-PAO brain SPECT. *J.Nucl.Med*, **28**, 1657-1666.
- PRINCE DA, WILDER BJ (1967) Control mechanisms in cortical epileptogenic foci. "Surround" inhibition. *Arch.Neurol.*, **16**, 194-202.
- PUPI A, DECRISTOFARO MTR., BACCIOTTINI L, ANTONIUCCI D, FORMICONI AR, MASCALCHI M, MELDOLESI U. (1991) An analysis of the arterial input curve for technetium-99m-HMPAO: quantification of rCBF using single photon emission computed tomography. *J Nucl Med* **32**, 1501-1506.
- QUESNEY LF (1986) Clinical and EEG features of complex partial seizures of temporal lobe origin. *Epilepsia*, **27 Suppl 2**, S27-S45
- QUESNEY LF, RISINGER MW, SHEWMON DA (1993) Extracranial EEG evaluation. In: *Surgical Treatment of the Epilepsies*. Edited by J Engel, Jr. New York: Raven Press Ltd. 173-195.
- RASMUSSEN T (1983 ) Hemispherectomy for seizures revisited. *Can.J.Neurol.Sci.*, **10**, 71-78.
- RASMUSSEN T (1983 .) The 1982 Penfield Lecture: Hemispherectomy for seizures revisited. *Can.J.Neurol.Sci.*, **10**, 71-78.
- RASMUSSEN T, MCCANN W (1968) Clinical studies of patients with focal epilepsy due to "chronic encephalitis". *Trans.Am.Neurol.Assoc.*, **93**, 89-94.
- RAYMOND AA, FISH DR, STEVENS JM, COOK MJ, SISODIYA SM, SHORVON SD (1994a) Association of hippocampal sclerosis with cortical dysgenesis in patients with epilepsy. *Neurology*, **44**, 1841-1845.
- RAYMOND AA, HALPIN SF, ALSANJARI N, COOK MJ, KITCHEN ND, FISH DR.,et al. (1994) Dysembryoplastic neuroepithelial tumour features in 16 patients. *Brain* **117**, 461-475.
- RESTA M, PALMA M, DICUONZO F, SPAGNOLO P, SPECCHIO LM, LANEVE A, et al (1994) Imaging studies in partial epilepsy in children and adolescents. *Epilepsia*, **35**, 1187-1193.
- REYNOLDS EH, ELWES RD, SHORVON SD (1983) Why does epilepsy become intractable? Prevention of chronic epilepsy. *Lancet*, **2**, 952-954.
- RIVELLO JJ, FOLEY CM (1992) The epileptiform significance of intermittent rhythmic delta activity in childhood. *J.Child Neurol.*, **7**, 156-160.

- RONNE-ENGSTROM E, CARLSON H., BLOM S, FLINK R, GAZELIUS B, SPANNARE B, HILLERED L. (1993) Monitoring of cortical blood flow in human epileptic foci using laser doppler flowmetry. *J Epilepsy* **6**, 145-151..
- ROSS EM, PECKHAM CS, WEST PB, BUTLER NR (1980) Epilepsy in childhood: findings from the National Child Development Study. *Br.Med.J.*, **280**, 207-210.
- ROTH SC, AZZOPARDI D, EDWARDS AD, BAUDU J, CADY EB, TOWNSEND J, DELPY DT, STEWART AL, WYATT JS, REYNOLDS EOR (1992) Relation between cerebral oxidative metabolism following birth asphyxia and neurodevelopmental outcome and brain growth at one year *Dev.Med.Child.Neurol.* **34**, 285-295.
- ROUGIER A, DARTIGUES JF, COMMENGES D, CLAVERIE B, LOISEAU P, COHADAN F (1992) A longitudinal assessment of seizure outcome and overall benefit from 100 corticectomies for epilepsy. *J. Neurol. Neurosurg. Psychiatry* **55**, 762-767.
- ROWE CC, BERKOVIC SF, AUSTIN MC, MCKAY WJ, BLADIN PF (1991a) Patterns of postictal cerebral blood flow in temporal lobe epilepsy: qualitative and quantitative analysis. *Neurology*, **41**, 1096-1103.
- ROWE CC, BERKOVIC SF, AUSTIN MC, SALING M, KALNINS RM, MCKAY WJ, et al (1991b) Visual and quantitative analysis of interictal SPECT with technetium- 99m-HMPAO in temporal lobe epilepsy. *J.Nucl.Med*, **32**, 1688-1694.
- ROWE CC, BERKOVIC SF, SIA ST, AUSTIN M, MCKAY WJ, KALNINS RM, et al (1989) Localization of epileptic foci with postictal single photon emission computed tomography. *Ann.Neurol.*, **26**, 660-668.
- RYVLIN P, PHILIPPON B, CINOTTI L, FROMENT JC, LE BARS D, MAUGUIERE F (1992) Functional neuroimaging strategy in temporal lobe epilepsy: a comparative study of 18FDG-PET and 99mTc-HMPAO-SPECT. *Ann.Neurol.* , **31**, 650-656.
- SALANOVA V, ANDERMANN F, RASMUSSEN T, OLIVIER A, QUESNEY LF (1995) Parietal lobe epilepsy. Clinical manifestations and outcome in 82 patients treated surgically between 1929 and 1988. *Brain*, **118**, 607-627.
- SAMMARITANO M, GIGLI GL, GOTMAN J (1991) Interictal spiking during wakefulness and sleep and the localization of foci in temporal lobe epilepsy. *Neurology*, **41**, 290-297.
- SARNAT HB (1992) *Cerebral Dysgenesis: Embryology and Clinical Expression*. Oxford: Oxford University Press.

- SHARP PF, SMITH FW, GEMMELL HG, LYALL D, EVANS NTS, GVOZDANOVIC D, et al (1994) Technetium-99m HMPAO stereoisomers as potential agents for imaging regional cerebral blood flow: human volunteer studies. *J. Nucl. Med.*, **27**, 171-177.
- SHIELDS WD, SHEWMON DA, CHUGANI HT, PEACOCK WJ (1992) Treatment of infantile spasms: medical or surgical? *Epilepsia*, **33 Suppl 4**, S26-S31
- SHINOZUKA T, NEMOTO EM, WINTER PM (1989) Mechanisms of cerebrovascular O<sub>2</sub> sensitivity from hyperoxia to moderate hypoxia in the rat. *J. Cerebr. Blood Flow Metab.*, **9**, 187-195.
- SILLANPAA M (1990) Children with epilepsy as adults: outcome after 30 years of follow-up. *Acta Paediatr.Scand.Suppl.*, **368**, 1-78.
- SISODIYA SM, FREE SL, STEVENS JM, FISH DR, SHORVON SD (1995) Widespread cerebral structural changes in patients with cortical dysgenesis and epilepsy. *Brain*, **118**, 1039-1050.
- SISODIYA SM, STEVENS JM, FISH DR, FREE SL, SHORVON SD (1996) The demonstration of gyal abnormalities in patients with cryptogenic partial epilepsy using three-dimensional MRI. *Arch.Neurol.*, **53**, 28-34.
- SISODIYA SM, MORAN N, FREE SL, KITCHEN ND, STEVENS JM, HARKNESS WF, FISH DR, SHORVON SD. (1997) Correlation of widespread preoperative magnetic resonance imaging changes with unsuccessful surgery for hippocampal sclerosis. *Ann. Neurol.* **41(4)**, 490-496.
- SMITH NM, CARLI MM, HANIEH A, CLARK B, BOURNE AJ, BYARD RW (1992) Gangliogliomas in childhood. *Child's Nerv.Syst.*, **8**, 258-265.
- SO N, GOTMAN J (1990) Changes in seizure activity following anticonvulsant drug withdrawal. *Neurology*, **40**, 407-413.
- SOMMER W (1880) Erkrankung des ammonshorns als aetiologisches moment der epilepsie. *Arch.Psychiatr.Nervenkr.*, **10**, 631-675.
- SPENCER SS, SPENCER DD, WILLIAMSON PD, MATTSON RH (1981) Ictal effects of anticonvulsant medication withdrawal in epileptic patients. *Epilepsia*, **22**, 297-307.
- SPENCER SS, WILLIAMSON PD, BRIDGERS SL, MATTSON RH, CICCHETTI DV, SPENCER DD (1985) Reliability and accuracy of localization by scalp ictal EEG. *Neurology*, **35**, 1567-1575.
- SPERLING MR, WILSON G, ENGEL J, Jr., BABB TL, PHELPS M, BRADLEY W (1986) Magnetic resonance imaging in intractable partial epilepsy: correlative studies. *Ann.Neurol.*, **20**, 57-62.

- STAUDER KH (1936) Epilepsie und schläfenlappen. *Arch.Psychiatr.Nervenkr.*, **104**, 181-212.
- STEFAN H, KUHNEN C, BIRSACK HJ, REICHMANN K (1987a) Initial experience with <sup>99m</sup>Tc-hexamethyl-propylene amine oxime (HM- PAO) single photon emission computed tomography (SPECT) in patients with focal epilepsy. *Epilepsy Res.*, **1**, 134-138.
- STEFAN H, PAWLIK G, BOCHER-SCHWARZ HG, BIRSACK HJ, BURR W, PENIN H, et al (1987b) Functional and morphological abnormalities in temporal lobe epilepsy: a comparison of interictal and ictal EEG, CT, MRI, SPECT and PET. *J.Neurol.*, **234**, 377-384.
- STORES G, ZAIWALLA Z, BERGEL N (1991) Frontal lobe complex partial seizures in children: a form of epilepsy at particular risk of misdiagnosis. *Dev.Med.Child Neurol.*, **33**, 998-1009.
- SUESS E, HUCK S, REITHER H, HORTNAGL H, ANGELBERGER P. (1992) Uptake mechanism of technetium-<sup>99m</sup>-d,l-HMPAO in cell cultures of the dissociated postnatal rat cerebellum. *J Nucl Med* **33**, 108-114.
- SUESS E, MALESSA S, UNGERSBOCK K, KITZ P, PODREKA I, HEIMBERGER K, et al. (1991) Technetium-<sup>99m</sup>-d,l-Hexamethylpropyleneamine oxime (HMPAO) uptake and glutathione content in brain tumors. *J. Nucl. Med* **32**, 1675-1681.
- SUTTON LN, WANG Z, GUSNARD D, LANGE B, PERILONGO G, BOGDAN AR., et al. (1992) Proton magnetic resonance spectroscopy of pediatric brain tumors. *Neurosurgery* **31**(2), 195-202..
- SWARTZ BE, WALSH GO, DELGADO-ESCUETA AV, ZOLO P (1991) Surface ictal electroencephalographic patterns in frontal vs temporal lobe epilepsy. *Can.J.Neurol.Sci.*, **18**, 649-662.
- SYED GMS, EAGGER S, TOONE BK, LEVY R, BARRETT JJ (1992) Quantification of regional cerebral blood flow (rCBF) using <sup>99m</sup>Tc<sup>m</sup>-HMPAO and SPECT: choice of the reference region. *Nucl.Med Commun.*, **13**, 811-816.
- TAMPIERI D, MELANSON D, ETHIER R (1991) Imaging of chronic encephalitis. In *Chronic Encephalitis and Epilepsy - Rasmussens Syndrome*. Edited by F. Andermann. Boston, Butterworth. 47-72.
- TAYLOR DC (1986) One hundred years of epilepsy surgery: Sir Victor Horsley's contribution. *J.Neurol.Neurosurg.Psychiatry*, **49**, 485-488.
- TAYLOR DC (1990) Murray Falconer and epilepsy surgery: An appreciation. *J.Epilepsy*, **3**, 1-5.
- TAYLOR DC, FALCONER MA, BRUTON CJ, CORSELLIS JA (1971) Focal dysplasia of the cerebral cortex in epilepsy. *J.Neurol.Neurosurg.Psychiatry*, **34**, 369-387.

- TAYLOR DC, NEVILLE BGR, CROSS JH (1997) New measures of outcome needed for the surgical treatment of epilepsy. *Epilepsia*, **38**, 625-630.
- THURSTON JH, THURSTON DL, HIXON BB, KELLER AJ (1982) Prognosis in childhood epilepsy: additional follow-up of 148 children 15 to 23 years after withdrawal of anticonvulsant therapy. *N.Engl.J.Med.*, **306**, 831-836.
- TINUPER P, ANDERMANN F, VILLEMURE JG, RASMUSSEN TB, QUESNEY LF (1988) Functional hemispherectomy for treatment of epilepsy associated with hemiplegia: rationale, indications, results, and comparison with callosotomy. *Ann.Neurol.*, **24**, 27-34.
- TOUCHON J, VALMIER J, BALDY-MOULINIER M, CADILHAC J (1986) Regional cerebral blood flow during interictal state: differences between temporal lobe epilepsy and primary generalized epilepsy. *Eur.Neurol.*, **25**, 43-52.(Abstract)
- TROJABORG W (1966) Focal spike discharges in children, a longitudinal study. *Acta Paediatr.Scand.*, Suppl 168:-Suppl 168:Suppl 168:-Suppl 168
- UDVARHALYI GB, WALKER AE (1965) Dissemination of acute focal seizures in monkey. i. from cortical foci. *Arch.Neurol.*, **12**, 333-356.(Abstract)
- UENO H, YAMASHITA Y, CAVENESS WF (1975) Regional cerebral blood flow pattern in focal epileptiform seizures in the monkey. *Exp.Neurol.*, **47**, 81-96.
- URENJAK J, WILLIAMS SR., GADIAN DG., NOBLE M. (1992) Specific expression of N-acetylaspartate in neurons, oligodendrocyte typ-2 progenitors and immature oligodendrocytes in vitro. *Journal of Neurochemistry* **59**, 55-61.
- URENJAK J, WILLIAMS SR, GADIAN DG, NOBLE M (1993) Proton Nuclear Magnetic Resonance Spectroscopy Unambiguously Identifies Different Neural Cell Types. *The Journal of Neuroscience*, **13**, 981-989.
- VAN DER KNAAP, M. S., VAN DER GROND, J., VAN RIJEN, P. C., FABER, J. A. J., VALK, J., AND WILLEMSE, K. (1990) Age-dependent changes in localized proton and phosphorus MR spectroscopy of the brain. *Radiology* **176**, 509-515..
- VAN NESS PC, SO NK, COLLURA T, BECK GJ, LÜDERS H (1990) Ictal and intrictal EEG: what constitutes an adequate sample for epilepsy surgery? *Epilepsia*, **31**, 623
- VAN PAESSCHEN W, CONNELLY A, KING MD, JACKSON GD, DUNCAN JS (1997a) The spectrum of hippocampal sclerosis: A quantitative magnetic resonance imaging study. *Ann.Neurol.*, **41**, 41-51.
- VAN PAESSCHEN W, DUNCAN JS, STEVENS JM, CONNELLY A (1997b) Etiology and early prognosis of newly diagnosed partial seizures in adults: a quantitative hippocampal MRI study. *Neurology*, **49**, 753-757.

- VAN PAESSCHEN W, REVESZ T, DUNCAN JS, KING MD, CONNELLY A (1997c) Quantitative neuropathology and quantitative magnetic resonance imaging of the hippocampus in temporal lobe epilepsy. *Neurology*, **In Press**,
- VARGHA-KHADEM F, ISAACS E, VAN DER WERF S, ROBB S, WILSON J (1992) Development of intelligence and memory in children with hemiplegic cerebral palsy. The deleterious consequences of early seizures. *Brain* , **115 Pt 1**, 315-329.
- VEITH G, WICKE R (1968) Cerebrale differenzierungsstörungen bei epilepsie. In: *Jahrbuch Köln Opalden*. Anonymous Westdeutscher Verlag. 515-534.
- VERITY CM, ROSS EM, GOLDING J (1993) Outcome of childhood status epilepticus and lengthy febrile convulsions: findings of a national cohort study. *Brit. Med. J* **307**, 225-228
- VIGEVANO F, BERTINI E, BOLDRINI R, BOSMAN C, CLAPS D, DI CAPUA M, et al (1989) Hemimegalencephaly and intractable epilepsy: benefits of hemispherectomy. *Epilepsia*, **30**, 833-843.
- WALSH CA (1995) Neuronal identity, neuronal migration and epileptic disorders of the cerebral cortex. In: *Brain Development and Epilepsy*. Edited by PA Schwartzkroin, SL Moshe, JL Noebels, JW Swann. Oxford: Oxford University Press. 122-143.
- WHITE HH (1961) Cerebral hemispherectomy in the treatment of infantile hemiplegia. *Confin. Neurol.*, **21**, 1-50.
- WILLIAMSON PD (1993) Postscript: Lessons from failures. In *Surgical Treatment of the Epilepsies, second edition*. Edited by J Engel Jr, Raven Press, New York.
- WILLIAMSON PD, BOON PA, THADANI VM, DARCEY TM, SPENCER DD, SPENCER SS, et al (1992) Parietal lobe epilepsy: diagnostic considerations and results of surgery. *Ann. Neurol.*, **31**, 193-201.
- WILLIAMSON PD, SPENCER DD, SPENCER SS, NOVELLY RA, MATTSON RH (1985) Complex partial seizures of frontal lobe origin. *Ann. Neurol.*, **18**, 497-504.
- WILLIAMSON PD, SPENCER SS (1986) Clinical and EEG features of complex partial seizures of extratemporal origin. *Epilepsia*, **27 Suppl 2**, S46-S63
- WILLIAMSON PD, THADANI VM, DARCEY TM, SPENCER DD, SPENCER SS, MATTSON RH (1992) Occipital lobe epilepsy: clinical characteristics, seizure spread patterns, and results of surgery. *Ann. Neurol.*, **31**, 3-13.
- WYLLIE E, CHEE M, GRANSTRÖM M-L, DELGIUDICE E, ESTES M, COMAIR Y, et al (1993) Temporal lobe epilepsy in early childhood. *Epilepsia*, **34**, 859-868.
- WYLLIE E, COMAIR YG, KOTAGAL P, RAJA S, RUGGIERI P (1996) Epilepsy surgery in infants. *Epilepsia*, **37**, 635-637.

- WYLLIE E, LUDERS H (1989) Complex partial seizures in children. Clinical manifestations and identification of surgical candidates. *Cleve.Clin.J.Med.*, **56 Suppl Pt 1**, S43-52.
- WYLLIE E, LUDERS H, MORRIS HH, LESSER RP, DINNER DS, ROTHNER AD, et al (1988) Subdural electrodes in the evaluation for epilepsy surgery in children and adults. *Neuropediatrics.*, **19**, 80-86.
- WYLLIE E, LÜDERS H, MORRIS HHI, LESSER RP, DINNER DS, HAHN J, et al (1987) Clinical outcome after complete or partial cortical resection for intractable epilepsy. *Neurology*, **37**, 1634-1641.
- YAMAMOTO N, WATANABE K, NEGORO T, TAKAESU E, ASO K, FURUNE S, et al (1987) Complex partial seizures in children: ictal manifestations and their relation to clinical course. *Neurology*, **37**, 1379-1382.
- YAMATANI M, KONISHI T, MURAKAMI M, OKUDA T (1995) Hyperventilation activation on EEG recording in children with epilepsy. *Pediatr.Neurol.*, **13**, 42-45.
- YANG JS, PARK YD, HARTLAGE PL (1995) Seizures associated with stroke in childhood. *Pediatr.Neurol.*, **12**, 136-138.
- YARNELL, P. R., BURDICK, D., SANDERS, B., AND STEARS, J. (1974) Focal seizures, early veins, and increased flow. A clinical, angiographic, and radiosotopic correlation. *Neurology*, 512-516..
- YONEKURA Y, NISHIZAWA S, MUKAI T, FUJITA T, FUKUYAMA H, ISHIKAWA, M., et al. (1988) SPECT with [<sup>99m</sup>Tc]-*d,l*-hexamethyl-propylene amine oxime (HM-PAO) compared with regional cerebral blood flow measured by PET: effects of linearization. *J. Cerebr. Blood Flow Metab* **8**, s82-s89..
- YOUNKIN DP, DELIVORIA-PAPADOPOULOS M, LEONARD JC, SUBRAMANIAN VH, ELEFF S, LEIGH JS, et al (1994) Unique aspects of human newborn cerebral metabolism evaluated with phosphorus nuclear magnetic resonance spectroscopy. *Ann.Neurol.*, **6**, 581-586.
- ZENTNER J, WOLF HK, OSTERTUN B, HUFNAGEL A, CAMPOS MG, SOLYMOSI L, et al (1994) Gangliogliomas: clinical, radiological, and histopathological findings in 51 patients. *J.Neurol.Neurosurg.Psychiatry*, **57**, 1497-1502.



## List of recognised typographical errors

Page no	Item	Should read
16	Figure 6.10	Reposition page no
58	Last paragraph, penultimate sentence	omit second 'techniques'
61	..cellular proliferation occurs between the 10th...	..cellular proliferation occurs between the 10th...
63	Figure 3.1	<i>From Martin, 1989</i>
103	last paragraph	(Jackson <i>et al.</i> , 1993b) and
127	Urenjak	Change format
144	Figure 6.3	ROI missing
171	Table A6.1	4th column, postrior= posterior
194	Table 7.5	Rythmic = Rhythmic, H4 and H10
228	Last paragraph	Magnetic resonance imaging <i>has.....</i>
253	Add reference	MARTIN JH (1989) <i>Neuroanatomy: Text and Atlas</i> . New York: Elsevier..
257	Rasmussen 1983a,b	Remove a

## APPENDIX

### Methodology of SPECT

#### i) Data acquisition

The principal components of the equipment required to detect  $\gamma$  emission are a collimator, a crystal, a light guide, photomultipliers and a system for interpreting the signal that is produced. The role of the collimator is to select the direction of photons incident on the camera. It defines the geometrical field of view of the system and strongly influences the spatial resolution and sensitivity of the system. Most commonly multihole collimators are used, made up of a series of multiple holes (in the case of the current study parallel to each other) separated by septa of an optimal thickness to prevent penetration of photons. Single hole collimators are used for imaging small organs where the collimator can be placed close to the source. The crystal acts as a scintillator, emitting visible or near visible light when energy is absorbed from ionising radiation. Thallium activated sodium iodide NaI(Tl) is the crystal most widely used. It emits blue green light close to 415nm, its spectral output matches well with the light photon response of standard photomultipliers, and about 90% of 150keV photons are absorbed in about 10mm, making it highly suitable for  $^{99}\text{Tc}^m$  imaging. In view of the high refractive index of NaI(Tl), a light guide is required in addition to interface the scintillator to the photomultiplier. The photomultiplier absorbs the light produced, and emits photoelectrons that are amplified in the process, producing signal that can be detected electronically.

Data acquired using a rotating gamma are in the form of a series of 2D datasets containing multiple profiles, each profile representing a 1D projection of radioactivity in a single slice. Each point on the profile represents the linear sum (in the absence of

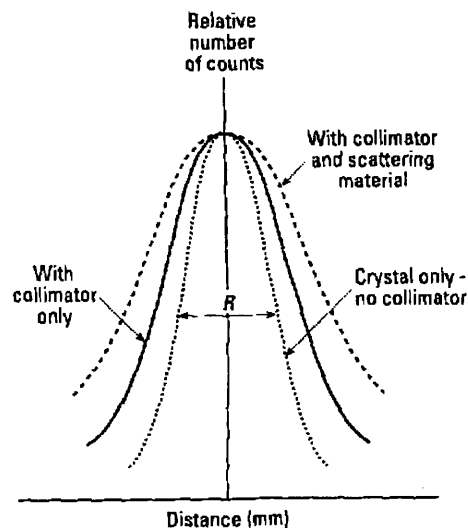
attenuation) of activity along the line of view. Spatial information is acquired by taking many datasets at regular angular intervals around an object. A single dataset is stored in a matrix where pixel size is smaller than desired image resolution. For a system such as the one used for the studies reported here, where spatial resolution is 10-15mm, a 64x64 matrix (with pixel size 6mm) is adequate with sampling every 6° over 360°. A greater matrix size (eg 128x128) may increase resolution but would require a greater number of samples, increase the storage requirements, increase processing time and consequently decrease counts per pixel.

A major source of error in the acquisition of data lies in any nonuniformities of the camera system. These are caused by variations in point source sensitivity across the camera, spatial distortion (from defects in the collimator) and variations caused by the earth's magnetic field. Spatial nonuniformity is corrected by generating a distortion map from a phantom. Energy nonuniformities, such as those resulting from decay and washout of the isotope during the study, are corrected by an energy correction map calculated by using an appropriate uniform radiation source. Such correction maps need to be acquired on the system to be used and applied online to each individual study.

### ***The problem of spatial resolution***

Spatial resolution can be defined as the ability of a system to produce two distinct images of two small sources close together. Spatial resolution of a gamma camera is predominantly influenced by the collimator and the distance from the patient. The *intrinsic* resolution of the system is defined as that achieved by the camera in the absence of the collimator and the patient, and is typically 3-4mm. The *system* spatial

resolution will be poorer than this, influenced by scatter of photons within the patient, and the geometrical spatial resolution of the collimator. With regard to the collimator, this is influenced by the length of holes within the collimator, and the distance between the source and the collimator. It is therefore necessary to acquire data with the collimator as close to the source as possible; this is extremely difficult in brain imaging of children in view of their short necks. The effect of this may be minimised by combining opposite projections.



**Figure A1:** Spatial resolution of a gamma camera as defined as the full width half maximum ( $R$ ) of the activity obtained from a line source. (Taken from Farr and Allisy-Roberts, 1997)

Spatial resolution may be quantified by determining the response of the camera to a line source of radioactivity, referred to as the line spread function. The *full width half maximum (FWHM)* is quoted (figure A1); that is the width in mm of the peak at which half the maximal counts are determined. The FWHM of the system used within this study was 10-15mm.

### ***Quality Control***

Many variables affect gamma camera performance in data acquisition. Such variables require regular checking and assessment to limit the effects of data related artifacts. Regular assessment should include that of nonuniformity, spatial resolution, energy resolution, spatial distortion, plane sensitivity, countrate performance and shield leakage. Regular measurements also include that of mechanical function (eg smooth rotation of the camera), electronic function, and determination of the centre of rotation through imaging of a point source.

### **ii) Reconstruction**

Reconstruction of images is achieved by filtered back projection. Back projection alone would result in blurred images. A filter applying weighting factors for different spatial frequencies is used within the matrix (a RAMP filter) to enhance the edge of images. Such a filter however will amplify statistical noise, particularly at higher frequencies. Further filtering is therefore required to minimise noise (a low pass filter eg Hanning, Butterworth), and therefore *smooth* the image. Certain filters, eg the Metz filter combine this function also with image enhancement or *sharpening*. These filters amplify an object spectrum over a selected range of frequencies to compensate for the attenuation caused by the collimator and detector during acquisition.

Attenuation and scatter of photons by tissues within the body result in an inaccurate representation of images following reconstruction within the area being studied if not corrected for. Scatter of photons in both the patient and the collimator can be corrected in a simplified fashion by use of a linear attenuation coefficient during the

attenuation correction (in this study  $0.12\text{cm}^{-1}$ ), therefore preventing overcorrection. Projections obtained directly opposite to each other also partly solve the attenuation problem, but a method of correction is still required. The majority of attenuation correction methods require the determination of a body outline. The Chang method of attenuation correction assumes the head outline to be that of an ellipse (Chang 1978). A uniform attenuation coefficient is assumed as indicated above. An attenuation correction factor is calculated for each pixel, and across a transverse slice each pixel is multiplied within the correction matrix. The correction factor is the average of the attenuation for that pixel along each projection. In children, the variation of cranium thickness may lead to error. Studies involving only the periphery of the brain have chosen not to use attenuation correction for this reason (Denays et al 1992).

The result of reconstruction is a series of transverse slices, the thickness of each slice determined by the size of the source as the number of slices produced is predetermined. These slices can be used to reconstruct the data as a series of images in transverse, coronal and sagittal planes, with a desired angle of slice. For the purpose of this study, the angles of orientation were parallel and perpendicular to the temporal lobe, as well as to the orbitomeatal line.

### **Quantitation of $^{99}\text{Tc}^{\text{m}}$ HMPAO SPECT images**

As described in Section 6.2, the HMPAO ligand can be used for assessment of regional cerebral blood flow (rCBF). It is a lipophilic compound, easily labelled with  $^{99}\text{Tc}^{\text{m}}$ , taken across the blood brain barrier, converted to a hydrophilic compound and retained long enough for suitable imaging (Nerinckx *et al.*, 1987, Sharp *et al.*, 1994). Normal volunteer (Costa *et al.*, 1986), animal (Costa *et al.*, 1987) and autoradiographic

studies (Bullock *et al.*, 1991, Duncan *et al.*, 1996) have demonstrated good correlation between HMPAO uptake and rCBF. However, it has been repeatedly shown that, although there appears to be a linear relationship between rCBF and HMPAO uptake at normal flow rates, the relationship becomes nonlinear at high flow rates (Lassen *et al.*, 1988, Duncan *et al.*, 1996). This is as a result of backdiffusion and washout of HMPAO. It is unlikely that this contributes any problem to visual assessment of images as data obtained from rats have suggested uptake does not decrease at high flow rates; uptake of HMPAO continues to increase as flow increases, but there is a greater spread of data (Duncan *et al.*, 1996). Lassen (Lassen *et al.*, 1988) has calculated a correction algorithm that adjusts for the nonlinearity at high flow rates. However, because of this problem together with the unknown kinetics between backdiffusion, first pass uptake and spontaneous conversion of the primary to secondary complex, absolute quantitation of rCBF using HMPAO is currently not possible in clinical practice.

The method of analysis used in this study was based on the semiquantitative colour scale provided with the Elscint software. This scale is based on total radioactivity count in each pixel relative to other pixels in each slice. Other methods of analysis that have been used have involved the mean counts of a predetermined region of interest (ROI) placed within an area compared to those in another ROI either within the same hemisphere (Costa *et al.*, 1988), the total counts of a whole slice ('normalisation', Rowe *et al.*, 1991) or the total counts of the whole brain (Bajc *et al.*, 1989). Problems arise with use of a direct comparison to another region within the brain as other areas are frequently undergo perfusion changes in epilepsy, as reported in this and other studies (Laich *et al.*, 1997, Harvey *et al.*, 1993)). In addition children

demonstrate regional variations in rCBF with age, particularly in a craniocaudal direction (Denays *et al.*, 1992). Comparison of a ROI to a total count of a brain slice will also be noncomparable, particularly in children, as slice thickness within our own system varied according to the size of the head. Finally, comparison to total brain counts will lead to an abnormality being underestimated to a greater extent as its size increases. Some groups have tried to get around this problem by use of asymmetry indices, a ratio of the difference in count rate between two matched regions either side of the midline to the mean of the number of counts between the two regions (Duncan *et al.*, 1993, Rowe *et al.*, 1991)

The decision was made in this study to use percent asymmetry based on the semiquantitative colour scale of predefined regions (see Section 6.4.4) as no further advantage could be gained by using ratios when comparing two scans from the same patient, or reviewing for outright asymmetry of perfusion. I did not have the benefit of normal controls and therefore was not able to define the exact scale of abnormality/normality for the system used, or for the age of children. In the current study, it was not possible to perform analysis other than direct side to side comparison of matched regions. Other studies have been able to determine the presence of multiple abnormalities to some degree, particularly those where there are normal controls. A way forward would be the use of a technique such as statistical parametric mapping (SPM) (Wellcome Department of Cognitive Neurology). This technique takes an individual scan, and by statistical analysis (repeated t tests) compares the scan with a normal template, acquired from a series of images from normal controls, and calculates the statistical probability that the scan in question differs from the normal template. Applying such a statistical technique to SPECT where many assumptions



are made in processing of data could be seen to be inappropriate, and therefore statistical nonparametric mapping (SnPM) may allow such comparisons in the future.

### **Review of scans in the current study**

All scans were initially reviewed by a Consultant in Nuclear Medicine who was aware of the clinical diagnosis (temporal, extratemporal or hemisindrome epilepsy) and whether the scan was ictal or interictal. A clinical report was then formulated. The scans were subsequently reprocessed and reported over a three week period at the end of the study by the PhD student, who was also aware of the clinical diagnosis and of whether the scans were ictal or interictal. Reports were compared for the 105 scans (64 interictal and 41 ictal/postictal) that had a complete data set and could be reviewed for abnormality alone. There was complete concordance in 84 scans (80%), with discordance in 21. Cohen's *Kappa* statistic was calculated at 0.64 implying good agreement (Bland, 1995). Where there was disagreement, scans were reviewed jointly and consensus opinion reached. Of the scans where there was not agreement, 13 scans were reported as no asymmetry by the second observer, but were reported as an area of abnormality by the first; four concordant with the seizure focus by the second and discordant by the first, and one concordant with the seizure focus by the second and no asymmetry by the first.

Ten scans, randomly selected, were also reprocessed and reviewed blind to the previous visual report after a further two year period to determine intraobserver variability of the second observer. The observer was aware of whether the scan was ictal or interictal, and whether the child was thought to have temporal or extratemporal epilepsy. All visual reports to these scans were identical to the reports

made two years previously. On semiquantitative analysis, Wilcoxon matched pair tests were performed on percent asymmetry of each of the regions discussed in section 6.4.4 . No significant difference was demonstrated between the means of the percent side to side asymmetry for any of the regions selected (see table A1)

Region	First analysis (mean % asymmetry +/- SD)	Second analysis (mean % asymmetry +/- SD)	p value
Cerebellum	0.7+/-5.1	-0.9+/-4.4	0.6
Frontocentral	19.02+/-30	16.7+/-33	0.2
Dorsolateral	8.5+/-21	10.5+/-19.8	0.3
Frontopolar	3.5+/-3	3.6+/-3.4	0.7
Orbitofrontal	-0.1+/-5.5	1.7+/-4.3	0.8
Medial frontal	1.0+/-3.4	0.9+/-4.1	0.4
Parietal	-1.5+/-6.1	0.35+/-5.9	0.3
Temporal			
Anterolat	4.5+/-8.3	3.02+/-9.8	0.4
Anteromed	4.9+/-6.7	2.7+/-7.5	0.2
Mid	6.1+/-7.2	6.4+/-5.4	0.7
Posterior	2.9+/-4.1	1.9+/-3.6	0.7
Basal ganglia	4.8+/-21.7	-1.04+/-4.3	0.8

**Table A1:** Mean percent asymmetry of preset regions as determined from first and second scan processing. No significant difference was found between the two groups for any region.

### **Qualification of the term 'ischaemia'**

Throughout this thesis the term 'ischaemia' refers to relative 'hypoperfusion', particularly at a time when one might expect hyperperfusion during seizures. The strict pathological definition refers to ischaemia as 'a reduction of blood flow below that critical for function of tissue'. Since the hypoperfusion is occurring in an area of probable high metabolic demand, the blood supply may not be adequate to meet demand. However it is recognised that SPECT cannot answer this question, but data from other investigations such as EEG within this current study may be suggestive of this during seizures in some children.

### **References**

- BAJC M, MEDVED V, BASIC M et al (1989) Cerebral perfusion inhomogeneities in schizophrenia demonstrated with single photon emission computed tomography and Tc99m hexamethylpropyleneoxime *Acta Psychiatr Scand* **80**, 427-33.
- BLAND M. (1995) *An Introduction to Medical Statistics* 2nd ed. Oxford University Press, Oxford.
- BULLOCK, R., PATTERSON, J., AND PARK, C. (1991) Evaluation of 99mTc-hexamethylpropyleneamine oxime cerebral blood flow mapping after acute focal ischemia in rats. *Stroke*, **22**, 1284-1290.
- CHANG LT. (1978) A method for attenuation correction in radionuclide computed tomography *IEEE Trans. Nucl. Sci* **NS-26**, 638-643
- COSTA DC, ELL PJ, CULLUM ID, JARRITT PH (1986) The in vivo distribution of 99Tcm-HMPAO in normal man. *Nucl.Med.Comm.*, **7**, 647-658.
- COSTA DC, JONES BE, STEINER TJ, ASPREY BS, ELL PJ, CULLUM ID, et al (1987) Relative <sup>99m</sup>Tc-HMPAO and <sup>113</sup>Sn-microspheres distribution in dog brain. *Nuklearmedizin.*, **suppl 23**, 489-500.

- COSTA DC, ELL PJ, BURNS A et al (1988) Tomograms with [<sup>99m</sup>Tc] HMPAO in patients with dementia (Alzheimer type and HIV) and Parkinsons disease - initial results. *J. Cereb. Blood Flow Metab.* **8** (suppl), s109-115
- DENAYS R, HAM H, TONDEUR M, PIEPSZ A, NOEL P (1992) Detection of bilateral and symmetrical anomalies in Technetium-99m-HMPAO brain SPECT studies. *J. Nucl. Med.*, **33**, 485-490.
- DUNCAN R, PATTERSON J, ROBERTS R, HADLEY DM, BONE I (1993) Ictal/postictal SPECT in the pre-surgical localisation of complex partial seizures. *J.Neurol.Neurosurg.Psychiatry*, **56**, 141-148.
- DUNCAN R, PATTERSON J, MACRAE M. (1996) HMPAO as a regional cerebral blood flow tracer at high flow levels *J Nucl Med* **37**, 661-664.
- FARR RF, ALLISY-ROBERTS PJ. (1997) *Physics for Medical Imaging*. WB Saunders Co Ltd, London.
- HARVEY AS, HOPKINS IJ, BOWE JM, COOK DJ, SHIELD LK, BERKOVIC SF (1993b) Frontal lobe epilepsy: clinical seizure characteristics and localization with ictal <sup>99m</sup>Tc-HMPAO SPECT. *Neurology*, **43**, 1966-1980.
- LASSON NA, ANDERSEN AR, FREIBERG L, PAULSON OB. (1988) The retention of <sup>99m</sup>Tc/DL-HMPAO in human brain after intracarotid bolus injection: a kinetic analysis. *J. Cereb. Blood Flow Metab.*,**8**, s13-s22.
- LAICH E, KUZNIECKY R, MOUNTZ J, LIU HG, GILLIAM F, BEBIN M, FAUGHT E, MORAWETZ R (1997) Supplementary sensorimotor area epilepsy. Seizure localization, cortical propagation and subcortical activation pathways using ictal SPECT. *Brain* **120**, 855-864.
- NEIRINCKX, R. D., CANNING, L. R., PIPER, I. M., NOWOTNIK, D. P., PICKETT, R. D., HOLMES, R. A., et al (1987) Technetium-99m d,l-HMPAO: a new radiopharmaceutical for SPECT imaging of regional cerebral blood perfusion. *J.Nucl.Med* **28**(2), 191-202..
- ROWE CC, BERKOVIC SF, AUSTIN MC, SALING M, KALNINS RM, MCKAY WJ, et al (1991) Visual and quantitative analysis of interictal SPECT with technetium- 99m-HMPAO in temporal lobe epilepsy. *J.Nucl.Med*, **32**, 1688-1694.
- SHARP PF, SMITH FW, GEMMELL HG, LYALL D, EVANS NTS, GVOZDANOVIC D, et al (1994) Technetium-99m HMPAO stereoisomers as potential agents for imaging regional cerebral blood flow: human volunteer studies. *J. Nucl. Med.*, **27**, 171-177.

# Proton Magnetic Resonance Spectroscopy in Children with Temporal Lobe Epilepsy

J. H. Cross, MBChB,\* A. Connelly, PhD,† G. D. Jackson, MD,\* C. L. Johnson,‡ B. G. R. Neville, MBBS,\* and D. G. Gadian, DPhil†

We performed proton magnetic resonance spectroscopy of the mesial temporal regions in 20 children with intractable temporal lobe epilepsy and compared results with those from 13 normal subjects. Abnormalities of the ratio of *N*-acetylaspartate to choline plus creatine (NAA/(Cho+Cr)) were seen in 15 patients (75%). The ratio NAA/(Cho+Cr) was correctly lateralizing in 55% and incorrectly lateralizing in none. Bilateral abnormalities were seen in 45%. Overall there was a unilateral decrease in *N*-acetylaspartate on the side ipsilateral to the seizure focus (mean 19% decrease vs normals, with 5% decrease on the contralateral side), suggesting neuronal loss or dysfunction. There was also a bilateral increase in creatine and choline (mean 18%), consistent with reactive astrocytosis. We conclude that proton magnetic resonance spectroscopy can contribute to lateralization of the seizure focus, and by detection of bilateral abnormalities, can contribute to the understanding of the underlying pathophysiology in temporal lobe epilepsy.

Cross JH, Connelly A, Jackson GD, Johnson CL, Neville BGR, Gadian DG. Proton magnetic resonance spectroscopy in children with temporal lobe epilepsy. *Ann Neurol* 1996;39:107-113

The significant mortality and high morbidity in intractable temporal lobe epilepsy of childhood are well documented [1] but remain poorly understood. Such morbidity may be reduced if children found to be suitable undergo early surgery. The presence of a structural brain abnormality associated with the seizure focus enhances the likelihood of a good postsurgical outcome [2]. In the younger age group, lateralization of the seizure focus is difficult, as clinical and electroencephalographic (EEG) data are often misleading [3-5]. Recent improvements in neuroradiological techniques have led to the increased preoperative detection of focal brain abnormality, particularly developmental and hippocampal abnormalities [6-8]. Magnetic resonance methods have been developed for quantitative analysis of the hippocampus. These include volumetric analysis of the hippocampal size [9-11], and quantitative T2 relaxation time measurements [12]. However, at present, imaging methodology to demonstrate more diffuse pathology is not well established. Mesial temporal sclerosis (MTS) accounts for a significant proportion of pathology responsible for intractable temporal lobe epilepsy of childhood [13, 14] but may be seen in the presence of extrahippocampal pathology [15]. Furthermore, neuropsychological data in children suggest that bilateral pathology is likely in a significant proportion, which is consistent with adult postmortem studies [16].

Proton magnetic resonance spectroscopy (<sup>1</sup>H MRS)

can be used for the noninvasive examination of brain metabolites *in vivo*. <sup>1</sup>H magnetic resonance (MR) spectra of the brain include major contributions from *N*-acetylaspartate (NAA), creatine and phosphocreatine (Cr), and choline-containing compounds (Cho). In animal and cell culture studies NAA was located primarily in neurons [17, 18], and any reduction in this compound therefore suggests neuronal loss or damage. Adult studies [19-23] showed that <sup>1</sup>H MRS may aid in lateralization of the seizure focus. However, our own work on adult epilepsy patients [19] and that of Ng and colleagues [23] demonstrated that there is also a high incidence of bilateral abnormality. In this report we present the results of <sup>1</sup>H MRS of the mesial temporal lobes in children with well-characterized temporal lobe epilepsy.

## Materials and Methods

### Patient Population

Twenty children (14 girls, 6 boys) with temporal lobe epilepsy and an age range of 5 to 17 years (mean, 11 years, 2 months) were investigated. The mean age at onset of epilepsy was 4 years, 1 month (range, 3 months-14 years). Seventeen children had a history of an event in early childhood—9 had a prolonged febrile convulsion; 6, status epilepticus; 1, a simple febrile convulsion; and 1 had encephalitis. Three children had no history of such an event.

In each child the seizures were lateralized and localized on

From the \*Neurosciences Unit and †Radiology and Physics Unit, Institute of Child Health, and ‡Great Ormond Street Hospital for Children NHS Trust, London, United Kingdom.

Received Apr 19, 1995, and in revised form Jul 24 and Sep 19. Accepted for publication Sep 20, 1995.

Address correspondence to Dr Cross, Institute of Child Health, The Wolfson Centre, Mecklenburgh Square, London WC1N 2AP, United Kingdom.

Table 1. Clinical, Electroencephalographic (EEG), and Magnetic Resonance Imaging (MRI) Data on the 20 Children with Temporal Lobe Epilepsy (TLE), with Results of Surgery Where Applicable

Patient No.	Age	Clinical	Interictal EEG	Ictal EEG	MRI	<sup>1</sup> H MRS NAA/(Cho+Cr)		Pathology (if Surgery)	Duration of Surgical Follow-up (Mo)	Outcome
						Ipsilateral	Contralateral			
1	17 yr 9 mo	L TLE	Bitemporal	L anterior temporal	L HS	0.62	0.89	Ammon's horn sclerosis	18	Seizure free
2	11 yr 8 mo	L TLE	Bilateral	L temporal	L HS + gliosis	0.60	0.77	Ammon's horn sclerosis	32	Seizure free
3	13 yr	L TLE	L temporal	N/A	L HS	0.73	0.80			
4	14 yr 4 mo	L TLE	No abnormality	L temporal	L HS	0.48	0.63	Ammon's horn sclerosis	18	Seizure free
5	11 yr 9 mo	L TLE	No abnormality	N/A	L HS	0.77	0.92			
6	13 yr 4 mo	L TLE	L temporal	L temporal	L HS	0.82	0.72	Ammon's horn sclerosis	2	Seizure free
7	9 yr 8 mo	L TLE	L midtemporal	L temporal	L HS	0.59	0.65	Ammon's horn sclerosis	24	Daily seizures, awaiting left amygdectomy
8	10 yr	TLE	Bitemporal	L temporal	Normal	0.84	0.92	End-plate gliosis	3	Seizure free
9	9 yr 10 mo	L TLE	L centrotemporal	L centrotemporal	L HS	0.47	0.76			
10	8 yr 10 mo	L TLE	L frontotemporal	L temporal	L HA	0.48	0.92	Rasmussen's encephalitis	28	Weekly seizures, >75% improved
11	9 yr	TLE	L temporal	N/A	L HS	0.71	0.68			
12	10 yr 7 mo	L TLE	Bitemporal	L anterior temporal	L HS	0.56	0.66	Ammon's horn sclerosis	8	Seizure free
13	10 yr	R TLE	R temporal	N/A	R HS	0.66	0.85	Ammon's horn sclerosis	40	Seizure free
14	9 yr 3 mo	R TLE	No abnormality	N/A	R HS	0.48	0.49			
15	5 yr 8 mo	TLE	R posterior temporal	R temporal	Normal	0.54	0.68			
16	8 yr	R TLE	Bilateral	N/A	R HS	0.62	0.77			
17	16 yr	TLE	R temporal	N/A	Normal	0.82	0.86			
18	5 yr	R TLE	R temporal	R temporal	R TLA	0.44	0.52			
19	14 yr	R TLE	No abnormality	R centrotemporal	R HS	0.64	0.69	Ammon's horn sclerosis	2	Seizure free
20	16 yr 11 mo	TLE	R temporal	N/A	R HS	0.62	0.59			

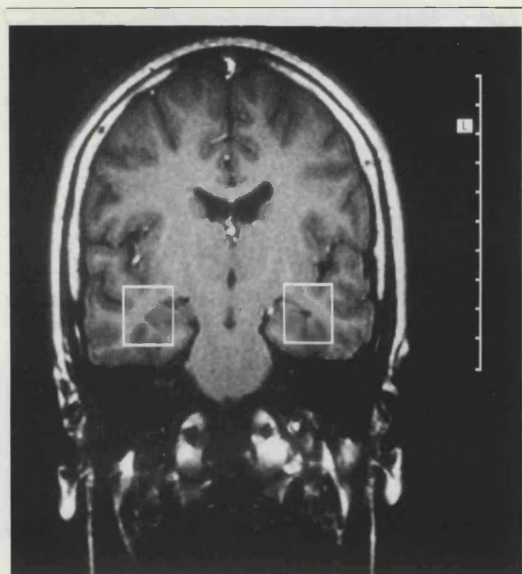
L = left; R = right; HS = hippocampal sclerosis, HA = hippocampal atrophy; N/A = not available; <sup>1</sup>H MRS = proton magnetic resonance spectroscopy; NAA = *N*-acetylaspartate; Cho = choline; Cr = creatine; TLA = temporal lobe atrophy.

the basis of clinical history and interictal and/or ictal EEG (Table 1). Clinical localization to the temporal lobe was accepted if there was any one of the following: orolimentary automatisms, stereotyped complex automatisms with postictal confusion, psychic aura such as fear or déjà vu, an aura of a formed auditory hallucination, a distinct epigastric aura, speech impairment prior to or immediately following the seizure, or nonspecific aura or automatisms followed by confusion postictally. Lateralization was based on lateralized motor phenomena or speech disturbance prior to or immediately following the seizure. On this basis, 12 children were found to have a left temporal focus and 8, a right temporal focus. Ten children have undergone temporal lobectomy and a further 2 are awaiting surgery. The decision about surgery was based on information from clinical, EEG, and MR data as well as interictal and ictal technetium 99m (<sup>99m</sup>Tc<sup>m</sup>) single-photon emission computed tomography. Two children are to undergo further preoperative evaluation.

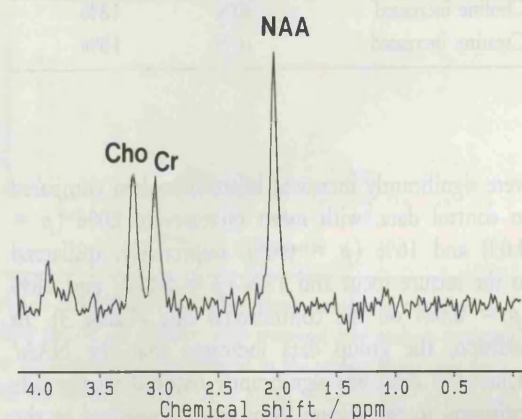
#### Magnetic Resonance Spectroscopy

Magnetic resonance spectroscopy (MRS) was carried out using a 1.5-T Siemens whole-body system with a standard quadrature head coil. Where necessary, the children were sedated

or underwent a general anesthetic. In the majority of patients, images were obtained using an inversion-recovery sequence (TR 3500/TI 300/TE 26) in oblique axial and coronal orientations, parallel and perpendicular to the long axis of the hippocampus. In the remaining children, the oblique axial images were not acquired but were instead reconstructed from a three-dimensional (3D) magnetization-prepared-rapid-acquisition-gradient-echo (MP-RAGE) data set (TR 10/TI 200/TE 4/flip angle 12 degrees). In all children, T2 images were also acquired in the coronal plane (TR 4600/TE 90). Spectra were obtained from 2 × 2 × 2-cm cubes centered on the medial portions of the right and left temporal lobes, as shown in Figure 1A. Spatial localization was achieved using a 90-180-180-degree spin-echo technique, with three selective radiofrequency pulses applied in the presence of orthogonal gradients of 2mT/m. Water suppression was achieved by preirradiation of the water resonance using a 90-degree gaussian pulse with a 60-Hz bandwidth, followed by a spoiler gradient (TR 1600/TE 135). After global and local shimming, and optimization of the water suppression pulse, data were collected in two to four blocks of 128 scans. The time domain data were corrected for eddy current-induced phase modulation using non-



A



B

Fig 1. Coronal magnetic resonance image (A) and a  $^1\text{H}$  spectrum (B) from a normal subject. The boxes indicate the position of the 8-ml cubic volume of interest from which spectra were obtained. The dominant contributions to the spectrum are from N-acetylaspartate (NAA), creatine plus phosphocreatine (Cr), and choline-containing compounds (Cho). The NAA/(Cho+Cr) ratio was 0.91.

water-suppressed data as a reference [24]. Exponential multiplication corresponding to 1-Hz line broadening was carried out prior to Fourier transformation, and a cubic spline baseline correction was performed.

Signal intensities at 2.0 ppm (primarily NAA), 3.0 ppm (Cr), and 3.2 ppm (Cho) were measured from the peak areas by integration. The effects of T1 and T2 relaxation were not determined, and therefore it was not possible to convert these intensities to concentration measurements. However, by multiplying the observed signal intensities by the 90-degree pulse voltage, it was possible to compensate for differences in radiofrequency coil loading [25, 26] and thereby to compare absolute signal intensities between different subjects. Data are presented in the form of these corrected signal intensities, and also in terms of the intensity ratio NAA/(Cho+Cr). The intensity ratio is dimensionless by definition, while the

absolute intensities are given in arbitrary units that reflect the settings of the MR system used.

#### Data Analysis

The intensity ratio NAA/(Cho+Cr) was used as a simple index of spectral abnormality. Choice of this particular ratio is based partly on the observation (see Results) that the group data show a significant mean decrease in NAA and increases in the Cr and Cho signals. In addition, in the temporal lobe it is sometimes difficult to achieve full spectral separation of the Cr and Cho signals due to particular problems with magnetic field inhomogeneity in this region. The NAA/(Cho+Cr) ratio is unaffected by this latter problem.

Multiple Student's *t* tests (two tailed) were used for comparisons between patients and normal subjects, and between ipsilateral and contralateral data. The 95% reference range for the NAA/(Cho+Cr) ratio was determined using log-transformed data from 13 normal subjects (age range, 19–42 years; mean, 30 years) as previously reported [19]. For determination of the reference range, we used one data point for each control subject, calculated as the mean of the ratios obtained from the two temporal lobes. This avoided the assumption that the temporal lobes in each control subject provided independent data. The lowest value of NAA/(Cho+Cr) seen in any of the control subjects was 0.72 and this was also the lower limit of the 95% reference range derived from the control data. Values below 0.72 were therefore considered to be abnormally low.

Studies in occipital white matter and basal ganglia have shown NAA/Cho and NAA/Cr ratios to increase with age, while the Cho/Cr ratio decreases, primarily as a result of an increase in NAA and decrease in Cho. Most of the changes seen occur during the first 3 years [27]. Obtaining control data from normal children poses difficulties, particularly in view of the likely need for sedation or general anesthetic. However, we have spectra from the mesial temporal lobes of one normal 8-year-old girl whose values for NAA/(Cho+Cr) are 0.74 and 0.87, and children 5 years old with conditions including epilepsy have been demonstrated to have NAA/(Cho+Cr) ratios from the mesial temporal lobes within the adult range. Therefore, we consider our previously published control data to be applicable to this study.

We considered the NAA/(Cho+Cr) ratio to be lateralizing only if it was (1) abnormally low and (2) lower than that on the contralateral side by more than 0.05. Although this latter value is somewhat arbitrary, used on an adult group of patients it was believed that these two criteria provided a reasonable basis for assessing abnormalities and for lateralization [19].

## Results

### Magnetic Resonance Imaging

Seventeen children had an abnormality on MRI concordant with the clinical seizure focus; in 15, changes seen were consistent with unilateral hippocampal sclerosis (as previously described [6]). In 1 there was unilateral hippocampal atrophy and in 1 the temporal lobe atrophy. In the remaining 3 children no abnormality was seen on MRI. For the

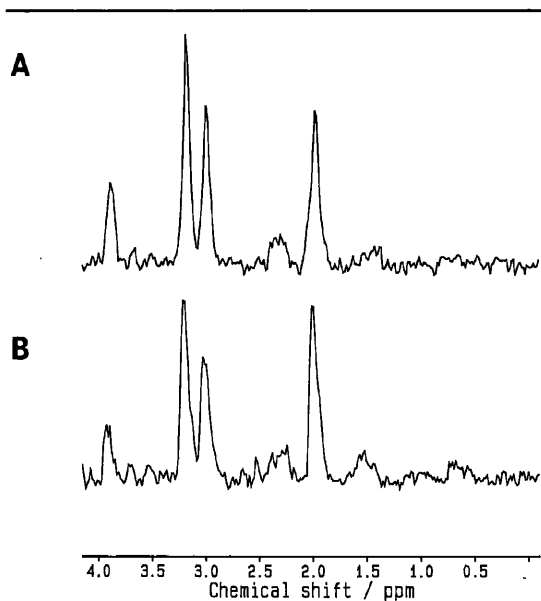


Fig 2.  $^1\text{H}$  spectra from a 5-year-old girl with a clinical right temporal lobe focus. The NAA/(Cho+Cr) ratio on the right (A) was 0.44 and the left, 0.52 (B).

purpose of this study, children with foreign tissue lesions of the mesial temporal region, recognized on MRI, were excluded.

#### Magnetic Resonance Spectroscopy

$^1\text{H}$  spectra were obtained from 40 temporal lobes of 20 study patients and the results were compared with those obtained from 26 temporal lobes from 13 normal adults previously reported [21]. Figure 1B shows a  $^1\text{H}$  spectrum from a  $2 \times 2 \times 2$ -cm cubic region centered on the mesial temporal lobe of a normal control subject. The signal at 2.0 ppm is from *N*-acetyl-containing compounds, the dominant contributions being from NAA. The signal at 3.0 ppm is from Cr, while the signal at 3.2 ppm is from Cho, including phosphocholine and glycerophosphocholine. The NAA/(Cho+Cr) ratio was 0.91. Figure 2 shows the  $^1\text{H}$  spectra from the right and left temporal lobes of a 5-year-old girl with the clinical indication of a right temporal focus. The NAA/(Cho+Cr) ratio on the right was 0.44 and on the left, 0.52.

Mean values for the NAA, Cho, and Cr signal intensities were obtained from the control data as well as a mean value for NAA/(Cho+Cr) (Table 2).

The absolute signal intensity data from the patient studies (see Materials and Methods) indicated that NAA was significantly reduced on the ipsilateral side compared to both the contralateral side ( $p = 0.02$ ) and normal intensities ( $p = 0.001$ ). Overall there was a mean decrease of 19% on the ipsilateral side and a mean decrease of 5% on the contralateral side ( $p = 0.31$ ) when compared to the normal data. Cho and Cr

Table 2. Mean Signal Intensities for 13 Control Subjects and 20 Patients\*

	Control	Ipsilateral	Contralateral
<i>N</i> -acetylaspartate (NAA)	18.4 (2.6)	14.6 (3.8)	17.3 (3.2)
Choline (Cho)	10.6 (1.6)	12.8 (3.7)	12.6 (2.1)
Creatine (Cr)	9.7 (1.7)	11.1 (3.1)	10.9 (2.5)
NAA/(Cho+Cr)	0.92 (0.16)	0.62 (0.12)	0.74 (0.14)

\*The numbers in parentheses refer to the standard deviation. Patient data are grouped with respect to the clinical/EEG seizure focus.

Table 3. Relative Mean Percentage Change in Absolute Intensity Data

	Ipsilateral vs Control	Contralateral vs Control
<i>N</i> -acetylaspartate decreased	19%	5%
Choline increased	20%	18%
Creatine increased	16%	18%

were significantly increased bilaterally when compared to control data, with mean increases of 20% ( $p = 0.03$ ) and 16% ( $p = 0.05$ ), respectively, ipsilateral to the seizure focus and 18% ( $p = 0.002$ ) and 18% ( $p = 0.04$ ) on the contralateral side (Table 3). In addition, the group data indicated that the NAA/(Cho+Cr) ratio was significantly reduced on the side ipsilateral to the seizure focus when compared to the contralateral side, but both sides were significantly reduced when compared to control data (Fig 3).

The NAA/(Cho+Cr) data from individual patients were also analyzed with respect to the normal data, in particular to determine the contribution of such data to lateralization of the seizure focus (Fig 4, Table 4). Abnormalities of NAA/(Cho+Cr) ratios were seen in 15 of the children in this study; bilateral abnormalities were seen in 9 and unilateral abnormalities in 6. Based on the criteria described in the methods section, the NAA/(Cho+Cr) ratio was lateralizing in 11 children; this was ipsilateral to the clinical seizure focus in all cases. In 1, the MRI appeared normal. Of the remaining 9 children, the NAA/(Cho+Cr) ratio was bilaterally normal in 5. Three of these children showed unilateral hippocampal sclerosis and 2 children had a normal-appearing MRI. Four children had bilaterally abnormal values for NAA/(Cho+Cr) but with less than 0.05 difference between the two sides. All 4 of these children showed unilateral abnormality on MRIs.

#### Discussion

In this study of 20 children with temporal lobe epilepsy, abnormalities were seen in the absolute intensi-



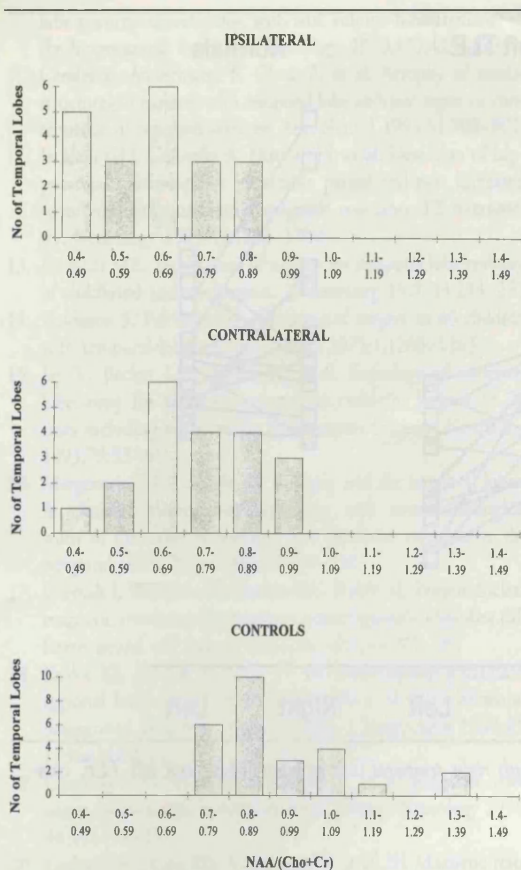


Fig 3. NAA/(Cho+Cr) ratios versus number of temporal lobes for the 20 children with temporal lobe epilepsy (grouped as ipsilateral and contralateral to the seizure focus) and for the 13 normal subjects. As a group, NAA/(Cho+Cr) ratios of the children with temporal lobe epilepsy were significantly reduced bilaterally when compared to those in control subjects (ipsilateral vs control,  $p < 0.0001$ ; contralateral vs control,  $p = 0.0001$ ) and there was also a significant difference between the two sides (ipsilateral vs contralateral,  $p = 0.007$ ).

ties of the NAA, Cho, and Cr signals, as well as the signal intensity ratio NAA/(Cho+Cr).

There was a 19% reduction in the NAA signal intensity ipsilateral to the seizure focus compared to normal data, with a 5% reduction on the contralateral side. Animal and cell culture studies suggested that NAA resides predominantly in neurons [18, 28]. Therefore our results suggest neuronal loss or dysfunction, particularly on the ipsilateral side.

As detailed in the methods section, we chose to use the NAA/(Cho+Cr) ratio as a simple index of spectral abnormality and of lateralization. This ratio showed abnormalities in 15 (75%) of the 20 children with temporal lobe epilepsy, with bilateral abnormalities in almost half (9/20, 45%). Correct lateralization of the seizure focus was achieved in 55% of the children, with incorrect lateralization in none. This is in a series of children at the severe end of the spectrum, 11 of whom

have undergone or are awaiting surgery and only 2 of whom were later controlled with medication.

Bilateral abnormalities were shown in 45% of children in this study. This is a similar percentage to that found in adult studies (40% [19], 42% [23]), and emphasizes the early presence of such abnormalities. As a group a significant increase was seen in both Cho and Cr bilaterally. The concentrations of Cr and of Cho are higher in astrocyte and oligodendrocyte cell preparations than in cerebellar granule neurons [17]. It is therefore possible that any increase in Cho and Cr may reflect reactive astrocytosis.

Bilateral pathology (predominantly bilateral MTS) has been observed postmortem in up to 50% of adults with temporal lobe epilepsy [16]. The relationship of contralateral pathology to postoperative outcome is not clear. However, a group of 34 adults who had undergone temporal resection demonstrated an incidence of abnormality on  $^1\text{H}$  MRS on the unoperated side (50%) [29] similar to that of bilateral pathology shown in adult  $^1\text{H}$  MRS studies performed preoperatively (45%) [19, 23]. In the postoperative study [29] no relationship was seen between the abnormalities on the unoperated side and seizure outcome, although there was a relationship to cognitive outcome. The high rate of bilateral abnormalities and the good seizure outcome in many such patients following surgery suggest that spectral abnormalities occur frequently in nonepileptogenic mesial temporal structures. This emphasizes the importance of obtaining some form of functional ictal information by means of techniques such as EEG and single-photon emission computed tomography.

Visual analysis of MRIs in this group of children revealed unilateral hippocampal sclerosis in 15 (75%) of the 20 children. This is a higher incidence than that reported from pediatric temporal lobectomy series [30, 31]. However, MRI can detect hippocampal sclerosis preoperatively in adults [7], and other MRI studies of children with intractable temporal lobe epilepsy suggested an incidence as high as 60% [32, 33].

$^1\text{H}$  MRS is complementary to MRI in lateralizing brain abnormalities. One child in this study with  $^1\text{H}$  MRS lateralization had a normal MRI, whereas 3 children with unilateral imaging abnormalities had bilaterally normal  $^1\text{H}$  MRS. The hippocampus occupies only a small proportion of the 8-ml region of interest used in this study, which includes a substantial proportion of neocortex.  $^1\text{H}$  MRS is therefore providing evidence of more diffuse abnormalities that extend beyond the focal lesions demonstrated by MRI. The presence of extrahippocampal pathology in addition to MTS in temporal lobe epilepsy is well recognized, occurring in 31 to 70% of resected specimens [34-37]. A recent study suggested that this "dual pathology" may predominate over isolated MTS in children [15]. Our study demonstrated that diffuse temporal lobe abnor-

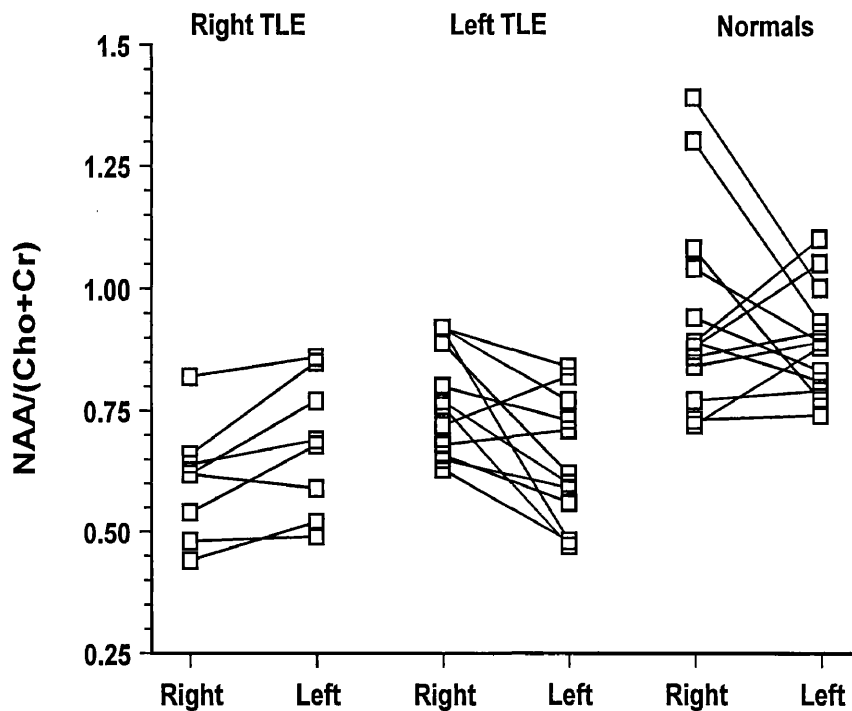


Fig 4. Individual right and left NAA/(Cho+Cr) ratios in children with right temporal lobe epilepsy (TLE) and left TLE, compared to normal subjects.

Table 4. Lateralization of the Seizure Focus by Proton Magnetic Resonance Spectroscopy

NAA/(Cho+Cr)	N	Correctly Lateralizing	Incorrectly Lateralizing	Not Lateralizing
Unilaterally low	6	6	0	0
Bilaterally low	9	5	0	4
Bilaterally normal	5	0	0	5

malities are common in temporal lobe epilepsy and occur with similar frequency to that in adults. The significance of this diffuse pathology and its relationship to postoperative outcome remains uncertain. However, outcome after surgery is improved if pathology is found in the resected specimen [2, 38], and MR can provide information about the presence of abnormality that may not be available from visual inspection. Further information about the distribution and extent of these abnormalities should be available using MRSI techniques [21–23].

In conclusion, this study showed a high rate of abnormality of the mesial temporal lobes in children with intractable temporal lobe epilepsy using  $^1\text{H}$  MRS. We showed that  $^1\text{H}$  MRS contributes to the lateralization of the seizure focus, and to the detection of bilateral abnormalities. This technique therefore contributes to our understanding of the underlying pathophysiology in temporal lobe epilepsy of childhood.

We thank Action Research and the Wellcome Trust for their support, and Dr B. Harding for advice on the pathology.

#### References

1. Ounsted C, Lindsay J, Richards P. Temporal lobe epilepsy: a biographical study. Oxford: Mac Keith Press, 1987
2. Fish DR, Smith SJ, Quesney LF, et al. Surgical treatment of children with medically intractable frontal or temporal lobe epilepsy: results and highlights of 40 years' experience. *Epilepsia* 1993;34:244–247
3. Duchowny M. The syndrome of partial seizures in infancy. *J Child Neurol* 1992;7:66–69
4. Holmes GL. Partial complex seizures in children: an analysis of 69 seizures in 24 patients using EEG FM radiotelemetry and videotape recording. *Electroencephalogr Clin Neurophysiol* 1984;57:13–20
5. Yamamoto N, Watanabe K, Negoro T, et al. Complex partial seizures in children: ictal manifestations and their relation to clinical course. *Neurology* 1987;37:1379–1382
6. Cross JH, Jackson GD, Neville BGR, et al. Early detection of abnormalities in partial epilepsy using magnetic resonance. *Arch Dis Child* 1993;69:104–109
7. Jackson GD, Berkovic SF, Tress BM, et al. Hippocampal sclerosis can be reliably detected by magnetic resonance imaging. *Neurology* 1990;40:1869–1875
8. Jackson GD, Berkovic SF, Duncan JS, Connelly A. Optimizing the diagnosis of hippocampal sclerosis using MR imaging. *AJNR* 1993;14:753–762
9. Cook MJ, Fish DR, Shorvon SD, et al. Hippocampal volumetric and morphometric studies in frontal and temporal lobe epilepsy. *Brain* 1992;115:1001–1015
10. Jack CR Jr, Sharbrough FW, Twomey CK, et al. Temporal

- lobe seizures: lateralization with MR volume measurements of the hippocampal formation. *Radiology* 1990;175:423-429
11. Cendes F, Andermann F, Gloor P, et al. Atrophy of mesial structures in patients with temporal lobe epilepsy: cause or consequence of repeated seizures? *Ann Neurol* 1993;34:795-801
  12. Jackson GD, Connelly A, Duncan JS, et al. Detection of hippocampal pathology in intractable partial epilepsy: increased sensitivity with quantitative magnetic resonance T2 relaxometry. *Neurology* 1993;43:1793-1799
  13. Falconer MA. Significance of surgery for temporal lobe epilepsy in childhood and adolescence. *J Neurosurg* 1970;33:233-252
  14. Davidson S, Falconer MA. Outcome of surgery in 40 children with temporal-lobe epilepsy. *Lancet* 1975;1:1260-1263
  15. Jay V, Becker LE, Otsubo H, et al. Pathology of temporal lobectomy for refractory seizures in children. Review of 20 cases including some unique malformative lesions. *J Neurosurg* 1993;79:53-61
  16. Margerison JH, Corsellis JA. Epilepsy and the temporal lobes. A clinical, electroencephalographic and neuropathological study of the brain in epilepsy, with particular reference to the temporal lobes. *Brain* 1966;89:499-530
  17. Urenjak J, Williams SR, Gadian DG, Noble M. Proton nuclear magnetic resonance spectroscopy unambiguously identifies different neural cell types. *J Neurosci* 1993;13:981-989
  18. Koller KJ, Zaczek R, Coyle JT. *N*-Acetyl-aspartyl-glutamate: regional levels in rat brain and the effects of brain lesions as determined by a new HPLC method. *J Neurochem* 1984;43:1136-1142
  19. Connelly A, Jackson GD, Duncan JS, et al. Magnetic resonance spectroscopy in temporal lobe epilepsy. *Neurology* 1994;44:1411-1417
  20. Gadian DG, Connelly A, Duncan JS, et al. <sup>1</sup>H Magnetic resonance spectroscopy in the investigation of intractable epilepsy. *Acta Neurol Scand Suppl* 1994;152:116-121
  21. Hugg JW, Laxer KD, Matson GB, et al. Neuron loss localizes human temporal lobe epilepsy by in vivo proton magnetic resonance spectroscopic imaging. *Ann Neurol* 1993;34:788-794
  22. Cendes F, Andermann F, Preul MC, Arnold DL. Lateralization of temporal lobe epilepsy based on regional metabolic abnormalities in proton magnetic resonance spectroscopic images. *Ann Neurol* 1994;35:211-216
  23. Ng TC, Comair YG, Xue M, et al. Temporal lobe epilepsy: presurgical localisation with proton chemical shift imaging. *Radiology* 1994;193:465-472
  24. Klose U. In vivo proton spectroscopy in presence of eddy currents. *Magn Reson Med* 1990;14:26-30
  25. Hoult DI, Richards RE. The signal-to-noise ratio of the nuclear magnetic resonance experiment. *J Magn Reson* 1976;24:71-85
  26. Austin SJ, Connelly A, Gadian DG, et al. Localized <sup>1</sup>H MR spectroscopy in Canavan's disease: a report of two cases. *Magn Reson Med* 1991;19:439-445
  27. van der Knaap MS, van der Grond J, van Rijen PC, et al. Age-dependent changes in localized proton and phosphorus MR spectroscopy of the brain. *Radiology* 1990;176:509-515
  28. Urenjak J, Williams SR, Gadian DG, Noble M. Specific expression of *N*-acetylaspartate in neurons, oligodendrocyte type-2 astrocyte progenitors and immature oligodendrocytes in vitro. *J Neurochem* 1992;59:55-61
  29. Incisa della Rochetta A, Gadian DG, Connelly A, et al. Verbal memory impairment after right temporal lobe surgery: the role of contralateral damage as revealed by <sup>1</sup>H magnetic resonance spectroscopy and T<sub>2</sub> relaxometry. *Neurology* 1995;45:797-802
  30. Hopkins IJ, Klug GL. Temporal lobectomy for the treatment of intractable complex partial seizures of temporal lobe origin in early childhood. *Dev Med Child Neurol* 1991;33:26-31
  31. Duchowny M, Levin B, Jayakar P, et al. Temporal lobectomy in early childhood. *Epilepsia* 1992;33:298-303
  32. Grattan-Smith ID, Harvey AS, Desmond PM, Chow CW. Hippocampal sclerosis in children with intractable epilepsy: detection with MR imaging. *AJR* 1993;161:1045-1048
  33. Harvey AS, Grattan-Smith ID, Desmond PM, et al. Febrile seizures and hippocampal sclerosis: frequent and related findings in intractable temporal lobe epilepsy of childhood. *Pediatr Neurol* 1995;12:201-206
  34. Levesque MF, Nakasato N, Vinters HV, Babb TL. Surgical treatment of limbic epilepsy associated with extrahippocampal lesions: the problem of dual pathology. *J Neurosurg* 1991;75:364-370
  35. Falconer MA. Mesial temporal (Ammon's horn) sclerosis as a common cause of epilepsy. Aetiology, treatment, and prevention. *Lancet* 1974;2:767-770
  36. Bruton CJ. The neuropathology of temporal lobe epilepsy. Oxford: Oxford University Press, 1988;1-158
  37. Mathieson G. Pathology of temporal lobe foci. *Adv Neurol* 1975;11:163-185
  38. Cascino GD, Jack CR Jr, Parisi JE, et al. MRI in the presurgical evaluation of patients with frontal lobe epilepsy and children with temporal lobe epilepsy: pathologic correlation and prognostic importance. *Epilepsy Res* 1992;11:51-59

# LORAZEPAM VERSUS DIAZEPAM IN THE ACUTE TREATMENT OF EPILEPTIC SEIZURES AND STATUS EPILEPTICUS

Richard Appleton  
Anne Sweeney  
Imti Choonara  
Joan Robson  
Elizabeth Molyneux

Convulsive status epilepticus (SE) is a potentially life-threatening medical emergency (Aicardi and Chevrie 1983). The mortality and morbidity of SE are related to its duration, and therefore early control is important (Delgado-Escueta and Bajorek 1982). A rapid and sustained control of status may obviate the need for multiple anti-epileptic drug (AED) administrations and prolonged hospitalisation. Finally, rapid control of an initial seizure may prevent the development of SE. The ideal drug for treating acute seizures (including SE) should act rapidly, have a sustained duration of action and be safe (Shorvon 1993). None of the AEDs that are commonly used in treating SE completely fulfils these criteria. Diazepam is generally considered to be the drug of first choice in status epilepticus (Delgado-Escueta *et al.* 1982), but although it is initially effective and relatively safe (Nicol *et al.* 1969), it has an effective half-life of only two to four hours (Mattson 1972). Repeated injections or continuous infusions are therefore often required for sustained control of seizures, with an increased risk of respiratory depression (necessitating endotracheal intubation) (Chiulli *et al.* 1991) and hypotension. Clonazepam may be superior to diazepam (Congdon and Forsythe 1980), but can cause excessive salivary and bronchial secretions,

increasing the risk of respiratory complications. Phenobarbitone is often effective in controlling seizures only at doses that depress consciousness or respiration (Crawford *et al.* 1988). Phenytoin has a slow onset of action and may cause hypotension and cardiac dysrhythmias (Wallis *et al.* 1968). Paraldehyde has a relatively short duration of action, may produce pulmonary oedema and, because of its recommended rectal route of administration, may be expelled before absorption (Woodbury and Fingl 1975).

Lorazepam is a newer benzodiazepine which is an effective anticonvulsant in animals (Gluckman and Stein 1978, Homan and Walker 1983), causes little respiratory depression (Walker *et al.* 1979, Leppik *et al.* 1983, Gilmore *et al.* 1984, Lacey *et al.* 1986, Crawford *et al.* 1987) and has an elimination half-life of approximately 13 hours (Greenblatt *et al.* 1977). A number of studies have suggested that lorazepam has a longer duration of anti-epileptic activity than diazepam (Waltregny and Dargent 1975, Walker *et al.* 1979, Griffith and Karp 1980, Leppik *et al.* 1983, Levy and Krall 1984) and that a single dose is usually sufficient to control SE, thereby reducing the risk of respiratory arrest associated with repeated doses. However, these studies have either been retrospective or have been based on anecdotal evidence,

# CHILDREN WITH INTRACTABLE FOCAL EPILEPSY: ICTAL AND INTERICTAL <sup>99</sup>Tc<sup>M</sup> HMPAO SINGLE PHOTON EMISSION COMPUTED TOMOGRAPHY

J. Helen Cross  
Isky Gordon  
Graeme D. Jackson  
Stewart G. Boyd  
Andrew Todd-Pokropek  
Peter J. Anderson  
Brian G. R. Neville

Surgery may be considered early in childhood in the management of intractable partial seizures if an epileptic focus can be identified. Reliable non-invasive methods of seizure localisation are particularly important in the assessment of the suitability of young children for surgery, as clinical and electrophysiological data alone may be misleading or uninformative with respect to localising the seizure onset (Holmes 1984, Yamamoto *et al.* 1987, Jayakar and Duchowny 1990, Duchowny 1992, Wyllie *et al.* 1993). Optimised magnetic resonance imaging (MRI) yields a high rate of lesions in children with intractable complex partial seizures (Cross *et al.* 1993), but these abnormalities cannot automatically be assumed to relate to the seizure origin. The development of non-invasive functional imaging techniques using technetium-99M hexamethyl propylamine oxime single photon emission computed tomography (<sup>99</sup>Tc<sup>M</sup> HMPAO SPECT) offers information about the location and extent of abnormal regional cerebral blood flow (rCBF). Using both ictal and interictal studies, such imaging may provide data about both the seizure origin and its relationship to structurally abnormal regions of the brain (Rowe *et al.* 1991a,b; Newton *et al.* 1992a,b; Berkovic *et al.* 1993, Duncan *et al.* 1993).

In adult studies, ictal injection of <sup>99</sup>Tc<sup>M</sup> HMPAO in patients with temporal lobe

epilepsy demonstrates focal hyperperfusion which appears to localise the seizure focus better than interictal hypoperfusion (Newton *et al.* 1992a, Berkovic *et al.* 1993). Similar patterns of interictal and ictal cerebral blood flow have been demonstrated in children with temporal lobe epilepsy (Harvey *et al.* 1993a). The use of ictal and interictal SPECT in children to help localisation of a seizure focus is attractive in view of the relatively non-invasive nature of the investigation (Harvey *et al.* 1992, 1993a,b). The aim of the current study was to determine whether ictal studies could be routinely acquired in the pre-operative investigation of children with intractable epilepsy and also whether patterns of rCBF that have been described in adult studies could be recognised in our paediatric population.

### Method

#### PATIENTS

We investigated 14 children (eight girls and six boys; Table I) with intractable complex partial seizures, using ictal and interictal <sup>99</sup>Tc<sup>M</sup> HMPAO examinations as part of the evaluation of their suitability for surgical treatment. Their mean age was 10 years 6 months (range 3 yrs 11 mths to 17 yrs 10 mths). We defined intractable epilepsy as seizures of at least two years duration that had failed to respond to at least three anticonvulsant drugs at ade-

Developmental Medicine and Child Neurology, 1995, 37, 673-681

TABLE I

## Clinical details and results of investigations in 14 children with intractable complex partial seizures

Patient	Age (yrs:mths)	Age of onset (yrs:mths)	Clinical focus	EEG		MRI	Interictal SPECT	Ictal SPECT
				Interictal	Ictal			
1	12:0	1:1	L temporal	Bilateral temporal L>R	L temporal	L hippocampal sclerosis	Hypoperfusion L temporal lobe	Hyperperfusion L temporal lobe
2	7:10	6:10	L temporal	L temporal slow	L mid-temporal onset	Small L hippocampus, no signal change	Hypoperfusion L temporal lobe	Hyperperfusion L temporal lobe
3	12:6	4:0	L temporal	L temporal discharges + slow anteriorly	L temporal	L temporal dysembryoplastic neuroepithelial tumour	Hypoperfusion L temporal lobe	Hyperperfusion L temporal lobe
4	4:9	0:3	R temporal	Normal	Bilateral temporal	R temporal dysembryoplastic neuroepithelial tumour	Hypoperfusion R temporal lobe	Hyperperfusion R temporal lobe
5	8:5	0:3	L temporal	L temporal	L temporal	L hippocampal sclerosis	Hypoperfusion L temporal lobe	Hyperperfusion L temporal lobe
6	10:3	5:0	L temporal	Bitemporal discharges	L temporal	Normal	Localised hypoperfusion L temporal lobe	Hyperperfusion L temporal lobe
7	17:10	0:10	L temporal	Bitemporal slow, L>R	L temporal	L hippocampal sclerosis	Hypoperfusion L temporal lobe	Hyperperfusion L temporal lobe with hypoperfusion rest of L cerebral hemisphere
8	8:7	4:0	R parietal EPC No hemiparesis	Normal	Normal	Signal change and atrophy, high R posteriorfrontoparietal region	Focal area hyperfusion not so clearly seen; adjacent area hypoperfusion still present; asymmetry of temporal lobes	Focal hyperperfusion R parietal with adjacent area hyperperfusion; asymmetry of temporal lobes
9	12:11	0:6	L, secondary generalisation	Frontocentral slow with sharp waves on R	Upper frontal discharges, R>L	L hippocampal sclerosis	Hypoperfusion L temporoparietal lobe	Hyperperfusion R temporoparietal
10	3:11	3:5	L parietal EPC	L centrottemporal slow	L centrottemporal discharges	L frontoparietal cortical abnormality	Hypoperfusion L parietal lobe	Hyperperfusion L frontoparietal
11	13:1	8:0	R parietal Mild L hemiparesis	R temporoparietal discharges	R temporoparietal — quickly wide- spread 17s into attack	Atrophy of whole R cerebral hemisphere	Hypoperfusion R temporoparietal lobe	Hyperperfusion R parietal
12	15:8	2:6	L R hemiparesis	L midtemporal slow and sharp waves	Low-amplitude activity over L hemisphere with discharges in R hemisphere	L temporoparietal cortical dysplasia	Hypoperfusion L temporoparietal region	Hyperperfusion L parietal
13	13:10	7:0	R parietal L hemiparesis	Normal	R mid and posterior slow, with runs of discharges same area during attack	Old R middle cerebral infarct	Absence of activity in R parietal region, with hypoperfusion most of R hemisphere	Absence of activity in R parietal region with hypoperfusion most of R hemisphere
14	9:2	2:6	L parietal, secondary generalisation R hemiparesis	L centroparietal discharges near midline	Widespread fast; no definite lateralisation	Old L middle cerebral infarct	Large defect in L parietal region	As interictal, with focal area hyperperfusion in vertex of L hemisphere

TABLE II  
Relative localising value of investigations performed

Investigation	Localising	Lateralising	Non-Diagnostic
EEG			
Temporal	6	0	1
Extratemporal	3	2	2
MRI			
Temporal	6	0	1
Extratemporal	4	2	1
Interictal SPECT (focal hypoperfusion)			
Temporal	6	1	0
Extratemporal	3	3	1
Ictal Spect (focal hyperperfusion)			
Temporal	7	0	0
Extratemporal	5	0	2

quate therapeutic doses. Only two patients had epilepsy that had lasted for less than two years. In these cases a high number of anticonvulsant drugs had been tried over a shorter period. Seizure frequency ranged from 12 per day to four per month.

Seven children had temporal lobe epilepsy and the other seven had extratemporal epilepsy (including four with a hemiparesis). This diagnosis was based on clinical history, and both ictal and interictal electroencephalography (EEG). A child was considered to have complex partial seizures of temporal lobe onset if there was evidence of oro-alimentary automatisms, stereotyped complex automatisms with postictal confusion, psychic aura such as fear or *déjà vu*, an aura of a formed auditory hallucination, a distinct epigastric aura or automatisms followed by postictal confusion. Features at the onset such as focal motor or sensory phenomena or rapid onset and cessation of the seizure suggested an extratemporal onset. Clinical lateralisation was based on lateralised motor phenomena or speech disturbance before or immediately after the seizure. 11 children had complex partial seizures of a single type with or without secondary generalisation; one had complex partial seizures of two types although the semiology in both was suggestive of a similar lateralisation. Two children in this series had

epilepsia partialis continua. All could be lateralised on the basis of features of the seizure history.

MRI was performed in all cases (as previously reported by Cross *et al.* 1993). MRI demonstrated a focal abnormality in 13 children (see Tables I and II). Of the seven children with temporal lobe epilepsy, three showed changes consistent with unilateral hippocampal sclerosis, two had a dysembryoplastic neuroepithelial tumour and one had hippocampal atrophy. One had a normal MRI. Of the seven children with extratemporal epilepsy, two had a porencephalic cyst, two had changes consistent with focal inflammation, one had unilateral cerebral atrophy, one had cortical dysplasia and one had unilateral hippocampal sclerosis.

#### ICTAL SPECT EXAMINATION

The child was admitted to the ward at least two days before the examination. Medication was withdrawn if seizure frequency was less than five per week. An intravenous cannula was inserted on the morning of the examination and continuous video-EEG monitoring was performed. A research fellow (J.H.C.) trained in the technique remained in attendance throughout the test, and when a typical seizure started, she mixed and injected the  $^{99}\text{Tc}^{\text{M}}$  HMPAO as soon after the seizure

onset as possible. Children were scanned within three hours of injection and were sedated using intravenous midazolam (0.5mg/kg) immediately before the scan. HMPAO is a fat-soluble lipophilic unstable substance which has a high first-pass extraction efficiency of 80 to 90 per cent. This diffuses intracellularly, then undergoes some metabolic change to a hydrophilic compound and is retained. So while it is extracted rapidly and uptake is probably within a minute, it then becomes fixed to the initial distribution at the time of injection, reflected in the subsequent scan. The video recording was used to review the seizure type as well as to document the timing of injection of  $^{99}\text{Tc}^{\text{M}}$  HMPAO relative to seizure onset. The EEG was reviewed for any evidence of lateralisation or localisation.

#### INTERICTAL SPECT EXAMINATION

An intravenous cannula was inserted on the morning of the examination. The child was allowed to play and was kept in as normal an environment as possible. All seizures were documented and the time of the last seizure was noted. Where possible, the injection was given after the child had been seizure-free for 24 hours. In two patients with epilepsy partialis continua, 'interictal' scans were performed 30 minutes after injection with intravenous benzodiazepine, which was given to terminate seizure activity. To minimise distress,  $^{99}\text{Tc}^{\text{M}}$  HMPAO was injected through the cannula while the child was on the ward. The dose was calculated as a fraction of adult dose (550 MBq) on the basis of surface area (Paediatric Task Force 1990). Imaging was done within three hours of the injection with  $^{99}\text{Tc}^{\text{M}}$  HMPAO. Sedation, when required, was achieved with intravenous midazolam after the injection of  $^{99}\text{Tc}^{\text{M}}$  HMPAO. Previous studies have shown in adults that scanning within four hours of injection is appropriate (Costa *et al.* 1986).

#### IMAGE ACQUISITION AND ANALYSIS

SPECT images were acquired using a single-headed Elscint SP6 gamma camera rotating by  $6^\circ$  increments over  $360^\circ$  for a total acquisition time of 40 minutes. Six studies had to be truncated to  $180^\circ$  total angle as movement occurred during the

latter part of the study. Images were subsequently reconstructed both parallel to the temporal lobe and parallel to the orbitomeatal line, creating two sets of axial slices in addition to slices in the coronal and sagittal planes. The scans were analysed visually for asymmetry of perfusion by one observer (I.G.) who knew whether the scan was ictal or interictal but was otherwise unaware of all clinical, EEG and MRI data. A scan was considered abnormal if an area of least  $2\text{cm}^2$ , which was considered visually abnormal, also showed  $>10$  per cent difference from the radioactivity in the same area on the opposite side. For the interictal scans an area with decreased activity was considered abnormal (interictal hypoperfusion), while for ictal studies an area with increased activity was considered abnormal (ictal hyperperfusion). A total absence of radioactivity in an area greater than  $2\text{cm}^2$  was always considered abnormal (Podreka *et al.* 1987).

#### Results

For the interictal scans  $^{99}\text{Tc}^{\text{M}}$  HMPAO was injected between 30 minutes and 48 hours after the seizure. This was at least 24 hours after the last seizure in eight cases. For the ictal studies the children were injected at a mean of 50 seconds from the onset of the seizure (range 0 to 105 seconds). This required the close attendance of a research fellow for up to 13 hours per patient (mean eight hours, range 0 to 13 hours) while video-telemetry was performed. 13 children were injected during the clinical seizure. In two children this was 28 and 39 seconds into the phase of secondary generalisation. One patient with temporal lobe epilepsy was injected 12 seconds after the cessation of clinical activity (69 seconds after the onset).

On the interictal study, all 14 children demonstrated a localised area of focal hypoperfusion. In all seven children with temporal lobe epilepsy the area of hypoperfusion was localised to one temporal lobe. Of the seven remaining children, two demonstrated absence of activity in one parietal region; two showed focal hypoperfusion, one in the frontal lobe and one in the parietal lobe; and three showed a wider area of hypoperfusion extending over more than one lobe of the same hemisphere.



On the ictal study twelve children demonstrated a focal area of hyperperfusion consistent with the clinical seizure focus. One of the remaining two children showed increased perfusion of the right temporoparietal region, with clinical suggestion of right frontal onset to her seizures. She was given the injection 85 seconds into the seizure, 39 seconds after secondary generalisation. At the time of injection there were no persisting focal features. In the other child, absence of activity was seen in one parietal lobe but there was no focal area of increased perfusion in this ictal study.

Comparison of the ictal and interictal scans showed a focal area of ictal hyperperfusion corresponding to an area of interictal hypoperfusion in 12 children (Fig. 1). This was the typical pattern associated with a focal seizure origin. In three (all with extratemporal epilepsy), the area of hyperperfusion on the ictal scan was more localised than the area of hypoperfusion on the interictal scan. This included one patient in whom MRI had revealed a porencephalic cyst, and who not surprisingly had a similar defect in that hemisphere on both interictal and ictal scans. Following ictal injection an additional area of focal hyperperfusion was seen adjacent to the vascular defect, and this was presumed to be the site of seizure activity. Neither of the two remaining children showed any difference between the ictal and interictal scans.

One child with temporal lobe epilepsy had ictal, postictal and interictal studies. These demonstrated the 'postictal switch' phenomenon previously reported in adults (Newton *et al.* 1992a). The ictal scan obtained with injection during the clinical seizure (55 seconds from the onset) showed focal hyperperfusion of the left temporal lobe; the postictal scan, for which injection was 43 seconds after the cessation of the seizure, indicated medial hyperperfusion of the left temporal lobe with lateral hypoperfusion. The interictal scan, for which the injection was given 30 minutes after the seizure, indicated hypoperfusion of the whole left temporal lobe.

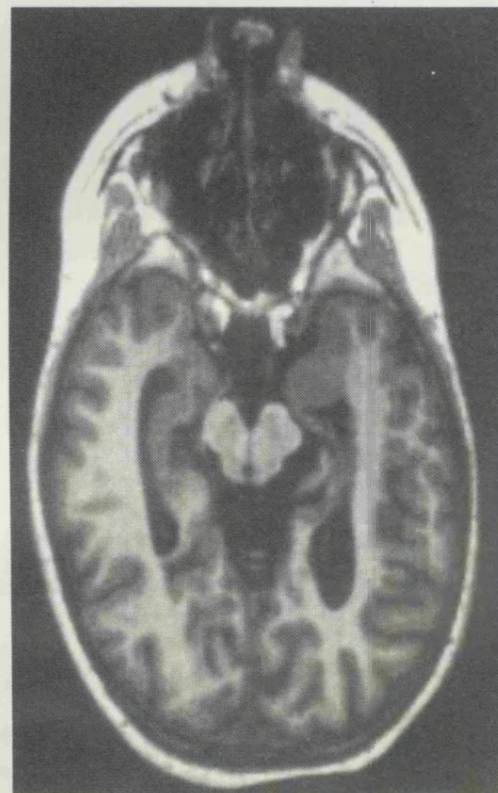
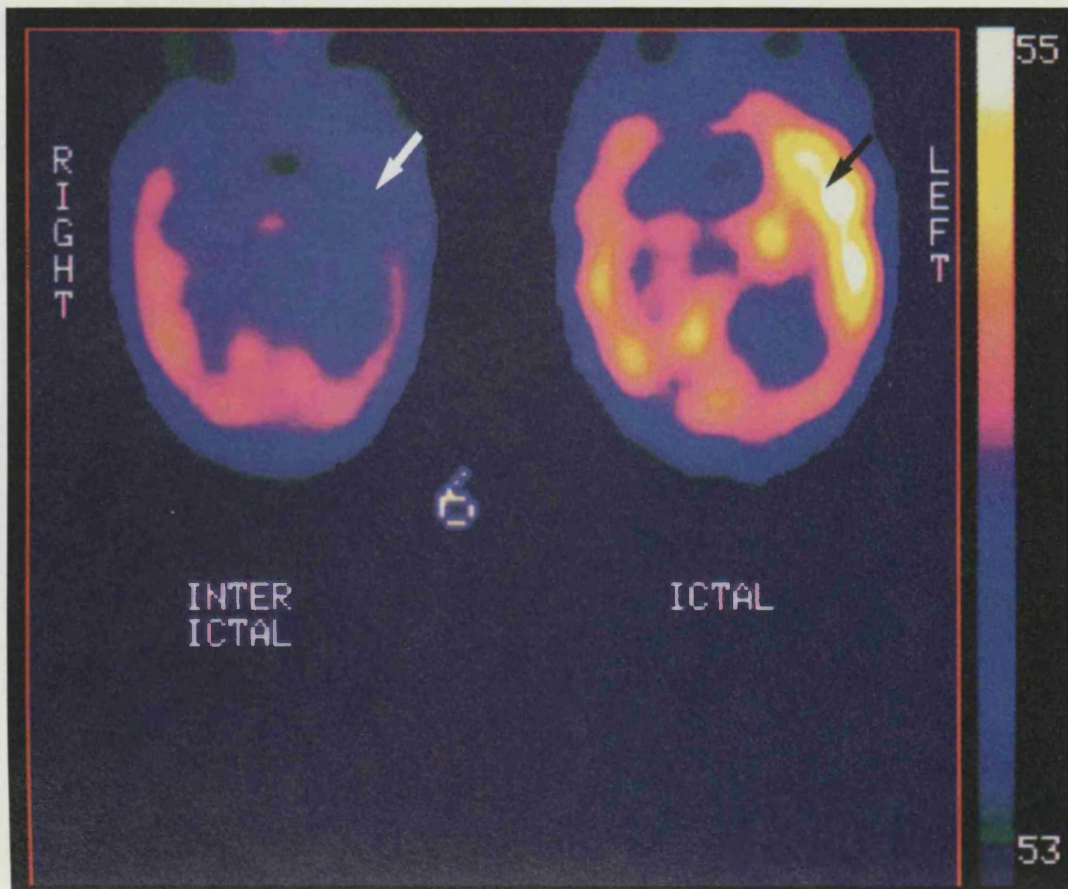
## Discussion

This study reports the ictal and interictal  $^{99}\text{Tc}^{\text{M}}$  HMPAO rCBF findings in 14 children

with intractable complex partial seizures. It has demonstrated that ictal and interictal scans can be routinely achieved in children. We have shown that this technique is of value in the presurgical investigation of patients, for children with temporal and those with extratemporal epilepsy. In all but one child in this series an injection of  $^{99}\text{Tc}^{\text{M}}$  HMPAO was achieved during the clinical seizure.

The role of  $^{99}\text{Tc}^{\text{M}}$  HMPAO in the interictal phase has been well described, an area of low uptake representing decreased rCBF and therefore decreased metabolism (Rowe *et al.* 1991a). Concern has been expressed as to how much reliance can be placed on interictal SPECT alone in localising the seizure focus (Rowe *et al.* 1991a, Berkovic *et al.* 1993). In this series an area of reduced rCBF was found in all cases, and this finding had a high rate of concordance with the site of clinical localisation (93 per cent). A similar concordance rate was found in a study of children with temporal lobe epilepsy (87 per cent) (Harvey *et al.* 1993a). In an adult series interictal studies were found to be less reliable (48 per cent) (Rowe *et al.* 1991a), which may reflect a difference in severity of disease, type or duration of epilepsy or method of interpretation. We also did not regard this localised reduced rCBF as reliable for seizure localisation. In 12 of the 14 children a localised increase in rCBF was seen on the ictal study in the same area as interictal hypoperfusion. This included one child for whom a total absence of activity had been seen in one area on interictal scan (concordant with a porencephalic cyst on MRI), and in two children in whom bilateral changes were seen on the ictal EEG. Since no other change had taken place in the children, apart from changes in the ictal vs the interictal state, it is our interpretation that the difference between the two  $^{99}\text{Tc}^{\text{M}}$  HMPAO scans reflects activity related to the epileptic focus.

In three children with extratemporal epilepsy the area of increased uptake on the ictal scan was more localised than the area of decreased rCBF on the interictal scan. The wider area of hypoperfusion on the interictal scan may suggest that there is a larger area of functional abnormality associated with the disease process; pos-



**Fig. 1.** (a) Interictal and ictal  $^{99}\text{Tc}^{\text{M}}$  HMPAO scans, transaxial slice parallel to temporal lobe, of a seven year old girl with temporal lobe epilepsy. Interictal scan shows focal hypoperfusion of the left temporal lobe (arrowed), whereas ictal scan shows hyperperfusion of the same area (arrowed). (b) MRI in tilted axial plane parallel to the long axis of hippocampus, reconstructed from 3D MPRAGE data set (TR/TE/TI=10/4/200,  $\alpha=12^\circ$ , matrix=128X256X256, FOV=160X256X256). This shows small left hippocampus with no signal change.

iron emission tomography and previous SPECT studies have suggested that this also occurs in temporal lobe epilepsy (Henry *et al.* 1990, Engel *et al.* 1992, Harvey *et al.* 1993a). This area, which may be involved in the propagation of the seizure, may remain functionally abnormal in both the interictal and ictal states (Prince and Wilder 1967; Engel 1990, 1993).

The timing of the injection in relation to the seizure is likely to be important. For example, in one child, focal hyperperfusion was demonstrated when the injection was given 12 seconds after the seizure had ended, yet in another child who had an injection 43 seconds after the cessation of the seizure, there was a different pattern of rCBF from that when the injection was made during the seizure. Previous data in adults with temporal lobe epilepsy have suggested that changes may remain when the injection is given up to 30 seconds after cessation of the seizure, and our data are consistent with this. On the other hand, the changes seen in the two patients for whom the interictal scan was obtained as little as 30 minutes following the cessation of the seizure (one with extratemporal and one with temporal lobe epilepsy) suggest that cerebral blood flow may have returned to the resting state by this time. This is in accordance with previous data in adults (Berkovic *et al.* 1993).

Although patterns of cerebral blood flow during and after seizures have been well described in temporal lobe epilepsy, there are only scattered reports in extratemporal epilepsy (Lee *et al.* 1987, Marks *et al.* 1991, Harvey *et al.* 1993b). Our results in extratemporal epilepsy are similar to those reported in temporal lobe epilepsy. Recognising that ictal injection is required for optimal results, greater difficulties could be foreseen in extratemporal epilepsy, in which the seizures are typically shorter and may give little warning. The shortest injection time achieved in this study (in children who did not have *epilepsia partialis continua*) was 34 seconds after seizure onset. However, this was a highly selected group as all but one child with extratemporal epilepsy had either hemiparesis or *epilepsia partialis continua*, *i.e.* lesional epilepsy.

When secondary generalisation of the

seizure occurs, focal changes are more likely to be seen if the injection is made before this generalisation (Lee *et al.* 1987, Harvey *et al.* 1993a) or if there are persistent lateralising features (Rowe *et al.* 1991b). In this series, two children with extratemporal epilepsy were injected during the phase of secondary generalisation. One showed focal hyperperfusion concordant with the clinical focus. In this child  $^{99}\text{Tc}^{\text{M}}$  HMPAO was injected earlier but there were persistent lateralising features to the seizure throughout. Lee *et al.* (1987) reported one case where focal changes were seen in extratemporal epilepsy in which  $\text{N}_1\text{N}_1\text{N}'$ -trimethyl- $\text{N}'$ -(2 hydroxy-3-methyl-5-[ $^{123}$ ] iodobenzyl)-1, 3-propanediamine 2HCl (HIPDM) was injected 42 seconds after the onset of the tonic phase. There is no indication as to whether there were persistent focal clinical changes. More data are required to determine the importance of the speed of injection or persistent localising features in such children.

Our previous data suggest that MRI demonstrates structural abnormality in most children with intractable partial epilepsy (Cross *et al.* 1993). It is still uncertain whether seizures originate from the region of these structural abnormalities. Data from this current study suggest that a high rate of abnormality is also seen when using  $^{99}\text{Tc}^{\text{M}}$  HMPAO SPECT. The use of ictal and interictal SPECT together provides a link between the ictal events and the fixed structural abnormalities. This is essential before surgical treatment for epilepsy; the only other method for demonstrating this link may be invasive electrophysiology. For this reason we believe the ictal SPECT, in particular when compared to the interictal SPECT, provides these data non-invasively. Interictal SPECT used on its own probably provides similar information to that seen on MRI. For this reason, and because the region of hypoperfusion may be more extensive than the ictal abnormalities, we would not recommend localisation of the seizure focus based solely on the interictal scan.

This study shows that ictal SPECT scans can be routinely acquired in the evaluation of children with intractable partial epilepsy for epilepsy surgery in our centre. The patterns of rCBF which occur

after ictal and interictal injection of  $^{99}\text{Tc}^{\text{M}}$  HMPAO in such children are similar to those reported in adults. The use of both an interictal and an ictal study means that seizure localisation (ictal) as well as the extent of the affected area (interictal) may be recognised in children with complex partial seizures. The exact timing of the injection in relation to the onset and cessation of seizures is critical. The non-invasive nature of these studies, and the ability to obtain these scans routinely, provides diagnostic information which could not otherwise be obtained and which helps in the presurgical investigation of such children. This investigation, which is directly related to seizure activity, is a powerful tool which can assist earlier surgical treatment of such children.

Accepted for publication 22nd October 1994.

#### Acknowledgements

This project is supported by Action Research. We would like to thank the radiographers who acquired the scans and Helen Thomas for radiopharmaceutical support.

#### Authors' Appointments

\*J. Helen Cross, MRCP, Clinical Research Fellow;  
G. D. Jackson, FRACP, Senior Lecturer;  
B. G. R. Neville, FRCP, Professor of Paediatric Neurology, Neurosciences Unit;  
A. Todd-Pokropek, MPhil, Professor, Radiology and Physics Unit;  
The Institute of Child Health, London.  
I. Gordon, FRCR, Consultant in Radiology;  
S. G. Boyd, MD, Consultant in Electrophysiology;  
P. J. Anderson, MSc, Physicist;  
The Great Ormond Street Hospital for Children NHS Trust, London.

\*Correspondence to first author at The Wolfson Centre, Mecklenburgh Square, London WC1N 2AP, UK.

#### SUMMARY

Fourteen children with intractable complex partial seizures underwent ictal and interictal  $^{99}\text{Tc}^{\text{M}}$  HMPAO single photon emission computed tomography (SPECT) scans. Abnormalities concordant with clinical and/or EEG localisation were present in 13 of 14 ictal and/or interictal scans. Focal hyperperfusion was seen at the seizure focus on ictal scans and focal hypoperfusion was seen on interictal scans. The timing of the injection in relation to the start of the seizure was crucial for reliable localisation. While recognisable patterns of regional cerebral blood flow (rCBF) were seen on either interictal or ictal scans, marked changes in the patterns of rCBF between the ictal study and interictal study provided the most reliable information about seizure localisation. Using both ictal and interictal studies,  $^{99}\text{Tc}^{\text{M}}$  HMPAO SPECT may provide data about both the seizure origin and its relationship to structurally abnormal regions of the brain.

#### RÉSUMÉ

*Enfants avec épilepsie focale réfractaire: tomographie à émissions de photon unique  $^{99}\text{Tc}^{\text{M}}$  HMPAO (SPECT) au cours des crises et entre les crises*

Des scanners de tomographie à émissions de photon unique  $^{99}\text{Tc}^{\text{M}}$  HMPAO (SPECT) ont été pratiqués chez 14 enfants présentant des crises comitiales focales, au moment des crises et entre les crises. Des anomalies correspondant aux données de la clinique et/ou des localisations EEG étaient présentes chez 13 de 14 enfants. Une hypercirculation focale fut observée à l'emplacement de la crise sur les scanners de crise, et une hypocirculation sur les scanners intercritiques. Le moment de l'injection par rapport au début de la crise fut crucial pour établir une localisation fidèle. Alors que des aspects reconnaissables de circulation sanguine cérébrale régionale (rCBF) étaient observées aux scanners intercritiques ou critiques, des modifications marquées d'allures des rCBF entre les enregistrements critiques et intercritiques fournissaient l'information la plus fidèle sur la localisation des crises. À l'aide d'enregistrements à la fois critiques et intercritiques, le SPECT  $^{99}\text{Tc}^{\text{M}}$  HMPAO peut fournir des données à la fois sur l'origine d'une crise et ses relations avec les régions structurellement anormales du cerveau.

#### ZUSAMMENFASSUNG

*Kinder mit unbeeinflussbarer fokaler Epilepsie: iktale und interiktale  $^{99}\text{Tc}^{\text{M}}$  HMPAO Single-Photon-Emissions-Komputer-Tomographie*

Bei 14 Kindern mit unbeeinflussbaren komplexen Partialanfällen wurden iktale und interiktale  $^{99}\text{Tc}^{\text{M}}$  HMPAO Single-Photon-Emissions-Komputertomogramme (SPECT) gemacht. 13 der 14 iktalen und/oder interiktalen Befunde zeigten Anomalien, die mit der klinischen und/oder EEG Lokalisation übereinstimmten. Die iktalen Scans zeigten eine fokale Hyperperfusion im Bereich des Krampfherdes, während die interiktalen Scans eine fokale Hypoperfusion aufwiesen. Der Injektionszeitpunkt in Relation zum Beginn des Anfalls war von entscheidender Bedeutung für eine genaue Lokalisation. Während erkennbare Muster des regionalen cerebralen Blutflusses (rCBF) entweder auf interiktalen oder iktalen Scans nachweisbar waren, lieferten die deutlichen Veränderungen der Muster des rCBF zwischen den iktalen und interiktalen. Untersuchungen die verlässlichste Information über den Anfallsursprung. Bei der Durchführung von iktalen und interiktalen Untersuchungen kann die  $^{99}\text{Tc}^{\text{M}}$  HMPAO SPECT sowohl über den Anfallsursprung als auch über seine Relation zu strukturell abnormen Regionen des Gehirns Befunde liefern.

## RESUMEN

*Niños con epi-lepsia focal intratable: Tomografía computarizada por la emisión de un simple foton (<sup>99</sup>Tc<sup>M</sup> HMPAO) ictal a interictal*

Catorce niños con convulsiones parciales complejas intratables fueron examinados ictal e interictalmente por medio de la tomografía computada por emisión de un solo foton: <sup>99</sup>Tc<sup>M</sup> HMPAO SPECT. Anomalías concordantes con una localización clínica o EEG, se dieron en 13 de los 14 casos estudiados. En los Scanners ictales se observó una hiperperfusión focal y una hipoperfusión en los interictales. El momento de la inyección en relación con el inicio de la convulsión fue crucial para una localización fiable. Mientras que los patrones reconocibles de la circulación cerebral regional (rCCR) fueron observados tanto en los scanners ictales como en los interictales proporcionaron la información más fiable sobre la localización de la convulsión. Utilizando ambos tipos de estudios la <sup>99</sup>Tc<sup>M</sup> HMPAO SPECT puede proporcionar datos acerca del origen de la convulsión y su relación con regiones estructuralmente anómalas del cerebro.

## References

- Berkovic, S. F., Newton, M. R., Chiron, C., Dulac, O. (1993) 'Single photon emission tomography.' In Engel, J., Jr (Ed.) *Surgical Treatment of the Epilepsies, 2nd Edn.* New York: Raven Press.
- Costa, D.C., Ell, P.J., Cullum, I.D., Jarritt, P.H. (1986) 'The normal distribution of Tc-99m HMPAO in normal man.' *Nuclear Medicine Communications*, **7**, 647-658.
- Cross, J. H., Jackson, G. D., Neville, B. G. R., Connelly, A., Kirkham, F. J., Boyd, S. G., Pitt, M. C., Gadian, D. G. (1993) 'Early detection of abnormalities in partial epilepsy using magnetic resonance.' *Archives of Disease in Childhood*, **69**, 104-109.
- Duchowny, M. (1992) 'The syndrome of partial seizures in infancy.' *Journal of Child Neurology*, **7**, 66-69.
- Duncan, R., Patterson, J., Roberts, R., Hadley, D. M., Bone, I. (1993) 'Ictal/postictal SPECT in the presurgical localisation of complex partial seizures.' *Journal of Neurology, Neurosurgery and Psychiatry*, **56**, 141-148.
- Engel, J. (1990) 'The Hans Berger lecture. Functional explorations of the human epileptic brain and their therapeutic implications.' *Electroencephalography and Clinical Neurophysiology*, **76**, 296-316.
- (1993) 'Intracerebral recordings: organisation of the human epileptogenic region.' *Journal of Clinical Neurophysiology*, **10**, 90-98.
- Brown, W. J., Kuhl, D. E., Phelps, M. E., Mazziotta, J. C., Crandall, P. H. (1977) 'Pathological findings underlying focal temporal lobe hypometabolism in partial epilepsy.' *Annals of Neurology*, **112**, 518-528.
- Harvey, A. S., Bowe, J. M., Hopkins, I. J., Shield, L. K., Cook, D. J., Berkovic, S. F. (1992) 'Ictal [<sup>99m</sup>Tc] HMPAO SPECT in children with frontal lobe epilepsy.' *Epilepsia*, **33** (S3), 55. (Abstract)
- — — — — (1993a) 'Ictal <sup>99m</sup>Tc-HMPAO single photon emission computed tomography in children with temporal lobe epilepsy.' *Epilepsia*, **34**, 869-877.
- Hopkins, I. J., Bowe, J., Cook, D. J., Shield, L. K., Berkovic, S. F. (1993b) 'Frontal lobe epilepsy: Clinical seizure characteristics and localization with ictal <sup>99m</sup>Tc HMPAO SPECT.' *Neurology*, **43**, 1966-1980.
- Henry, T. R., Mazziotta, J. C., Engel, J. Jr., Christenson, P. D., Zhang, J-X., Phelps, M. E., Kuhl, D. E. (1990) 'Quantifying interictal metabolic activity in human temporal lobe epilepsy.' *Journal of Cerebral Blood Flow Metabolism*, **10**, 748-757.
- Holmes, G. L. (1984) 'Partial complex seizures in children: an analysis of 69 seizures in 24 patients using EEG FM radiotelemetry and videotape recording.' *Electroencephalography and Clinical Neurophysiology*, **57**, 13-20.
- Jayakar, P., Duchowny, M. S. (1990) 'Complex partial seizures of temporal lobe origin in early childhood.' *Journal of Epilepsy*, **3**, 41-45.
- Lee, B. I., Markand, O. N., Wellman, H. N., Siddiqui, A. R., Mock, B., Krepshaw, J., Kung, H. (1987) 'HIPDM single photon emission computed tomography brain imaging in partial onset secondarily generalised tonic clonic seizures.' *Epilepsia*, **28**, 305-311.
- Marks, D. A., Katz, A., Hoffer, P., Spencer, S. S. (1991) 'Ictal SPECT in extratemporal epilepsy.' *Epilepsia*, **32**, 79. (Abstract)
- Newton, M. R., Berkovic, S. F., Austin, M. C., Rowe, C. C., McKay, W. J., Bladin, P. F. (1992a) 'Postictal switch in blood flow distribution and temporal lobe seizures.' *Journal of Neurology, Neurosurgery and Psychiatry*, **55**, 891-894.
- — — Reutens, D. C., McKay, W. J., Bladin, P. F. (1992b) 'Dystonia, clinical lateralisation and regional blood flow changes in temporal lobe seizures.' *Neurology*, **42**, 371-377.
- Paediatric Task Group European Association of Nuclear Medicine (Members A. Piepsz (Chairman), K. Hahn, I. Roca *et al.* (1990) 'A radiopharmaceuticals schedule for imaging in paediatrics.' *European Journal of Nuclear Medicine*, **17**, 127-129.
- Podreka, I., Suess, E., Goldenberg, G., Steiner, M., Brucke, T., Muller, Ch., Lang, W., Neirinckx, R. D., Deecke, L. (1987) 'Initial experience with technetium-99m HMPAO brain SPECT.' *Journal of Nuclear Medicine*, **28**, 1657-1666.
- Prince, D. A., Wilder, B. J. (1967) 'Control mechanisms in cortical epileptogenic foci. "Surround inhibition".' *Archives of Neurology*, **16**, 194-202.
- Rowe, C. C., Berkovic, S. F., Austin, M. C., Saling, M., Kalnins, R.M., McKay, W.J., Bladin, P. F. (1991a) 'Visual and quantitative analysis of interictal SPECT with Technetium-99m-HMPAO in temporal lobe epilepsy.' *Journal of Nuclear Medicine*, **32**, 1688-1694.
- — — McKay, W. J., Bladin, P. F. (1991b) 'Patterns of postictal cerebral blood flow in temporal lobe epilepsy: qualitative and quantitative analysis.' *Neurology*, **41**, 1096-1103.
- Wyllie, E., Chee, M., Granstrom, M. L., DelGiudice, E., Estes, M., Comair, Y., Pizzi, M., Kotagal, P., Bourgeois, B., Luders, H. (1993) 'Temporal lobe epilepsy in early childhood.' *Epilepsia*, **34**, 859-868.
- Yamamoto, N., Watanabe, K., Negaro, T., Takaesu, E., Aso, K., Furune, S., Takahashi, I. (1987) 'Complex partial seizures in children; ictal manifestations and their relation to clinical course.' *Neurology*, **37**, 1379-1382.

# LORAZEPAM VERSUS DIAZEPAM IN THE ACUTE TREATMENT OF EPILEPTIC SEIZURES AND STATUS EPILEPTICUS

Richard Appleton  
Anne Sweeney  
Imti Choonara  
Joan Robson  
Elizabeth Molyneux

Convulsive status epilepticus (SE) is a potentially life-threatening medical emergency (Aicardi and Chevrie 1983). The mortality and morbidity of SE are related to its duration, and therefore early control is important (Delgado-Escueta and Bajorek 1982). A rapid and sustained control of status may obviate the need for multiple anti-epileptic drug (AED) administrations and prolonged hospitalisation. Finally, rapid control of an initial seizure may prevent the development of SE. The ideal drug for treating acute seizures (including SE) should act rapidly, have a sustained duration of action and be safe (Shorvon 1993). None of the AEDs that are commonly used in treating SE completely fulfils these criteria. Diazepam is generally considered to be the drug of first choice in status epilepticus (Delgado-Escueta *et al.* 1982), but although it is initially effective and relatively safe (Nicol *et al.* 1969), it has an effective half-life of only two to four hours (Mattson 1972). Repeated injections or continuous infusions are therefore often required for sustained control of seizures, with an increased risk of respiratory depression (necessitating endotracheal intubation) (Chiulli *et al.* 1991) and hypotension. Clonazepam may be superior to diazepam (Congdon and Forsythe 1980), but can cause excessive salivary and bronchial secretions,

increasing the risk of respiratory complications. Phenobarbitone is often effective in controlling seizures only at doses that depress consciousness or respiration (Crawford *et al.* 1988). Phenytoin has a slow onset of action and may cause hypotension and cardiac dysrhythmias (Wallis *et al.* 1968). Paraldehyde has a relatively short duration of action, may produce pulmonary oedema and, because of its recommended rectal route of administration, may be expelled before absorption (Woodbury and Fingl 1975).

Lorazepam is a newer benzodiazepine which is an effective anticonvulsant in animals (Gluckman and Stein 1978, Homan and Walker 1983), causes little respiratory depression (Walker *et al.* 1979, Leppik *et al.* 1983, Gilmore *et al.* 1984, Lacey *et al.* 1986, Crawford *et al.* 1987) and has an elimination half-life of approximately 13 hours (Greenblatt *et al.* 1977). A number of studies have suggested that lorazepam has a longer duration of anti-epileptic activity than diazepam (Waltregny and Dargent 1975, Walker *et al.* 1979, Griffith and Karp 1980, Leppik *et al.* 1983, Levy and Krall 1984) and that a single dose is usually sufficient to control SE, thereby reducing the risk of respiratory arrest associated with repeated doses. However, these studies have either been retrospective or have been based on anecdotal evidence,

## Ictal cerebral perfusion related to EEG in drug resistant focal epilepsy of childhood

J H Cross, S G Boyd, I Gordon, A Harper, B G R Neville

### Abstract

**Objectives**—To evaluate the EEG changes during seizures in children with drug resistant focal epilepsy who demonstrate hypoperfusion at the “seizure focus” interictally, but no perfusion change during the seizure.

**Methods**—Ictal EEG findings of six children with focal epilepsy who demonstrated hypoperfusion on rCBF SPECT after an interictal injection of  $^{99}\text{Tc}^{\text{m}}$  HMPAO concordant with the seizure focus, but who did not demonstrate rCBF change after an ictal injection (group 1) were reviewed. These were contrasted with the EEG data of six children matched as closely as possible for age, type of epilepsy, and pathology who did show hyperperfusion at the seizure focus on ictal scan when compared with the interictal study (group 2).

**Results**—The children in group 1 showed slowing of the EEG at the time of the  $^{99}\text{Tc}^{\text{m}}$  HMPAO injection relative to that seen at the onset of the seizure. Those in group 2 showed rhythmic activity, or sharp waves, or both on EEG at the time of injection. This last change was also seen consistently when the EEG data of a further 13 children who also showed ictal hyperperfusion at the seizure focus were reviewed.

**Conclusion**—Ictal rCBF does not invariably increase at the seizure focus in patients with drug resistant focal epilepsy.

(*J Neurol Neurosurg Psychiatry* 1997;62:377-384)

**Keywords:** electroencephalography; hypoperfusion; single photon emission computed tomography

Regional cerebral blood flow studies using  $^{99}\text{Tc}^{\text{m}}$  HMPAO single photon emission computed tomography (rCBF SPECT) have been advocated as a useful non-invasive preoperative tool in the presurgical evaluation of adults and children with drug resistant focal epilepsy.<sup>1-4</sup> Scans after an ictal injection of  $^{99}\text{Tc}^{\text{m}}$  HMPAO have correctly identified the seizure focus in 93%–99% of cases by demonstrating a focal area of hyperperfusion.<sup>1,3,4</sup> However, several factors influence reliable interpretation of ictal rCBF SPECT. The timing of the injection relative to seizure onset and offset is crucial, with a higher prediction rate noted after an ictal (when the injection is

given during a seizure) as opposed to an immediate postictal injection (when the injection is given as soon after seizure offset as possible).<sup>5,6</sup> There has also been some debate as to whether comparable results are obtained in temporal and extratemporal epilepsy. This may relate to the shorter duration of extratemporal seizures and the lower probability of obtaining an ictal injection. Injection after secondary generalisation has been shown to reliably identify the focus, particularly in the presence of persistent focal features during the clinical seizure or if injection is made soon after the generalisation.<sup>2,3,7</sup> Finally, with the resolution of a single headed gamma camera, it may be assumed that minor perfusion changes within extensive underlying pathology may not be detected.

We report the EEG findings of a particular group of children with drug resistant focal epilepsy who underwent ictal and interictal rCBF SPECT as part of their investigation before consideration for surgery. These children showed hypoperfusion at the site of the clinical/EEG focus after interictal injection, but no change in perfusion pattern was noted after ictal injection.

### Methods

#### PATIENTS

Of 50 children with drug resistant focal epilepsy who were investigated with interictal and ictal rCBF SPECT as part of their preoperative evaluation, 30 had technically satisfactory ictal EEG recordings for the seizure in which  $^{99}\text{Tc}^{\text{m}}$  HMPAO was injected. Of these, seizures could be localised in 25 children on the basis of clinical, EEG, and MRI data (23 have subsequently undergone surgery for the management of their epilepsy) and such localisation was termed the “seizure focus”. Nineteen of these 25 children showed an area of hyperperfusion after the ictal injection of  $^{99}\text{Tc}^{\text{m}}$  HMPAO concordant with the seizure focus. In 17 of these 19 this was concordant with an area of hypoperfusion after the interictal injection; in one there was no asymmetry of perfusion on interictal scan and in one hypoperfusion of an area non-concordant with the seizure focus. The remaining six children showed an area of hypoperfusion after interictal injection that was concordant with the seizure focus, but no perfusion change after ictal injection.

The six children who did not show a perfusion change formed group 1 for this study. They were then matched as closely as possible with regard to age, timing of  $^{99}\text{Tc}^{\text{m}}$  HMPAO

Neurosciences Unit 1,  
Institute of Child  
Health, The Wolfson  
Centre, Mecklenburgh  
Square, London  
WC1N 2AP, UK

J H Cross  
A Harper  
B G R Neville

Department of  
Radiology  
I Gordon

Department of Clinical  
Neurophysiology,  
Great Ormond Street  
Hospital for Children  
NHS Trust, Great  
Ormond Street,  
London WC1N 3JH,  
UK

Correspondence to:  
Dr J H Cross.

Received 16 January 1996  
and in final revised form  
8 October 1996  
Accepted 16 October 1996

injection, temporal versus extratemporal epilepsy, and underlying pathology with a further group of six children (group 2) who did show a focal area of hyperperfusion after ictal injection concordant with the seizure focus. We then checked the findings from these two groups against those of the remaining 13 children (group 3).

#### EEG TELEMETRY

Time locked video/digital EEG recording was carried out at the bedside initially using a 16 channel Grass EEG machine linked to a videotape system developed in house<sup>8</sup> (12 patients) and recently, a 32 channel cable system connected through an A/D card to a PC for display and storage of the signals (Stellate Systems Ltd) (13 patients). Remontaging was carried out off line. Videos were reviewed for seizure semiology and were also used to determine the exact timing of the injection of <sup>99</sup>Tc<sup>m</sup> HMPAO relative to the seizure onset. Changes on EEG at seizure onset, the time of <sup>99</sup>Tc<sup>m</sup> HMPAO injection, and for the next 30 seconds were determined.

#### SINGLE PHOTON EMISSION COMPUTED TOMOGRAPHY

For the ictal rCBF SPECT children were admitted to the ward at least two days before the examination. Medication was withdrawn if seizure frequency was less than five a week. An intravenous cannula was inserted on the morning of the examination and continuous video-EEG monitoring was performed. A doctor trained in the technique remained in attendance throughout the test, and, when a typical seizure started, injected the <sup>99</sup>Tc<sup>m</sup> HMPAO as soon after the seizure onset as possible. Children were scanned within three hours of injection and if necessary, sedated with intravenous midazolam (0.5 mg/kg) immediately before the scan.

For the interictal rCBF SPECT examination, the children were admitted to hospital and an intravenous cannula was inserted on the morning of the examination. The children were allowed to play and kept in a "normal" environment. All seizures were documented and the time of the last seizure noted. To minimise distress, the appropriate dose of <sup>99</sup>Tc<sup>m</sup> HMPAO was injected through the cannula

while the children were on the ward. Sedation, when required, was achieved with intravenous midazolam given after the injection of <sup>99</sup>Tc<sup>m</sup> HMPAO at the time of the scan as with the ictal scan.

Images were acquired every 6° for 360° on a single headed Elscint SP6 gamma camera for a total acquisition time of 40 minutes. Images were subsequently reconstructed parallel to the temporal lobe and along the orbitomeatal line, to create two sets of axial slices as well as slices in the coronal and sagittal planes. The scans were reviewed visually for asymmetry of perfusion by two observers blind to all EEG or MRI data. Semiquantitative analysis was also performed, a difference of greater than 10% between matched regions in the two hemispheres being considered abnormal.

#### Results

##### GROUP 1

The mean age of the six children who did not show a perfusion change after ictal injection of <sup>99</sup>Tc<sup>m</sup> HMPAO was 11 years 3 months (range 4 years 11 months to 16 years). Their mean age of onset of epilepsy was 2 years with a mean duration of epilepsy of 9 years (table 1). Three had temporal lobe epilepsy and three extratemporal epilepsy (two with hemisymphromes). The range of timing of injection of <sup>99</sup>Tc<sup>m</sup> HMPAO from the seizure onset was 24–85 seconds (mean 44 seconds), with a mean duration of seizure of 78 seconds. Five of the six were ictal injections (that is, during the seizure) and one was soon after clinical cessation (immediate postictal). The underlying pathology as determined by MRI was dysembryoplastic neuroepithelial tumour in two, porencephalic cyst in two, and hippocampal sclerosis in two (table 1; fig 1).

Table 2 shows the interictal and ictal EEG findings. The EEG changes were lateralised in five children in this group, and also localised in four. In four children there was slowing of activity relative to the onset of the seizure at the time of <sup>99</sup>Tc<sup>m</sup> HMPAO injection (fig 2B). Two children had slow activity at the onset of the seizure; in one (patient 5) there was attenuation followed by slow activity, with subsequent secondary generalisation at the time of the injection.

Table 1 MRI and SPECT data of group 1

Patient No	Age (months)	Age at first seizure (months)	MRI	Interictal rCBF SPECT	Duration of seizure recorded (s)	Time of injection of <sup>99</sup> Tc <sup>m</sup> HMPAO (s)	Ictal rCBF SPECT
1	166	30	R MCA infarct	Absence activity R parietal region	40	35	Absence activity R parietal region
2	59	18	Atrophy and gliosis L hemisphere	Decreased uptake through whole L hemisphere	14	24	Decreased uptake through whole L hemisphere
3	152	60	L frontoparietal DNET	Absence activity L frontoparietal region	57	32	Absence activity L frontoparietal region
4	68	7	L temporal cortical dysplasia	Hypoperfusion L temporoparietal region	80	36	Hypoperfusion L temporoparietal region
5	155	6	L hippocampal sclerosis	L temporoparietal hypoperfusion	98 (2 <sup>nd</sup> gen at 27s)	62	L temporoparietal hypoperfusion
6	193	24	L hippocampal sclerosis	L temporal hypoperfusion	167	52	L temporal hypoperfusion

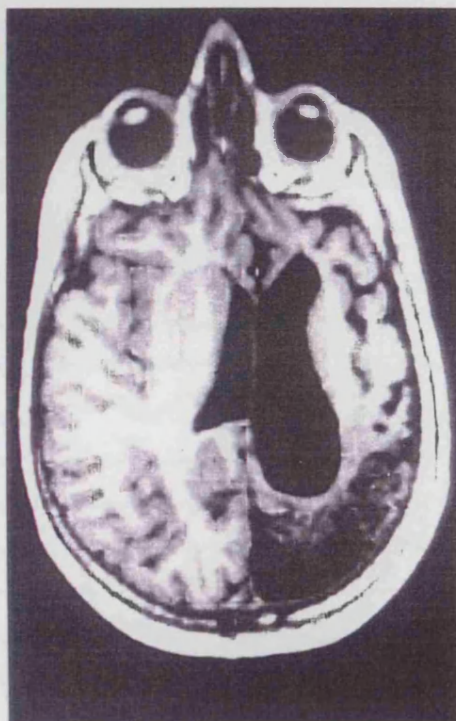MCA = Middle cerebral artery; DNET = dysembryoplastic neuroepithelial tumour.



Table 2 EEG data of group 1

Patient No	Interictal EEG	EEG at seizure onset	EEG at $^{99}\text{Tc}^m$ HMPAO injection	EEG over next 30 seconds
1	Occasional R centrottemporal sharp wave, irregular 4-5/s	Abrupt 10-12/s rhythmic activity R	Attenuation, isolated sharp wave, some slow	Gradually slow fades
2	2/s spikes/sharp waves L frontal region	Attenuation followed by 10-12/s rhythmic activity over L	Activity slows to 4-5/s	As at injection
3	Irregular L temporal 4-5/s	Abrupt L centrottemporal slowing, 1-1.5/s	L sided 2/s at time of injection	Slowly fades, but 2/s for next 30s
4	Spike wave complexes 2/s, L sided	Spike wave 7/s before, then bilateral attenuation, L > R	Rhythmic 3-4/s L posterior temporal	Rhythmic activity 3-4/s L posterior temporal
5	Slow activity 2-3/s, spike wave and spikes, often prominent upper frontal, R > L	Attenuation, then slow activity 1-2/s over both frontotemporal regions	2° generalised, 4-5/s	Generalised, 4-5/s
6	Slow activity L temporal	L anterior temporal 2-3/s, some sharp waves	Pronounced slowing 1.5-2/s	Returns to 4/s, later slows < 2/s

Figure 1 (A) Transverse MRI parallel to the axis of the temporal lobes of patient 2 (group 1), reconstructed from a 3D magnetisation prepared rapid acquisition gradient echo (MP-RAGE) data set (TR = 10 ms, TI = 200 ms, TE = 4 ms, flip angle = 12°). This shows atrophy and gliosis of a large part of the left hemisphere, particularly posteriorly. (B) Interictal and ictal  $^{99}\text{Tc}^m$  HMPAO SPECT; transverse sections parallel to the axis of the temporal lobes of patient 2. Decreased uptake through the left hemisphere is noted on both scans.

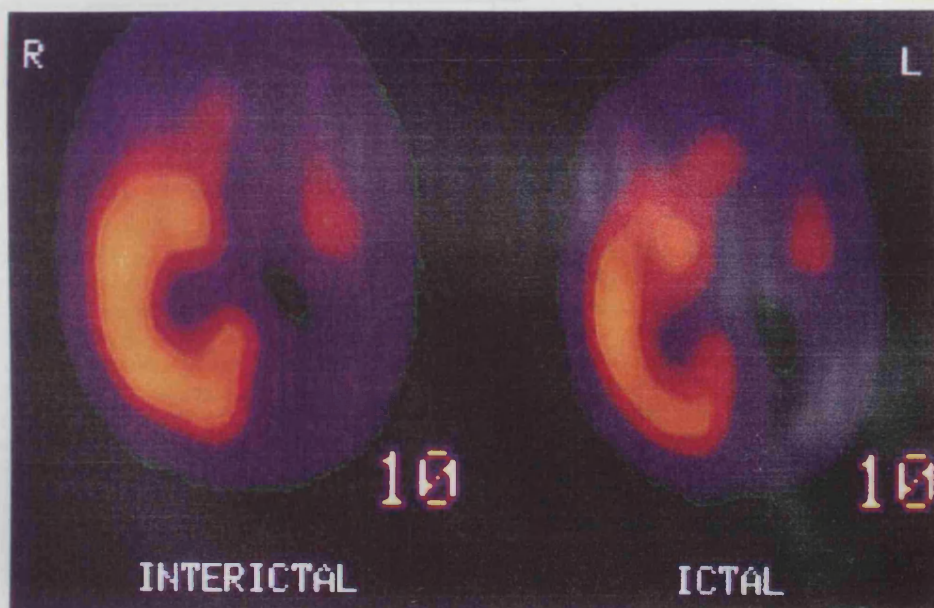


A

## GROUP 2

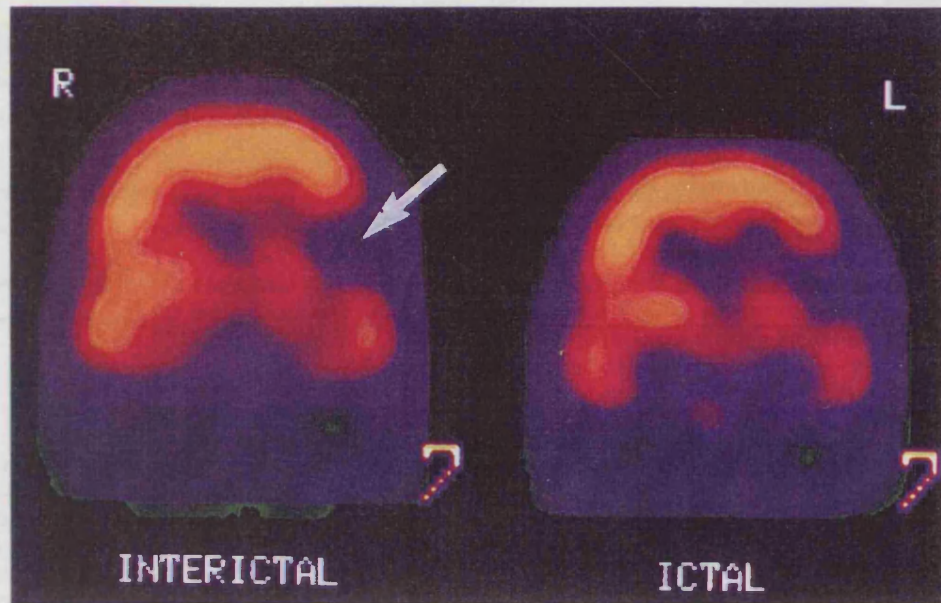
The mean age of this group was 9 years 9 months (range 9 months to 12 years 5 months) with a mean age at onset of epilepsy of 2 years 5 months and mean duration of epilepsy 5 years 10 months (table 3; fig 3). Three had temporal lobe epilepsy and three extratemporal epilepsy (three with hemisyn-dromes). The range of timing of injection of  $^{99}\text{Tc}^m$  HMPAO from seizure onset was 39-78 (mean 54) seconds with five ictal and one immediately postictal injection. The mean duration of seizure recorded was 72 (range 56-103) seconds. The underlying pathology as determined by MRI was hippocampal sclerosis in two, porencephalic cyst in two, cortical dys-plasia in one, and a dysembryoplastic neuroepithelial tumour in one (table 3; fig 3).

Table 4 shows the interictal and ictal EEG findings for this group. The EEG changes were lateralised in all children in this group and also localised in four. Five children had sharp waves, or rhythmic activity, or both of > 4/s at the onset of the seizure and this was seen in all children at the time of  $^{99}\text{Tc}^m$  HMPAO injection (fig 4B). In only one child (patient 9) was there marginal slowing of 6/s activity at seizure onset to 4/s at the time of injection; this activity was rhythmic through-out.

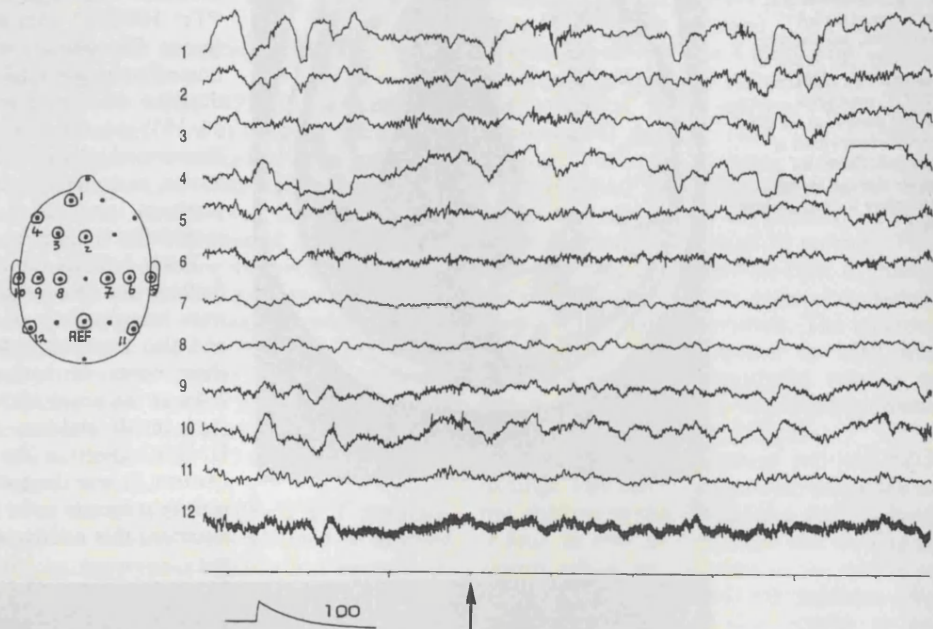


B

Figure 2 (A) Interictal and ictal  $^{99}\text{Tc}^{\text{m}}$  HMPAO SPECT; coronal sections perpendicular to the axis of the temporal lobes of patient 3 (group 1). Both scans show an area of absence of activity in the left frontoparietal region (arrow). There was no area of hyperperfusion seen on the ictal scan. (B) EEG at the time of injection of  $^{99}\text{Tc}^{\text{m}}$  HMPAO (arrowed) in patient 3. This shows irregular slow activity at 2/s.



A



B

#### GROUP 3

These 13 children were those remaining in our series who showed an area of hyperperfusion after ictal injection of  $^{99}\text{Tc}^{\text{m}}$  HMPAO and who had EEG recordings at the time of injection available for review. Eight had temporal lobe epilepsy and five extratemporal epilepsy (two with a hemisindrome). Their mean age was 8 years 6 months (range 2 years 6 months to 16 years 4 months) and they had a mean duration of epilepsy of 5 years 5 months (range 1 year to 13 years 10 months). The ictal scans comprised 10 in which the injections were ictal and three in which they were immediately postictal. The MRI in this group showed developmental anomalies in six (dysplasia in four, tuberous sclerosis in one, and dysembryoplastic neuroepithelial tumour in one), hippocampal sclerosis in three, hemiatrophy in one, hippocampal atrophy in one,

tumour in one, and no abnormality in one.

Table 5 summarises the EEG data from these children. The EEG was lateralising in 11, and also localising in eight. All children in this group showed sharp waves, or rhythmic activity, or both at the onset of the seizure that was maintained at least until the time of  $^{99}\text{Tc}^{\text{m}}$  HMPAO injection: two children with temporal lobe epilepsy showed slowing at the time of injection relative to the onset of the seizure; spikes were also seen in one and a degree of slowing of rhythmic activity in the other (4/s to 2–3/s).

#### Discussion

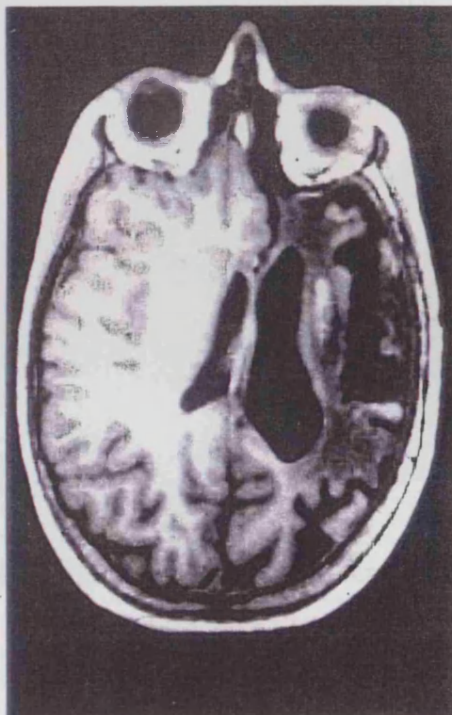Ictal  $^{99}\text{Tc}^{\text{m}}$  HMPAO SPECT has been reported to show focal hyperperfusion concordant with the seizure focus in around 95% of children with temporal and frontal lobe

Table 3 MRI and SPECT data of group 2

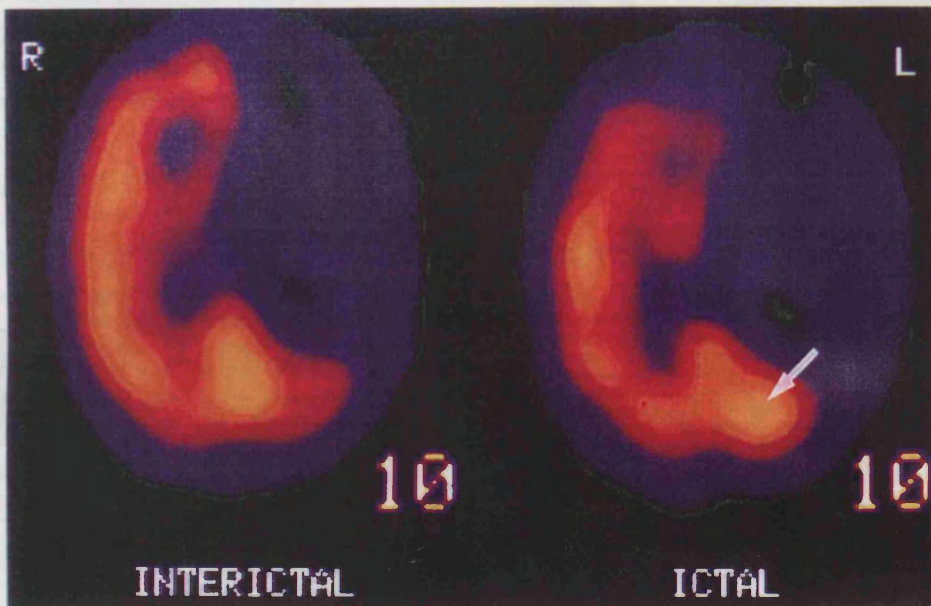
Patient No	Age (months)	Age at first seizure (months)	MRI	Interictal rCBF SPECT	Duration of seizure recorded (s)	Time of injection of $^{99}\text{Tc}^m$ HMPAO (s)	Ictal rCBF SPECT
7	110	30	L MCA infarct	Absence activity L parietal region	72 (2 <sup>o</sup> gen at 26/s)	54	As interictal with area hyperperfusion superior to defect
8	96	42	Encephalomalacia L cerebral hemisphere with atrophy L brain stem	Absence activity L frontal/parietal, with hypoperfusion temporal and occipital lobes	66	39	Hyperperfusion L posterior parietal and occipital
9	9	0.3	L posterior temporal and inferior parietal cortical dysplasia	L temporoparietal - occipital hypoperfusion	82	41	L temporoparietal hyperperfusion
10	149	84	L temporal DNET	L temporal hypoperfusion	78	78	L temporal hyperperfusion with parietal hypoperfusion
11	129	15	L hippocampal sclerosis	Left parietal hypoperfusion	56	69	L temporal hyperperfusion
12	101	3	L hippocampal sclerosis	L temporal hyperperfusion	81	42	L temporal hyperperfusion

MCA = Middle cerebral artery; DNET = dysembryoplastic neuroepithelial tumour.

Figure 3 (A) Transverse MRI parallel to the axis of the temporal lobes of patient 8 (group 2) reconstructed from a 3D MP-RAGE data set. There is encephalomalacia of the left hemisphere. (B) Interictal and ictal  $^{99}\text{Tc}^m$  HMPAO SPECT; transverse sections parallel to the axis of the temporal lobes of patient 8. Although hypoperfusion of a large part of the left hemisphere is present on both scans, after an ictal injection an additional area of hyperperfusion is seen over the left parieto-occipital region (arrowed).



A



B

epilepsy.<sup>3,4</sup> In this study we have reviewed children with intractable focal epilepsy who had an area of hypoperfusion on interictal rCBF SPECT which was concordant with the seizure focus (determined from clinical, EEG, and MRI data), but who did not show a change in rCBF after an ictal or immediate postictal injection. This seems to correlate with prominent slowing of the EEG at the time of the  $^{99}\text{Tc}^m$  HMPAO injection. By contrast, when ictal focal hyperperfusion was demonstrated in groups 2 and 3, it was associated with rhythmic activity, sharp waves, or both at that time.

On review of the findings of group 1, it became clear that none of the factors implicated in lack of ictal rCBF change, whether taken singly or in combination, could explain all the cases. The group included examples of definitely ictal as well as postictal injections, and of temporal as well as extratemporal epilepsy. Furthermore, whereas it might be considered that the resolution of the scan would not be sufficient to detect a change in rCBF within the extensive pathology in patient 2 (group 1; fig 1), changes were clearly shown in another child with comparable pathology (patient 8, fig 3).

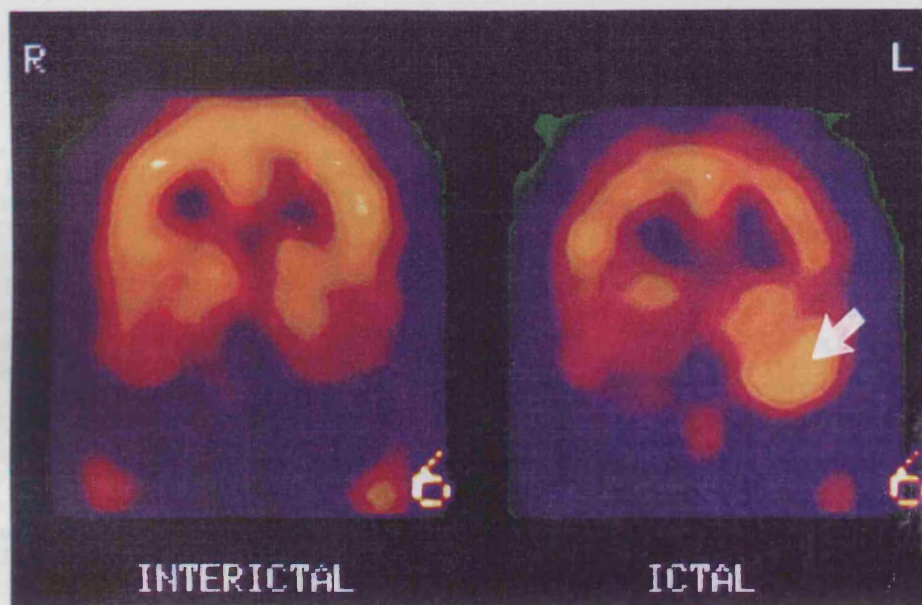
Table 4 EEG data of group 2

Patient No	Interictal EEG	EEG at seizure onset	EEG at $^{99}\text{Tc}^m$ HMPAO injection	EEG over next 30 seconds
7	2-3/s L temporal slow with sharp waves	Subtle increase in sharp, 6-7/s	Increase in sharp waves on L with rhythmic 12-14/s over R occipitotemporal	2/s activity, multiple spikes over R, later over L
8	Intermittent spikes/sharp waves over L hemisphere	Rhythmic fast L anterior region, 10-12/s	Rhythmic sharp waves 4/s	Persists, particularly L temporal
9	Repetitive L temporo-occipital sharp waves every 2s	L temporoparietal rhythmic activity 6/s	L temporoparietal rhythmic 4/s	Persists as at injection
10	L temporal sharp waves	L temporal rhythmic sharp waves, 3/s, soon increases to 6/s	L temporal rhythmic sharp waves 6-7/s	Stops abruptly 4-5/s after injection, postictal L sided slow 1-2/s
11	Frequent epileptiform phenomena bitemporally, L > R	Attenuation, followed by run 2-3/s L anterior temporal	L anterior temporal 6-7/s sharp wave activity	L anterior temporal sharp wave activity 4-5/s continues
12	L mid temporal 2-5/s sharp waves and spikes	2/s sharp waves and runs 4-5/s rhythmic, L	Runs of L temporal spikes with rhythmic activity 4-5/s	Continues as at injection

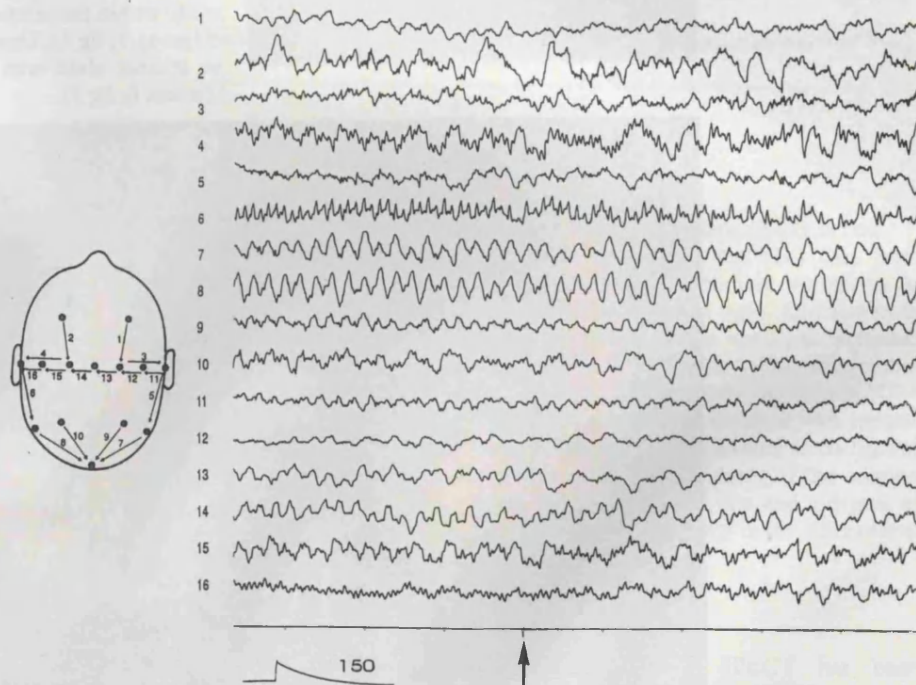
Acute slowing of scalp recorded EEG activities may be recognised as ictal, especially when this is rhythmic.<sup>9</sup> This is usually interpreted, however, as evidence that the seizure

onset is relatively distant from the electrodes. Focal ischaemic changes may also produce localised slow activity, which is often irregular. Such irregular slow activity was found

Figure 4 (A) Interictal and ictal  $^{99}\text{Tc}^m$  HMPAO SPECT; coronal sections perpendicular to the axis of the temporal lobes of patient 10 (group 2). The scan after an interictal injection shows left temporal hypoperfusion, whereas the scan after an ictal injection shows hyperperfusion of a similar area (arrowed). (B) EEG at the time of injection of  $^{99}\text{Tc}^m$  HMPAO (arrowed) in patient 10. Rhythmic sharp waves at 6-7/s are seen over the left temporal region.



A



B

Table 5 Summary of EEG findings in group 3

EEG abnormality	EEG at onset of seizure	EEG at time of <sup>99</sup> Tc <sup>m</sup> HMPAO injection	EEG over next 30 s
Sharp waves	8	9	4
Rhythmic activity	5	4	4
Attenuation	0	0	0
Slow activity < 4/s	0	0	4
Return to normal	0	0	1

consistently at the time of the injection of <sup>99</sup>Tc<sup>m</sup> HMPAO in those children in whom there was no change in an area of hypoperfusion between interictal and ictal scans; in four of the six this was a change relative to the onset of the seizure when more typical regional/focal rhythmic activity or sharp waves were seen. The notion that this area of hypoperfusion was concordant with the seizure focus was supported by the results of surgical resection.

Slowing of the EEG at the time of <sup>99</sup>Tc<sup>m</sup> HMPAO injection was a consistent finding in group 1 suggesting a real phenomenon, and implies that ischaemia rather than hyperaemia may be occurring during the seizure. Rowe *et al*<sup>5</sup> correlated EEG findings (depth or sphenoidal) with postictal rCBF SPECT and found that the degree of postictal slow activity at the time of injection of <sup>99</sup>Tc<sup>m</sup> HMPAO was significantly associated with the presence of lateral temporal hypoperfusion, consistent with our data. Hyperventilation tends to produce slowing of the EEG, and has been found in association with a reduction in rCBF as determined by Doppler ultrasound of the common carotid artery.<sup>10</sup> Three of the children under study here had seizures triggered by hyperventilation; one from group 1 (patient 6) and two from group 3. In view of the demonstration in the two patients from group 3 of a clear area of temporal hyperperfusion concordant with the seizure focus, associated with rhythmic sharp waves at the onset of the seizure and at <sup>99</sup>Tc<sup>m</sup> HMPAO injection, we think that it is unlikely that hyperventilation influenced the results in patient 6.

Although the EEG findings in this study suggest that there may be relative ischaemia during focal seizures in some children rather than hyperperfusion, we were unable to determine whether there was further hypoperfusion on the ictal scan relative to the interictal scan as absolute quantitation of rCBF using <sup>99</sup>Tc<sup>m</sup> HMPAO SPECT is not currently possible in the clinical context. Penfield originally described "cortical anaemia" from arterial vasoconstriction during focal seizures induced by intraoperative stimulation.<sup>11</sup> After further observations, Penfield suggested a sequence of events involving capillary dilatation during the seizure, and arterial vasoconstriction after the seizure, although recognising that the second could occur during the seizure. More recent studies with laser Doppler flowmetry during subdural monitoring of focal seizures in humans have also shown that a reduction in rCBF may occur.<sup>12</sup> Although decreased rCBF may make tissue susceptible to further damage, the few children in this study preclude any comment on differences in clinical fea-

tures between groups 1 and 2 such as seizure semiology and cognitive function.

Although there are many studies of rCBF during focal seizures, the underlying mechanisms responsible for the commonly reported increase during seizures remain poorly understood. This may be caused by increased metabolic demands, although the stimulus for, and control of, increased blood flow remains unclear. There are also few studies investigating cerebral metabolism during focal seizures. <sup>18</sup>Fluorodeoxyglucose positron emission tomography (<sup>18</sup>FDG PET) studies are difficult to obtain ictally, but those reported describe both an increase<sup>13-16</sup> and decrease<sup>13</sup> in cerebral glucose metabolism at the seizure focus. Where this has been compared to rCBF, a parallel increase in each has been shown,<sup>15,16</sup> with no increase in oxygen consumption.<sup>15</sup> Engel *et al* suggested that patterns seen on ictal <sup>18</sup>FDG PET in partial epilepsy are unique to each patient.<sup>13</sup> Studies during generalised seizures in animals suggest an abolition of normal cerebral autoregulation<sup>17</sup> and a local metabolic change, particularly ion exchange, may be responsible.<sup>18</sup> If cerebral autoregulation is abolished, local factors in each individual may determine whether ictal rCBF is increased or decreased.

Our study has shown that ictal rCBF does not invariably increase at the seizure focus in patients with intractable focal epilepsy and that this correlates with irregular slowing on the EEG suggestive of ischaemia. This is of practical importance when interpreting ictal and interictal rCBF <sup>99</sup>Tc<sup>m</sup> HMPAO SPECT studies and also emphasises the usefulness of concurrent EEG monitoring at the time of the ictal injection.

We thank the Wellcome Trust and Action Research for their support.

- Berkovic SF, Newton MR, Chiron C, Dulac O. Single photon emission tomography. In: Engel J Jr, ed. *Surgical treatment of the epilepsies*. 2nd ed. New York: Raven Press, 1993;233-43.
- Cross JH, Gordon I, Jackson GD, *et al*. Children with intractable focal epilepsy: ictal and interictal <sup>99</sup>Tc<sup>m</sup> HMPAO single photon emission computed tomography. *Dev Med Child Neurol* 1995;37:673-81.
- Harvey AS, Bowe JM, Hopkins IJ, Shield LK, Cook DJ, Berkovic SF. Ictal <sup>99</sup>Tc<sup>m</sup>-HMPAO single photon emission computed tomography in children with temporal lobe epilepsy. *Epilepsia* 1993;34:869-77.
- Harvey AS, Hopkins IJ, Bowe JM, Cook DJ, Shield LK, Berkovic SF. Frontal lobe epilepsy: clinical seizure characteristics and localization with ictal <sup>99</sup>Tc<sup>m</sup>-HMPAO SPECT. *Neurology* 1993;43:1966-80.
- Rowe CC, Berkovic SF, Austin MC, McKay WJ, Bladin PF. Patterns of postictal cerebral blood flow in temporal lobe epilepsy: qualitative and quantitative analysis. *Neurology* 1991;41:1096-103.
- Rowe CC, Berkovic SF, Austin MC, *et al*. Visual and quantitative analysis of interictal SPECT with technetium-<sup>99m</sup>-HMPAO in temporal lobe epilepsy. *J Nucl Med* 1991;32:1688-94.
- Rowe CC, Berkovic SF, Sia ST, *et al*. Localization of epileptic foci with postictal single photon emission computed tomography. *Ann Neurol* 1989;26:660-8.
- Lester M. Capturing the image with the signal: a system developed in a paediatric neurophysiology department which changes a routine EEG into a video/EEG. *J Electrophysiol Technol* 1993;19:121-8.
- Rivello JJ, Foley CM. The epileptiform significance of intermittent rhythmic delta activity in childhood. *J Child Neurol* 1992;7:156-60.
- Yamatani M, Konishi T, Murakami M, Okuda T. Hyperventilation activation on EEG recording in children with epilepsy. *Pediatr Neurol* 1995;13:42-5.
- Penfield W. The evidence for a cerebral vascular mechanism in epilepsy. *Ann Intern Med* 1933;7:303-10.
- Ronne-Engstrom E, Carlson H, Blom S, *et al*. Monitoring of cortical blood flow in human epileptic foci using laser doppler flowmetry. *J Epilepsy* 1993;6:145-51.
- Engel J, Jr., Kuhl DE, Phelps ME, Rausch R, Nuwer M.

- Local cerebral metabolism during partial seizures. *Neurology* 1983;33:400-13.
- 14 Chugani HT, Rintahaka PJ, Shewmon DA. Ictal patterns of cerebral glucose utilization in children with epilepsy. *Epilepsia* 1994;35:813-22.
- 15 Franck G, Sadzot B, Salmon E, et al. Regional cerebral blood flow and metabolic rates in human focal epilepsy and status epilepticus. *Adv Neurol* 1986;44:935-48.
- 16 Kuhl DE, Engel J, Phelps ME, Selin C. Epileptic patterns of local cerebral metabolism and perfusion in humans determined by emission computed tomography of  $^{18}\text{F}$ FDG and  $^{15}\text{N}$ H $_3$ . *Ann Neurol* 1980;8:348-60.
- 17 Plum F, Posner JB, Troy B. Cerebral metabolic and circulatory responses to induced convulsions in animals. *Arch Neurol* 1968;18:1-13.
- 18 Meyer JS, Gotoh F, Favale E. Cerebral metabolism during epileptic seizures in man. *Electroencephalogr Clin Neurophysiol* 1966;21:10-22.

---

## NEUROLOGICAL STAMP


---

### Sigmund Freud (1856-1939)

The Austrian neurologist and psychiatrist Sigmund Freud was born in Freiberg in eastern Moravia (now Pribor, Czechoslovakia) in 1856. As a student he already worked at the Institute of Physiology (University of Vienna) and had published papers on neurohistology. In 1885 Freud became Docent for Neuropathology and travelled to Paris for six months. There the introduction to the phenomena of hysteria and hypnotism brought a fundamental reorientation in Freud's scientific interests. Back in Vienna he withdrew from academic life and opened a practice. The cooperation with the physician Breuer—aimed at developing promising methods of treating hysteria—led to Freud's development of psychoanalysis as a therapeutic procedure, which at the same time provided him with the basis for his ideas on the instinctive structure of human behaviour, at the centre of which, in his opinion, was the sexual drive.

Sigmund Freud died in London on 23 September 1939. In 1938 the publications of this Jewish doctor had been "consigned to the flames". His teaching—much criticised, rejected, misinterpreted, and in part disproved—had had a considerable and worldwide influence on the development not only of anthropology, psychology, psychiatry, and psychotherapy, but also on philosophy, art, and literature. Austria commemorated him in 1981 with a stamp.

FRANZ ALLERBERGER



## Interictal $^{99}\text{Tc}^{\text{m}}$ HMPAO SPECT and $^1\text{H}$ MRS in Children with Temporal Lobe Epilepsy

\*J. H. Cross, †I. Gordon, †A. Connelly, \*G. D. Jackson, ‡C. L. Johnson, \*B. G. R. Neville, and †D. G. Gadian

\*Neurosciences Unit and †Radiology and Physics Unit, Institute of Child Health, and ‡Department of Radiology, Great Ormond Street Hospital for Children NHS Trust, London, England

**Summary:** *Purpose:* To understand the pathological basis of focal hypoperfusion seen on interictal  $^{99}\text{Tc}^{\text{m}}$  hexamethylpropyleneamine oxime (HMPAO) single-photon-emission computed tomography (SPECT) in intractable temporal lobe epilepsy, and to determine why the technique may be misleading in the localization and lateralization of the seizure focus in some cases.

*Methods:* Interictal  $^{99}\text{Tc}^{\text{m}}$  HMPAO SPECT and proton magnetic resonance spectroscopy ( $^1\text{H}$  MRS) of the mesial temporal regions were performed in 14 children with intractable temporal lobe epilepsy not caused by a foreign tissue lesion.

*Results:* Hypoperfusion of one temporal lobe ipsilateral to the seizure focus was demonstrated in 10 (71%) of the children;  $^1\text{H}$  MRS correctly lateralised in eight of these 10. No asym-

metry of perfusion of the anterior temporal regions was seen in the remaining four children; on  $^1\text{H}$  MRS, three of these were bilaterally abnormal but nonlateralising. Repeated SPECT and  $^1\text{H}$  MRS in three children demonstrated changes over time, the findings from the two techniques being consistent with each other on both the initial and the repeated scans.

*Conclusions:* Abnormalities demonstrated by  $^1\text{H}$  MRS correlate well with those seen on interictal SPECT and can help to understand the pathologic basis of these SPECT abnormalities. Furthermore, the presence of bilateral damage can result in an absence of perfusion asymmetry on interictal SPECT. **Key Words:** Temporal lobe epilepsy—Single-photon-emission computed tomography—Proton magnetic resonance spectroscopy—Child—Hypoperfusion—Neuronal loss.

Studies of patients with epilepsy have shown that  $^{99}\text{Tc}^{\text{m}}$  hexamethylpropyleneamine oxime (HMPAO) single-photon-emission computed tomography (SPECT) can aid in seizure localisation, with ictal studies demonstrating an area of hyperperfusion predictive of the seizure focus in <95% of cases (1–5). Interictal studies alone, however, have a low sensitivity in predicting the seizure focus in adults with temporal lobe epilepsy [~45–50% (6,7)]. More recent studies suggested that the sensitivity of interictal SPECT is higher in children than in adults, but that these studies are still not as reliable as ictal studies (1,5). There is the possibility of false localisation with hypoperfusion, seen on the side contralateral to the seizure focus (6); also, hypoperfusion, if correctly lateralising, may extend over a wider area than the temporal lobe (5,8,9).

$^{99}\text{Tc}^{\text{m}}$  HMPAO SPECT studies are analysed for asymmetry of perfusion, whether by visual or semiquantitative

analysis. Absolute quantitation of cerebral blood flow is not possible in the clinical context by using this technique, and direct side-to-side comparison provides the most common method of interpretation. It could therefore be postulated that if bilateral cerebral damage is present, a similar degree of hypoperfusion (or hypometabolism) may be present on both sides and no asymmetry of perfusion seen.

Normal volunteer studies (10) and animal studies using radioactive microspheres (11) have shown the pattern of uptake of  $^{99}\text{Tc}^{\text{m}}$  HMPAO to be equivalent to that of regional cerebral blood flow. However, various other factors also may influence HMPAO uptake. HMPAO has a far higher binding capacity to the nuclei of neurons than to the nuclei of glial cells (12). Uptake will therefore be reduced in the presence of neuronal loss or where there is an increase in glial cells. Although the lipophilicity of HMPAO renders it ideal for crossing the blood-brain barrier, mechanisms influencing uptake across cell membranes remain unclear. A reduction in tissue lipid and a relative increase in water content, however, may affect such uptake. Changes in energy metabolism will modify phospholipids and other lipid contents of nerve cell membranes, reducing membrane permeability (13),

Accepted October 9, 1996.

Address correspondence and reprint requests to Dr. J. H. Cross at Institute of Child Health, The Wolfson Centre, Mecklenburgh Square, London, WC1N 2AP, U.K.

and also will affect levels of glutathione (GSH), a reducing agent, which is thought to be chiefly responsible for the conversion of HMPAO from the lipophilic to the hydrophilic form required for its subsequent retention in the brain (14–16).

Proton magnetic resonance spectroscopy ( $^1\text{H}$  MRS) can provide information about brain damage via the signals from *N*-acetylaspartate (NAA), creatine + phosphocreatine (Cr), and choline-containing compounds (Cho). Several lines of evidence suggest that almost all the NAA within the brain is neuronal (17–20), and so it is commonly accepted that a reduction in the NAA signal reflects neuronal loss or damage. This interpretation is consistent with the spectral changes that have been observed in a number of disorders for which neuronal loss can be expected, including epilepsy (21–26). Our investigations of patients with epilepsy also have shown increases in the Cr and Cho signals (24–26) that, on the basis of studies of purified neural cell types (20), may reflect reactive astrocytosis. We have therefore used the NAA/(Cho + Cr) signal intensity ratio as an index of regional cellular pathology, and in our studies of children with temporal lobe epilepsy, we showed that a reduction in the NAA/(Cho + Cr) signal-intensity ratio can aid in lateralisation of the seizure focus (26). We also showed that ~45% of these children have abnormalities in the contralateral and the ipsilateral temporal lobes (26) and that this is related to cognitive function (27). In this study, we prospectively investigated 14 children with intractable epilepsy to determine whether hypoperfusion as detected by  $^{99}\text{Tc}^m$  HMPAO SPECT is related to brain damage, as indicated by  $^1\text{H}$  MRS.

## METHODS

### Patient population

Fourteen children (nine girls and five boys) with intractable temporal lobe epilepsy were investigated as part of their preoperative evaluation for epilepsy surgery. We defined intractable epilepsy as seizures that had failed to respond to at least three anticonvulsant drugs (AEDs) at adequate therapeutic doses. Children with a foreign tissue lesion seen on magnetic resonance imaging (MRI) were excluded from the study. The children under study had a duration of epilepsy from 1 year to 14 years 11 months (mean, 8 years 7 months). Eight had a history of a febrile seizure in early childhood; in all eight, this was prolonged. A further four had a history of status epilepticus. Three children in the whole group had their first afebrile seizure at age younger than 12 months. These 14 children are a subgroup of a larger population of 20 children whose  $^1\text{H}$  MRS findings in relation to seizure lateralisation have been described previously (26). The remaining six children did not have interictal SPECT, as they were assessed before our inclusion of SPECT in the presurgical evaluation of children with epilepsy.

All children had a single seizure type. We considered a child to have partial seizures of temporal lobe onset if there was evidence of oro-alimentary automatisms, stereotyped complex automatisms with postictal confusion, psychic aura such as fear or *deja-vu*, an aura of a formed auditory hallucination, a distinct epigastric aura, or automatisms followed by confusion postictally. Clinical lateralisation was based on lateralised motor phenomena or speech disturbance during or immediately after the seizure. All children underwent surface EEG recording by using a Grass 12- or 16-channel EEG. Eleven children also underwent ictal recording by using 20-channel video-EEG telemetry. On review of the clinical history and EEG findings, nine children had evidence of a left temporal onset to their seizures, and five, a right temporal onset.

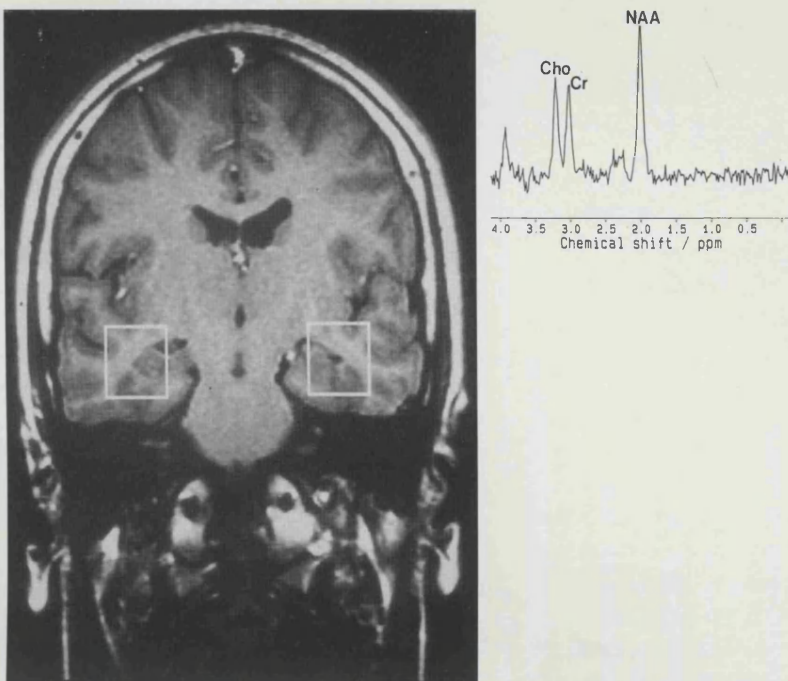
### Magnetic resonance

Magnetic resonance imaging was carried out on all children by using a 1.5 T Siemens whole-body system with a standard quadrature head coil. Where necessary, the children were sedated or underwent a general anaesthetic. In the majority of patients, images were obtained by using an inversion recovery sequence (TR = 3.5 s, TI = 300 ms, TE = 26 ms) in oblique axial and coronal orientations, parallel and perpendicular to the long axis of the hippocampus. In the remaining children, oblique axial images were reconstructed from a 3D Magnetization Prepared Rapid-Gradient-Echo (MP RAGE) (28) data set (TR = 10 ms, TI = 200 ms, TE = 4 ms, flip angle = 12°). In all children,  $T_2$ -weighted images were acquired also in the tilted coronal plane. Spectra were obtained from  $2 \times 2 \times 2$ -cm cubes centred on the mesial temporal lobes (Fig. 1), by using a 90–180–180° spin-echo technique, with three selective radiofrequency pulses applied in the presence of orthogonal gradients of 2 mT/m. Water suppression was achieved by preirradiation of the water resonance by using a 90° gaussian pulse with a 60 Hz bandwidth, followed by a spoiler gradient. TR was 1,600 ms and TE, 135 ms. After global and local shimming and optimisation of the water suppression pulse, data were collected in two to four blocks of 128 scans. The time-domain data were corrected for eddy-current-induced phase modulation by using non-water-suppressed data as a reference (29). Exponential multiplication corresponding to 1-Hz line broadening was carried out before Fourier transformation, and a cubic spline baseline correction was performed.

Signal intensities at 2.0 ppm (primarily NAA), 3.0 ppm (creatine + phosphocreatine, Cr), and 3.2 ppm (choline-containing compounds, Cho) were measured from the peak areas by integration. After earlier studies, data are presented in terms of the intensity ratio NAA/(Cho + Cr), which is, by definition, dimensionless. By using previously defined criteria (25,26) values of NAA/(Cho



1A,B



**FIG. 1.** **A:** Coronal T<sub>1</sub>-weighted image showing the positions of the 2 × 2 × 2-cm cubes from which <sup>1</sup>H magnetic resonance (MR) spectra were obtained. **B:** <sup>1</sup>H MR spectrum from a normal child. The dominant contributions to the spectrum are *N*-acetylaspartate (NAA), creatine + phosphocreatine (Cr), and choline-containing compounds (Cho). The NAA/(Cho + Cr) ratio is 0.84.

+ Cr) <0.72 were considered to be abnormally low. In addition, NAA/(Cho + Cr) was considered lateralising if it was (a) abnormally low on one side and also (b) lower than the other side by >0.05.

#### Interictal SPECT

All children were admitted to hospital, and an intravenous cannula was inserted on the morning of the examination. The children were allowed to play and kept in a "normal" environment. All seizures were documented, and the time of the most recent seizure noted. To minimise distress, the appropriate dose of <sup>99</sup>Tc<sup>m</sup> HMPAO was injected through the cannula while the children were on the ward. The dose was calculated as a fraction of adult dose (550 MBq) on the basis of surface area (30). Injection was made between 2 hours and 5 days after the last seizure (median, 24 h). Sedation, when required, was achieved with intravenous midazolam given at the time of scan.

Images were acquired every 6° for 360° on a single-headed Elscint SP6 gamma camera for a total acquisition time of 40 min. Axial images were subsequently reconstructed parallel to the temporal lobe, as well as slices in the coronal and sagittal planes. The scans were reviewed visually for asymmetry of perfusion by two observers blind to all EEG or MR data. Semiquantitative analysis was also performed, a difference of >10% between matched regions in the two hemispheres being considered abnormal.

## RESULTS

### Magnetic resonance imaging

Magnetic resonance imaging was abnormal on visual assessment in 12 of the 14 children (see Table 1).

Changes consistent with unilateral hippocampal sclerosis (31) were seen in 11 cases, whereas one other child showed unilateral hippocampal atrophy with no signal change. In all 12 children, the abnormalities were ipsilateral to the seizure focus; in one, there was a suggestion of an additional abnormality of the contralateral temporal lobe (patient 3; see Table 1). In two children (patients 5 and 6), there was no convincing abnormality on visual inspection of the MRI. Twelve children have undergone temporal lobectomy with follow-up ranging from 4 weeks to 4 years (six younger than 1 year). Of the two remaining children, one has decided against surgery, and one is now seizure free, taking anticonvulsant medication.

### Proton magnetic resonance spectroscopy

All children underwent <sup>1</sup>H MRS of the mesial temporal lobes. Figure 1B shows the <sup>1</sup>H spectrum obtained from the mesial temporal lobe of a child without epilepsy. The signal at 2.0 ppm is from *N*-acetyl-containing compounds, the dominant contribution being from NAA. The signal at 3.0 ppm is from creatine + phosphocreatine (Cr), whereas the signal at 3.2 ppm is from choline-containing compounds (Cho), including phosphorylcholine and glycerophosphorylcholine. The NAA/(Cho + Cr) signal-intensity ratio is 0.84.

The results from the mesial temporal lobes of the 14 children in this study are shown in Fig. 2 together with the results from 13 normal subjects [as previously reported (25,26)]. As a group, the children in this study show mesial temporal NAA/(Cho + Cr) signal-intensity ratios lower than normals, and this is more marked in the ipsilateral rather than in the contralateral temporal lobes.

TABLE 1. Clinical, MR and interictal  $^{99}\text{Tc}^m$  HMPAO SPECT findings of 14 children with intractable temporal lobe epilepsy

Patient	Age	Age of onset	Seizures/ mo	Focus	MRI	H MRS findings [NAA/(Cho + CR)]		$^1\text{H}$ MRS Lateralisation	Interictal $^{99}\text{Tc}^m$ HMPAO SPECT
						Right	Left		
1	10 yr	14 mo	30	Right temporal	Right hippocampal sclerosis	0.66	0.83	Right	Right temporal hypoperfusion
2	16 yr 11 mo	2 yr	240	Right temporal	Right hippocampal sclerosis	0.62	0.59	None	1. No asymmetry 2. Right temporal hypoperfusion
						0.60	0.88	Right	
3	9 yr 3 mo	7 mo	4	Right temporal	Right hippocampal sclerosis	0.48	0.49	None	No asymmetry
4	14 yr	7 yr 8 mo	5	Right temporal	Right hippocampal sclerosis	0.64	0.69	None	1. Left parietal hypoperfusion, no temporal asymmetry 2. Right temporal hypoperfusion
						0.71	0.83	Right	
5	5 yr 8 mo	6 mo	20	Right temporal	Normal	0.54	0.64	Right	Right temporal hypoperfusion
6	10 yr	5 yr	4	Left temporal	Normal	0.92	0.84	None	Left temporal hypoperfusion
7	9 yr 10 mo	16 mo	12	Left temporal	Left hippocampal sclerosis	0.76	0.47	Left	1. Left temporal hypoperfusion 2. Marginal left temporal hypoperfusion
						0.84	0.67	Left	
8	17 yr 10 mo	108 mo	8	Left temporal	Left hippocampal sclerosis	0.89	0.62	Left	Left temporal hypoperfusion
9	8 yr 5 mo	3 mo	30	Left temporal	Left hippocampal sclerosis	0.65	0.58	Left	Left temporal hypoperfusion
10	7 yr 10 mo	6 yr 10 mo	60	Left temporal	Left hippocampal atrophy	0.92	0.48	Left	Left temporal hypoperfusion
11	11 yr 8 mo	2 yr	30	Left temporal	Left hippocampal sclerosis with temporal gliosis	0.77	0.60	Left	Left temporal hypoperfusion
12	14 yr 4 mo	18 mo	1	Left temporal	Left hippocampal sclerosis	0.63	0.48	Left	Left temporal hypoperfusion
13	13 yr 4 mo	15 mo	2	Left temporal	Left hippocampal sclerosis	0.72	0.82	None	Left temporal hypoperfusion
14	10 yr 7 mo	15 mo	10	Left temporal	Left hippocampal sclerosis	0.66	0.56	Left	Left parietal hypoperfusion, temporal lobes symmetrical

Where two sets of  $^1\text{H}$  MRS and  $^{99}\text{Tc}^m$  HMPAO SPECT data shown, these refer to the first and repeated scans.

MR, magnetic resonance; MRS, magnetic resonance spectroscopy; HMPAO, hexamethylpropyleneamine oxine; SPECT, single-photon-emission computed tomography; NAA, *N*-acetylaspartate.

Five children in this study had unilaterally abnormal ratios of NAA/(Cho + Cr); in all cases, this was on the side ipsilateral to the seizure focus. Seven children had a bilaterally low value for NAA/(Cho + Cr); this was correctly lateralising in four and incorrectly lateralising in none. NAA/(Cho + Cr) ratios were normal on both sides in two children.

Three children underwent repeated  $^1\text{H}$  MRS investigation 2 years after their first examination; two were undergoing reassessment for epilepsy surgery (patients 2 and 4), and one (patient 7) had been seizure free on medication for the 2 years. Patients 2 and 4 on the repeated examination had unilaterally low NAA/(Cho + Cr) that was correctly lateralising; previously they had been bilaterally low and nonlateralising. Patient 7 again had a unilaterally low NAA/(Cho + Cr) that was correctly lateralising as before.

### Interictal SPECT

Figure 3 shows the interictal  $^{99}\text{Tc}^m$  HMPAO SPECT of patient 11 and demonstrates hypoperfusion of the left

temporal lobe. Ten of the 14 children showed hypoperfusion of one temporal lobe; in all 10, this was ipsilateral to the clinical/EEG focus. Four children showed no asymmetry of perfusion of the anterior temporal lobes; of these, two showed hypoperfusion of one region outside the temporal lobe. In one, this was on the same side as the clinical/EEG focus, and in one, the contralateral side. The remaining two children demonstrated no abnormality on interictal  $^{99}\text{Tc}^m$  HMPAO SPECT.

The mean age of onset of epilepsy was the same (2 years 10 months) in both the group demonstrating ipsilateral hypoperfusion (range, 3 months to 9 years) and the group with no asymmetry of perfusion (range, 8 months to 14 years) ( $p = 0.99$ ). The group with asymmetry had a shorter mean duration of epilepsy (8 years 1 month; range, 1 to 12 years 10 months) compared with the no-asymmetry group (9 years 10 months; range, 2 years 11 months to 14 years 11 months), but again there was not a significant difference ( $p = 0.43$ ). Mean seizure frequency in the group demonstrating asymmetry was 20/month (range, 1–60) compared with 65/month

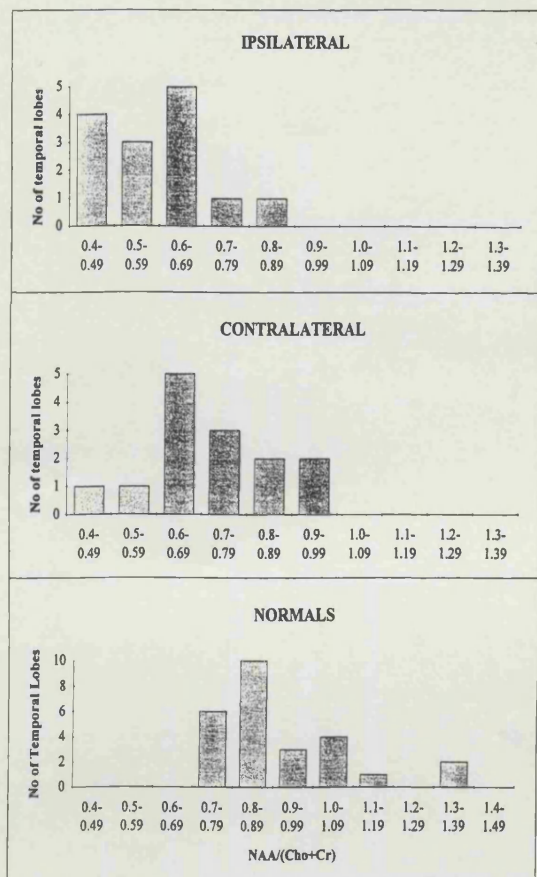


FIG. 2. N-Acetylaspartate/[choline + (creatine + phosphocreatine)] [NAA/(Cho + Cr)] ratios vs. number of temporal lobes for the children with temporal lobe epilepsy, grouped as ipsilateral and contralateral to the seizure focus, compared with those of 13 normal subjects.

(range, 2–240) in the group with no asymmetry ( $p = 0.50$ ).

The three children who had undergone repeated  $^1\text{H}$  MRS also underwent repeated interictal SPECT examination. Patients 2 and 4 on repeated examination had unilateral temporal hypoperfusion concordant with the seizure focus; neither patient had previously demonstrated temporal asymmetry. Patient 7 had only marginal unilateral temporal hypoperfusion that did not reach 10% significance; she previously had demonstrated definite hypoperfusion of that temporal lobe concordant with the seizure focus.

#### Comparison of interictal SPECT with $^1\text{H}$ MRS

Figure 4 shows the initial SPECT and  $^1\text{H}$  MRS data for the 14 children grouped according to whether SPECT showed hypoperfusion of one temporal lobe or no asymmetry of perfusion of the temporal lobes. In eight of the 10 children showing unilateral temporal hypoperfusion on interictal SPECT, the NAA/(Cho + Cr) was abnormally low on the ipsilateral side and lower than the contralateral side by  $>0.05$  (i.e., it was lateralising to the hypoperfused side). This included six children with a left

temporal focus and two children with a right temporal focus. Two children who had unilateral temporal hypoperfusion (patients 6 and 13) had bilaterally normal NAA/(Cho + Cr) ratios. Of the four children who showed no asymmetry in perfusion between the temporal lobes, three had bilaterally abnormal NAA/(Cho + Cr) ratios that were not lateralising (see Fig. 5), and one, bilaterally abnormal ratios that were correctly lateralising.

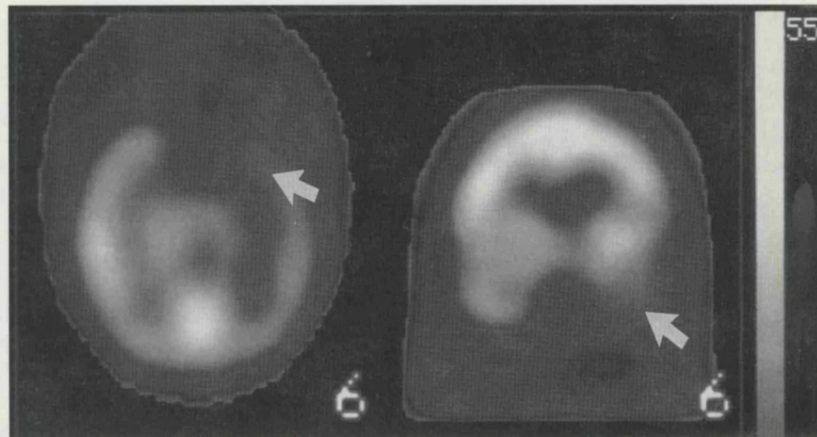
In the three children who had undergone repeated examinations, the two who had previously demonstrated symmetrical perfusion of the temporal lobes, with bilaterally abnormal NAA/(Cho + Cr) ratios, now showed unilateral  $^1\text{H}$  MRS abnormalities with concordant hypoperfusion of the temporal lobe on that side. The third child initially demonstrated clear perfusion asymmetry on an initial  $^{99}\text{Tc}^m$  HMPAO SPECT examination but only marginal hypoperfusion of that temporal lobe on repeated scanning. There had been some recovery of NAA/(Cho + Cr) on that side; the ratio was 0.47 on the first occasion and 0.67 after a 2-year seizure-free period.

#### DISCUSSION

This study of a group of 14 children with intractable temporal lobe epilepsy has demonstrated hypoperfusion of one temporal lobe ipsilateral to the seizure focus in 10 (71%) of the children, with abnormalities seen in a region outside the temporal lobe in two of the remaining four children. Eight of the 10 children in this study with ipsilateral temporal hypoperfusion had an abnormally low NAA/(Cho + Cr) ratio that was lateralising to the same side; the other two children had bilaterally normal NAA/(Cho + Cr) ratios. Our study therefore demonstrates a good correlation between unilateral temporal abnormalities on  $^{99}\text{Tc}^m$  HMPAO SPECT and lateralising abnormalities in NAA/(Cho + Cr) on  $^1\text{H}$  MRS. As discussed previously, it is commonly accepted that a reduction in NAA reflects neuronal loss or damage, and the increase in the Cr and Cho signals that has also been observed may reflect gliosis. We therefore conclude that in these children, there are areas of neuronal loss, dysfunction, reactive astrocytosis, or a combination of these, that are associated with areas of hypoperfusion as detected by  $^{99}\text{Tc}^m$  HMPAO SPECT, although we are not proposing that there is just one mechanistic basis for the hypoperfusion seen on SPECT. That both techniques have fairly modest spatial resolution suggests that the abnormalities detected by the two techniques are widespread and not, for example, restricted specifically to the hippocampus.

Interictal studies using  $^{18}\text{F}$ fluoro-2-deoxy-D-glucose ( $^{18}\text{FDG}$ ) positron emission tomography (PET) in temporal lobe epilepsy have shown focal hypometabolism in 65–80% of patients (1,32,33). Comparative studies between  $^{18}\text{FDG}$  PET and  $^{99}\text{Tc}^m$  HMPAO SPECT have

**FIG. 3.** Axial (left) and coronal (right) interictal  $^{99}\text{Tc}^m$  hexamethylpropyleneamine oxime (HMPAO) single-photon-emission computed tomography (SPECT) images of patient 11. There is hypoperfusion of the left temporal lobe (arrow). The *N*-acetylaspartate/[choline + (creatine + phosphocreatine)] [NAA/(Cho + Cr)] ratio of the mesial temporal lobe on the right was 0.77 and on the left, 0.6 (lateralising to the left side as detailed in Methods).



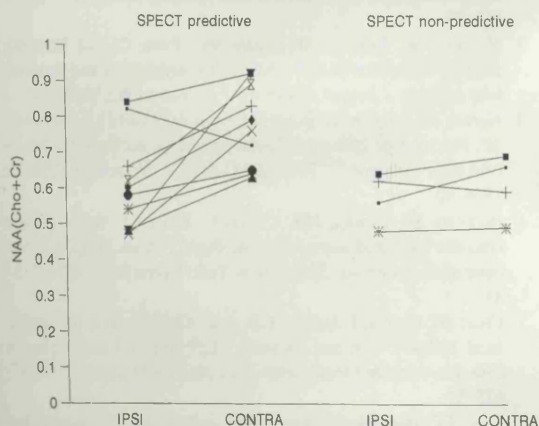
shown that where abnormalities of perfusion are demonstrated by SPECT, they correlate with areas of hypometabolism as detected by PET, but that abnormalities are seen less frequently with SPECT than with PET (33,34). Abnormalities of oxidative metabolism may be expected to influence HMPAO uptake. The lack of exact correlation between PET and SPECT has been attributed to the poor spatial resolution of SPECT (34). One study, however, has correlated the degree of hypometabolism seen on PET with pathologically proven neuronal loss (35), and this would support our observed relation between hypoperfusion and MRS abnormalities.

Absolute quantitation can be used in analysis of PET data, and bilateral abnormalities of the temporal lobe can therefore be detected (35). Our SPECT studies, however, rely on side-to-side comparisons and may therefore be expected to be insensitive to perfusion abnormalities when there is a similar degree of pathology in the two

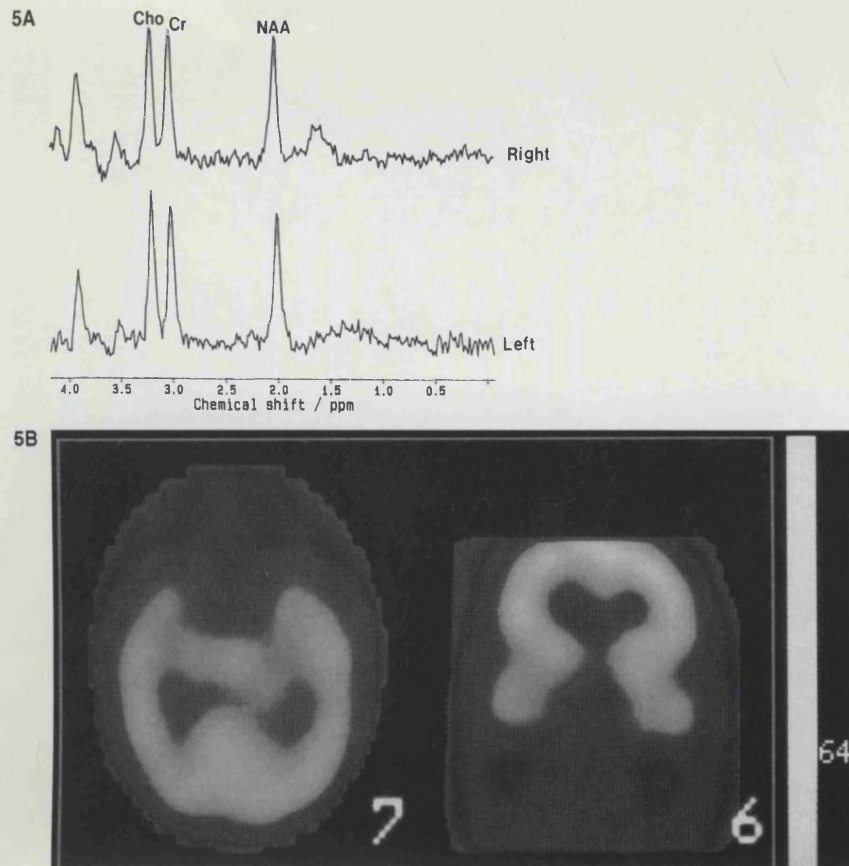
temporal lobes. Our findings in this study, although based on a small number of patients, nevertheless are consistent with this; none of the three children with NAA/(Cho + Cr) ratios that were bilaterally abnormal and nonlateralising showing unilateral temporal hypoperfusion on interictal SPECT.

It is of obvious interest to determine whether cases with bilateral abnormalities on  $^1\text{H}$  MRS also demonstrated bilateral temporal lobe hypoperfusion on  $^{99}\text{Tc}^m$  HMPAO SPECT. To this end, comparison of temporal perfusion with that in other areas of the brain has been attempted. Comparisons with the cerebellum are unhelpful in epilepsy because of the well-recognised crossed cerebellar perfusion (1,36). The calcarine cortex also has been suggested in adults, but there is a lack of normative data in children. The only normative data that compare perfusion of the temporal lobes with that in the rest of the brain were obtained from children with a neurologic history, although apparently normal at the time of the scans (37). It was therefore not possible in this study to determine whether there was relative bitemporal hypoperfusion in children with no side-to-side asymmetry of the anterior temporal regions on  $^{99}\text{Tc}^m$  HMPAO SPECT.

Repeated SPECT and  $^1\text{H}$  MRS examinations in three patients demonstrated changes over time, the findings from the two techniques being consistent with each other on both the initial and the repeated scans. Two children underwent the studies in the process of reassessment for surgery. These two girls had shown no asymmetry in the temporal lobe perfusion on the first SPECT examination and bilaterally low NAA/(Cho + Cr) ratios that were nonlateralising. The repeated SPECT studies demonstrated unilateral hypoperfusion of the temporal lobe concordant with the seizure focus, and  $^1\text{H}$  MRS showed a unilaterally low NAA/(Cho + Cr) on that side. The ratio on the side contralateral to the seizure focus had normalised. In the child who had been seizure free for 2 years, the unilateral temporal hypoperfusion that had been clearly seen was not so striking, and there had been some



**FIG. 4.** Comparison of the *N*-acetylaspartate/[choline + (creatine + phosphocreatine)] [NAA/(Cho + Cr)] ratios from the temporal lobes ipsilateral and contralateral to the seizure focus of the 14 children with temporal lobe epilepsy, grouped according to whether the single-photon-emission computed tomography (SPECT) showed hypoperfusion of one temporal lobe (predictive) or no asymmetry of perfusion of the temporal lobes (nonpredictive).



**FIG. 5. A:**  $^1\text{H}$  magnetic resonance spectra of the left and right temporal lobes of patient 3. The *N*-acetylaspartate/[choline + (creatine + phosphocreatine)] NAA/(Cho + Cr) ratio is 0.49 on the left and 0.48 on the right (bilaterally low and nonlateralising as defined in Methods). **B:** Axial (left) and coronal (right) interictal  $^{99\text{m}}\text{Tc}$  hexamethylpropyleneamine oxime (HMPAO) single-photon-emission computed tomography (SPECT) images of patient 3. There is no asymmetry of perfusion of the temporal lobes.

recovery in the NAA/(Cho + Cr) on that side. Previous data from our larger group of children with temporal lobe epilepsy suggested that the changes seen in  $^1\text{H}$  MRS ipsilateral to the seizure focus involve a reduction in NAA and therefore neuronal loss or dysfunction, whereas the changes in the contralateral temporal lobe was predominantly caused by an increase in Cho and Cr, possibly as a result of reactive gliosis (26). The number of children reported here who have undergone repeated examinations is too small to make any comments on the signal intensities of individual compounds. It may be speculated, however, that recovery on the contralateral side may be the result of a reduction in gliosis rather than of neuronal/axonal recovery.

In summary, this study has shown abnormalities both in interictal  $^{99\text{m}}\text{Tc}$  HMPAO SPECT studies and in  $^1\text{H}$  MRS of the mesial temporal lobes in a group of children with intractable temporal lobe epilepsy. On the basis of comparisons between the two techniques, we conclude that these abnormalities represent areas of neuronal loss or damage, or reactive astrocytosis, or both, and that these areas are associated with focal hypoperfusion. Therefore if there is minimal damage in the form of neuronal damage or astrocytosis, or if there is bilateral damage to a similar degree on both sides, interictal  $^{99\text{m}}\text{Tc}$  HMPAO SPECT may in such cases be nonlateralising.

**Acknowledgment:** We thank Action Research and the Wellcome Trust for their support.

## REFERENCES

1. Harvey AS, Bowe JM, Hopkins IJ, Shield LK, Cook DJ, Berkovic SF. Ictal  $^{99\text{m}}\text{Tc}$ -HMPAO single photon emission computed tomography in children with temporal lobe epilepsy. *Epilepsia* 1993;34: 869-77.
2. Newton MR, Berkovic SF, Austin MC, Rowe CC, McKay WJ, Bladin PF. Postictal switch in blood flow distribution and temporal lobe seizures. *J Neurol Neurosurg Psychiatry* 1992;55:891-4.
3. Harvey AS, Hopkins IJ, Bowe JM, Cook DJ, Shield LK, Berkovic SF. Frontal lobe epilepsy: clinical seizure characteristics and localization with ictal  $^{99\text{m}}\text{Tc}$ -HMPAO SPECT. *Neurology* 1993;43: 1966-80.
4. Berkovic SF, Newton MR, Chiron C, Dulac O. Single photon emission computed tomography. In: Engel J Jr, ed. *Surgical treatment of the epilepsies*. 2nd ed. New York: Raven Press, 1993:233-43.
5. Cross JH, Gordon I, Jackson GD, et al. Children with intractable focal epilepsy: ictal and interictal  $^{99\text{m}}\text{Tc}$  HMPAO single photon emission computed tomography. *Dev Med Child Neurol* 1995;37: 673-81.
6. Rowe CC, Berkovic SF, Austin MC, et al. Visual and quantitative analysis of interictal SPECT with technetium-99m-HMPAO in temporal lobe epilepsy. *J Nucl Med* 1991;32:1688-94.
7. Jack CR Jr, Mullan BP, Sharbrough FW, et al. Intractable nonlesional epilepsy of temporal lobe origin: lateralization by interictal SPECT vs MRI. *Neurology* 1994;44:829-36.
8. Uvebrant P, Bjure J, Hedstrom A, Ekholm S. Brain single photon emission computed tomography (SPECT) in neuropaediatrics. *Neuropaediatrics* 1991;22:3-9.

9. Hajek M, Siegel AM, Haldemann R, von Schulthess GK, Wieser HG. Value of HM-PAO SPECT in selective temporal lobe surgery for epilepsy. *J Epilepsy* 1991;4:43-51.
10. Costa DC, Ell PJ, Cullum ID, Jarritt PH. The in vivo distribution of  $^{99m}\text{Tc}$ -HMPAO in normal man. *Nucl Med Commun* 1986;7:647-58.
11. Costa DC, Jones BE, Steiner TT. Relative  $^{99m}\text{Tc}$  HMPAO and  $^{113}\text{Sn}$  microspheres distribution in dog brain. *Nucl Medizin (Suppl)* 1987;23:498-500.
12. Costa DC, Lui D, Sinha AK, Jarritt PH, Ell PJ. Intracellular localisation of  $^{99m}\text{Tc}$ -*d,l*-HMPAO and  $^{201}\text{Tl}$ -DDC in rat brain. *Nucl Med Commun* 1989;10:459-66.
13. Ahn CS, Tow DE, Yu CC, Greene RW. Effect of metabolic alterations on the accumulation of technetium-99m-labeled *d,l*-HMPAO in slices of rat cerebral cortex. *J Cerebr Blood Flow Metab* 1994;14:324-31.
14. Suess E, Malessa S, Ungersbock K, et al. Technetium-99m-*d,l*-hexamethylpropyleneamine oxime (HMPAO) uptake and glutathione content in brain tumors. *J Nucl Med* 1991;32:1675-81.
15. Neirinckx RD, Burke JF, Harrison RC, Forster AM, Andersen AR, Lassen NA. The retention mechanism of technetium-99m-HMPAO: intracellular reaction with glutathione. *J Cerebral Blood Flow Metab* 1988;8:s4-12.
16. Suess E, Huck S, Reither H, Hortnagl H, Angelberger P. Uptake mechanism of technetium-99m-*d,l*-HMPAO in cell cultures of the dissociated postnatal rat cerebellum. *J Nucl Med* 1992;33:108-14.
17. Koller JK, Zaczek R, Coyle JT. *N*-Acetyl-aspartyl-glutamate: regional levels in rat brain and the effects of brain lesions as determined by a new HPLC method. *J Neurochem* 1984;43:1136-42.
18. Moffett JR, Nambodiri MA, Cangro CB, Neale JH. Immunohistochemical localization of *N*-acetylaspartate in rat brain. *Neuroreport* 1991;2:131-4.
19. Urenjak J, Williams SR, Gadian DG, Noble M. Specific expression of *N*-acetylaspartate in neurons, oligodendrocyte-type-2 astrocyte progenitors and immature oligodendrocytes in vitro. *J Neurochem* 1992;59:55-61.
20. Urenjak J, Williams SR, Gadian DG, Noble M. Proton nuclear magnetic resonance spectroscopy unambiguously identifies different neural cell types. *J neurosci* 1993;13:981-9.
21. Hugg JW, Laxer KD, Matson GB, Maudsley AA, Weiner MW. Neuron loss localizes human focal epilepsy by in vivo proton MR spectroscopic imaging. *Ann Neurol* 1993;34:788-94.
22. Cendes F, Andermann F, Preul MC, Arnold DL. Lateralization of temporal lobe epilepsy based on regional metabolic abnormalities in proton magnetic resonance spectroscopic images. *Ann Neurol* 1994;35:211-6.
23. Ng TC, Comair YG, Xue M, et al. Temporal lobe epilepsy: pre-surgical localisation with proton chemical shift imaging. *Radiology* 1994;193:465-72.
24. Gadian DG, Connelly A, Duncan JS, et al.  $^1\text{H}$  magnetic resonance spectroscopy in the investigation of intractable epilepsy. *Acta Neurol Scand (suppl)* 1994;152:116-21.
25. Connelly A, Jackson GD, Duncan JS, King MD, Gadian DG. Magnetic resonance spectroscopy in temporal lobe epilepsy. *Neurology* 1994;44:1411-7.
26. Cross JH, Connelly A, Jackson GD, Johnson CL, Neville BGR, Gadian DG. Proton magnetic resonance spectroscopy in children with temporal lobe epilepsy. *Ann Neurol* 1996;39:107-13.
27. Gadian DG, Isaacs EB, Cross JH, et al. Lateralization of brain function in childhood revealed by magnetic resonance spectroscopy. *Neurology* 1996;46:974-7.
28. Mugler JP, Brookeman JR. Three-dimensional magnetization-prepared rapid gradient-echo imaging (3-D MPRAGE). *Magn Reson Med* 1990;15:152-7.
29. Klose U. In vivo proton spectroscopy in the presence of eddy currents. *Magn Reson med* 1990;14:26-30.
30. Paediatric Task Group European Association Nuclear Medicine Members: A. Piepsz (Chairman), K. Hahn, I. Roca, G. Ciofetta, G. Toth, I. Gordon, J. Kolinska, J. Gwidet. A radiopharmaceuticals schedule for imaging in paediatrics. *Eur J Nucl Med* 1990;17:127-9.
31. Jackson GD, Berkovic SF, Duncan JS, Connelly A. Optimizing the diagnosis of hippocampal sclerosis using MR imaging. *AJNR Am J Neuroradiol* 1993;14:753-62.
32. Engel J Jr, Kuhl DE, Phelps ME, Mazziotta JC. Interictal cerebral glucose metabolism in partial epilepsy and its relation to EEG changes. *Ann Neurol* 1982;12:510-7.
33. Ryvlin P, Philippon B, Cinotti L, Froment JC, Le Bars D, mauguere F. Functional neuroimaging strategy in temporal lobe epilepsy: a comparative study of  $^{18}\text{F}$ FDG-PET and  $^{99m}\text{Tc}$ -HMPAO-SPECT. *Ann Neurol* 1992;31:650-6.
34. Stefan H, Pawlik G, Bocher-Schwarz HG, et al. Functional and morphological abnormalities in temporal lobe epilepsy: a comparison of interictal and ictal EEG, CT, MRI, SPECT and PET. *J Neurol* 1987;234:377-84.
35. Engel J Jr, Brown WJ, Kuhl DE, Phelps ME, Mazziotta JC, Crandall PH. Pathological findings underlying focal temporal lobe hypometabolism in partial epilepsy. *Ann Neurol* 1982;12:518-28.
36. Marks DA, Kutz A, Hoffer P, Spencer SS. Localization of extra-temporal epileptic foci during ictal single photon emission computed tomography. *Ann Neurol* 1992;31:250-5.
37. Denays R, Ham H, Tondeur M, Piepsz A, Noel P. Detection of bilateral and symmetrical anomalies in technetium-99m-HMPAO brain SPECT studies. *J Nucl Med* 1992;33:485-90.