



## Case report

## Stimulated single-fiber electromyography (sSFEMG) in Lambert-Eaton syndrome



Vincenzo Todisco<sup>a,1</sup>, Giovanni Cirillo<sup>a,b,\*,1</sup>, Rocco Capuano<sup>a</sup>, Alessandro d'Ambrosio<sup>a</sup>,  
Gioacchino Tedeschi<sup>a</sup>, Antonio Gallo<sup>a,\*</sup>

<sup>a</sup> I Division of Neurology and Neurophysiopathology, University of Campania "Luigi Vanvitelli", Naples, Italy

<sup>b</sup> Division of Human Anatomy – Neuronal Networks Morphology Lab, Dept. of Mental, Physical Health and Preventive Medicine, University of Campania "Luigi Vanvitelli", Naples, Italy

## ARTICLE INFO

## Article history:

Received 18 July 2018

Received in revised form 24 July 2018

Accepted 28 July 2018

Available online 13 August 2018

## Keywords:

Lambert-Eaton myasthenic syndrome (LEMS)

Stimulated single fiber electromyography (sSFEMG)

Neuromuscular jitter

## ABSTRACT

**Objective:** To report the clinical features and the neurophysiological approach of a patient with Lambert-Eaton myasthenic syndrome (LEMS), highlighting the diagnostic role of the stimulated single fiber electromyography (sSFEMG).

**Case report:** A 60-year-old woman presenting with the LEMS triad (proximal and axial weakness, autonomic dysfunction and areflexia) was evaluated by neurophysiological tests (electroneuromyography, repetitive stimulation test (TSR), voluntary and stimulated SFEMG). We reported: 1) increase of compound muscle action potential (CMAP) amplitude (>60%) following brief isometric exercise compared to the rest (baseline); 2) decremental/incremental response of CMAP amplitude at low- (3 Hz) and high-frequency (30 Hz) repetitive stimulation test (RST), respectively; 3) increased neuromuscular jitter and blocking at voluntary single-fiber electromyography (vSFEMG); 4) stimulation rate-dependent reduction of the neuromuscular jitter and blocking at sSFEMG. Diagnosis was confirmed by serological demonstration of circulating voltage gated calcium channels (VGCC) antibodies.

**Significance:** The present case highlights the role of the sSFEMG in the diagnosis of LEMS, underling the stimulation rate-dependency of both neuromuscular jitter and blocks.

© 2018 International Federation of Clinical Neurophysiology. Published by Elsevier B.V. This is an open access article under the CC BY-NC-ND license (<http://creativecommons.org/licenses/by-nc-nd/4.0/>).

## 1. Introduction

The Lambert-Eaton myasthenic syndrome (LEMS) is a rare autoimmune disease of the neuromuscular transmission involving the presynaptic voltage-gated calcium channels (VGCCs) (Schoser et al., 2017). In most cases (60%), LEMS represents a paraneoplastic syndrome associated with small cell lung cancer, in the remaining an idiopathic, autoimmune disease, with frequent overlap with other dysimmune syndromes, including myasthenia gravis (MG) (Oh and Sher, 2005).

The typical clinical triad in LEMS consists of weakness (predominantly affecting proximal muscles), autonomic dysfunctions (including xerostomia, pupillomotor dysfunction, constipation,

impaired sweating) and hypo/areflexia (Kesner et al., 2018). Strength and deep tendon reflexes should be tested at baseline and soon after exercise, in order to detect the well-known phenomenon of the "post-exercise facilitation", a short-lasting improvement of both reflexes and muscle strength immediately after muscle contraction (Oh et al., 2005). LEMS patients typically present a proximal lower > upper limb weakness that progressively involves axial, oculomotor and pharyngo-laryngeal muscles, thus leading to gait and upright alteration, ocular and bulbar symptoms in severely affected patients (Hülsbrink and Hashemolhosseini, 2014).

Diagnosis is confirmed by detection of circulating VGCC antibodies and neurophysiological study, showing: 1) significant increase of compound muscle action potential (CMAP) amplitude (>60%) following brief isometric exercise compared to the rest (baseline), 2) decremental response of CMAP amplitude at low-frequency (LF) (3 Hz) repetitive stimulation test (RST), 3) incremental response of CMAP amplitude at high-frequency (HF) RST (10, 20, and 50 Hz), and 4) increased neuromuscular jitter at single-fiber electromyography (SFEMG).

\* Corresponding authors at: Division of Human Anatomy – Neuronal Networks Morphology Lab, Dept. of Mental, Physical Health and Preventive Medicine, University of Campania "Luigi Vanvitelli", via L Armanni 5, 80138 Naples, Italy (G. Cirillo). I Division of Neurology and Neurophysiopathology, University of Campania "Luigi Vanvitelli", Piazza Miraglia, 2, 80138 Naples, Italy (A. Gallo).

E-mail addresses: [giovanni.cirillo@unicampania.it](mailto:giovanni.cirillo@unicampania.it) (G. Cirillo), [antonio.gallo@unicampania.it](mailto:antonio.gallo@unicampania.it) (A. Gallo).

<sup>1</sup> These authors equally contributed to this work.

SFEMG is a neurophysiological test to study the neuromuscular junction (Stålberg and Sanders, 2009). Stimulated SFEMG (sSFEMG), in particular, has the following advantages compared to voluntary SFEMG (vSFEMG): 1) allows the study of the neuromuscular junction without the voluntary activation; 2) allows stimulation rate control (Trontelj and Stålberg, 1991); 3) requires only a limited patient cooperation; 4) is far more comfortable.

## 2. Case report

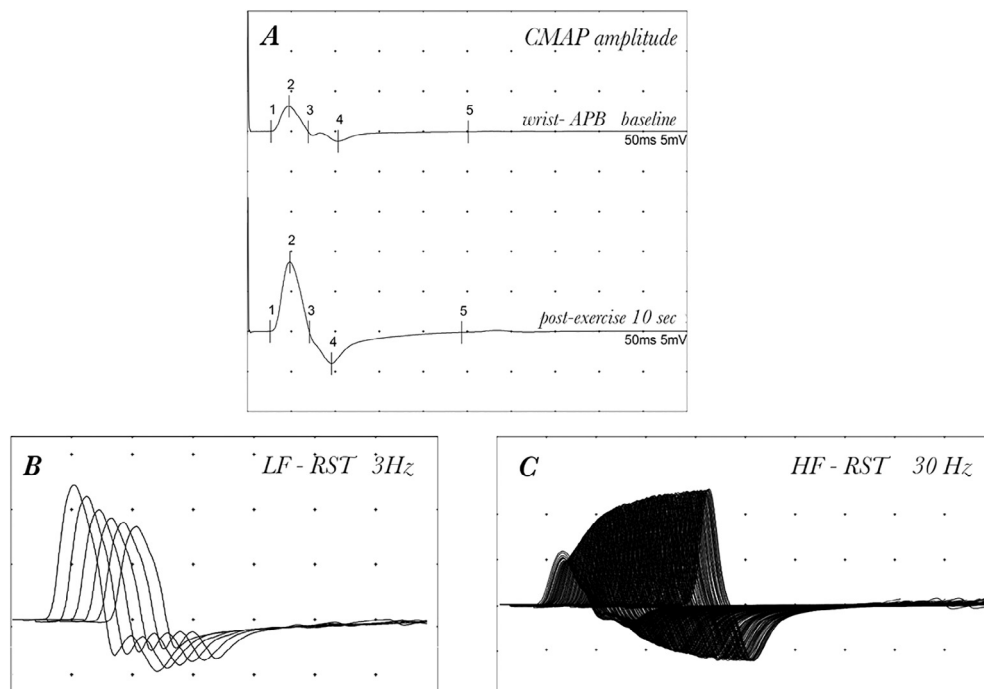
We report the case of a 60-year-old woman presenting with proximal and axial weakness, waddling gait and bilateral ptosis. After consultation with her general practitioner, a needle electromyography (EMG) was performed and showed early recruitment, polyphasic motor unit potentials (MUPs) with small amplitudes and short durations (SASD MUPs), absence of resting activity, suggesting a diagnosis of non-inflammatory myopathy. At this point, the patient was referred to our Division of Neurology for further diagnostic procedures. A more detailed medical history revealed that patient was also complaining of xerostomia, xerophthalmia and constipation, symptoms compatible with an autonomic dysfunction. At neurological evaluation, deep tendon reflexes were absent at rest but showed the post-exercise facilitation phenomenon. All these clinical findings were suggestive of a pre-synaptic myasthenic syndrome. Extended neurophysiological testing revealed an increase of the median nerve CMAP basal amplitude after brief (10 s) isometric contraction (4.4 → 12.7 mV, increase of 288%) (Fig. 1A), a decremental response of CMAP amplitude at LF-RST (3 Hz) (−22.7%) and incremental response at HF-RST (30 Hz) (227%) (Fig. 1B–C), recording from right abductor pollicis brevis (APB). At rest, needle EMG in the right biceps showed early recruitment with a reduced firing rate (2:1), normal activation, SASD and polyphasic MUPs. This pattern is called pseudomyopathic because of its normalization after brief muscle contraction, showing normal recruitment, firing rate (5:1) and

MUPs parameters. To better characterize the neurophysiology of this syndrome, we performed both vSFEMG and sSFEMG in the right extensor digitorum communis (EDC) muscle using a concentric needle EMG with the smallest recording area (0.03 mm<sup>2</sup>). We used a Synergy EMG machine (Synopo) with automatic jitter, MCD and percentage of blocking analysis. For sSFEMG, three different rates of intramuscular axonal stimulation were used (10, 20 and 50 Hz). Inter-potential intervals represent the difference in latency between the artifact stimuli and the action potential, therefore representing the variability of the end-plate (Chaudhry et al., 1991). Blocking was expressed as a percentage of the number of stimulations that failed to evoke a potential over the total number of stimulations.

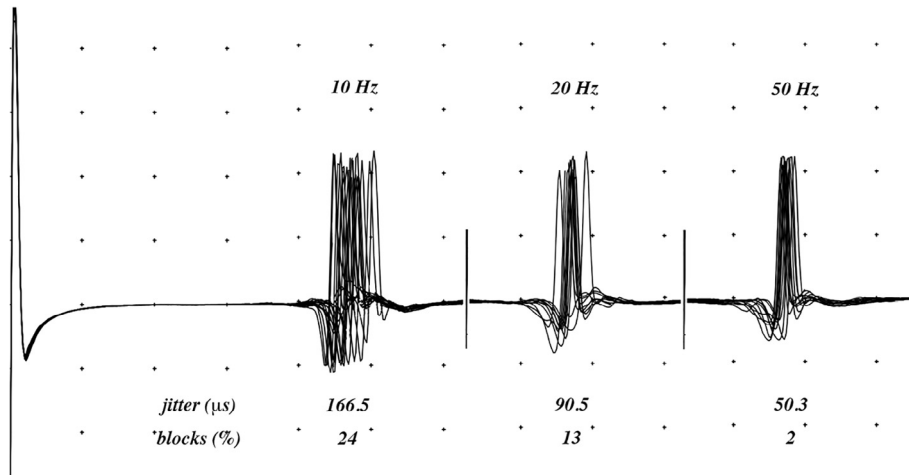
vSFEMG showed a non-specific increased duration of the neuromuscular jitter (mean jitter and MCD 97.9 μs, n.v. <30) with blocks in the 20% of the analyzed fibers, as also typically observed in MG. In contrast, sSFEMG showed the typical rate-dependent reduction of the neuromuscular jitter and blocking: neuromuscular jitter and the percentage of blocks were significantly reduced at the increase of the stimulation rate (jitter: 166.5 → 90.5 → 50.3 μs; percentage of blocks: 24 → 13 → 2% at 10, 20, and 50 Hz, respectively) (Fig. 2). Diagnosis was confirmed by serological demonstration of circulating VGCC antibodies (265.39 pmol/L, n.v. <80).

## 3. Discussion

This case report highlights the importance of the correct execution and interpretation of the neurophysiological evaluation, suggesting that pseudomyopathic pattern at EMG should be correlated with other clinical (e.g. weakness and deep tendon reflexes at rest and after exercise) and neurophysiological findings (fibrillations, complex repetitive discharges) (Komatsu et al., 2013) to differentiate myasthenic from myopathic syndrome. Recently, SASD MUPs and marked type II fiber atrophy mimicking myopathy have been also reported in LEMS patients (Crone et al., 2013), thus



**Fig. 1.** Neurophysiological tests in LEMS. Representative neurophysiological diagnostic approach in patients with LEMS. (A) the baseline low amplitude of the median nerve compound muscle action potential (CMAP) from right abductor pollicis brevis (APB) was significantly increased after brief isometric exercise; (B) in the same muscle, low- (LF) and (C) high-frequency (HF) repetitive stimulation test (RST) showed significant decremental (B) and incremental response (C), respectively.



**Fig. 2.** Frequency-dependent neuromuscular jitter in LEMS. Stimulated single-fiber electromyography (sSFEMG) demonstrated a frequency-dependent reduction of the neuromuscular jitter values at the increase of the stimulation rate.

making differential diagnosis even more complex. sSFEMG represents, therefore, a very helpful approach in the differential diagnosis of LEMS thanks to the peculiar rate-dependence of neuromuscular jitter that is not observed in myopathies.

In conclusion, sSFEMG findings in LEMS underlie the stimulation rate-dependency of both neuromuscular jitter and blocks, reflect the basic pathophysiology of this neuromuscular syndrome, thus making this technique very specific and, therefore, clinically useful for an early and accurate diagnosis.

#### Acknowledgments

The authors thank Dr. Silvana D'Amico, a neurophysiology technician, for her assistance.

This research did not receive any financial support from commercial or non-profit companies.

#### Conflict of interest

The authors declare that they have no conflicts of interest and nothing to disclose.

#### References

- Chaudhry, V., Watson, D.F., Bird, S.J., Cornblath, D.R., 1991. Stimulated single-fiber electromyography in Lambert-Eaton myasthenic syndrome. *Muscle Nerve* 14 (12), 1227–1230.
- Crone, C., Christiansen, I., Vissing, J., 2013. Myopathic EMG findings and type II muscle fiber atrophy in patients with Lambert-Eaton myasthenic syndrome. *Clin. Neurophysiol.* 124 (9), 1889–1892.
- Hülsbrink, R., Hashemolhosseini, S., 2014. Lambert-Eaton myasthenic syndrome – diagnosis, pathogenesis and therapy. *Clin. Neurophysiol.* 125 (12), 2328–2336.
- Kesner, V.G., Oh, S.J., Dimachkie, M.M., Barohn, R.J., 2018. Lambert-Eaton myasthenic syndrome. *Neurol. Clin.* 36 (2), 379–394.
- Komatsu, T., Bokuda, K., Shimizu, T., Komori, T., Koide, R., 2013. Pseudomyopathic changes in needle electromyography in Lambert-Eaton myasthenic syndrome. *Case Rep. Neurol. Med.* 2013, 369278.
- Oh, S.J., Sher, E., 2005. MG and LEMS overlap syndrome: case report with electrophysiological and immunological evidence. *Clin. Neurophysiol.* 116 (5), 1167–1171.
- Oh, S.J., Kurokawa, K., Claussen, G.C., Ryan Jr, H.F., 2005. Electrophysiological diagnostic criteria of Lambert-Eaton myasthenic syndrome. *Muscle Nerve* 32, 515–520.
- Schoser, B., Eymard, B., Datt, J., Mantegazza, R., 2017. Lambert-Eaton myasthenic syndrome (LEMS): a rare autoimmune presynaptic disorder often associated with cancer. *J. Neurol.* 264 (9), 1854–1863.
- Stålberg, E.V., Sanders, D.B., 2009. Jitter recordings with concentric needle electrodes. *Muscle Nerve* 40 (3), 331–339.
- Trontelj, J.V., Stålberg, E., 1991. Single motor end-plates in myasthenia gravis and LEMS at different firing rates. *Muscle Nerve* 14 (3), 226–232.