

CASE REPORT

Consecutive double-level lumbar spondylolysis successfully treated with the double “smiley face” rod method

Makoto Takeuchi^(1,2), Fumitake Tezuka⁽²⁾, Takashi Chikawa⁽¹⁾, Naohito Hibino⁽¹⁾, Yoshinori Takahashi⁽¹⁾, Yuhei Yamasaki⁽¹⁾, Kaori Momota⁽¹⁾, Tatsuhiko Henmi⁽¹⁾, Toru Maeda⁽²⁾, and Koichi Sairyo⁽²⁾

⁽¹⁾Department of Orthopedic Surgery, Tokushima Prefecture Naruto Hospital, Tokushima, Japan, ⁽²⁾Department of Orthopedics, Tokushima University Graduate School, Tokushima, Japan

Abstract : We report a case of double-level lumbar spondylolysis at L4 and L5 that was successfully treated with the double “smiley face” rod method. A healthy 29-year-old man who presented with a 6-year history of chronic low back pain was referred to us for surgical treatment. Plain radiographs and computed tomography of the lumbar spine revealed bilateral pars defects at L4 and L5 without slip or scoliosis. The patient underwent direct repair of the pars defects using the double smiley face rod method at L4 and L5. There were no intraoperative or postoperative complications, and the patient had improved clinically by 1 year after surgery. The low back pain was completely disappeared and visual analog scale was 0. He restarted tennis again as the recreational level. While several techniques for direct repair of lumbar spondylolysis have been described, this is the first report of the double smiley face rod method being used to repair the consecutive double-level lumbar spondylolysis. *J. Med. Invest.* 67:202-206, February, 2020

Keywords : multi-level spondylolysis, smiley face rod method, spine surgery

INTRODUCTION

Lumbar spondylolysis is caused by stress fracture of the pars interarticularis and may lead to a bony defect or spondylolisthesis (1). Sakai *et al.* (2) reviewed 2000 computed tomography (CT) scans for individuals in the general Japanese population and found that the incidence of lumbar spondylolysis was 5.9%, with only 5 cases of multi-level spondylolysis. Lumbar spondylolysis usually occurs at a single level and often affects the L5 pars interarticularis unilaterally or bilaterally. Multi-level lumbar spondylolysis is rare ; however, in the report by Ravichandran, it accounted for low back pain (LBP) in up to 1.48% of cases (3). Few cases of multi-level spondylolysis and its treatment have been reported in the literature, and the best surgical method remains controversial.

The “smiley face” rod method is a technique used for direct repair of a pars defect (4). This case report describes a 29-year-old man with double-level lumbar spondylolysis at L4 and L5 that was successfully treated with the double smiley face rod method, which has not been reported before.

CASE REPORT

A healthy 29-year-old male dental college student presented with a 6-year history of chronic LBP. He had first experienced severe LBP when playing tennis 6 years earlier. He consulted a local doctor and was diagnosed with lumbar spondylolysis. The LBP did not improve despite conservative treatment with non-steroidal anti-inflammatory drugs, wearing a brace, and injection

of local anesthetic into the pars defect. Therefore, he was referred to our hospital for surgical treatment. His only major complaint was LBP on extension of the lumbar spine.

Neurological examination at the first visit revealed no muscle weakness or sensory disturbance and normal deep tendon reflexes in both lower limbs. Femoral and sciatic nerve tension tests were negative. Plain radiographs of the lumbar spine revealed double-level pars defects at L4 and L5 but without any slip or scoliosis. Pars defects, i.e., “Scotty dog” signs, were clearly visible on oblique radiographs (Fig. 1). CT scans revealed pseudoarthrosis of the pars interarticularis bilaterally at L4 and L5 (Fig. 2). T2-weighted magnetic resonance images showed mild (Pfirrmann grade 2) (5) disc degeneration at L4-5 and L5-S1. No sign of slip or central or foraminal stenosis was present in the affected area (Fig. 3). The patient’s LBP resolved completely after infiltration of lidocaine into the pars defects at L4 and L5 ; therefore, the diagnosis was chronic LBP caused by synovitis in the pseudoarthrosis of the pars defects. We elected to repair the L4 and L5 pars defects using the double smiley face rod method.

A conventional posterior midline approach to the lumbar spine was used. A 7-cm midline skin incision was made. The paravertebral muscles were dissected subperiosteally and detached from the vertebral lamina of L4 and L5 while preserving the supraspinous and interspinous ligaments. Pars defects at L4 and L5 cause hypermobility of the affected lamina ; so-called “floating” lamina were confirmed at L4 and L5. After resection of the abnormally increased synovium in the pars defects, we decorticated the posterior aspect of each pars defect using a high-speed burr until bleeding in the decorticated areas was confirmed. Using anatomical landmarks and fluoroscopic guidance, a starting hole for the pedicle screw was burred, the hole was tapped, and multiaxial pedicle screws were inserted bilaterally. A cancellous bone graft was harvested from the iliac crest through the existing midline skin incision. A rod measuring 100 mm in length and bent into a U-shape was placed just caudal to the L4 spinous process by piercing the interspinous ligament at L4-5

Received for publication May 27, 2019 ; accepted September 26, 2019.

Address correspondence and reprint requests to Makoto Takeuchi, MD, Department of Orthopedics, Tokushima Prefecture Naruto Hospital, 32 Otani, Muyacho Kurosaki, Naruto-shi, Tokushima 772-0001, Japan and Fax : +81-88-683-1860.

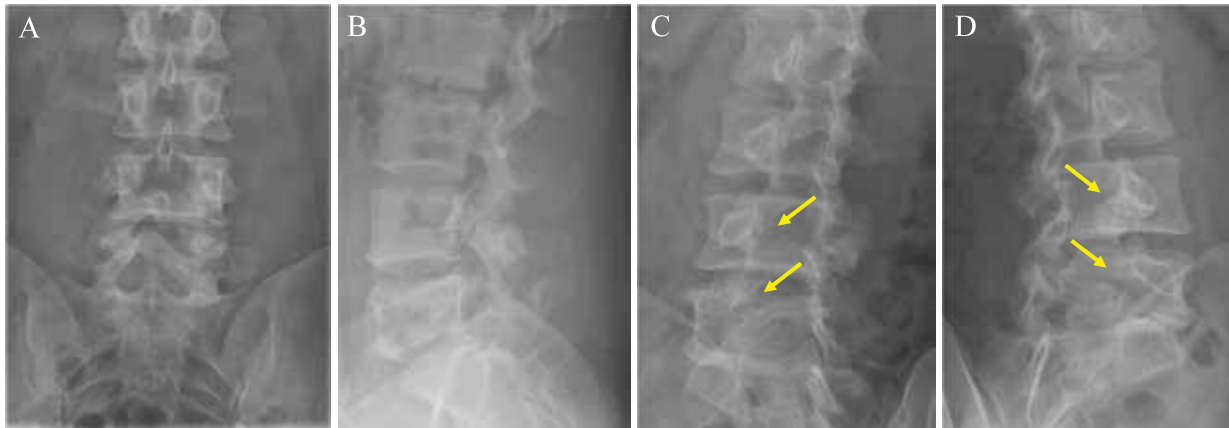


Figure 1. Preoperative anteroposterior (A), lateral (B), right oblique (C), and left oblique (D) radiographs demonstrating bilateral lumbar spondylolysis at L4 and L5 in a 26-year-old man.

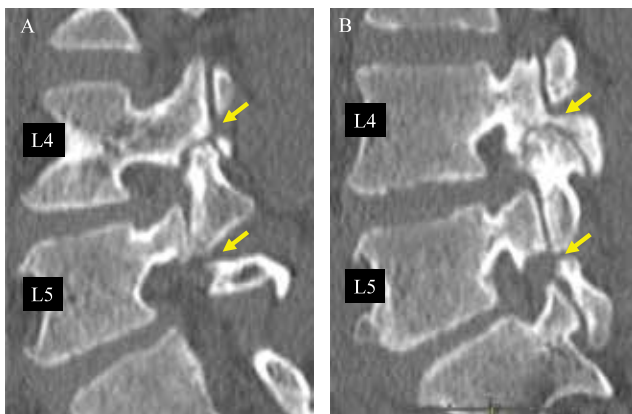


Figure 2. Preoperative right para-sagittal (A) and left para-sagittal (B) computed tomography scans showing pseudoarthrosis of the pars interarticularis bilaterally at L4 and L5.

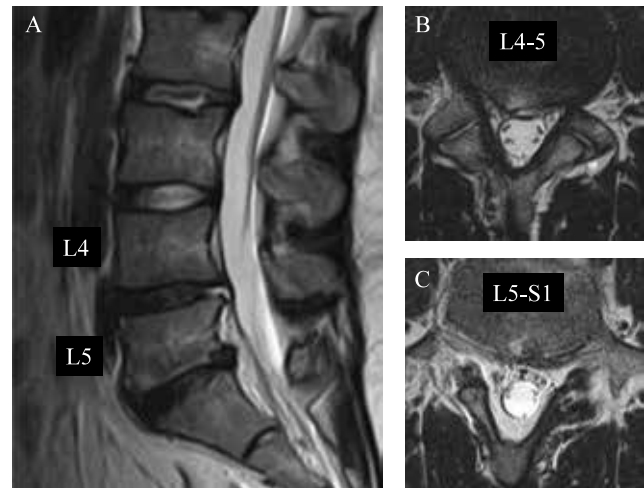


Figure 3. Preoperative sagittal (A) and axial T2-weighted magnetic resonance scans at L4-5 (B) and L5-S1 (C) demonstrating mild disc degeneration at both levels but no evidence of slip and no central or foraminal stenosis.

and attaching it to the heads of the pedicle screws at L4 bilaterally. In order to fix the floating lamina more firmly, we inserted the set screws while applying pressure to the bent rod against the base of the spinous process using a rod pusher. Another bent rod was attached to the pedicle screws at L5 in the same fashion. Finally, bone chips mixed with autograft and hydroxyapatite were implanted at the pars defects at L4 and L5. The wound was closed in a routine manner and a surgical drain was left in place. The intraoperative course was uneventful, with a total operating time of 174 min and an estimated blood loss of 160 ml. Plain radiographs confirmed that the floating lamina at L4 and L5 were secured by the pedicle screws and smiley face rods (Fig. 4). Cancellous bone was confirmed to be packed around the pars defects (Fig. 5). The patient was allowed to stand with a hard brace on the day following surgery.

During a year of follow-up, there were signs of bony consolidation in the pars defects with no screw loosening (Fig. 6). The patient has remained pain-free and resumed playing tennis without problems. The visual analog scale for the pain was 0.

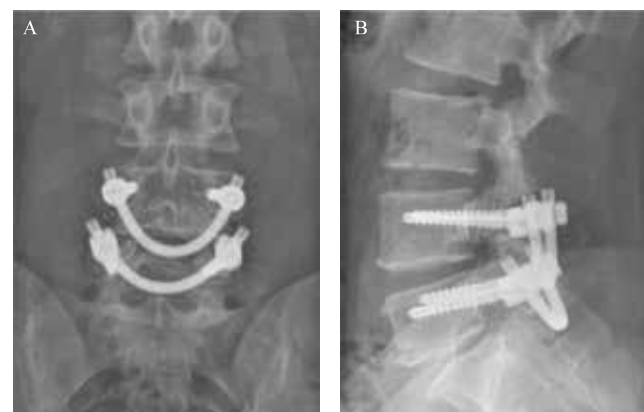

Figure 4. Postoperative anteroposterior (A) and lateral (B) radiographs demonstrating that the floating lamina at L4 and L5 are secured by the pedicle screws and smiley face rods.

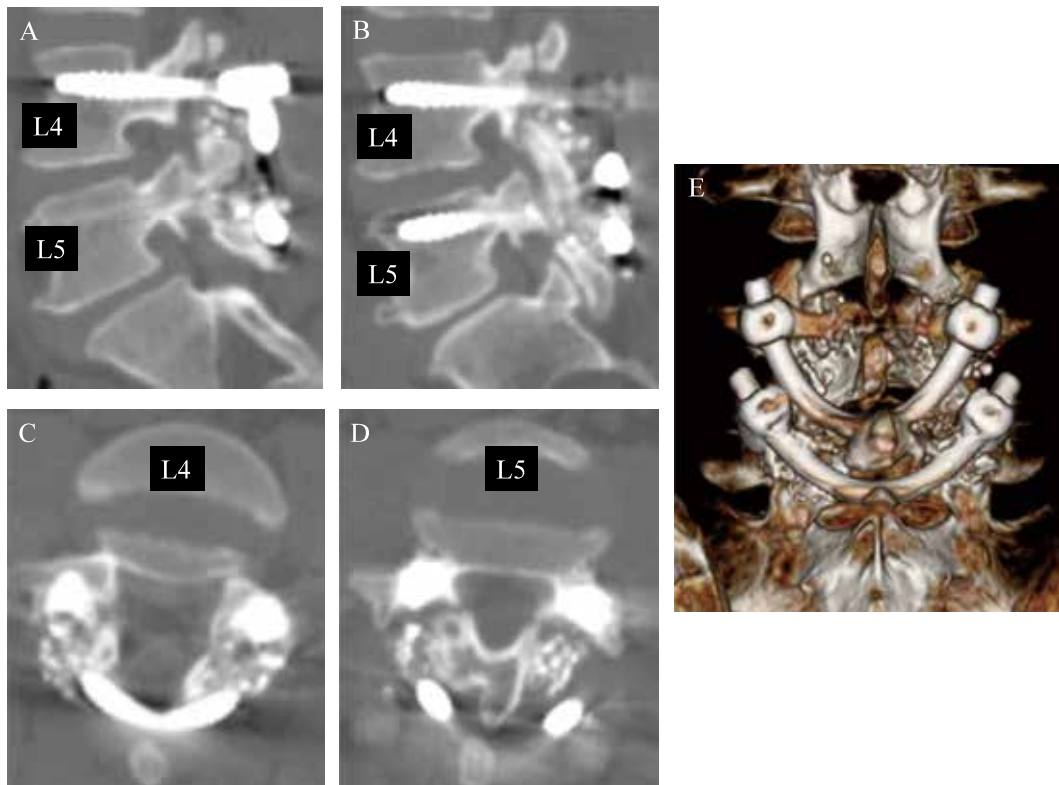


Figure 5. Postoperative right para-sagittal (A), left para-sagittal (B), axial (C, D) and three-dimensional computed tomography scans (E) at L4 and L5 showing packing of cancellous bone around the pars defects.

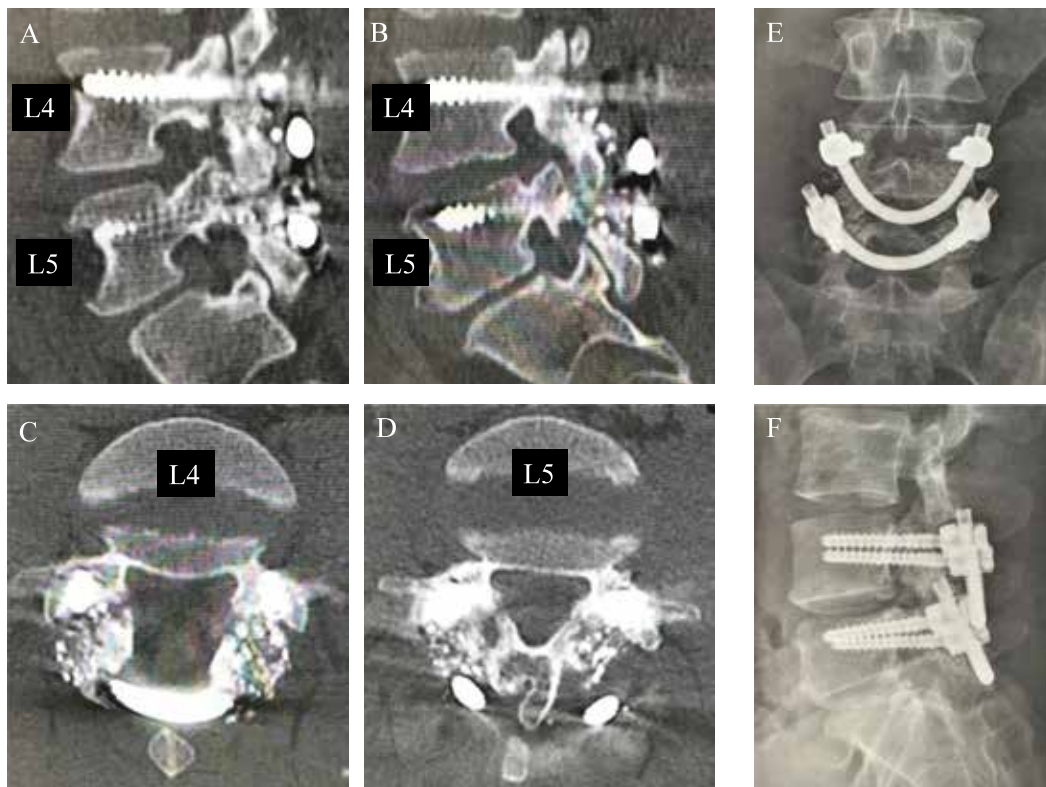


Figure 6. 1 year after surgery, postoperative right para-sagittal (A), left para-sagittal (B), axial (C, D) and plain radiographs (E, F) at L4 and L5 showing the signs of bony consolidation in the pars defects with no screw loosening.

DISCUSSION

Multi-level spondylolysis is very rare and its etiology is unclear. Ogawa *et al.* (6) hypothesized that multi-level spondylolysis, like single-level spondylolysis, results from fatigue fractures of the pars interarticularis. However, all but one of the six cases of multi-level spondylolysis reported by Ravichandran (3) involved symptoms that were precipitated by trauma. Ravichandran concluded that trauma is an important factor in producing multiple pars defects in the same patient but suggested that genetics may also play a role. Our patient had been playing tennis before his initial presentation, which may have aggravated his pars defects and triggered the onset of symptoms.

The main surgical methods used to treat lumbar spondylolysis are arthrodesis and direct repair. Arthrodesis of the posterior elements has been performed for years. However, a disadvantage is loss of motion at the affected segment, which increases loading on the adjacent segment (7). In contrast, direct repair has the advantage of preserving segmental motion, which is preferred in younger patients who do not have severe disc degeneration or instability.

Several direct repair methods for lumbar spondylolysis have been reported. In 1968, Kimura (8) used only a bone graft and prescribed a cast and a long rest period for fusion. In 1970, Buck (9) used a screw across the pars, and in 1986, Nicol and Scott (10) used a wire to surround the pars defect. Tokuhashi *et al.* (11) in 1996 and Roca *et al.* (12) in 2005 introduced the pedicle screw and hook method, a procedure used to compress pars defects with pedicle screws and angled lamina hooks. In 2009, Sairyo *et al.* (13) reported a minimally invasive technique using a percutaneous pedicle screw and hook-rod (PSHR) system. Using the PSHR method, we are able to perform a direct repair of a pars defect via a small (3–4-cm) skin incision and it is not necessary to detach all the back muscles.

We repaired the pars defect in our patient using a smiley face rod method. This method was first reported in 1999 by Gillet and Petit (14), who called it the “V-rod” method. The screw head and rod were subsequently noticed to resemble a smiling face on anteroposterior plain radiographs; therefore, Yamashita *et al.* (4) renamed it the “smiley face” rod method. A biomechanical evaluation of the smiley face rod method by Ulibarri *et al.* (15) showed marked improvement in postoperative stability of the pars defect when compared with conventional direct repair surgery.

There is still no consensus on the optimal treatment for multi-level spondylolysis. There have been several descriptions of direct repair in patients with multi-level spondylolysis (16-19), all of which involved wire fixation or screw and hook repair. In 2013, Arai *et al.* (19) described a three-level direct repair using the PSHR method at L3-5 in a 45-year-old man with lumbar spondylolysis but encountered a previously unreported postoperative complication. The patient was pain-free after surgery; however, six months later, he felt discomfort and heard a metallic sound as he twisted his trunk. The cause of this sound was identified as interference between the hook head for L3 and the screw head for L4. Therefore, there was no option but to remove the PSHR system at L3 after bone union. Arai *et al.* stressed that surgeons should be aware of this possible complication if a direct repair of adjacent multi-level spondylolysis was performed using the PSHR method.

Due to the report by Arai *et al.* (19), we hesitated to use the PSHR method in our patient. We considered that the problem of interference between implants could be avoided by using the smiley face rod method with two pedicle screws and one U-shaped rod per segment at L4 and L5. Our patient had not felt any discomfort or heard a metallic sound when twisting his trunk since his operation. Voisin *et al.* (20) reported on a patient in whom

they repaired a non-consecutive multi-level spondylolysis at L3 and L5 using the smiley face rod method. The surgical planning for non-consecutive multi-level spondylolysis appears to be more straightforward than that for spondylolysis at adjacent levels because there is no risk of interference between the implants. Therefore, the PSHR method can be considered an effective and problem-free procedure for non-consecutive multi-level spondylolysis, e.g., at L3 and L5.

In summary, we have successfully treated a 29-year-old man with consecutive double-level spondylolysis at L4 and L5 using the double smiley face rod method. To the best of our knowledge, no similar cases have been reported. Surgeons should take into account the risk of interference between the implants when planning surgery for a patient with consecutive multi-level lumbar spondylolysis.

REFERENCES

1. Ranawat VS, Dowell JK, Heywood-Waddington MB. Stress fractures of the lumbar pars interarticularis in athletes: a review based on long-term results of 18 professional cricketers. *Injury* 2003; 34(12): 915-9.
2. Sakai T, Sairyo K, Takao S, Nishitani H, Yasui N. Incidence of lumbar spondylolysis in the general population in Japan based on multidetector computed tomography scans from two thousand subjects. *Spine (Phila Pa 1976)* 2009; 34(21): 2346-50
3. Ravichandran G. Multiple lumbar spondylolyses. *Spine (Phila Pa 1976)* 1980; 5(6): 552-7.
4. Yamashita K, Higashino K, Sakai T, *et al.* The reduction and direct repair of isthmic spondylolisthesis using the smiley face rod method in adolescent athlete: technical note. *J Med Invest* 2017; 64(1.2): 168-172.
5. Pfirrmann CW, Metzendorf A, Zanetti M, Hodler J, Boos N. Magnetic resonance classification of lumbar intervertebral disc degeneration. *Spine (Phila Pa 1976)* 2001; 26(17): 1873-8.
6. Ogawa H, Nishimoto H, Hosoe H, *et al.* Clinical outcome after segmental wire fixation and bone grafting for repair of the defects in multiple level lumbar spondylolysis. *J Spinal Disord Tech* 2007; 20(7): 521-5.
7. Ghiselli G, Wang JC, Bhatia NN, Hsu WK, Dawson EG. Adjacent segment degeneration in the lumbar spine. *J Bone Joint Surg Am* 2004; 86-A(7): 1497-503.
8. Kimura M. My method of filling the lesion with spongy bone in spondylolysis and spondylolisthesis. *Seikei Geka* 1968; 19(4): 285-96.
9. Buck JE. Direct repair of the defect in spondylolisthesis. Preliminary report. *J Bone Joint Surg Br* 1970; 52(3): 432-7.
10. Nicol RO, Scott JH. Lytic spondylolysis. Repair by wiring. *Spine (Phila Pa 1976)* 1986; 11(10): 1027-30.
11. Tokuhashi Y, Matsuzaki H. Repair of defects in spondylolysis by segmental pedicular screw hook fixation. A preliminary report. *Spine (Phila Pa 1976)*. 1996 Sep 1; 21(17): 2041-5.
12. Roca J, Iborra M, Cavanilles-Walker JM, Albertí G. Direct repair of spondylolysis using a new pedicle screw hook fixation: clinical and CT-assessed study: an analysis of 19 patients. *J Spinal Disord Tech* 2005; 18(8): S82-S89.
13. Sairyo K, Sakai T, Yasui N. Minimally invasive technique for direct repair of pars interarticularis defects in adults using a percutaneous pedicle screw and hook-rod system. *J Neurosurg Spine* 2009; 10(5): 492-5.
14. Gillet P, Petit M. Direct repair of spondylolysis without

- spondylolisthesis, using a rod-screw construct and bone grafting of the pars defect. *Spine (Phila Pa 1976)* 1999 ; 24(12) : 1252-6.
15. Ulibarri JA, Anderson PA, Escarcega T, Mann D, Noonan KJ : Biomechanical and clinical evaluation of a novel technique for surgical repair of spondylolysis in adolescents. *Spine (Phila Pa 1976)* 2006 ; 31(18) : 2067-72.
 16. Eingorn D, Pizzutillo PD. Pars interarticularis fusion of multiple levels of lumbar spondylolysis. A case report. *Spine (Phila Pa 1976)* 1985 ; 10(3) : 250-2.
 17. Chang JH, Lee CH, Wu SS, Lin LC. Management of multiple level spondylolysis of the lumbar spine in young males : a report of six cases. *J Formos Med Assoc* 2001 ; 100(7) : 497-502.
 18. Chung C-H, Chiu H-M, Wang S-J, Hsu S-Y, Wei Y-S. Direct repair of multiple levels lumbar spondylolysis by pedicle screw laminar hook and bone grafting : clinical CT, and MRI-assessed study. *J Spinal Disord Tech* 2007 ; 20(5) : 399-402.
 19. Arai T, Sairyo K, Shibuya I, Kato K, Dezawa A. Multilevel direct repair surgery for three-level lumbar spondylolysis. *Case Rep Orthop* 2013 ; 2013 : 1-6.
 20. Voisin MR, Witiw CD, et al. Multilevel Spondylolysis Repair Using the "Smiley Face" Technique with 3-Dimensional Intraoperative Spinal Navigation. *World Neurosurg*. 2018 ; Jan 109 : e609-e614.