

Practique Clinique et Investigation

Clearer Image of Computed Tomography by Reconstruction Analysis Method

Katsunori Ogura¹ | Hiroshi Bando^{2,3*} | Yoshikane Kato¹ | Masahiro Irikawa¹ | Takafumi Kawata¹ | Setsuko Kanazawa¹ | Sayuri Matsuzaki¹

¹Kanaiso Hospital, Komatsushima, Tokushima, Japan

²Tokushima University / Medical Research, Tokushima, Japan

³Shikoku Division of Integrative Medicine Japan (IMJ), Japan

*Correspondence: Hiroshi Bando, Shikoku Division of Integrative Medicine Japan (IMJ), Nakashowa 1-61, Tokushima 770-0943, Japan, Tel: +819031872485; Fax: +81886031030; E-mail: pianomed@bronze.ocn.ne.jp

ABSTRACT

Computed tomography (CT) has been widely used for long. In recently years, the useful application of CT would be the method of the reconstruction images. Historically speaking, reconstruction images were conducted so far by algebraic reconstruction technique (ART), filtered back projection (FBP), iterative reconstruction (IR) algorithms and so on. There are various effects of reconstruction image of CT in clinical practice. Two cases with such beneficial experiences were reported. Case 1 is 74-year-man with hypertension. He was diagnosed to have abdominal aortic aneurysm (AAA). By reconstruction images, the general shape and details were clearly observed including regulating background data. Case 2 is 48-year-female without history of low back pain. When she received abdominal CT, she was pointed out to have lumbar disc herniation between L4 and L5. The diagnosis was done from the lateral tomography of lumbar vertebrae. By reconstruction images with colored modification, the detail status of herniation was clearly observed. Consequently, reconstruction image method of CT would be useful and effective. Further evolution of CT apparatus and development of computer analysis would be expected for better clinical practice and research in the future.

Keywords: *Computed tomography (CT); Reconstruction method; Abdominal aortic aneurysm; Lumbar disc herniation*

INTRODUCTION

In the actual clinical practice, the examination of computed tomography (CT) has been widely used for long. It is useful diagnostic apparatus, which has been applied about 80 million cases per year in US [1]. CT was born in 1972 and developed with a variety of evolution for about 50 years [2].

In recently years, the useful development of CT would be the reconstruction method of the images [3]. Formerly, the images of CT were reconstructed by the iterative way. It was called as the algebraic reconstruction technique (ART), which has not good enough to yield satisfactory images [4]. Consequently, ART was replaced afterward by rather simplified analyzing method of filtered back projection (FBP). It was utilized for comparatively long time, and after that the next generation would be succeeded. Then, iterative reconstruction (IR) algorithms have been prevalent in the clinical practice. Moreover, there are photon-counting CT scan [5] and other evolution method used by artificial intelligence (AI) [6].

Citation: Katsunori Ogura, Clearer image of computed tomography by reconstruction analysis method. *Prac Clin Invest* 1(1): 33-37.

As mentioned above, various technology concerning CT have been developed for long. Authors have continued diagnosis and treatment, and have important experiences with useful CT reconstruction [7]. In this article, some cases are introduced associated with useful aspect of reconstruction CT images.

CASE 1 PRESENTATION

The case 1 is a 74-year-old man who has been hypertensive for years. He was given the hypertensive agents from another clinic, which were calcium blockade and angiotensin II receptor blocker (ARB). When he received annual check-up including blood test, ECG, chest X-P and abdominal echogram in our clinic, he was suspected to have abdominal aortic aneurysm (AAA).

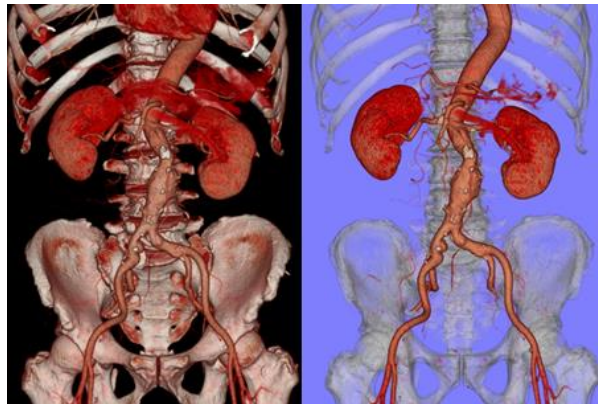


Figure 1: Reconstruction image abdominal aortic aneurysm in case 1. **(A)** The image of the abdominal aortic aneurysm (AAA) from the anterior aspect, which is not clearly observed because of the similar colors in the background. **(B)** The same image of AAA, which is clearly observed because of the modified back ground by the computerized technique.

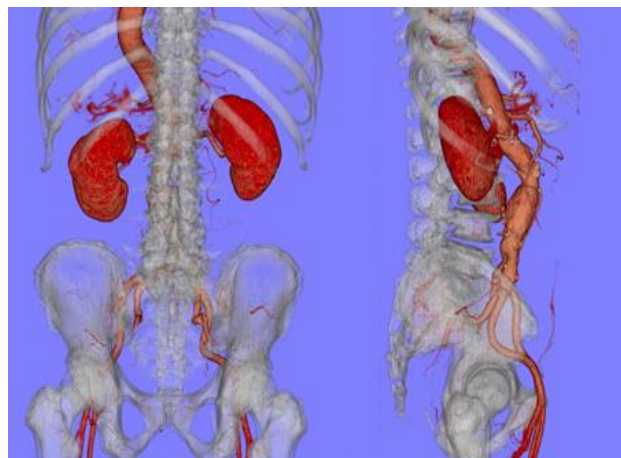


Figure 1: **(C)** The image of AAA from the posterior aspect, which is clearly observed because of the modified background. **(D)** The lateral view of AAA, which is clearly observed because of the transparent bone image by the computerized technique.

Consequently, he received abdominal CT scan for further evaluation, which showed the presence of AAA. However, only usual images of CT were not enough to observe the shape of the aneurysm clearly. Then, the procedure of the reconstruction image was performed.

General shape of AAA in the anterior aspect was shown in (Figure 1A and Figure 1B). The former image has multiple factors with similar colors, then the detail is not clearly grasped in (Figure 1A). On the other hand, the latter image was clearly to observe the aneurysm, because of the modified background (Figure 1B). Similarly, reconstruction images of AAA in the posterior and lateral aspects were shown in (Figure 1C and Figure 1D). The former image can clearly show the detail condition from posterior angle (Figure 1C), and the latter image enable to give precise information, because of the transparent bone image by the computerized technique (Figure 1D).

CASE 2 PRESENTATION

Case 2 is 48-year-old female, who was diagnosed as psychosomatic disorder. She has felt light degree of anxiety and muscle tension probably from climacteric period, and was given Etizolam 10 mg per day. She did not complain of low back pain or problems of lower extremities. When she felt some discomfort in abdomen, she hoped to be checked up in detail. Then she was evaluated by several exams including abdomen CT.

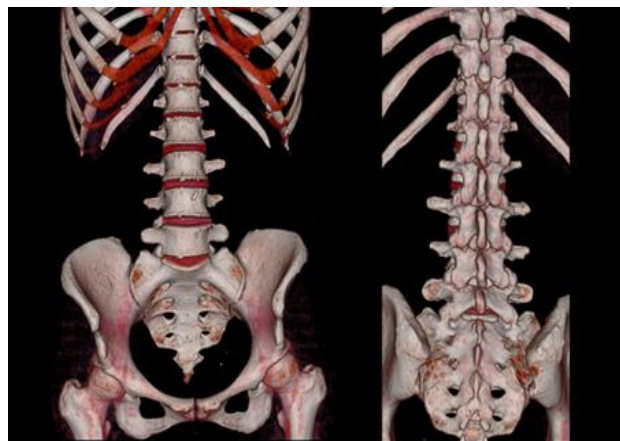


Figure 2: Reconstruction image of lumbar region in case 2. (A) The image of lumbar vertebrae from the anterior aspect. (B) The image of lumbar vertebrae from the posterior aspect.

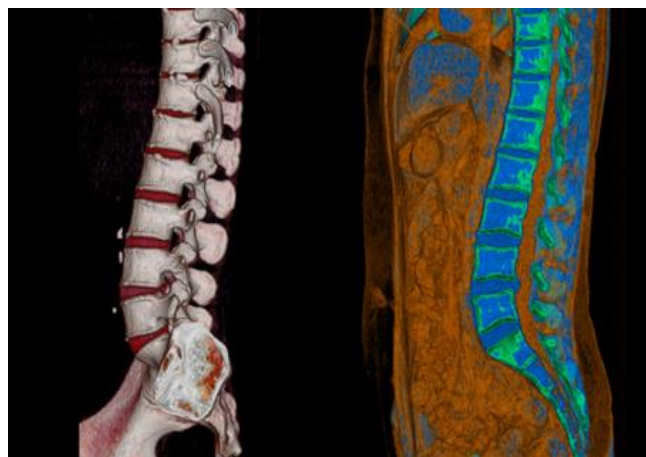


Figure 2: (C) The lateral view of the lumbar vertebrae by the reconstruction image technique. (D) The image of lumbar vertebrae in tomography with colored distinction technique. It can clearly show lumbar disc herniation between L4 and L5.

As for the result of CT, the anterior and posterior aspects showed unremarkable (Figure 2A and Figure 2B). The lateral view of the spine vertebrae did not show remarkable changes in (Figure 2C).

On the other hand, the tomogram of spine vertebrae showed lumbar disc herniation between L4 and L5 (Figure 2D). The detail of the change was clearly observed in (Figure 2D). It is from the colorful distinguished data of the reconstruction. This is one of the beneficial points of reconstruction image method.

METHODS

In this study, method includes CT scan apparatus made in Japan, which is Toshiba Alexion 16 (Toshiba/Canon in Japan) [8]. This is the spiral type which has the scan time at 0.75, 1.0, 1.5, 2.0 and 3.0 seconds associated with 16 slice system. The limit of the product would be 0.5 mm detector elements. This Alexion 16 has been the smallest in current CT technology, and has the beneficial effects with razor-sharp images, lower exposure dose, fast and accurate diagnosis for all parts of the body.

The mechanism of Alexion has the multiplanar reconstruction or reformation (MPR) [7]. It has several useful functioning, such as 3D surface rendering, 3D color image processing, 3D volume rendering, curved MPR and cine display. Making the advantages of this function, we could analyze and make the reconstruction image of the CT scan, which will be useful in clinical practice for all purposes.

DISCUSSION

Since CT was introduced to clinical practice about several decades ago [2], clinical applications have expanded, and many technologies such as noise reduction and reconstruction attempts have shown great evolution [3,9].

In this report, case 1 have shown AAA. The reconstruction image method is beneficial for the diagnosis of the vascular system [10]. It includes both of venous system and arterial system. In the former, accurate morphological modeling can be performed. The latter can show the precise assessment and quantification of the arterial morphology. Before various operational procedure, the use of augmented reality can give important information and preparation for assisting the surgical training [10].

Taking the advantages of the reconstruction image, the digital research has been developed for the beneficial information with the vascular surgery [11]. They include 2D segmentation and also 3D reconstruction in the case of aortic aneurysms. In such cases, interactive 3D modeling of the aortic aneurysm can be achieved with visualized precise reconstruction images [11].

There is a report about the follow-up status of patients with stent treatment after abdominal aortic aneurysms [12]. They compared the follow up method between 3D-ultrasound and CT scan in 52 cases. As a result, both measurements showed similar inter-planar distance and angle. Consequently, it is suggested that not only CT but also ultra-sound would be beneficial for precise investigation of vascular problems when performing 3D images in the future [12].

The reconstruction image method seemed to be useful for the management and the understanding in case 2. There was a report that patients with lumbar diseases were randomized into three groups [13]. The protocol has the following program by 1) CT & MRI imaging, 2) 3D reconstructions, and 3) personalized 3D printed models. As for the management for patients with low back pain, several exam and information would lead to better satisfactory management such as these three factors [13].

A recent report has indicated the efficacy of 3D reconstruction [14]. Fifty patients with lumbar disc herniation who received intervertebral foramen endoscopy were divided into two groups, which are experimental group and control group. The former group was conducted beforehand with 3D construction data, and the latter has usual method as before. Consequently, the former showed the predominance as to the efficiency of operation, and postoperative efficacy with pain management [14].

Furthermore, National Cancer Institute (NCI) has contributed improving the application of CT in cancer screening, diagnosis and treatment, including new uses for CT imaging technology [15].

In summary, the reconstruction image method of CT was described in this article. Further evolution of CT apparatus and development of computer analysis would be expected for better clinical practice and research in the future.

ACKNOWLEDGEMENT

The authors would like to express our sincere gratitude to the patients, all staffs of the hospital and all related people for the understanding and cooperation.

REFERENCES

1. OECD (2017) Health at a glance 2017: OECD Indicators. OECD Publishing, Paris.
2. Ambrose J, Hounsfield G (1973) Computerized transverse axial tomography. *British Journal of Radiology* 46: 148-149.
3. Willeminck MJ, Noël PB (2019) The evolution of image reconstruction for CT-from filtered back projection to artificial intelligence. *European Radiology* 29(5): 2185-2195.
4. Fleischmann D, Boas FE (2011) Computed tomography-old ideas and new technology. *European Radiology* 21(3): 510-517.
5. Willeminck MJ, Persson M, Pourmorteza A, et al. (2018) Photon-counting CT: Technical principles and clinical prospects. *Radiology* 289(2): 293-312.
6. Wolterink JM, Leiner T, Viergever MA, et al. (2017) Generative adversarial networks for noise reduction in low-dose CT. *IEEE Transactions on Medical Imaging* 36(12): 2536-2545.
7. <https://www.indiamart.com/proddetail/alexion-16-ct-scan-machine-19323524448.html>
8. https://jp.medical.canon/products/computed-tomography/alexion_feature
9. Anam C, Fujibuchi T, Toyoda T, et al. (2019) An investigation of a CT noise reduction using a modified of wiener filtering-edge detection. In *Journal of Physics: Conference Series* 1217(1): 012022.
10. Uhl JF, Chahim M, Cros F, et al. (2016) 3D modeling of the vascular system. *Journal of Theoretical and Applied Vascular Research* 1(1): 8-15.
11. Saidi M, Uhl JF, Chahim M (2019) The value of segmentation with 2D and 3D reconstruction before vascular surgery (about a case of aortic aneurysm). *Annals of Medicine* 51(Suppl. 1): 64-64.
12. Rouet L, Dufour C, Billon AC, et al. (2019) CT and 3D-ultrasound registration for spatial comparison of post-EVAR abdominal aortic aneurysm measurements: A cross-sectional study. *Computerized Medical Imaging and Graphics* 73: 49-59.
13. Zhuang Y, Zhou M, Liu S, et al. (2019) Effectiveness of personalized 3D printed models for patient education in degenerative lumbar disease. *Patient Education and Counseling*.
14. Peng Z, Zhao W, Hu S (2019) Computer three-dimensional reconstruction and pain management for lumbar disc herniation treated by intervertebral foramen endoscopy. *Journal of Medical Imaging and Health Informatics* 9(8): 1776-1781.
15. Gomez DR, Rimner A, Simone II CB, et al. (2019) The use of radiation therapy for the treatment of malignant pleural mesothelioma: expert opinion from the National Cancer Institute thoracic malignancy steering committee, International Association for the study of lung cancer, and mesothelioma applied research foundation. *Journal of Thoracic Oncology* 14(7): 1172-1183.