

The effect of static magnetic field on partial thickness burn wound healing

Static magnetic field, burn wound healing

Ebru H. Ayvazoğlu Soy¹, Hüseyin Onur Aydın¹, Ayşen Terzi², Yahya Ekici¹, Gökhan Moray¹¹Department of General Surgery, ²Department of Pathology, Baskent University Faculty of Medicine, Ankara, Turkey

Abstract

Aim: During the past decades, there has been a substantial and growing evidence that static magnetic fields (SMF) and pulsed electromagnetic fields (EMF) can both produce satisfying therapeutic effects on various disorders. There have been researches about the efficacy of SMF in wound healing. However, there is no any investigation about the efficacy of SMF in burn wound healing. In this experimental study, we aimed to investigate the efficacy of SMF in partial thickness burn wound in rats. **Material and Method:** Forty male Sprague-Dawley male rats were used in the experiment. The modification of Sawada's burn model was applied. In Group1 magnets, in Group2 non-magnetic bars were placed vertically to the burn wound. In Group3 magnets, in Group4 non-magnetic bars were placed horizontally to the burn wound. The wound healing is evaluated by gross wound healing rate and histopathological examination. **Results:** In study groups, wound healing was faster, granulation with fibroblast migration was earlier, collagen production and neovascularisation were more than control groups. We found no relationship between wound healing and vector direction. **Discussion:** According to these results static magnetic field can be used in clinic to promote the healing in patients with burns. Especially, in cases that have no chance for grafting, to decrease complications and increase the survival, the static magnetic field can be an alternative.

Keywords

Static Magnetic Field; Wound; Burn; Experimental; Healing

DOI: 10.4328/ACAM.6078 Received: 07.11.2018 Accepted: 08.12.2018 Published Online: 21.12.218 Printed: 01.09.2019 Ann Clin Anal Med 2019;10(5): 611-5
Corresponding Author: Ebru H. Ayvazoğlu Soy, Department of General Surgery, Baskent University Faculty of Medicine, Ankara, Turkey.
T.: +90 3122036868 F.: +90 3122030521 E-Mail: ebruayvazoglu@gmail
ORCID ID: <https://orcid.org/0000-0002-0993-9917>

Introduction

Burns are one of the most severe traumas and cause coagulative skin necrosis. Impressive results are attainable by an early debridement and grafting of burn wounds. The use of various substances accelerating wound healing, especially for patients with a large burn area, may affect survival and reduce the rate of possible infective complications. To serve that purpose, wound covering materials and artificial skins have been manufactured and intensively studied. Studies are ongoing and new solutions are actively sought. Overwhelming evidence has been accumulated recently on the role of static magnetic field (SMF) and electromagnetic field (EMF) as alternative noninvasive tools with satisfactory therapeutic effects in a variety of disorders [1]. Many experimental studies have shown that SMF promotes wound healing in various tissues [1-6]. SMF and EMF also exert positive effects on dermal healing in humans [6]. Although there are experimental and clinical studies indicating some beneficial effects of SMF on wound healing, no study has yet explored its effects on burn wound healing. The aim of the present experimental study was to investigate the wound healing effect of the local application of an SMF to partial-thickness burn area in rats.

Material and Method

The protocol of this experimental study was approved by Baškent University Faculty of Medicine Experimental Research Committee with respect to ethical and scientific aspects, and it was conducted in compliance with the criteria of 'National Institute of Health Guide for the care and use of laboratory animals'. The rats used in the study were obtained from the Laboratory Animals Production Center at Baskent University Research Center. We used 40 randomly selected male Sprague-Dawley rats weighing 250-300 grams.

A modified version of the burn model described by Sawada et al. was used as the burn model [7]. A preliminary study was performed with 5 rats to determine the optimum application time, in which the rats were applied the sponge for 15, 20, 25, 30, 35 seconds and burn depth was examined histopathologically. As a result, 35-second application time was found to reach the desired burn depth. The back skins of all rats were shaved and prepared with povidone-iodine solution and sterile isotonic saline prior to the procedure. Formation of superficial, partial-thickness burns was histopathologically confirmed in all rats. A total of 40 rats enrolled for the study were divided into 4 groups, that included two study groups (magnet bar groups) and two control groups (non-magnetic bar groups). NeFeB magnets were used in the study groups and NeFeB bars that are identical with the magnet bars but possess no magnetic property in the controls. In order to prevent inadvertent displacement, the magnets and bars were sutured to tissue with 3/0 silk sutures. Magnetic and non-magnetic NeFeB bars each weighing 9.2 gr and having a size of 24x10x5 mm (Magnet Sales and Service Limited, Wiltshire, UK) were used for the study. Magnetic strength of each bar was measured using a Gauss Meter with a transverse probe (Magnet Sales and Service Limited) before they were placed under intact skin next to the burn area. The magnetic field strength of 20 magnets was measured 4000 Gauss (G) at both poles and 390-420 Gauss (G) at the exact center of the bar. The same measurements were also carried out with the non-magnetic bars and their magnetic forces were measured between 1 G and 8 G; these values were similar with the magnetic strength of the laboratory's floor (1-2 G).

Group 1 (n=10) and Group 2 (n=10); after forming a burn on the back skin of rats, magnetic bars and non-magnetic bars were placed vertically to the burn area under the intact skin next to the burn area. Group 3 (n=10) and Group 4 (n=10); after forming a burn on the back skin of 20 rats magnetic bars and non-magnetic bars were placed horizontally to the burn area under the intact skin next to the burn area.

Burn wound areas were quantified on the third and seventh days. On the seventh day, burn tissue samples harvested from all sacrificed rats were histopathologically examined. Burn wound areas were measured to calculate the wound healing rate. The burn wound area was calculated with the pixel method in all groups on the third and seventh days. All histopathological examinations were performed by a single pathologist. The sample tissues were fixed with a 10% formaldehyde solution and then embedded in paraffin blocks. Then, the sections were sampled and stained with hematoxylin-eosin (H&A) and trichrome stains. The stages of wound healing were examined in H&E stained sections while collagen production was examined in trichrome-stained sections. Wound healing assessment was based on the polymorphonuclear leukocyte (PMNL) count, fibroblast count, and vascular proliferation rate at one gross magnification field (x40). PMNL and fibroblast counts were rated between 0 and 5 as the following: 0 = (<5), 1 = (5-10), 2 = (10-50), 3 = (50-100), 4 = (100-150), 5 = (>150). Epithelization and collagen production was recorded as present/absent.

Statistical analyses were performed with SPSS 11.0 software package. The histopathological cell counts were compared using the Chi-Square test and neovascularization and wound healing rates using the Student's t-test, p-value of less than 0.05 was considered statistically significant.

Results

The study findings were analyzed in two parts. In the first part, macroscopic wound healing was compared between the study groups, while in the second part, pathological changes in the burned skin, as well as wound healing in the burn tissue excised at the end of the study, were histopathologically compared across the study groups.

Gross Wound Healing

Third- and seventh-day burn areas were calculated with the pixel method for all groups. Burn wound healing rate was calculated for all groups using the formula (Wound healing rate = (3rd-day burn wound area - 7th-day burn wound area) / 3rd-day burn wound area). The mean wound healing rates of the study and control groups were $33,74 \pm 8,60$ and $9,71 \pm 3,90$, respectively ($p < 0.001$). No significant difference was found between the control groups (11,04 and 8,38, $p = 0,378$) and study groups (34,01 and 33,47, $p = 0,334$) with respect to mean wound healing rates.

Histopathological Findings

In each of the four groups where experimental burn was formed, superficial partial-thickness burn occurred at the microscopic and macroscopic levels. As a general observation, wound healing arrested at the inflammatory stage in Groups 2 and 4 but it was better and progressed to the proliferative stage in Groups 1 and 3.

Inflammatory Cell (PMNL) Distribution

While there was no subject with a PMNL count above 50% in

the study groups (Groups 1 and 3), 55% (n=11) of the subjects of the control groups had a PMNL count above 50. The likelihood of having a PMNL count above 50 was significantly higher in the control groups than the study groups ($p < 0,001$) (Figure 1). An analysis of the PMNL distributions of the control groups (Groups 2 and 4) revealed no significant difference ($p = 0,178$).

Fibroblast Cell Distribution.

There were 14 (70%) subjects with a fibroblast count above 50 in the study groups (Groups 1 and 3) whereas only one (5%) subject in the control groups had a fibroblast count above 50. The study groups had a significantly greater likelihood of having a fibroblast count above 50 compared to the control groups ($p < 0,001$). An analysis of the control groups with respect to fibroblast distributions revealed no significant differences between the Groups 2 and 4 ($p = 0,305$) (Figure 2). The study groups (Groups 1 and 3) also showed no significant difference ($p = 0,329$).

Vascular proliferation

The study groups had a mean number of newly developed vascular structures of $12,55 \pm 6,07$ and the control groups had a corresponding figure of $3,25 \pm 2,71$. The study groups had a significantly greater number of newly developed vascular structures ($p < 0.001$) (Figure 3). The comparison of control groups (Groups 2 and 4) (2,70 vs. 3,80, $p = 0.943$) and study groups (Groups 1 and 3) (11,20 vs. 13,90, $p = 1.679$) were compared with respect to mean vascular proliferation and there was no significant difference.

Collagen Production

Collagen production was observed in 13 (65%) subjects in the study groups and 4 (20%) subjects in the control groups. The study groups showed a significantly greater collagen production (65% vs. 20%, $p < 0.004$) (Figure 4).

Epithelization

In the study groups, 3 (15%) subjects had epithelization (Figure 5) whereas the control groups had no subject with epithelization. However, the difference was not statistically significant owing to a low number of subjects in the subgroups ($p = 0.072$).

Discussion

The most important factors affecting mortality after thermal burns are the size of the burn area, patient's age, and burn depth. The latter is also the most important factor affecting the physical appearance and functions of a patient in the long term [8]. Treatment of burns with a large surface area is quite problematic. In these patients, inadequacy of the amount of an autograft intended to use for early debridement and grafting is the most significant limitation [9]. After a full-thickness burn, a new dermal layer is to be formed to attain better outcomes both aesthetically and functionally. Therefore, wound covering materials and synthetic skin have been introduced into clinical use in such patients, albeit with unclear indications for use. The main problem with wound healing in deep partial burns and full-thickness burns is the inadequacy of cells and structural matrix support. As skin epithelization is traditionally regarded as wound healing, the first ever developed product was epithelial cells produced at a laboratory setting. As stem cell technologies have been advanced, dermal analogs are combined with autologous epidermal stem cells, endothelial stem cells, hair follicles' stem cells, and even melanocytes to obtain physiological, easy-to-apply, enduring, and aesthetically superior grafts [10-

12]. However, a wound covering material possessing all those properties is yet to exist. More time and research are needed to overcome these problems and to implement advances in the field into clinical practice.

The effects of electromagnetic field (EMF) on biological system have been investigated for centuries. Living organisms are electromagnetic systems using electromagnetic fields for biological processes ranging from membrane function to information transfer in the nervous system and macromolecular relations. Scientific research has been focused on pulse and static magnetic field. An interest in the electromagnetic field and living organism has been raised with the epidemiological studies showing a relationship, albeit weak, between the magnetic field and cancer development [1-6]. Non-ionizing electromagnetic energy is known to affect physiological processes in an organism. Electromagnetic fields have been in use for medical treat-

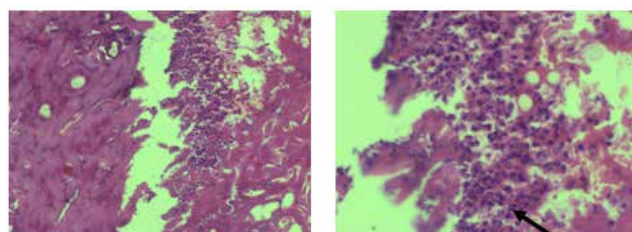


Figure 1. PMNL rich tissue granulation

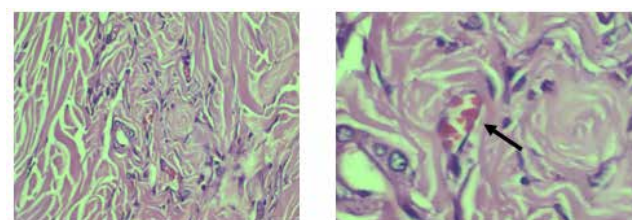


Figure 2. Fibroblastic proliferation with low PMNL

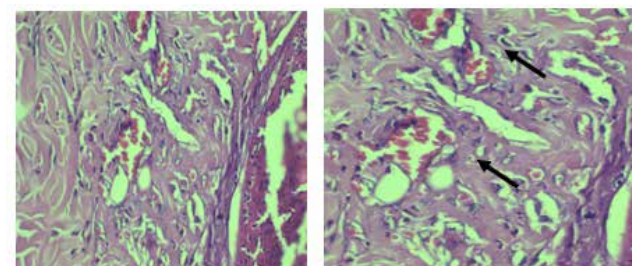


Figure 3. Tissue healing with neovascularisation and fibroblast proliferation

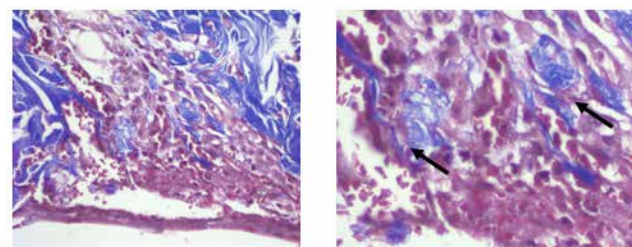


Figure 4. Reepithelization and collagen production

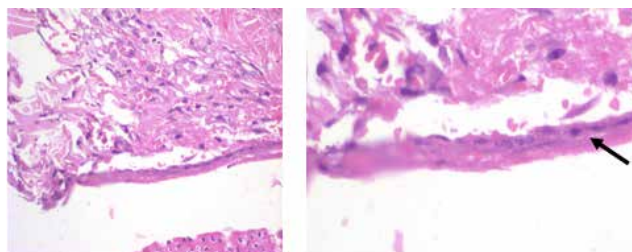


Figure 5. Reepithelization

ments in recent years. Therefore, studies have focused on weak and particularly low frequencies [13,14]. Low-frequency electromagnetic field has been reported to have an untoward effect on cellular metabolism and to trigger malignancy development [15]. However, EMF has also been shown to exert beneficial effects on bone healing in rats [16]. Other studies have shown that 50 Hz 200 G EMF hastened healing of skin wounds formed on rats' backs [17]. Another study has shown that 50 Hz 200 G EMF had positive effects on both small intestinal and colonic healing when applied in 2-hour open, 10-hour closed cycles [18]. All these results suggest that EMF affects healing. However, there are some difficulties with the application of EMF under experimental conditions because these fields do not focus on target tissues. Generators creating a magnetic field that are connected to a cage create an EMF that affects a subject's whole body. As magnetic field vectors would change when a subject is displaced, subjects need to be kept in a constantly stable position. In order to comply with ethical reasons and to meet the subjects' necessary daily actions, they could only be applied magnetic field at certain times in a given day. The magnets produce a permanent static magnetic field with constant power and vectors. This study used a static magnetic field (PMF) produced by the magnets. As a magnetic field's strength is geometrically reduced by increasing distance from the source (magnetic field strengths of the magnets are reduced to 1-2 G at a distance of 6 cm from the source), magnetic bars were placed under the intact skin at the closest neighborhood of the burn areas.

SMF's effects have not been well documented as those of EMF. In an in vitro study, it was shown that forearm fibroblasts were aligned parallel to high-intensity SMF vectors [19]. In our study, the magnets were placed to the study groups both vertically and horizontally. By this way, the relationship of the fibroblasts and their products, collagen fibrils alignment with magnetic field vector directions would be demonstrated in a comparison between the study groups. A comparison of the study groups with Group 1 (vertical) and Group 3 (horizontal) showed no significant difference with regard to average healing rates (34,01 vs 33,47, respectively; $p=0.334$), PMNL distribution (PMNL >50 in both groups, no statistical comparison could be made), fibroblast distribution ($p=0,329$), mean vascular proliferation ($p=1.679$) and collagen production ($p=0.160$).

Another study demonstrated that proliferation and synthetic activities of neonatal rat calvarium fibroblasts increased at a mean intensity of 6000G, and even with the lowest SMF intensity [20]. In experimental in vivo studies, it was stressed that SMF had a positive effect on healing. In a study where samarium cobalt magnets with an intensity of 220-260G were placed next to broken rabbit radiuses, the magnets were shown to accelerate healing [21]. Similar effects were observed by a study conducted with neodymium magnets (40-80G) placed to the osteotomy regions in the mandible [22]. In a double-blind study involving patients operated with lipectomy, it was shown that wound healing was accelerated when a magnetic patch with a magnetic strength of 150-400G was used [23]. The exact mechanism of SMF's therapeutic effect on wound healing is unknown. However, considering wound healing is dependent on adequate blood supply and oxygenation at the microcirculatory level, SMF is thought to affect by increasing blood flow to the region of interest [1]. Many clinical and experimental studies have proved that SMF therapy is an effective noninvasive method for treatment of many disorders. Its efficacy has been

shown in soft tissue injury, insomnia, osteoarthritis, and chronic pain syndrome [1]. Although there is a number of studies on wound healing in burns [24,25] no study has yet investigated the effect of SMF on burn wound healing. Herein, we observed that, as expected, the inflammatory stage was shortened, and wound healing progressed to the proliferative stage in the SMF-applied study groups while healing was paused at the inflammatory stage in the control groups. In this context, higher fibroblast cell distribution, vascular proliferation, collagen accumulation, and epithelization in the SMF-applied group than the control groups actually suggest that SMF favorably affects these aspects of wound healing even in this superficial partial-thickness burn model. Another finding supporting this view is the macroscopic wound healing rates. A comparison of the study and control groups for wound healing rates revealed a significantly better wound healing in the study groups ($p<0.001$). Based on these results, static magnetic field may be introduced into clinical practice for superficial partial-thickness burns.

Scientific Responsibility Statement

The authors declare that they are responsible for the article's scientific content including study design, data collection, analysis and interpretation, writing, some of the main line, or all of the preparation and scientific review of the contents and approval of the final version of the article.

Animal and human rights statement

All procedures performed in this study were in accordance with the ethical standards of the institutional and/or national research committee and with the 1964 Helsinki declaration and its later amendments or comparable ethical standards. No animal or human studies were carried out by the authors for this article.

Funding: None

Conflict of interest

None of the authors received any type of financial support that could be considered potential conflict of interest regarding the manuscript or its submission.

References

1. Da Jing, Guanghao Shen, Jing Cai. Effects of 180 Mt static magnetic fields on diabetic wound healing in rats. *Bioelectromagnetics*. 2010; 31; 640-8.
2. Kelleher MO, Al-Abri RK, Lenihan DV. Use of a static magnetic field to promote recovery after peripheral nerve injury. *J Neurosurgery*. 2006; 105; 610-5.
3. Henry SL, Concannon MJ, Yee GJ. The effect of magnetic fields on wound healing: experimental study and review of the literature. *Eplasty*. 2008; 8; 40-4.
4. Bruce GK, Howlett CR, Huckstep RL. Effect of a static magnetic field on fracture healing in rabbit radius. *Clin Orthop Relat Res*. 1987; 222; 300-6.
5. Trock DH. Electromagnetic fields and magnets, investigational treatment of musculoskeletal disorders. *Rheum Dis Clin N Am*. 2000; 26; 51-62.
6. Man D, Man B, Plosker H. The influence of permanent magnetic field therapy on wound healing in suction lipectomy patients. *Plast Reconstr Surg*. 1999; 104; 2261-6.
7. Sawada Y. Is prolonged and excessive cooling of a scalded wound effective? *Burns*. 1997; 23; 55-8.
8. Monstrey S. Assessment of burn depth and wound healing potential. *Burns*. 2008; 34; 761-9.
9. Shakespeare P. The role of skin substitutes in the treatment of burn injuries. *Clinics in Dermatology*. 2005; 23; 413-8.
10. Compton CC, Hickerson W, Nadire K. Acceleration of skin regeneration from cultured epithelial autografts by transplantation to homograft dermis. *J Burn Care Rehabil*. 1993; 14; 653-62.
11. Boyce ST, Kagan RJ, Yakuboff KP. Cultured skin substitutes reduce donor skin harvesting for closure of excised, full-thickness burns. *Ann Surg*. 2002; 235; 269-79.

12. Sheridan RL, Morgan JR, Cusick JL. Initial experience with a composite autologous skin substitute. *Burns*. 2001; 27: 421-4.
13. Sabo J, Mirossay L, Horovcak L. Effects of static magnetic field on human leukemic cell line HL-60. *Bioelectrochemistry*. 2002; 56: 227-31.
14. Funk R, Monsees T, Ozkucur N. Electromagnetic effects- from cell biology to medicine. *Progress in Histochemistry and Cytochemistry*. 2009; 43: 177-264.
15. Boorman GA, Bernheim NJ, Galvin MJ. National Institute of Environmental Health Sciences National Institutes of Health report on health effects from exposure to power-line frequency electric and magnetic fields. NIH Publication. 1999; 99: 4493-7.
16. Ottani V, Pasquale V, Govoni P. Augmentation of bone repair by pulsed Elf magnetic fields in rats. *Anat Anz*. 1991; 172: 143-7.
17. Patino O, Grana D, Bolgiani A. Pulsed electromagnetic fields in experimental cutaneous wound healing in rats. *J Burn Care Rehabil*. 1996; 17: 528-31.
18. Nayci A, Cakmak M, Aksoyek S. Comparison of electromagnetic field stimulation on the healinh of small and large intestinal anastomoses. *Dis Colon Rectum*. 2001; 44: 1181-8.
19. Guido S, Tranquillo RT. A methodology for the systemic and quantative study of cell contact guidance in oriented collagen gels. *J Cell Sci*. 1993; 105: 317-31.
20. Mc Donald F. Effect of static magnetic fields on osteoblasts and fibroblasts in vitro. *Bioelectromagnetics*. 1993; 14: 187-96.
21. Bruce GK, Howlett CR, Huckstep RL. Effect of a static magnetic field on fracture healing in a arabbit radius. *Clin Orthop*. 1987; 222: 300-6.
22. Darendeliler MA, Darendeliler A, Sinclair PM. Effects of static magnetic and pulsed electromagnetic fields on bone healing. *Int J Adult Orthodon Orthognath Surg*. 1997; 12: 43-53.
23. Man D, Man B, Plosker H. The influence of permanent magnetic field therapy on wound healing in suction lipectomy patients. *Plast Reconstr Surg*. 1999; 104: 2261-6.
24. Ozcelik U, Ekici Y, Haberal M. Effect of topical platelet-rich plasma on burn healing after partial-thickness burn injury. *MedSci*. 2016; 22: 1903-9.
25. Eyuboglu AA, Uysal CA, Haberal M. The effect of adipose derived stromal vascular fraction on stasis zone in an experimental burn model. *Burn*. 2018; 44: 386-96.

How to cite this article:

Ayvazoğlu Soy EH, Aydın HO, Terzi A, Ekici Y, Moray G. The effect of static magnetic field on partial thickness burn wound healing. *Ann Clin Anal Med* 2019;10(5): 611-5.