

Rapid Spontaneous Resolution of Acute Epidural Hematoma: A Case Report and Review of the Literature

Fatih Aydemir, Melih Çekinmez, Özgür Kardeş, Feyzi Birol Sarıca

Department of Neurosurgery, Başkent University School of Medicine, Adana Practice and Research Center, Adana, Turkey

Background: Epidural hematomas (EDH) are pathologies in which the early diagnosis and treatment are important. Resolution under 24 hours is very rare.

Case Report: An 11-month-old male patient was brought to the emergency department with head trauma from falling out of bed onto his back. There were no neurological deficits, except for the patient being somnolent. Computed tomography (CT) of the patient revealed subgaleal edema in the right parietal region, linear fracture and image consistent with EDH with a thickness of about 9 mm underneath fracture. A control CT was performed after 3 hours as somnolence continued in follow-up of the patient. Hematoma in

the epidural region was observed to completely resolve and edema in the subgaleal region was observed to gain hemorrhagic characteristics.

Conclusion: In total, 15 cases have been reported, including our case, in the literature with resolution less than 24 hours. Our case has the fourth fastest resolution ever reported in the English literature. We think that the most important factor in the rapid spontaneous resolution is the presence of a connection between the epidural and epicranial space, either through a fracture or cranial sutures

Keywords: Epidural hematoma, skull fracture, spontaneous resolution

Epidural hematomas (EDH) are pathologies in which early diagnosis and treatment are important. Although symptomatic EDH requires immediate surgical evacuation, asymptomatic EDH may be followed by serial neurological examination and radiological imaging. This process results in growth, calcification or resolution at the end. Resolution time in EDH is about 2 weeks (1), whereas resolution under 24 hours is very rare. Our case has the fourth fastest resolution ever reported in the English literature.

CASE PRESENTATION

Written informed consent was obtained from the relatives of the patient who participated in this case. An 11 month-old male patient was brought to the emergency department with

head trauma after falling out of bed onto his back. There were no neurological deficits except for the patient being somnolent. There were no abrasions and erythema but only edema in the trauma area. Other system examinations were normal. Computed tomography (CT) (Somatom Emotion 16-slice; Siemens; Erlangen, Germany) of the patient revealed subgaleal edema in the right parietal region, linear fracture and image consistent with epidural hematoma with a thickness of about 9 mm underneath the fracture (Figure 1a, b). Surgical intervention was not planned. A control CT was performed after 3 hours as somnolence continued in the follow-up of the patient. Hematoma in the epidural region was observed to completely resolve and edema in the subgaleal region was observed to gain hemorrhagic characteristics (Figure 1c, d). Control CT after 12 hours was unremarkable. The patient was discharged 36 hours after trauma without any neurological deficits.

This study was presented at the Turkish Neurosurgical Society 29th Annual Scientific Congress, 17-21 April 2015, Antalya, Turkey.

Address for Correspondence: Dr. Fatih Aydemir, Department of Neurosurgery, Başkent University School of Medicine, Adana Practice and Research Center, Adana, Turkey

Phone: +90 533 640 64 99

e-mail: md.fatihaydemir@gmail.com

Received: 26 December 2014

Accepted: 1 August 2015 • DOI: 10.5152/balkanmedj.2016.141020

Available at www.balkanmedicaljournal.org

Cite this article as:

Aydemir F, Çekinmez M, Kardeş Ö, Sarıca FB. Rapid spontaneous resolution of acute epidural hematoma: A case report and review of the literature. *Balkan Med J* 2016;33:373-6



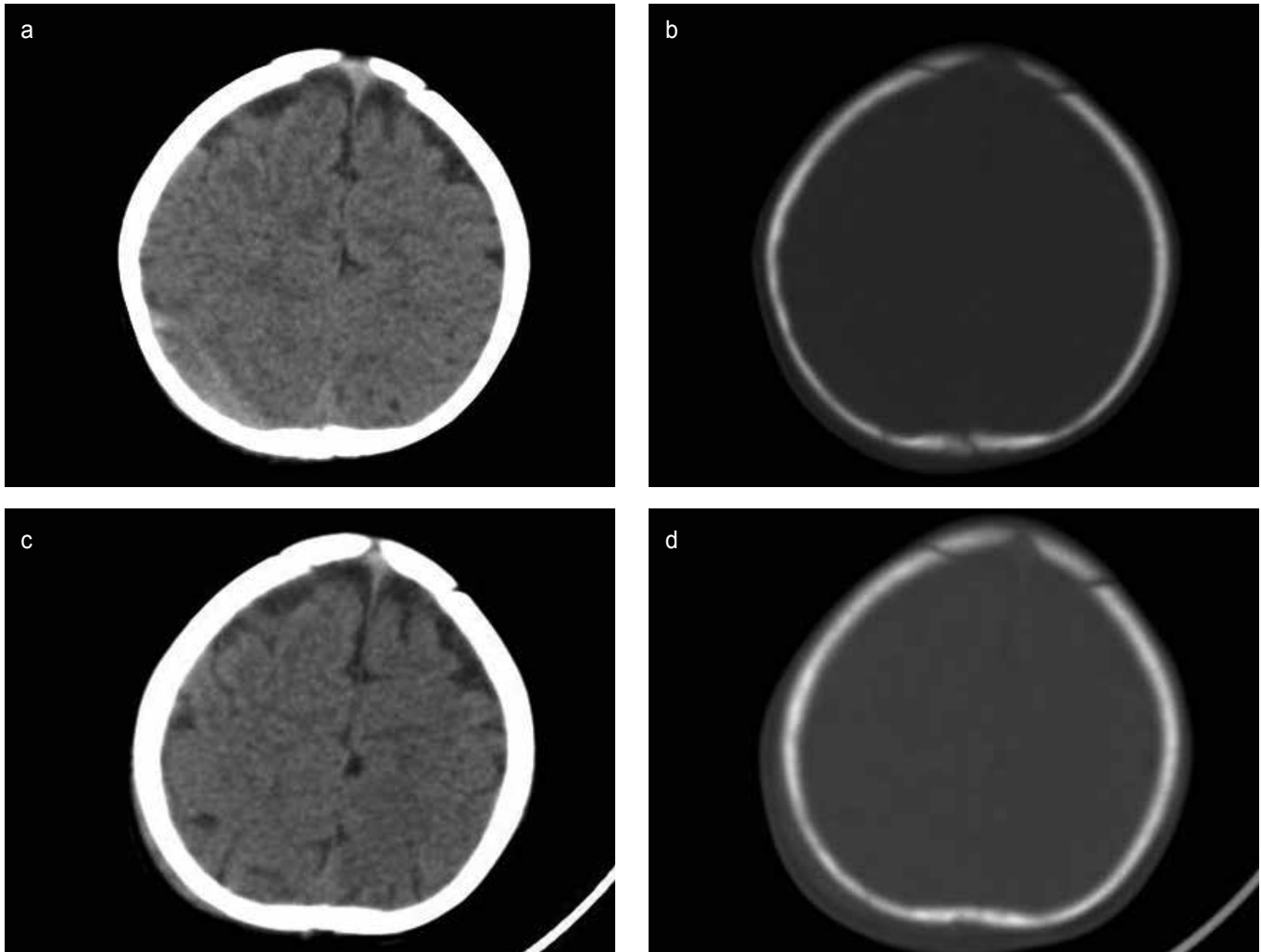


FIG. 1. a-d. Axial computerized tomography revealed that epidural hematoma at the right parietal region (a), right parietal fracture at the bone window (b), and axial brain computerized tomography demonstrated that the complete resolution of epidural hematoma and increasing epicranial hemorrhage (c, d).

DISCUSSION

Although several theories have been suggested regarding the spontaneous resolution of EDH, it has not yet been fully elucidated. Fifteen cases have been reported in the literature with a resolution less than 24 hours, including our case; these are summarized in Table 1 (2-9). Of the patients, ten were pediatric (under age 18) and five were adults. All cases except one were associated with skull fractures. Aoki et al. (2) reported that skull fracture has a positive impact on prognosis as it provides a connection between the epicranial and epidural spaces. Two EDH cases with fractures including the external auditory canal have been published in the literature and rapid spontaneous resolution without an increase in intracranial pressure was reported

(5,8). However, Gülşen et al. (9) reported a 4 year-old with a case of spontaneous resolution without skull fracture. In this case, hematoma was adjacent to cranial sutures and it was thought to be related to the opening in the sutures. According to the hypothesis of Malek et al. (4), blood and serous fluid in the epicranial space passes through the fracture into the epidural space due to increased pressure after head trauma, and then they pass into the epicranial space through fracture by counter flow as epicranial pressure decreases. However, this process is completed within about 18 hours, which is insufficient to explain the 3-hour resolution in our case. Furthermore, increased intracranial pressure was thought to be the cause of the counter flow of epidural hematoma into the epicranial area (3). However, increased intracranial pressure has been reported in

TABLE 1. Literature review of cases of spontaneous resolution of epidural hematoma within 24 hours

Author, years	Age/Sex	Location of hemorrhage	Size of hemorrhage	Skull fracture	Increased ICP	Epicranial hematoma	Time to resolution
Aoki et al. (2), 1988	8 years/M	Left temporal	15 mm	Yes	None	Increase	23 h
	17 years/M	Left occipital	10 mm	Yes	None	Increase	5 h
Servadei et al. (3), 1989	65 years/M	Right parietal	15 mm	Yes	Yes	NA	4 h
Kuroiwa et al. (7), 1993	17 years/M	Right occipital, posterior fossa	20 mm	Yes	None	NA	12 h
Malek et al. (4), 1997	17 months/M	Right temporal	8 mm	Yes	None	Increase	20 h
Akagami et al. (7), 1999	3,5 years/M	Left temporal	15 mm	Yes	None	Increase	16 h
Ugarriza et al. (5), 1999	43 years/M	Right temporal	22 mm	Yes	None	Increase	6 h
Wagner et al. (8), 2002	48 years/M	NA	NA	NA	NA	NA	1 h
Celikoglu et al. (8), 2002	8 years/M	Right temporal	10 mm	Yes	None	Increase	1 h
Kang et al. (8), 2005	34 years/M	Bilateral posterior fossa	NA	Yes	Yes	Increase	21 h
Neely et al. (6), 2005	2,5 years/F	Left parietal	10 mm	Yes	None	Increase	10 h
Eom et al. (7), 2009	13 years/F	Right temporal	18 mm	Yes	None	Increase	16 h
Dolgun et al. (8), 2011	27 years/M	Right temporal	12 mm	Yes	None	NA	3 h
Gulsen et al. (9), 2013	4 years/F	Right temporal	17 mm	No	None	NA	12 h
Present case	11 months/M	Right parietal	9 mm	Yes	None	Increase	3 h

M: male; F: female; NA: non-available; h: hours

only two of the cases published in the literature. According to another theory, bleeding from the diploic space during early phases of trauma spreads into the epidural and subgaleal spaces through fracture and passage into the subgaleal space from the epidural space happens due to the pulsatile effect of the brain (6). Tataryn et al. (10) have published a case of spontaneous resolutions without ICP increasing. This may have ultimately contributed to relatively lower pressure in the subgaleal space compared to the intracranial pressure and acted as a driving force, decompressing the hemorrhage into the subgaleal space. An increase in hematoma in the epicranial area was reported in 10 cases previously published in the literature (Table 1).

In our case, epidural hematoma was determined under the fracture and no significant hemorrhage was detected in the epicranial area on CT scan after trauma. However, on CT performed three hours later, hematoma in the epidural space was observed to be completely resorbed and hemorrhage was observed in the subgaleal area. There was no evidence of increased intracranial pressure on brain CT scan and neurological examination. We believe that the pressure difference between the epicranial and epidural spaces, which are connected to each other through the fracture, and brain pulsations are effective in the transfer of hemorrhage to the epicranial space as the cause of resolution of the EDH.

Although many theories have been postulated for the rapid spontaneous resolution of EDH, the cause is not yet fully understood. However, when previously published cases, including ours, are evaluated, we think that the most important factor in the rapid spontaneous resolution is the presence of a connection between the epidural and epicranial spaces, either through a fracture or cranial sutures.

Ethics Committee Approval: N/A.

Informed Consent: Written informed consent was obtained from the relatives of the patient who participated in this case.

Peer-review: Externally peer-reviewed.

Author contributions: Concept - F.A.; Design - F.A., M.Ç.; Supervision - F.A., M.Ç.; Resource - F.A.; Literature Search - F.A., Ö.K., F.B.S.; Writing - F.A.

Conflict of Interest: No conflict of interest was declared by the authors.

Financial Disclosure: The authors declared that this study has received no financial support.

REFERENCES

1. Pang D, Horton JA, Herron JM, Wilberger JE, Vries JK. Nonsurgical management of extradural hematomas in children. *J Neurosurg* 1983;59:958-71. [\[CrossRef\]](#)
2. Aoki N. Rapid resolution of acute epidural hematoma. Report of two cases. *J Neurosurg* 1988; 68:149-51. [\[CrossRef\]](#)
3. Servadei F, Staffa G, Pozzati E, Piazza G. Rapid spontaneous disappearance of an acute extradural hematoma: case report. *J Trauma* 1989;29:880-2. [\[CrossRef\]](#)
4. Malek AM, Barnett FH, Schwartz MS, Scott RM. Spontaneous rapid resolution of an epidural hematoma associated with an overlying skull fracture and subgaleal hematoma in a 17-month-old child. *Pediatr Neurosurg* 1997;26:160-5. [\[CrossRef\]](#)
5. Ugarriza LF, Cabezudo JM, Fernandez-Portales I. Rapid spontaneous resolution of an acute extradural hematoma: case report. *Br J Neurosurg* 1999;13:604-5. [\[CrossRef\]](#)
6. Neely JC 2nd, Jones BV, Crone KR. Spontaneous extracranial decompression of epidural hematoma. *Pediatr Radiol* 2008;38:316-8. [\[CrossRef\]](#)
7. Eom K, Park J, Kim T, Kim J. Rapid spontaneous redistribution of acute epidural hematoma: case report and literature review. *J Korean Neurosurg Soc* 2009;45:96-8. [\[CrossRef\]](#)
8. Dolgun H, Türkoğlu E, Kertmen H, Yılmaz ER, Ergun BR, Sekerci Z. Rapid resolution of acute epidural hematoma: case report and review of the literature. *Ulus Travma Acil Cerrahi Derg* 2011;17:283-5. [\[CrossRef\]](#)
9. Gülşen I, Ak H, Sösüncü E, Yavuz A, Kiymaz N. Spontaneous rapid resolution of acute epidural hematoma in childhood. *Case Rep Med* 2013;2013:956849. [\[CrossRef\]](#)
10. Tataryn Z, Botsford B, Riesenburger R, Kryzanski J, Hwang S. Spontaneous resolution of an acute epidural hematoma with normal intracranial pressure: case report and literature review. *Childs Nerv Syst* 2013;29:2127-30. [\[CrossRef\]](#)