



## EXPERIMENTAL STUDY

Acta Orthop Traumatol Turc 2015;49(6):676–682  
doi: 10.3944/AOTT.2015.15.0158

## Effect of pentoxifylline on healing of segmental bone defects and angiogenesis

Gökhan ÇAKMAK<sup>1</sup>, Mehmet Şükrü ŞAHİN<sup>1</sup>, B. Handan ÖZDEMİR<sup>2</sup>, Emre KARADENİZ<sup>1</sup>

<sup>1</sup>Başkent University Faculty of Medicine, Department of Orthopaedics and Traumatology, Antalya, Turkey

<sup>2</sup>Başkent University Faculty of Medicine, Department of Pathology, Ankara, Turkey

**Objective:** The aim of this study was to determine the effect of pentoxifylline (PTX) on angiogenesis and the healing of a critical-sized segmental defect of the radius diaphysis in a rat model, using radiological and histological grading systems.

**Methods:** The study included 24 female Sprague-Dawley rats (weight: 300±20 g) divided into 4 groups. A critical-sized segmental defect was created in the radius diaphysis in all rats. In Group 1, morcellized iliac crest autografts were used to fill the segmental bone defect. In Group 2, segmental bone defects were filled using morcellized iliac crest autografts, and 25 mg/kg/day PTX was applied intraperitoneally. In Group 3, the segmental bone defects were not filled, and in Group 4 the segmental bone defects were left unfilled, and an intraperitoneal (IP) dose of 25 mg/kg/day PTX was applied. Rats were sacrificed at postoperative Week 8, and defects were evaluated using radiographic, histological and immunohistochemical methods.

**Results:** There were significant differences between Group 1 and 2 according to radiological evaluation ( $p=0.003$ ) and quality of union at the defect site ( $p=0.01$ ). Union quality was higher in Group 4 than Group 3 ( $p=0.01$ ). Cluster of differentiation 31 (CD31) and vascular endothelial growth factor (VEGF) levels were higher in Group 2 than in Groups 3 and 4.

**Conclusion:** According to radiological and histological parameters, PTX appears to improve angiogenesis and healing of segmental cortical bone defects of the radius in a rat model.

**Keywords:** Bone graft; bone healing; cortical defect; pentoxifylline.

Angiogenesis is known as one of the most important and critical steps of bone formation and fracture healing, and is driven by a complex interaction of various cytokines. Complications such as delays in bone healing and nonunion may therefore be associated with altered concentrations of specific angiogenic factors. Pentoxifylline (PTX) is a xanthine derivative which has been approved for extensive clinical use.<sup>[1]</sup> It attenuates reperfusion-

associated membrane injury and tissue edema in order to suppress leukocyte adhesion and improve hindlimb blood flow during the reperfusion period.<sup>[2,3]</sup>

The aim of this study was to determine the effect of PTX through angiogenesis on the healing of critical-sized segmental defects of the radius diaphysis in a rat model, using radiological and histological grading systems.

**Correspondence:** Gökhan Çakmak, MD. Başkent Üniversitesi Alanya Araştırma ve Uygulama Merkezi, Saray Mah., Yunusemre Cad., No: 1, 07400 Alanya, Antalya, Turkey.

Tel: +90 242 – 510 25 25 e-mail: gokhancakmak75@gmail.com


**Submitted:** March 19, 2015 **Accepted:** May 17, 2015

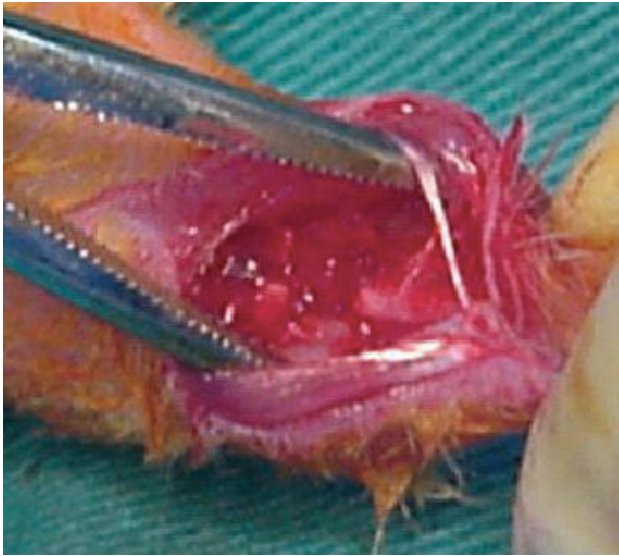
©2015 Turkish Association of Orthopaedics and Traumatology

Available online at  
www.aott.org.tr

doi: 10.3944/AOTT.2015.15.0158

QR (Quick Response) Code





**Fig. 1.** Critical-sized bone defect performed at the radius diaphysis. [Color figure can be viewed in the online issue, which is available at [www.aott.org.tr](http://www.aott.org.tr)]

## Materials and methods

The study was carried out at our institution's Animal Research Laboratories, and the experimental protocol was approved by the Ethics Committee.

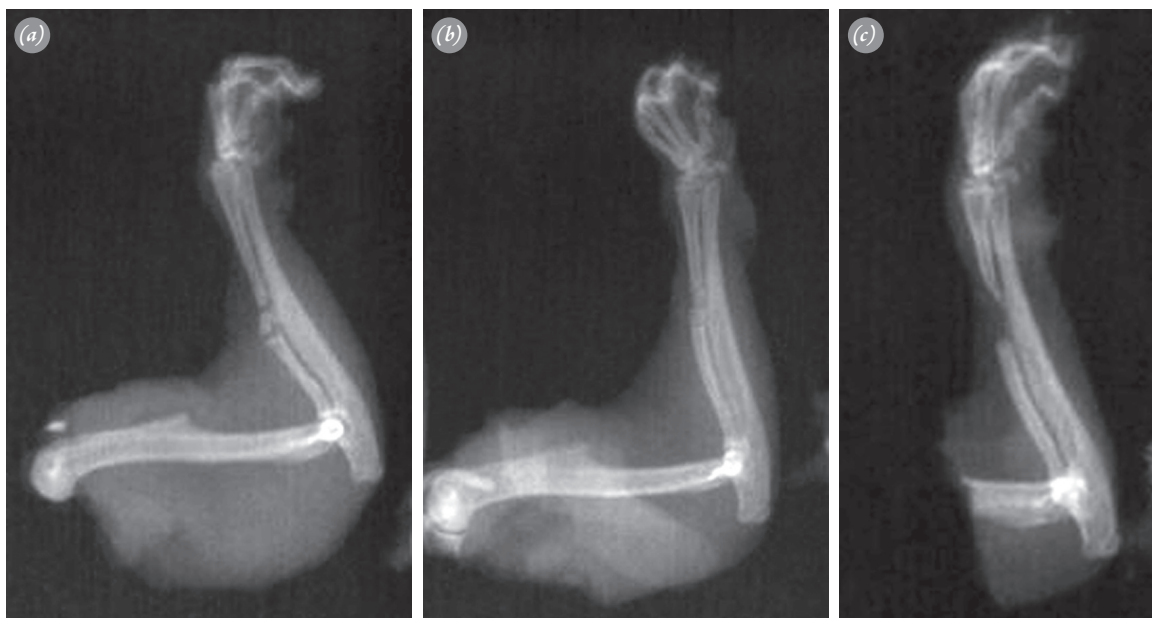
The study included 24 female Sprague-Dawley rats weighing approximately  $300 \pm 20$  g. Rats were kept in cages in groups of 6 at the same institution. All surgical procedures were carried out by the same surgeon under

ketamine and xylazine anesthesia.

The critical-sized defect model was performed, as described by other studies in the literature. The right forelimbs of the rats were shaved, prepared, and draped in a sterile fashion. A longitudinal incision was made on the radius, and the overlying tissues were dissected. The middle third of the radius diaphysis was osteotomized, and a segmental defect 2 times greater than the radius of the bone diaphysis was created (Figure 1).<sup>[4,6-8]</sup> The defect was irrigated using a saline solution. Postoperatively, the rats were randomly divided into 4 experimental groups: morcellized iliac crest autografts were used to fill in the segmental bone defects in Group 1; morcellized iliac crest autografts were used to fill the segmental bone defects, and a dose of 25 mg/kg/day PTX was given intraperitoneally in Group 2; segmental bone defects were not filled in Group 3; and the segmental bone defects were not filled and an intraperitoneal (IP) dose of 25 mg/kg/day PTX was administered in Group 4 rats. The skin was sutured postoperatively using monofilament 4-0 nylon thread.

Rats were sacrificed using a high dose of ketamine and xylazine at postoperative Week 8. The right forelimbs were dissected, with care taken to avoid damaging the callus tissues.

Anteroposterior radiographs were taken for each specimen (Figures 2a-c). Osseous union was graded according to the radiographic evaluation scale prepared by Cook et al.<sup>[4]</sup> No device was used for radiodensity mea-



**Fig. 2.** (a) Radiographic image of a segmental bone defect filled with morcellized iliac crest autograft. (b) Radiographic image of a segmental bone defect filled with morcellized iliac crest autograft and receiving IP 25 mg/kg/day PTX. (c) Radiographic image of a segmental bone defect which was not filled.

surement because previous studies have shown no need for any specific device for radiographic evaluation.<sup>[4–6,9]</sup>

Specimens were placed in a 10% formaldehyde solution for 24 hours and decalcified in 10% formic acid for 10 days. 5 µm slides were prepared, and specimens were stained using hematoxylin and eosin (HE). Histopathological evaluation was performed under light microscope. Bone healing was determined at the defect site. Histological evaluation was performed according to the histopathological evaluation scale used by Salkeld et al.<sup>[6,9–11]</sup>

Immunohistochemical evaluation was performed using cluster of differentiation 31 (CD31) and vascular endothelial growth factor (VEGF) antibodies (Leica Biosystems, Buffalo Grove, IL, USA) to determine evidence of angiogenesis. CD31 is a 130 kDa integral membrane protein, a member of the immunoglobulin super family that mediates cell-to-cell adhesion. It is also known as platelet endothelial cell adhesion molecule-1 (PECAM-1) and has been detected on bone marrow-derived hematopoietic stem cells and embryonic stem cells. CD31-mediated endothelial cell-cell interactions are involved in angiogenesis.<sup>[12–15]</sup> VEGF stimulates the mitosis of vascular endothelial cells, induces endothelial cell proliferation, promotes cell migration, and inhibits apoptosis. *In vivo* VEGF induces angiogenesis as well as permeabilization of blood vessels, and plays a central role in the regulation of vasculogenesis.

In the immunohistochemical evaluation, 3-µm thick sections were deparaffinized and mounted on Poly-L-lysine-coated slides. Sections were placed in a citrate buffer (0.01 mol/L; pH: 6), heated in a microwave oven for 15 min at maximum power (700 W), and cooled at room temperature for 20 min. Tissue sections were incubated with the primary antibodies CD31 and VEGF for 1 hr in a humidified chamber at room temperature. After washing in buffer, the slides were incubated with biotinylated goat anti-polyvalent for 15 min and in streptavidin peroxidase for an additional 15 min at room temperature. The slides were then developed for 12 min in diaminobenzidine and counterstained with hematoxylin. Positive and negative controls were used for immunostaining.

The density of microvessels highlighted by CD31 immunostaining was measured by grid at a magnification of x200 using an eyepiece screen with an examination area of 0.25mm<sup>2</sup>. Results are presented as the number of microvessels per unit of area.

VEGF was graded in a semiquantitative manner using a 1–3+ scale as follows: 1+ indicates that stained cells comprise <25% of the representative biopsy; 2+

indicates that stained cells comprise 25–50% of the representative biopsy; and 3+ indicates that stained cells comprise >50% of the representative biopsy.

Statistical evaluation was carried out using Statistical Package for the Social Sciences (SPSS) software (SPSS Inc., Chicago, IL, USA). Continuous variables are given as mean±SD, and categorical variables as numbers and percentages. Data were tested for normal distribution using the Kolmogorov-Smirnov test. Continuous variables were compared using the Mann-Whitney U test. The Kruskal-Wallis test was used for comparison of the categorical variables between groups. All tests of significance were two-tailed. A p value <0.05 was considered statistically significant.

## Results

The Kruskal-Wallis test revealed significant radiological differences between all groups (p<0.001). Radiological bone union was observed in Groups 1 and 2 only (p=0.006), and there was a significant difference between Groups 1 and 2 (p=0.006).

In the histological evaluation, Group 2 had better bone union quality than Group 1, while Group 4 had better bone union quality than Group 3. There were no significant differences between Groups 1 and 2 or between Groups 3 and 4 according to cortex formation-remodeling and graft incorporation-new bone formation.

Immunohistochemical evaluation showed that while there were no significant differences between Groups 1 and 2 in terms of CD31 staining, there were significant differences between Groups 1 and 2 in VEGF staining (union: p=0.007; cortex: p=0.031; graft: p=0.031). In addition, there were significant differences between Groups 2 and 3 and between Groups 2 and 4 for CD31 levels (p=0.004, p=0.026, respectively) and VEGF staining (union: p=0.03, p=0.002, respectively; cortex: p=0.01, p=0.014, respectively; graft: p=0.008, p=0.006, respectively). CD31 staining revealed significant differences between Groups 3 and 4 (p=0.017), while VEGF grades did not. CD31 level was highest in Group 2 (Table 1).

Callus formation and mineralization were observed at the bone defect sites in Groups 1 and 2. Significant osteoblastic activity was seen in Group 2 (Figure 3).

## Discussion

In the United States annually, 33 million people are affected by musculoskeletal injuries, and the incidence of bone fractures is approximately 6 million.<sup>[16,17]</sup> As bone fractures cause both loss of function and significant economic effects related to the subsequent loss of

**Table 1.** Distribution of the radiological, histological, and immunohistochemical evaluations among the groups.

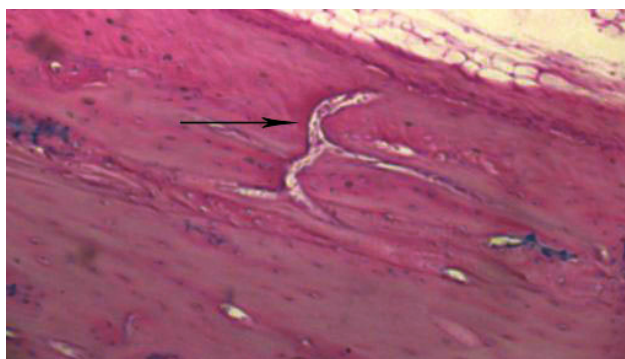Grade	Group 1		Group 2		Group 3		Group 4		p <sup>1</sup>	p <sup>2</sup>	p <sup>3</sup>	p <sup>4</sup>
	n	%	n	%	n	%	n	%				
X-ray												
0	0	0	0	0	5	100	6	100				
1	1	16.7	0	0	0	0	0	0				
2	4	66.6	0	0	0	0	0	0	0.006	1.0	<0.001	<0.001
3	1	16.7	3	50	0	0	0	0				
4	0	0	2	33.3	0	0	0	0				
5	0	0	1	16.7	0	0	0	0				
Histounion												
1	3	50	0	0	4	80	0	0				
2	3	50	2	33.3	1	20	6	100	0.011	0.009	0.145	0.003
3	0	0	4	66.7	0	0	0	0				
Histicortex												
0	0	0	0	0	3	60	2	33.3	0.784	0.313	0.008	0.045
1	3	50	4	66.7	2	40	3	50				
2	3	50	1	16.7	0	0	1	16.7				
3	0	0	1	16.7	0	0	0	0				
Histograft												
0	1	16.7	0	0	4	80	2	33.3	0.676	0.106	0.014	0.046
1	2	33.3	3	50	1	20	2	33.3				
2	0	0	2	33.3	0	0	2	33.3				
3	1	16.7	1	16.7	0	0	0	0				
4	2	33.3	0	0	0	0	0	0				
Histounion-VEGF												
0	0	0	0	0	1	20	0	0				
0	3	50	0	0	2	40	3	50	0.007	0.545	0.013	0.005
1	2	33.3	0	0	2	40	3	50				
2	1	16.7	6	100	0	0	0	0				
Histicortex-VEGF												
0	2	33.3	0	0	2	40	1	16.7				
0	2	33.3	1	16.7	3	60	3	50	0.031	0.190	0.071	0.025
1	2	33.3	2	33.3	0	0	2	33.3				
2	0	0	3	50	0	0	0	0				
Histograft-VEGF												
0	2	33.3	0	0	3	60	2	33.3				
0	2	33.3	1	16.7	2	40	4	66.7	0.031	0.399	0.010	0.011
1	2	33.3	2	33.3	0	0	0	0				
2	0	0	3	50	0	0	0	0				
CD31, mean±SD	33.1±11.3		35.0±11.1		11.7±5.7		18.1±7.7		0.310	0.017	<0.001	<0.001

p<sup>1</sup>: Comparison of Groups 1 and 2; p<sup>2</sup>: Comparison of Groups 3 and 4; p<sup>3</sup>: Comparison of Groups 1 and 2 and Groups 3 and 4; p<sup>4</sup>: Comparison of all groups.

Histounion: Histological bone union quality; Histicortex: Cortex formation-remodeling; Histograft: Graft incorporation and new bone formation; VEGF: Vascular endothelial growth factor; CD31: Cluster of differentiation 31.

productivity, treatment aims to provide sufficient and timely fracture healing. Upon fracture, hypoxic-necrotic sites develop due to reduced vascularization and oxygen pressure, and pH decreases. After this period, cytokines are excreted at the fracture site, and the healing period begins. Vascularization is important in this early stage and is managed by the cytokines which facilitate angio-

genesis. Angiogenesis is assisted by capillary circulation from non-injured bone sites. One of the most important vascular sites of the bone is the periosteal artery, with periosteal circulation playing an important role in early fracture healing.<sup>[11,16,18,19]</sup> Fracture healing is a unique type of wound healing response. While the majority of fractures heal well, some resist treatment and result in



**Fig. 3.** Osteoblastic activity, callus formation, and vascularization in a rat in Group 2 (HE: x12.5). [Color figure can be viewed in the online issue, which is available at [www.aott.org.tr](http://www.aott.org.tr)]

nonunion or malunion. In some cases, the fracture site must be supported by bone graft materials.<sup>[17,20,21]</sup> In recent decades, alternative biophysical and biological treatment methods have been developed for use in the event of impaired fracture healing. Such methods include stimulation of fracture healing using mechanical, electrical, and ultrasound methods; growth promoting proteins; and osteogenic, osteoconductive, and osteoinductive methods.<sup>[22–24]</sup> In the present study, we evaluated the adjuvant effect of PTX on the healing of segmental bone defects.

PTX is a xanthine derivative that has been proven to attenuate reperfusion-associated membrane injuries and tissue edema, as well as suppress leukocyte adhesion and improve hindlimb blood flow during the reperfusion period.<sup>[2,3]</sup> It has been shown to improve ischemia/reperfusion (I/R) injury by attenuating neutrophil sequestration, producing reactive oxygen species, and activating platelets.<sup>[3,25]</sup>

*In vitro* and *in vivo* studies have demonstrated that PTX significantly reduces production of cytokines, including tumor necrosis factor alpha (TNF- $\alpha$ ). The ability of the drug to decrease TNF- $\alpha$  level may be related to its ability to increase cyclic adenosine monophosphate (c-AMP). Due to the discovery of these multiple effects, several clinical studies have been conducted. Animal studies have documented a beneficial effect of PTX on spinal cord ischemia and I/R injury in the liver.<sup>[1,24–32]</sup> In a study using an animal spinal cord ischemia model, Zhu et al. concluded that PTX may induce protection against ischemia injury in the spinal cord, thereby preventing both necrosis and apoptosis.<sup>[1]</sup> Emreca et al. showed in their *in vivo* study that iloprost and PTX may reduce I/R injury in the early phase of skeletal muscle ischemia.<sup>[3]</sup>

Delenian et al. evaluated the administration of a combination of PTX and vitamin E with clodronate to reduce radiation-induced osteonecrosis and fibrosis, and report-

ed that the combination is useful in the healing of sternocostal and some mandibular osteoradionecrosis. They concluded that long-term use of PTX and vitamin E, combined with clodronate treatment, is effective, safe, and curative for the treatment of refractory osteoradionecrosis; furthermore, they found that it induces mucosa and bone healing, with significant symptom improvement.<sup>[33]</sup> In the current study, similar results on the effect of PTX on the angiogenesis and healing of bone were found.

Some *in vitro* studies have indicated that elevated levels of c-AMP enhance the bone-forming activity of osteoblasts.<sup>[34]</sup> Kimmel et al.<sup>[35]</sup> and Shen et al.<sup>[36]</sup> observed that c-AMP and c-AMP-dependent protein kinase may promote the growth response of rat bone to intermittent pulses of parathyroid hormone (PTH). In addition to the rate of synthesis of c-AMP by adenylate cyclase, c-AMP levels can be regulated by the rate of hydrolysis to the inactive form of 5' adenosine monophosphate (5' AMP) by cyclic nucleotide phosphodiesterases (PDEs). PDE inhibitors are effective in elevating intracellular c-AMP levels by inhibiting the breakdown of c-AMP by PDEs. Therefore, the administration of PDE-inhibiting compounds such as PTX may have the potential to increase bone mass by elevating intracellular c-AMP levels.<sup>[37]</sup>

Kinoshita et al.<sup>[38]</sup> reported that the administration of PTX increased the density of radiographs of rat femurs and vertebrae in a dose-dependent manner without changing body weight on densitometry analysis. Horiuchi et al.<sup>[39]</sup> injected PTX subcutaneously daily for 3 weeks from the day of implantation of bone morphogenetic protein (BMP)-laden disks and found that ossicles from mice treated with 50 mg/kg/day PTX were significantly larger in size and had greater calcium content. However, no differences were noted in mice treated with lower doses (5 and 25 mg/kg/day) of PTX. The authors did not find any significant differences in bone mineral density (BMD) between ossicles in the control and PTX treatment groups. The data from the study of Horiuchi et al.<sup>[39]</sup> indicated that PTX has an anabolic effect on BMP-induced ectopic new bone formation. Significant bone formation effect at the osteotomy sites was achieved with administration of 25 mg/kg/day PTX in the current study.

The exact mechanism by which PTX modulates bone formation remains unknown and may be related with the pharmacologic effects of the drug. PTX's ability to decrease TNF- $\alpha$  levels may be related to its ability to increase c-AMP. TNF- $\alpha$  is a cytokine which promotes bone resorption and inhibits bone formation. The reduced production of TNF- $\alpha$  in bone marrow as a result of PTX may produce an increase in BMD. In

addition, PDE inhibitors might improve bone formation through the pathway for bone morphogenetic proteins, which have the capacity to induce mesenchymal cells to differentiate into chondrocytic or osteoblastic lineage.<sup>[40]</sup> The high intracellular *c*-AMP levels in BMP-responding cells amplify the effects of BMP on the cells and stimulate the cell differentiation, causing bone formation.<sup>[37,41]</sup>

Kurtoğlu et al. attempted to determine the adverse effects of maternal nicotine exposure during pregnancy and lactation, and of the protective effect of PTX on neonatal rat bone development. They concluded that PTX supplementation prevented the adverse effects of maternal nicotine exposure (such as decreased birth weight, pregnancy weight gain, bone lengthening, and increased apoptosis) on BMD and birth weight.<sup>[37]</sup>

Aydin et al. evaluated the effect of PTX on closed femur shaft fractures after 2- and 3-week periods. While they concluded that PTX accelerated healing histologically in the early phases of fracture healing, the authors reported that this effect decreases in the long term. Moreover, infection rates in the PTX groups were high. The current study was designed with a longer study period than that of Aydin et al., and PTX was found histologically and radiologically to accelerate graft incorporation. There were no infections in any rats, despite our use of open surgery and grafting.<sup>[42]</sup>

In our study, rats that were administered PTX had better radiological graft incorporation and histological quality of union at the segmental cortical defects. Additionally, the non-grafted cortical defects of the rats which received PTX showed greater improvement in union quality than the control group (Group 3). These findings may be the result of the pharmacologic interaction of PTX in cellular response, which causes osteogenesis and angiogenesis. Angiogenesis is an important step in the healing process of the bone. Groups which were exposed to PTX had higher angiogenesis, with high CD31 and VEGF levels.

In conclusion, PTX appears to promote bone healing in segmental bone defects and have the ability to improve vascularization and osteogenesis at the defect site. Although there are many treatment methods for bone healing, the adjuvant effects of agents such as PTX should not be overlooked. Further *in vivo* and *in vitro* studies on these effects are necessary.

**Conflicts of Interest:** No conflicts declared.

## References

- Zhu DJ, Xia B, Bi Q, Zhang SJ, Qiu BS, Zhao C. Functional protection of pentoxifylline against spinal cord ischemia/reperfusion injury in rabbits: necrosis and apoptosis effects. *Chin Med J (Engl)* 2008;121:2444–9.
- Kishi M, Tanaka H, Seiyama A, Takaoka M, Matsuoka T, Yoshioka T, et al. Pentoxifylline attenuates reperfusion injury in skeletal muscle after partial ischemia. *Am J Physiol* 1998;274:H1435–42.
- Emreca B, Tulukoğlu E, Bozok S, Aksun M, Yağdı S, Özcan AV, et al. Iloprost and pentoxifylline attenuate ischemia-reperfusion injury in skeletal muscle in rabbit model. *Ulus Travma Acil Cerrahi Derg* 2008;14:182–7.
- Cook SD, Baffes GC, Wolfe MW, Sampath TK, Rueger DC. Recombinant human bone morphogenetic protein-7 induces healing in a canine long-bone segmental defect model. *Clin Orthop Relat Res* 1994;301:302–12.
- Boden SD, Zdeblick TA, Sandhu HS, et al. The use of rhBMP-2 in interbody fusion cages. Definitive evidence of osteoinduction in humans: a preliminary report. *Spine (Phila Pa 1976)* 2000;25:376.
- Salkeld SL, Patron LP, Barrack RL, Cook SD. The effect of osteogenic protein-1 on the healing of segmental bone defects treated with autograft or allograft bone. *J Bone Joint Surg Am* 2001;83-A:803–16.
- Ozturk AM, Cila E, Kanatli U, Isik I, Senkoylu A, Uzunok D, Piskin E. Treatment of segmental bone defects in rats by the stimulation of bone marrow osteo-progenitor cells with prostaglandin E2. *Int Orthop* 2005;29:73–7.
- Cakmak G, Bolukbasi S, Simsek A, Erdem O, Yilmaz G, Senkoylu A. Effect of synthetic cell-binding peptide on the healing of cortical segmental bone defects. *Saudi Med J* 2006;27:777–80.
- Bostrom M, Lane JM, Tomin E, Browne M, Berberian W, Turek T, et al. Use of bone morphogenetic protein-2 in the rabbit ulnar nonunion model. *Clin Orthop Relat Res* 1996;327:272–82.
- Bostrom MP, Yang X, Kennan M, Sandhu H, Dicarlo E, Lane JM. An unexpected outcome during testing of commercially available demineralized bone graft materials: how safe are the nonallograft components? *Spine (Phila Pa 1976)* 2001;26:1425–8.
- Brighton CT, Hunt RM. Early histological and ultrastructural changes in medullary fracture callus. *J Bone Joint Surg Am* 1991;73:832–47.
- Huss WJ, Hanrahan CF, Barrios RJ, Simons JW, Greenberg NM. Angiogenesis and prostate cancer: identification of a molecular progression switch. *Cancer Res* 2001;61:2736–43.
- Vecchi A, Garlanda C, Lampugnani MG, Resnati M, Matteucci C, Stoppacciaro A, et al. Monoclonal antibodies specific for endothelial cells of mouse blood vessels. Their application in the identification of adult and embryonic endothelium. *Eur J Cell Biol* 1994;63:247–54.
- Vanzulli S, Gazzaniga S, Braidot MF, Vecchi A, Mantovani A, Wainstok de Calmanovici R. Detection of en-

- dothelial cells by MEC 13.3 monoclonal antibody in mice mammary tumors. *Biocell* 1997;21:39–46.
15. DeLisser HM, Christofidou-Solomidou M, Strieter RM, Burdick MD, Robinson CS, Wexler RS, et al. Involvement of endothelial PECAM-1/CD31 in angiogenesis. *Am J Pathol* 1997;151:671–7.
  16. Einhorn TA. The cell and molecular biology of fracture healing. *Clin Orthop Relat Res* 1998;(355 Suppl):7–21.
  17. Szpalski M, Gunzburg R. Applications of calcium phosphate-based cancellous bone void fillers in trauma surgery. *Orthopedics* 2002;25(5 Suppl):601–9.
  18. Kelly CM, Wilkins RM, Gitelis S, Hartjen C, Watson JT, Kim PT. The use of a surgical grade calcium sulfate as a bone graft substitute: results of a multicenter trial. *Clin Orthop Relat Res* 200;382:42–50.
  19. Webb JCJ, Tricker J. A review of fracture healing. *Current Orthopaedics* 2000;14:457–63.
  20. Greenwald AS, Boden SD, Goldberg VM, Khan Y, Laurencin CT, Rosier RN. Bone-graft substitutes: facts, fictions, and applications. *J Bone Joint Surg Am* 2001;83-A Suppl 2 Pt 2:98–103.
  21. Buttermann GR, Glazer PA, Bradford DS. The use of bone allografts in the spine. *Clin Orthop Relat Res* 1996;324:75–85.
  22. Kerimoğlu S, Livaoglu M, Sönmez B, Yuluğ E, Aynaci O, Topbas M, et al. Effects of human amniotic fluid on fracture healing in rat tibia. *J Surg Res* 2009;152:281–7.
  23. Hannouche D, Petite H, Sedel L. Current trends in the enhancement of fracture healing. *J Bone Joint Surg Br* 2001;83:157–64.
  24. Einhorn TA. Enhancement of fracture-healing. *J Bone Joint Surg Am* 1995;77:940–56.
  25. Adams JG Jr, Dhar A, Shukla SD, Silver D. Effect of pentoxifylline on tissue injury and platelet-activating factor production during ischemia-reperfusion injury. *J Vasc Surg* 1995;21:742–9.
  26. Hoie EB, McGuire TR, Leuschen PM, Zach TL. Pentoxifylline inhibits tumor necrosis factor-alpha induced synthesis of complement component C3 in human endothelial cells. *Biol Pharm Bull* 2004;27:1670–3.
  27. Bombini G, Canetti C, Rocha FA, Cunha FQ. Tumour necrosis factor-alpha mediates neutrophil migration to the knee synovial cavity during immune inflammation. *Eur J Pharmacol* 2004;496:197–204.
  28. Feng D, Nagy JA, Pyne K, Dvorak HF, Dvorak AM. Ultrastructural localization of platelet endothelial cell adhesion molecule (PECAM-1, CD31) in vascular endothelium. *J Histochem Cytochem* 2004;52:87–101.
  29. Luu NT, Rainger GE, Buckley CD, Nash GB. CD31 regulates direction and rate of neutrophil migration over and under endothelial cells. *J Vasc Res* 2003;40:467–79.
  30. Kiyoshima T, Fukuda S, Matsumoto M, Iida Y, Oka S, Nakakimura K, et al. Lack of evidence for apoptosis as a cause of delayed onset paraplegia after spinal cord ischemia in rabbits. *Anesth Analg* 2003;96:839–46.
  31. Mackey ME, Wu Y, Hu R, DeMaro JA, Jacquin MF, Kanellopoulos GK, et al. Cell death suggestive of apoptosis after spinal cord ischemia in rabbits. *Stroke* 1997;28:2012–7.
  32. Oz Oyar E, Korkmaz A, Kardesş O, Omeroğlu S. Aortic cross-clamping-induced spinal cord oxidative stress in rabbits: the role of a novel antioxidant adrenomedullin. *J Surg Res* 2008;147:143–7.
  33. Delanian S, Chatel C, Porcher R, Depondt J, Lefaix JL. Complete restoration of refractory mandibular osteoradionecrosis by prolonged treatment with a pentoxifylline-tocopherol-clodronate combination (PENTOCLO): a phase II trial. *Int J Radiat Oncol Biol Phys* 2011;80:832–9.
  34. Ahlström M, Lamberg-Allardt C. Rapid protein kinase A-mediated activation of cyclic AMP-phosphodiesterase by parathyroid hormone in UMR-106 osteoblast-like cells. *J Bone Miner Res* 1997;12:172–8.
  35. Kimmel DB, Bozzato RP, Kronis KA, Coble T, Sindrey D, Kwong P, et al. The effect of recombinant human (1–84) or synthetic human (1–34) parathyroid hormone on the skeleton of adult osteopenic ovariectomized rats. *Endocrinology* 1993;132:1577–84.
  36. Shen V, Dempster DW, Birchman R, Xu R, Lindsay R. Loss of cancellous bone mass and connectivity in ovariectomized rats can be restored by combined treatment with parathyroid hormone and estradiol. *J Clin Invest* 1993;91:2479–87.
  37. Kurtoglu S, Gunes T, Koklu E, Bastug O, Canoz O, Kula M, et al. Influence of maternal nicotine exposure on neonatal rat bone: protective effect of pentoxifylline. *Exp Biol Med (Maywood)* 2007;232:398–405.
  38. Kinoshita T, Kobayashi S, Ebara S, Yoshimura Y, Horiuchi H, Tsutsumimoto T, et al. Phosphodiesterase inhibitors, pentoxifylline and rolipram, increase bone mass mainly by promoting bone formation in normal mice. *Bone* 2000;27:811–7.
  39. Horiuchi H, Saito N, Kinoshita T, Wakabayashi S, Tsutsumimoto T, Takaoka K. Enhancement of bone morphogenetic protein-2-induced new bone formation in mice by the phosphodiesterase inhibitor pentoxifylline. *Bone* 2001;28:290–4.
  40. Shimizu K, Yoshikawa H, Matsui M, Masuhara K, Takaoka K. Periosteal and intratumorous bone formation in athymic nude mice by Chinese hamster ovary tumors expressing murine bone morphogenetic protein-4. *Clin Orthop Relat Res* 1994;300:274–80.
  41. Lee YS, Chuong CM. Activation of protein kinase A is a pivotal step involved in both BMP-2- and cyclic AMP-induced chondrogenesis. *J Cell Physiol* 1997;170:153–65.
  42. Aydin K, Sahin V, Gürsu S, Mercan AS, Demir B, Yildirim T. Effect of pentoxifylline on fracture healing: an experimental study. *Eklemler Hastalik Cerrahisi* 2011;22:160–5.