



Int Surg 2017;**102**:367–376
DOI: 10.9738/INTSURG-D-16-00124.1

Approaches to Female Congenital Genital Tract Anomalies and Complications

Emine Ince¹, Pelin Oğuzkurt¹, Semire Serin Ezer¹, Abdülkerim Temiz¹, Hasan Özkan Gezer¹, Şenay Demir², Akgün Hiçsönmez¹

¹Departments of Pediatric Surgery and ²Radiology, Başkent University Faculty of Medicine, Ankara, Turkey

Objective: Female congenital genital tract anomalies may appear with quite confusing and deceptive complications. This study aims to evaluate the difficulties in diagnosis and treatment of female congenital genital tract anomalies that frequently present with complications.

Summary: During a 10-year period, we evaluated 20 female patients with congenital genital tract anomalies aged between 3 days and 16 years. All patients were retrospectively analyzed in terms of the results of diagnostic studies, surgical intervention, and treatment.

Methods: Ultrasonography and magnetic resonance imaging revealed hydromucocolpos or hematocolpometra, imperforate hymen, distal vaginal atresia, didelphys uterus, an obstructed right hemivagina, uterovaginal atresia, a unicornuate uterus with a noncommunicating rudimentary horn, a vesicovaginal fistula, a utero-rectal fistula, intraabdominal collection, and a vaginal calculus.

Results: Two patients had Mayer-Rokitansky-Küster-Hauser syndrome and 6 patients had obstructed hemivagina and ipsilateral renal anomaly syndrome. Definitive surgical interventions were hymenotomy, vaginal pull-through, vaginovaginostomy, and vesicovaginal fistula repair using a transvesical approach. In conclusion, female congenital genital tract anomalies may appear with a wide range of complications.

Conclusions: There is a potential to do significant harm, if the patient's anatomic problems are not understood using detailed imaging. Revealing the anatomy completely and defining the complications that have already developed are critical to tailor the optimal treatment strategies and surgical approaches.

Corresponding author: Emine Ince, MD, Başkent Üniversitesi Tıp Fakültesi, Adana Uygulama ve Araştırma Hastanesi, Çocuk Cerrahisi Kliniği, Seyhan Hastanesi Baraj Yolu, 1. Durak Seyhan /Adana, 01150, TURKEY.
Tel.: 90 322 458 68 68 1000; Fax: 90 322 459 26 22; E-mail: inceemine@yahoo.com

Key words: Female congenital genital tract anomalies – Hematocolpos – Hydromucocolpos
Imperforate hymen – Müllerian anomalies

Female congenital genital tract anomalies may present with different clinical appearances and deceptive complications. The most common condition seen in congenital malformations of the genital tract is imperforate hymen (IH) with an incidence of 1 in 1000 to 16,000 live births.¹ Müllerian duct anomalies (MDAs), which are rarely seen, result from the interruption of normal development of the female genital tract, which involves a series of complex processes characterized by the differentiation, migration, fusion, and subsequent canalization of the Müllerian system.^{2,3} Müllerian duct anomalies usually present with obstructive symptoms. The mass and compression symptoms due to mucocolpos are distinct in the neonatal and infantile periods, whereas hematometra and hematocolpos are prominent after menarche during the adolescent period.¹⁻³ Müllerian duct anomalies such as uterus didelphys, unicornuate uterus, rudimentary horn, distal vaginal atresia, transverse vaginal septum, and ipsilateral distal vaginal atresia are rare, and the exact incidence in the general population or infertile population still remains unclear.² Urinary system anomalies are most frequently defined as anomalies that accompany genital tract anomalies.⁴⁻⁷ Due to inappropriate physical examinations and laboratory evaluations in patients with recurrent abdominal pain and urinary tract infections, many types of complications may occur in these patients.

Genital tract anomalies and accompanying complications have been introduced in individual case reports in the literature. In the present study, we aimed to evaluate the difficulties in diagnosis and treatment of female congenital genital tract anomalies, which frequently present with complications in children to increase attention to this subject.

Materials and Methods

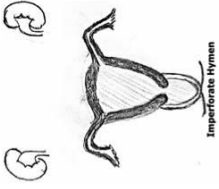
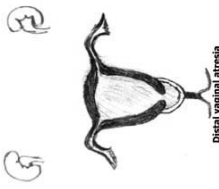
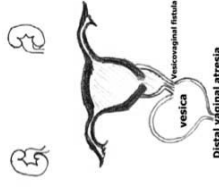
The study included 20 children with the diagnosis of congenital genital tract anomalies in our institution between January 2006 and April 2016. Patients with intersex anomalies and persistent cloacal anomalies were excluded from the study. The records of the patients were reviewed for age, complaints, diagnostic studies, associated malformations, surgical techniques used, and treatment results retrospectively. Ultrasonography (USG) was performed to evaluate the internal genital organs and the pelvic

region and to exclude associated urological malformations. In more complex cases, magnetic resonance imaging (MRI), a dimercaptosuccinic acid (DMSA) scan, voiding cystourethrography (VCUG), intravenous pyelography, and colon radiography were performed. All definitive surgeries were performed by 2 surgeons who had scientific knowledge, skills, and experience at the same levels. All patients were followed after hospital discharge with a mean follow-up of 2 years, and no eligible patients were excluded during the study.

Results




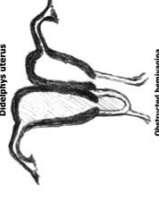


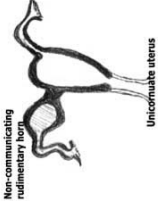




Twenty patients with a median age of 12.3 years (range: 3 days to 16 years) were included in the study. The presenting complaints were abdominal pain (n = 15), acute urinary retention or AUR (n = 11), abdominal distention (n = 4), antenatally detected cystic abdominal mass (n = 2). Physical examination revealed an abdominal mass (n = 17), vaginal dimple (n = 2), lower abdominal tenderness (n = 1), and bulging of hymenal membrane (n = 5) (Tables 1 and 2). Two patients, one of whom was a newborn baby, had impaired renal functions. All patients underwent USG evaluation. Abdominal MRI was performed in 16 patients. Additional imaging modalities were DMSA (n = 4), VCUG (n = 5), and barium enema (n = 1). Abdominal USG revealed a distended uterus and a vagina filled with hematocolpometra (n = 12), mucocolpos (n = 2), hydrocolpos (n = 3), uterus didelphys (n = 5), absences of uterovaginal structure (n = 2), torsion of the left ovary (n = 1), and bladder stone (n = 1). Unilateral renal agenesis (n = 7), hydroureteronephrosis or HUN (n = 3), and pelvic abscess (n = 1) has been identified as additional urinary system anomalies. Laryngeal web (n = 1), esophageal atresia with a tracheoesophageal fistula (n = 1), polydactyly (n = 1), corpus callosum agenesis (n = 1), and partial sacral agenesis (n = 1) were detected as other system anomalies (Tables 1 and 2). MRI was not needed because the diagnosis of the imperforate hymen was confirmed based on clinical and USG findings in 4 patients. Magnetic resonance imaging showed a normal uterus with distal vaginal atresia (n = 5), normal uterovaginal structure with HI (n = 3), absence of uterus and vagen (n = 2), uterus didelphys and duplicated vagen with right distal

Table 1 Clinical characteristics of patients with vaginal anomalies

n	Complaint (n)	Physical examination (n)	USG (n)	MRI (n)	Association with anomalies (n)	Drainage tube (n)	Diagnosis (n)	Operating (n)	Classification
7	AAP (6) AUR (6) Abdominal distension (1)	Suprapubic mass (6) Bulging IH (5) Abdominal mass (1)	Hematocolpometra (6) Mucocolpos (1) Hydrocolpos (2)	Cystic mass along the upper part of the vagina (3) causing compression on the urinary (2) Vaginal stone (1)	Left HUN (1) Right renal hypoplasia (1) Laryngeal web (1)	No (6) Yes (1)	IH (7) Vaginal stone (1)	Hymenotomy (7) Cystoscopy (1) Removal of vaginal stones (1)	 Imperforate Hymen
4	AAP (3) Antenatal abdominal cystic mass (1)	Suprapubic mass (3)	Hematocolpometra (2) Mucocolpos (1)	Cystic mass along the upper part of the vagina (4) Distal vaginal atresia (4)	Left nephrectomy (1) CRF (1) Partial sacral agenesis (1) Left HUN (1) Polydactyly (1)	Yes (3)	Distal vaginal atresia (4)	Cystoscopy (1) Laparotomy (1) Vaginal pull-through (4)	 Distal vaginal atresia
1	Antenatal abdominal cystic mass	Giant abdominal cystic mass	Hydrocolpos	Vaginal cavity was filled with hydrocolpos, distal vaginal atresia	Left HUN	Yes	Distal vaginal atresia VVF	Laparotomy, repair of vesicovaginal fistula, Vaginal pull-through	 Distal vaginal atresia

AAP, acute abdominal pain; AUR, acute urinary retention; CRF, chronic renal failure; HUN, hydronephrosis; IH, imperforate hymen; MRI, magnetic resonance imaging; USG, ultrasonography; VVF, vesicovaginal fistula.

Table 2 Clinical characteristics of patients with Müllerian duct anomalies

n	Complaint (n)	Physical examination	USG (n)	MRI (n)	Association with anomalies (n)		Diagnosis (n)	Syndrome (n)	Operating (n)	Classification
					Drainage tube (n)	with anomalies (n)				
2	AAP (2)	Vaginal Dimple (2)	Uterovaginal atresia (2) Torsion of the left ovary (1)	Uterovaginal atresia (2) Torsion of the left ovary (1)	EA+TEF (1)	Solitary ectopic Kidney (1) EA+TEF (1)	Uterovaginal atresia (2)	MRKH (2)	Laparoscopy (2) Left oophorectomy (1)	 
4	AAP (3) AUR (4)	Suprapubic mass (3) Abdominal mass (1)	Didelphys uterus (4) Obstructed right hemivagina (4) Hematocolpometra (4)	Didelphys uterus (4) Obstructed right hemivagina (4) Hematocolpometra (4)	Right renal agenesis (4) Corpus callosum agenesis (1)	Right renal agenesis (4) Corpus callosum agenesis (1)	Didelphys uterus (4) Obstructed right hemivagina (4)	HWW (4)	Vaginostomy (4) Vaginostomy (4)	  
1	AAP, AUR	Lower abdominal tenderness Suprapubic mass	Uterus didelphis, intensive abscess collection	Unicornuate uterus with a left single horn open into a normal vagina and a contralateral non-communicating rudimentary horn	Right renal agenesis Utero-rectal fistula	Right renal agenesis Utero-rectal fistula	Unicornuate uterus, non-communicating rudimentary horn, utero-rectal fistula	OHVIRA	Colostomy Laparoscopy Rudimentary horn excision	  
1	AAP	Suprapubic mass	Hematocolpometra	Unicornuate uterus, hematocolpos, distal vaginal atresia left tube agenesis	Right renal agenesis	Right renal agenesis	Distal vaginal atresia	OHVIRA	Laparotomy, Vaginal pull-through	  

AAP, acute abdominal pain; AUR, acute urinary retention; EA + TEF, esophageal atresia with tracheoesophageal fistula; HWW, Herlyn-Werner-Wunderlich syndrome; MRI, magnetic resonance imaging; MRKH, Mayer-Rokitansky-Küster-Hauser syndrome; OVIRA, obstructed hemi-vagina with ipsilateral renal agenesis; USG, ultrasonography.

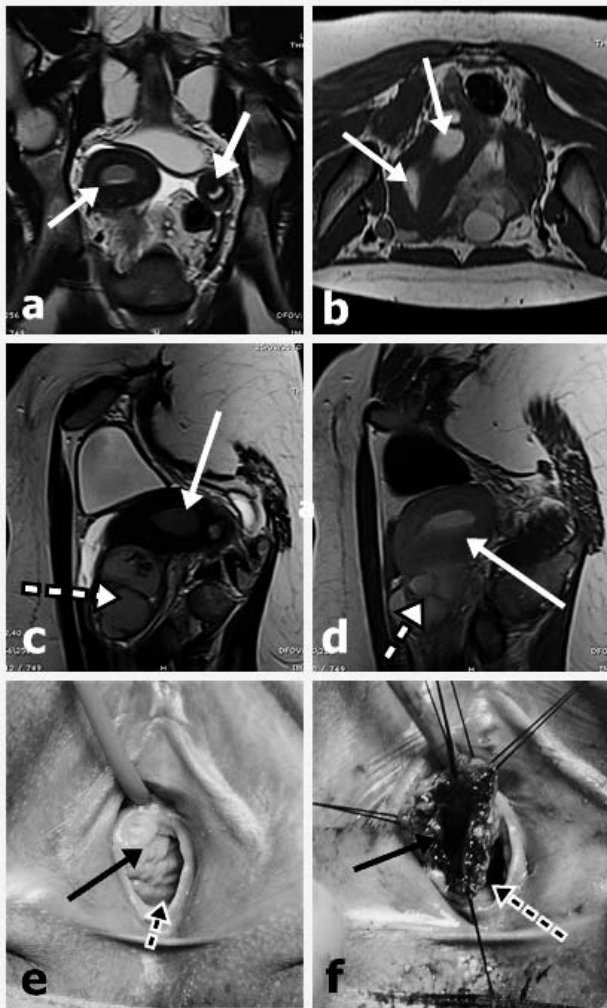


Fig. 1 OHVIRA syndrome. A 14-year-old female patient presented with the triad of didelphys uterus (CIII), an obstructed right hemivagina, and ipsilateral renal agenesis. (a, b) Coronal and axial T2-weighted MRI demonstrated complete duplication of the uterine horns (arrows). (c, d) Sagittal T2-weighted MRI showed a distended right uterus (white arrows) with a transverse vaginal septum causing unilateral hematocolpos (dashed arrows). (e) Clinical examination demonstrated duplication of the vagina, forming a distended obstructed hemivagina (black arrow) and non-obstructed hemivagina (dashed arrow). (f) Surgical opening of the vaginovaginostomy. MRI, magnetic resonance imaging.

vaginal atresia and renal agenesis (n = 4), a unicornuate uterus without horn, distal vaginal atresia, and right renal agenesis (n = 1), a unicornuate uterus with noncommunicating horn and renal agenesis (n = 1) (Figs. 1, 2, and 3). The last 6 patients were diagnosed with obstructed hemivagina and ipsilateral renal anomaly (OHVIRA) syndrome. MRI represented the vaginal calculus,

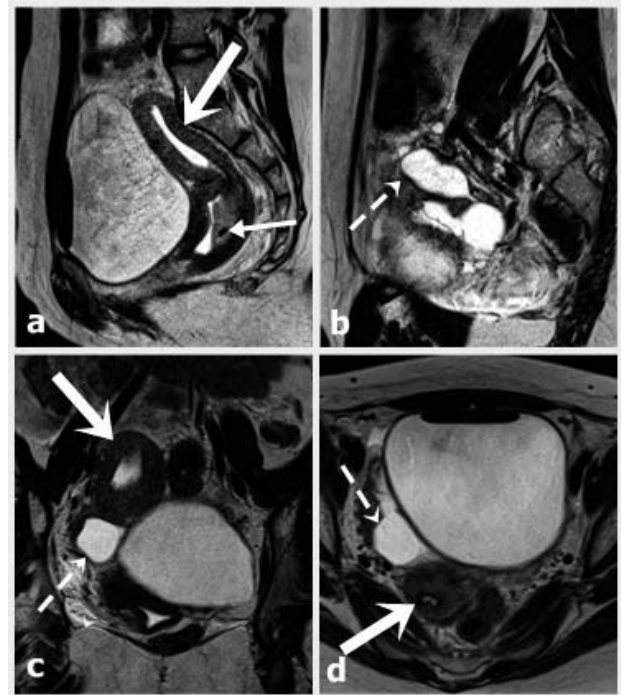


Fig. 2 A 14-year-old female patient presented with a unicornuate uterus without horn (CIId). (a) Sagittal T2-weighted MRI illustrated the classic banana-shape caused by the distended unicornuate uterus (bold arrow), compatible with hematocolpos (thin arrow). (b, c, d) Coronal and axial T2-weighted MRI demonstrated a unicornuate uterus (bold arrows) and hydrosalpinx (dashed arrows). MRI, magnetic resonance imaging.

which was defined as bladder stone by USG. Two patients were diagnosed with Mayer-Rokitansky-Küster-Hauser (MRKH) syndrome due to uterine and vaginal agenesis, which were demonstrated absence of uterus and vagen with MRI (Table 2). A percutaneous drainage catheter was inserted in 8 patients with hydrocolpos, hematocolpometra, or pelvic abscess. Radiography via a percutaneous drainage catheter demonstrated the utero-rectal fistula in a patient with the unicornuate uterus with noncommunicating horn (Fig. 3). Definitive interventions were performed between 3 days and 2 years (median: 1 month) after first admission. Hymenotomy was performed in 7 patients with HI. In one of them who developed vaginal calculus, an urethrovaginal fistula was detected during cystoscopy. Urethrovaginal fistula was repaired by vaginal route after hymenotomy. The calculus was fragmented and removed by vaginoscopy at the same session. Vaginal pull-through was performed as a perineal and abdominoperineal approach in 4 and 2 patients, respectively. The diagnoses of these

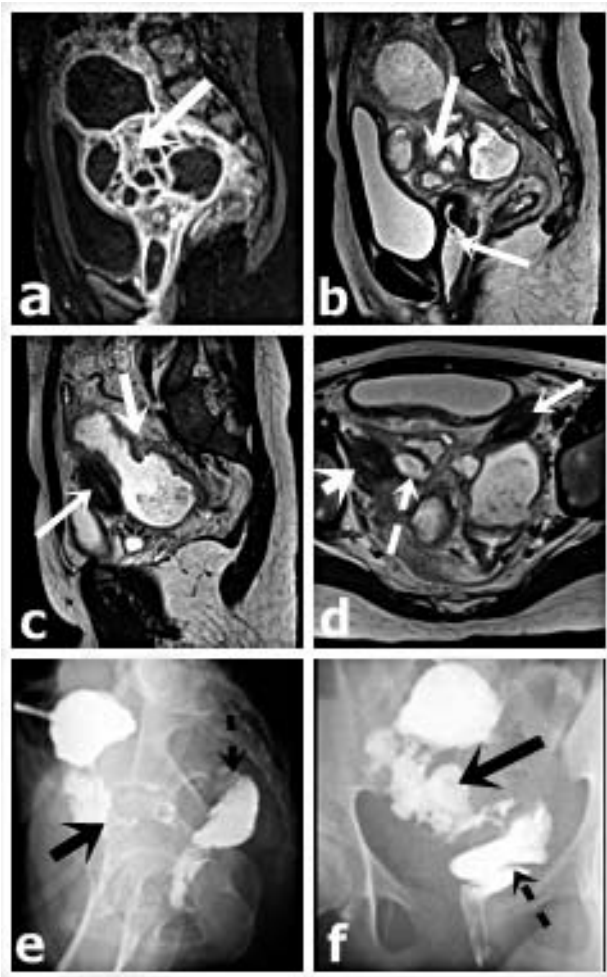
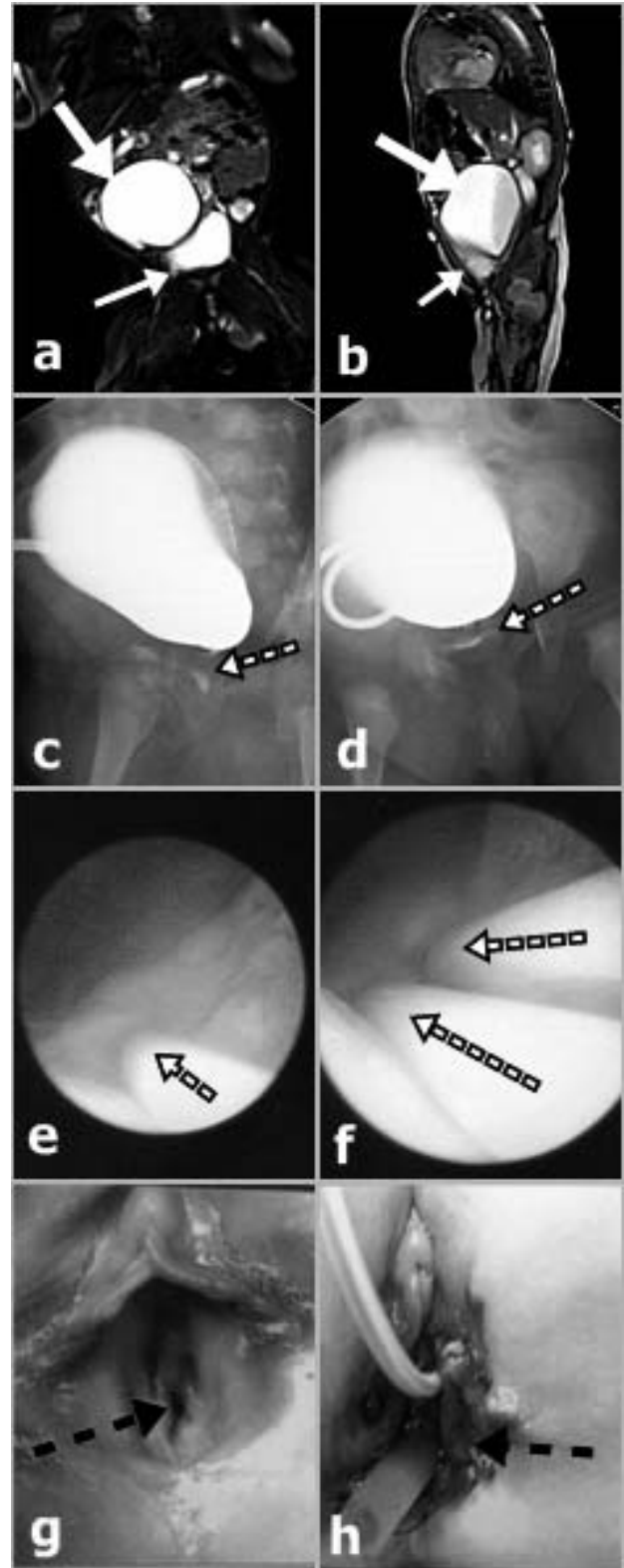


Fig. 3 A 16-year-old female patient presented with a unicornuate uterus and rudimentary horn (CIIB). (a, b, c) Sagittal T2-weighted MRI illustrated an intensive abscess collection (bold arrows) and a uterus normally communicating with a non-obstructed hemivagina (thin arrows). (d) Axial T2-weighted MRI illustrated 2 separate uterine horns (bold arrows) and hydrosalpinx (dashed arrows). (e, f) Radiography performed with a percutaneous drainage catheter demonstrated the opaque substance passing into the rectum (black arrow). MRI, magnetic resonance imaging.

patients were “unicornuate uterus without horn with distal vaginal atresia” and “distal vaginal atresia with normal uterine structure” in 1 and 5 patients, respectively. Cystoscopy revealed 2 vesicovaginal fistula (VVF) in 1 patient with distal vaginal atresia. Transvesical fistula repair and vaginal pull-through were done at 3 months of age of patients with VVF (Fig. 4). Vaginovaginostomy with vaginal septum excision was performed by transvaginal approach in 4 patients with uterus



didelphys and right distal vaginal atresia (Fig. 1) (Tables 2). The patient with the diagnosis of unicornuate uterus with noncommunicating horn had pelvic abscess. Percutaneous drainage was ineffective. For this reason the patient underwent laparotomy.

Laparotomy demonstrated intestinal adhesion and abscess collection and utero-rectal fistula between noncommunicating horn and rectum (Fig. 3). The abscess was evacuated; adhesiolysis and colostomy were performed. One month later, the noncommunicating rudimentary horn was excised laparoscopically. Colon radiography was normal 1 month later. Then colostomy was closed. The symptoms of HUN regressed following definitive surgery in the patients with hydronephrosis developed secondary to the mass compression. Two patients who underwent hymenotomy required 2 sessions of vaginal dilatation under general anesthesia. The mean follow-up duration was 5 years (range: 2 to 7 years). Three adolescent patients have normal menstrual cycles.

This study was conducted at Baskent University, medical faculty, after the approval of the Ethics Committee (Project no: KA15/318) and was conducted in conformance with the principles of the Declaration of Helsinki. A written informed consent was obtained from each parent. Statistical analysis was performed using the Statistical Package for the Social Sciences (SPSS, Inc., Chicago, Illinois), version 17.0. Data were analyzed using descriptive statistical methods.

Discussion

The paramesonephric ducts protrude from the dorsal wall of the urogenital sinus as the Müllerian canal, from which the vaginal plate arises at the end

of nine weeks of gestation.^{8–10} The hymen forms at the junction of the vaginal plate and urogenital sinus. It is imperforate during early fetal development. It ruptures prenatally, leaving a residual hymen of variable configuration.¹ Failure of this development results with congenital genital tract anomalies. Some authors have suggested that fusion anomalies may cause uterus didelphys and congenital VVF, which appears after duplication or early bifurcation of the ureteric bud.^{4,6,11} Genital tract anomalies may present with several types and different complications in females. These anomalies may lead to incorrect diagnosis and unnecessary and inaccurate operative procedures without detailed imaging and understanding of the anatomy. Revealing the anatomy completely is essential in defining the complications, which have already occurred as well as in tailoring the treatment and surgeries, which are needed. Most of the previous studies included adult patients and most of these patients were diagnosed during an infertility examination.^{1–3} However, there are only a few reports about matter in childhood and most of them are case reports.^{1,5,7,12}

A reliable classification system seems to be extremely useful for their management, and effective categorization allows correct diagnosis and more appropriate treatment as well as a better understanding of the underlying pathophysiology.^{2,3,12–14} Patients with congenital genital tract anomalies may present with an intraabdominal mass and compression symptoms due to mucocolpos during the neonatal and infantile periods.^{1,13} Post-menarche abdominal pain, chronic constipation, lower back pain, AUR, urinary tract infection, and primary amenorrhea can be seen in adolescence period.^{1,5,7,12} AUR secondary to mass effects of distended uterine or vaginal cavities occur due to compression to the urethra, urethral angulations, and obstruction. The incidence of AUR reported between 3% and 46%.^{4,15,16} Nagai *et al*¹³ reported a newborn with acute renal failure concomitant IH. Three patients presented with an antenatal cystic mass, mucocolpos, and hydrocolpos during the neonatal and infantile periods whereas 15 patients presented with recurrent abdominal pain and tenderness, and difficulty in urinating during adolescence in the present study. Two of them with renal function impairment were presented in current study. Percutaneous drainage was adequate for clinical and laboratory improvement in a newborn with bilateral hydronephrosis and acute renal failure. The second case was a 14-year-old girl

Fig. 4 (a, b) Coronal and sagittal T2-weighted MRI demonstrated hyperintense fluid in the distended remnant vagina (bold arrow) and bladder (thin arrow). (c, d) Contrast vaginography was performed via a percutaneous drainage catheter inserted to the distal vaginal atresia, and a fistulous trajectory was visualized. (e, f) Cystoscopy revealed two VVFs (dashed arrows). (g) A sole vulvar orifice (urethral meatus) was located very distant from the clitoris. Absence of the vaginal introitus was noted (dashed arrow). (h) The urorectal septum was surgically opened to access the blind vagina and suture it to the skin graft (dashed arrows). MRI, magnetic resonance imaging; VVF, vesicovaginal fistula.

diagnosed with distal vaginal atresia and chronic renal failure on admission. This clinical condition was considered to be the result of vesicoureteral reflux and bladder dysfunction, which developed secondary to mass effects of distended uterovaginal cavity. Percutaneous drainage should be considered as primary procedure in patients who present with urinary tract symptoms or renal insufficiency secondary to mass effects. After improve of clinical condition, definitive surgical procedure of primary anomaly should be planned.

Although imperforate hymen is a rare condition, it is the most common obstructive anomaly of the female genital tract.^{1,17} In the present study, 7 patients were diagnosed with IH. One of them presented with renal function impairment in neonatal period. Hymenotomy is the standard treatment for this anomaly and can be done with X, T, cross, or cruciate incisions or resection of the excess tissues. However, sometimes even a small central circular hymenectomy may resolve the problem and provide a permanent cure in almost all cases.^{12-14,16,18,19} Recurrent urinary retention may develop due to inadequate hymenectomy; therefore, close monitoring during the postoperative period is necessary.^{12,14,16,18,19} In the present study, a standard hymenotomy with cross incision was performed in 7 patients, and recurrent urinary retention or infection were not observed. We think that the shape of the incision is not important.

Cases of concurrent IH and a primary vaginal calculus have been reported in the literature, to date.^{20,21} We encountered a complicated and unusual 6-year-old case with tenderness and abdominal pain from a stone that misevaluated as bladder stone by ultrasound. However the diagnosis of the primary vaginal calculus secondary to an urethrovaginal fistula was proved by interpretation of MRI findings and cystoscopy and vaginoscopy. Surgical procedures included hymenotomy, fragmentation and removing of calculus, primary repair of urethrovaginal fistula were performed by vaginal route with limited surgical intervention. These fistulas are likely to repeat despite adequate repair. As a result, recurrent infections or vaginal discharge may also occur.

Distal vaginal atresia is also very rare entity in children. Vaginal pull-through is most preferred approach in treatment of distal vaginal atresia. However, colovaginoplasty may occur in selected patients with long atretic segment.¹⁰ The sigmoid segment is providing an excellent tissue for vaginal replacement. Ileal loop is an alternative intestinal

choice. Several chronic complications including introital stenosis, mucosal prolapse, partial small bowel obstruction, perineal wound hematoma, or vaginal prolapse may develop secondary to vaginal reconstruction by intestinal segments. However vaginal pull-through reduces complication rates as a result of limited dissection selected patients. Vaginal pull-through was adequate and performed perineal or abdominoperineal approach in all of our patients. We did not need colovaginoplasty in any patients.

VVF, which is a result of intrauterine developmental anomaly, may be accompanying distal vaginal atresia and other genital and urinary anomalies.^{4,11} Continuous urinary incontinence and cyclic hematuria were reported in childhood and early adulthood, respectively in previous study about distal vaginal atresia with VVF. US, video urodynamics, and MRI were inadequate for the diagnosis of VVF while they demonstrated the distal vaginal atresia.^{4,5,11,22} Repair of congenital VVF with distal vaginal atresia has usually been reported by the abdominal approach, vaginally or the transvesical route.^{4,11,22} The vaginal atresia should be corrected with fistula repair in the same operation. It is an uneasy operation with risk of complications. Rectoneovaginal fistula was reported.⁴ The author has associated this complication with no thick urorectal septum plane.⁴ In the present patient, fistula repair with transvesical approach and vaginal pull-through procedures were performed at 3 months of age in the present patient. Our patient has reported the smallest in the literature. She had undergone 3 vaginal dilatation sessions, and at 3 years of follow-up, she did not develop any complications. In the present patient, surgical correction could also be done via abdominal approach. However, we think that the transvesical approach requires more limited dissection without pelvic dissection. Also the possibility of complications is less.

OHVIRA syndrome, formerly known as Herlyn-Werner-Wunderlich (HWW) syndrome, is a rare entity characterized by the triad of uterus didelphys, obstructive hemivagina, and ipsilateral renal agenesis.^{5-7,10,11,22-25} There have been also few reports of varied uterine anatomy, such as a septate uteri, a unicornuate uterus with noncommunicating horn, or a unicornuate uterus without horn.⁵⁻⁷ The standard surgery is defined as septectomy, or marsupialization of the blind hemivagina.^{7,23,24} In the present study, there were a total of 6 patients with OHVIRA syndrome, 4 of whom were the

classical type. The patients presented with abdominal pain, difficulty of micturition, and a pelvic mass. Four patients with classical OHVIRA syndrome underwent vaginovaginostomy and were uneventfully followed. The other 2 patients with non-classic type of OHVIRA syndrome underwent surgical interventions included vaginal pull-through and rudimentary noncommunicating horn excision appropriate to anatomic and clinical condition. MRKH syndrome is characterized by congenital aplasia of the uterus and two-thirds of the vagina.²⁶ This syndrome is caused by the interruption of the Müllerian duct during embryonic development. It may either be isolated (type I MRKH) or may occur in conjunction with renal, cardiac, or skeletal system anomalies or hearing defects (type II MRKH).²⁶ In the present study, 2 patients were diagnosed with MRKH syndrome and scheduled for colovaginoplasty. We attempted to classify different anomalies according to clinical, radiologic findings. Definitive surgery was planned based on the results of detailed physical examination and radiologic imaging scans include USG and MRI, and laparoscopy, vaginoscopy, or cystoscopy. However, our study is limited by the retrospective nature of the analysis and heterogeneity of the patients. Although there is no prospective clinical study about effects of surgical age on patients' psychology and sexual functions, we believe that MDAs must be corrected at a pediatric age to obtain better aesthetic and functional results. We are convinced that early correction in childhood can prevent various psychologic reflections on self-esteem and sexuality in adolescence or adulthood. In the future we are planning a study with psychologists and gynecologists about these patients' evaluations. In conclusion, our results suggest that accurate early diagnosis is critical, as the treatment for these anomalies is based on the type of the abnormality. Revealing the anatomy completely is the essential and critical stage to perform appropriate surgical procedures and to avoid unnecessary operation and to prevent complications.

Furthermore, in conclusion, the patients with uterovaginal anomalies can administer with different clinical presentations at different ages. In each patient, detailed examination and imaging studies should be performed before planning the surgical intervention. Evaluation and treatment planning should be individualized in each patient. This can be avoided during unexpected situations during surgery. Complications can be minimized.

Acknowledgments

Emine Ince, Pelin Oğuzkurt, Semire Serin Ezer, Abdülkerim Temiz, Hasan Özkan Gezer, Şenay Demir, and Akgün Hiçsönmez have no financial disclaimers or conflicts of interest. The authors' contributions are as follows: E. Ince: project development, data collection, manuscript writing; P. Oğuzkurt: protocol, project development; S.S. Ezer: data collection; A. Temiz: manuscript writing, editing; H.Ö. Gezer: data collection, data analysis; Ş. Demir: data analysis; and A. Hiçsönmez: editing. There was no funding for this paper.

References

1. Deligeoroglou E, Deliveliotou A, Makrakis E, Creatsas G. Concurrent imperforate hymen, transverse vaginal septum, and unicornuate uterus: a case report. *J Pediatr Surg* 2007;**42**(8):1446–1448
2. Grimbizis GF, Gordts S, Di Spiezio Sardo A, Brucker S, De Angelis C, Gergolet M *et al*. The ESHRE–ESGE consensus on the classification of female genital tract congenital anomalies. *Gynecol Surg* 2013;**10**(3):199–212
3. Chan YY, Jayaprakasan K, Tan A, Thornton JG, Coomarasamy A, Raine-Fenning NJ. Reproductive outcomes in women with congenital uterine anomalies: a systematic review. *Ultrasound Obstet Gynecol* 2011;**38**(4):371–382
4. Martínez Escoriza JC, Lobato JJ, Lorda E, De Vera M, Moya A, Ramirez R *et al*. Congenital vesicovaginal fistula with menouria: An anomaly of the urogenital sinus. *Eur J Obstet Gynecol Reprod Biol* 2011;**159**(2):472–475
5. Adair L 2nd, Georgiades M, Osborne R, Ng T. Uterus didelphys with unilateral distal vaginal agenesis and ipsilateral renal agenesis: Common presentation of an unusual variation. *J Radiol Case Rep* 2011;**5**(1):1–8
6. Bandhu S, Gunabushanam G, Kriplani A, Kuriakose AM. Congenital vesicovaginal fistula with partial vaginal agenesis. *Clin Radiol* 2006;**61**(7):630–633
7. Del Vecovo R, Battisti S, Di Paola V, Piccolo CL, Cazzato RL, Sansoni I *et al*. Herlyn-Werner-Wunderlich syndrome: MRI findings, radiological guide (two cases and literature review), and differential diagnosis. *BMC Medical Imaging* 2012;**12**:4
8. Chandler TM, Machan LS, Cooperberg PL, Harris AC, Chang SD. Mullerian duct anomalies: from diagnosis to intervention. *Br J Radiol* 2009;**82**(984):1034–1042
9. Saravelos SH, Cocksedge KA, Li TC. Prevalence and diagnosis of congenital uterine anomalies in women with reproductive failure: a critical appraisal. *Hum Reprod Update* 2008;**14**(5):415–429
10. Ruggeri G, Gargano T, Antonellini C, Carlini V, Randi B, Destro F *et al*. Vaginal malformations: A proposed classifica-

- tion based on embryological, anatomical and clinical criteria and their surgical management (an analysis of 167 cases). *Pediatr Surg Int* 2012;**28**(8):797–803
11. Dolan LM, Easwaran SP, Hilton P. Congenital vesicovaginal fistula in association with hypoplastic kidney and uterus didelphys. *Urology* 2004;**63**(1):175–177
 12. Rabani SM. A rare non-urologic cause for urinary retention; report of 2 cases. *Nephrourol Mon* 2013;**5**(2):766–768
 13. Nagai K, Murakami Y, Nagatani K, Nakahashi N, Hayashi M, Higaki T *et al.* Life threatening acute renal failure due to imperforate hymen in an infant. *Pediatr Int* 2012;**54**(2):280–282
 14. Ghadian A, Heidari F. Is hymenotomy enough for treatment of imperforated hymen? *Nephrourol Mon* 2013;**5**(5):1012
 15. Sarathi V, Naregal A, Lila AR, Bandgar T, Shah NS. Mucocolpos in a toddler: Central precocious puberty with vaginal atresia. *Endocr Pract* 2012;**18**(6):e144–146
 16. Temizkan O, Kucur SK, Açar S, Gözükarı I, Akyol A, Davas I. Virginity sparing surgery for imperforate hymen: Report of two cases and review of literature. *J Turk Ger Gynecol Assoc* 2012;**13**(4):278–280
 17. Mou JW, Tang PM, Chan KW, Tam YH, Lee KH. Imperforate hymen: cause of lower abdominal pain in teenage girls. *Singapore Med J* 2009;**50**(11):e378–379
 18. Mwenda AS. Imperforate hymen – A rare cause of acute abdominal pain and tenesmus: Case report and review of the literature. *Pan Afr Med J* 2013;**15**:28
 19. Abu-Ghanem S, Novoa R, Kaneti J, Rosenberg E. Recurrent urinary retention due to imperforate hymen after hymenotomy failure: a rare case report and review of the literature. *Urology* 2011;**78**(1):180–182
 20. Oguzkurt P, Ince E, Ezer SS, Temiz A, Demir S, Hicsonmez A. Primary vaginal calculus secondary to urethrovaginal fistula with imperforate hymen in a 6-year-old girl. *J Pediatr Surg* 2009;**44**(7):e11–13
 21. Garcia Liger J, Tomas Ross M, Naves Pastor J, Gracia GF, Semperegutierrez A, Rico Galiano J *et al.* Primary vaginal lithiasis associated with urethrovaginal fistula. Report of a case and review of the literature. *Actas Urol Esp* 2001;**25**(8):582–585
 22. Chin AI, Rutman M, Raz S. Transverse vaginal septum with congenital vesical-vaginal communication and cyclical hematuria. *Urology* 2007;**69**(3):575.e5–7
 23. Smith NA, Laufer MR. Obstructed hemivagina and ipsilateral renal anomaly (OHVIRA) syndrome: management and follow-up. *Fertil Steril* 2007;**87**(4):918–922
 24. Afrashtehfar CD, Piña-Garcia A, Afrashtehfar KI. Müllerian anomalies. Obstructed hemivagina and ipsilateral renal anomaly syndrome (OHVIRA). *Cir Cir* 2014;**82**(4):460–471
 25. Gungor Ugurlucan F, Bastu E, Gulsen G, KurekEken M, Akhan SE. OHVIRA syndrome presenting with acute abdomen: a case report and review of the literature. *Clin Imaging* 2014;**38**(3):357–359
 26. Üstüner I, Keskin L, Öztürk Ö, Özyiğit E, Avsar AF. Mayer-Rokitansky-Küster-Hauser (MRKH) sendromu. *Yeni Tıp Dergisi* 2008;**25**(4):241–244

© 2017 Ince et al.; licensee The International College of Surgeons. This is an Open Access article distributed under the terms of the Creative Commons Attribution Non-commercial License which permits use, distribution, and reproduction in any medium, provided the original work is properly cited, the use is non-commercial and is otherwise in compliance with the license. See: <http://creativecommons.org/licenses/by-nc/3.0>