

**OLGU SUNUMU/CASE REPORT****Association between treatment with coil embolization of renal artery aneurysm and resistant hypertension**

Coil embolizasyon ile tedavi edilmiş renal arter anevrizmasıyla dirençli hipertansiyon arasındaki ilişki

Enes Duman¹, Erkan Yıldırım¹, Özgür Çiftçi², Egemen Çifçi¹

¹Başkent Üniversitesi Konya Uygulama ve Araştırma Merkezi Radyoloji Bölümü; ²Kardiyoloji Bölümü; Konya, Turkey

Cukurova Medical Journal 2016;41(3):584-585.

Abstract

Hypertension is the number one risk factor in preventable causes of death in the world. Resistant hypertension is defined as blood pressure that remains uncontrolled despite at least three antihypertensive medications including a diuretic. Treatment of hypertension includes many modalities from lifestyle changing to multiple drug using, angioplasty. In this case report, we aim to emphasize the effects of renal artery aneurysm treatment on resistant hypertension.

Key words: Renal artery aneurysm, resistant hypertension, embolization

Öz

Hipertansiyon dünyada önlenabilir ölüm nedenleri arasında bir numaralı risk faktörüdür. Dirençli hipertansiyon bir tanesi diüretik olmakla birlikte en az üç tane antihipertansif ilaç kullanılmasına rağmen kontrol altına alınamayan hipertansiyon olarak olarak tanımlanır. Hipertansiyon tedavisi yaşam tarzı değişikliklerinden çoklu ilaç kullanımına, anjiyoplastiye kadar çeşitli modaliteler içerir. Bu sunumda renal arter anevrizma tedavisinin dirençli hipertansiyona olan etkisini vurgulamayı amaçladık.

Anahtar kelimeler: Renal arter anevrizması, dirençli hipertansiyon, embolizasyon

INTRODUCTION

Hypertension is the number one risk factor in preventable causes of death in the world. As of the year 2000, 26.4% of the adult population has hypertension in the world and this rate is expected to rise to 29.2 % in 2025. In other words, there are still 972 million people with hypertension and 25 years later, this number will surpass 1.5 billion¹. Treatment of hypertension includes many modalities from lifestyle changing to multiple drug using, angioplasty^{2,3}. We aimed to emphasize the effects on resistant hypertension of the renal artery aneurysm treatment that it is a rare factor.

CASE REPORT

A sixty seven years old woman patient who had resistant hypertension. was referred to our interventional radiology unit to perform renal angiography. Although she had used combined

antihypertensive therapy (angiotensin-converting-enzyme inhibitor, calcium channel blocker, diuretics, alpha-1 blockers, beta blockers), blood pressure was not on control. Under standart sterile conditions, we punctured right femoral artery with 18G needle (Bio-art medical, Istanbul, Turkey) by sonographic guidance, we placed 5F vascular sheath (Medtronic, Minneapolis, Mexico) then we put pig-tail catheter (Boston scientific, Nanterre, France) with the aid of guide wire. After contrast agent injections, there were no stenosis on renal arteries but there was a saccular aneurysm on distal brunch of right renal artery (Figure 1). We planned with cardiology doctors that she would have used another antihypertensive drug (aldosterone receptor blockers) for two weeks. If the blood pressure still wasn't on control we would have treated renal artery aneurysm. Two weeks later, tension was higher so we planned the treatment. We informed patient before treatment and she signed the patient consent form.

Yazışma Adresi/Address for Correspondence: Dr. Enes Duman, Başkent Üniversitesi Konya Uygulama ve Araştırma Merkezi, Radyoloji Bölümü, Konya, Turkey. E-mail: drenesduman@hotmail.com
Geliş tarihi/Received: 01.12.2015 Kabul tarihi/Accepted: 07.02.2016

Under standart sterile conditions, we punctured femoral artery with 18G needle, we placed 6F 45cm vascular sheath (Medtronic, Minneapolis, Mexico) with the aid of guide wire. We have catheterized right renal artery selectively with 5F cobra catheter (Terumo Europe, Leuven, Belgium) following on the taking angiographic images, micro catheter was placed as coaxial into the aneurysm sac. We

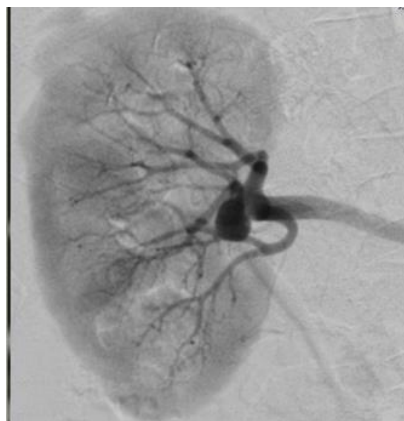

Figure 1. Renal artery aneurysm

embolized the aneurysm with coils using the micro catheter (Figure 2). Aneurysm was completely shut down with coils and renal flow was normal, so operation was terminated. Combined antihypertensive therapy was reduced to the dual therapy as a controlled in two months. She's using only angiotensin-converting-enzyme inhibitor and diuretics; blood pressure is on control.

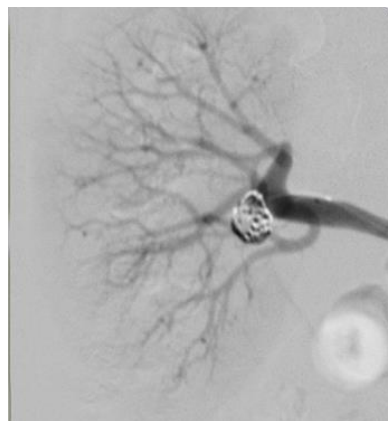


Figure 2. Aneurysm was embolized with coils

DISCUSSION

Resistant hypertension is defined as blood pressure that remains uncontrolled despite at least three antihypertensive medications including a diuretic. Its prevalence varies from 15% to 27%. Its prognosis is poor due to multiple cardiovascular risk factors such as obesity, diabetes and chronic kidney disease. The evaluation of patients with resistant hypertension focuses on identifying contributing factors and secondary causes of hypertension, including hyperaldosteronism, obstructive sleep apnea, chronic kidney disease, renal artery stenosis, Cushing's syndrome and pheochromocytoma. Treatment includes: exclusion of pseudo-resistance, identification and correction of contributing factors and/or secondary causes of hypertension, adoption of lifestyle changes, and use of effective multidrug antihypertensive regimens. Recommendations for the pharmacological treatment of resistant hypertension remain largely empiric due to the lack of systematic assessments of three or four drug combinations. However, studies indicate that the addition of spironolactone to standard treatment regimens induces significant blood pressure reduction in patients with resistant hypertension⁴. In our case; patient used five combined

antihypertensive therapy, then additionally she used another drug (aldosterone receptor blockers) but tension was not on control. After treatment of the renal artery aneurysm, resistant hypertension was disappeared. Patient has been using only angiotensin-converting-enzyme inhibitor and diuretics for two years. In patients with resistant hypertension; renal artery aneurysm should also be kept in minds and endovascular coil embolization is the most effective and reliable treatment method for renal artery aneurysm.

REFERENCES

1. Altun B, Arıcı M, Nergizoğlu G, Derici U, Karatan o, Turgan C et al. Prevalence, awareness, treatment and control of hypertension in Turkey in 2003. *J Hypertens.* 2005;23:1817-23.
2. Chobanian AV, Bakris GL, Black HR, Cushman WC, Green LA, Izzo JL Jr et al. Seventh report of the Joint National Committee on prevention, detection, evaluation and treatment of high blood pressure. *Hypertension.* 2003;42:1206–52.
3. Kaplan NM. *Kaplan's Clinical Hypertension.* 8th ed. Philadelphia, Lippincott Williams and Wilkins, 2002.
4. Sarafidis PA, Bakris GL. Resistant hypertension: an overview of evaluation and treatment. *J Am Coll Cardiol.* 2008;52:1749–57.