



THE AGA KHAN UNIVERSITY

eCommons@AKU

---

Section of Neurosurgery

Department of Surgery

---

1-20-2016

## Cerebellopontine angle primitive neuroectodermal tumor mimicking trigeminal schwannoma

Saad Akhtar Khan

Badar Uddin Ujjan

Adnan Salim

Muhammad Shahzad Shamim

Follow this and additional works at: [https://ecommons.aku.edu/pakistan\\_fhs\\_mc\\_surg\\_neurosurg](https://ecommons.aku.edu/pakistan_fhs_mc_surg_neurosurg)



Part of the [Neurology Commons](#), [Neurosurgery Commons](#), and the [Surgery Commons](#)

---

## Case Report

# Cerebellopontine angle primitive neuroectodermal tumor mimicking trigeminal schwannoma

Saad Akhtar Khan, Badar Uddin Ujjan, Adnan Salim<sup>1</sup>, Shahzad ShamimDepartment of Neurosurgery, Aga Khan University Hospital, <sup>1</sup>Dow Medical College, Dow University of Health Sciences, Karachi, PakistanE-mail: Saad Akhtar Khan - [saad.akhtar@aku.edu](mailto:saad.akhtar@aku.edu); Badar Uddin Ujjan - [badar.ujjan@aku.edu](mailto:badar.ujjan@aku.edu); Adnan Salim - [adnansalim7@outlook.com](mailto:adnansalim7@outlook.com);\*Shahzad Shamim - [shahzad.shamim@aku.edu](mailto:shahzad.shamim@aku.edu)

\*Corresponding author

Received: 04 July 15    Accepted: 25 November 15    Published: 20 January 16

## Abstract

**Background:** Primitive neuroectodermal tumors (PNETs) comprise a group of aggressive, poorly differentiated embryonal tumors occurring in central nervous system as well as in peripheral locations. Primary cerebellopontine angle (CPA) PNET is an extremely rare entity. It is important to have knowledge of this pathology and to be able to differentiate it from other commonly occurring CPA tumors, such as vestibular and trigeminal schwannomas. This distinction is essential because of the difference in the overall treatment plan and prognosis.

**Case Description:** This report describes a case of a young male presenting with diplopia and numbness of face; magnetic resonance imaging showed a CPA mass. With a provisional diagnosis of trigeminal schwannoma, the patient underwent surgery. Histopathology provided a diagnosis of PNET.

**Conclusion:** We discuss the importance of recognizing this rare condition and how this entity differs from the commonly occurring tumors.

**Key Words:** Cerebellopontine angle, primitive neuroectodermal tumor, schwannoma, trigeminal, vestibular

### Access this article online

**Website:**[www.surgicalneurologyint.com](http://www.surgicalneurologyint.com)**DOI:**

10.4103/2152-7806.174599

**Quick Response Code:**

## INTRODUCTION

The term primitive neuroectodermal tumor (PNET) refers to a group of poorly differentiated embryonal tumors occurring predominantly in children and adolescents and exhibit aggressive behavior.<sup>[10]</sup> One of the best characterized of these tumors is the medulloblastoma, which occurs in the posterior fossa while those occurring in the cerebrum are morphologically identical to the aforementioned, they are referred to as supratentorial PNETs.<sup>[13]</sup> Similar tumors occurring outside the central nervous system (CNS) are referred to as peripheral PNETs.<sup>[9]</sup> In the cerebellopontine angle (CPA) and internal acoustic meatus (IAM), these malignant tumors were shown to comprise only 0.1% of the cases.<sup>[4]</sup> The most common tumor in this location is the vestibular schwannoma (acoustic neuroma), meningioma, cavernoma,

lymphoma, schwannomas of other cranial nerves, and secondary deposits are also found.<sup>[1,4,5,9,11]</sup>

Management of most CPA tumors can be planned on the basis of contrast-enhanced magnetic resonance imaging (MRI). Here, we present a case of a young male with a suspected CPA trigeminal schwannoma which turned out to be a PNET. Clinical and pathological features are discussed.

This is an open access article distributed under the terms of the Creative Commons Attribution-NonCommercial-ShareAlike 3.0 License, which allows others to remix, tweak, and build upon the work non-commercially, as long as the author is credited and the new creations are licensed under the identical terms.

**For reprints contact:** [reprints@medknow.com](mailto:reprints@medknow.com)

**How to cite this article:** Khan SA, Ujjan BU, Salim A, Shamim S. Cerebellopontine angle primitive neuroectodermal tumor mimicking trigeminal schwannoma. *Surg Neurol Int* 2016;7:7.

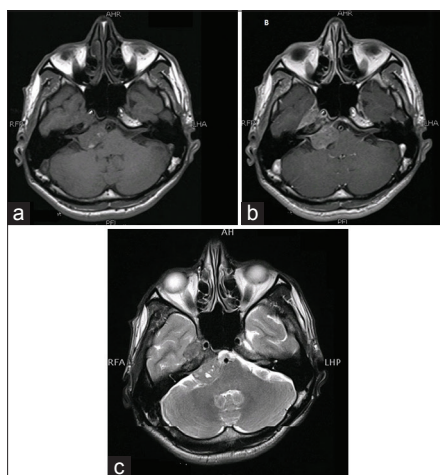
<http://surgicalneurologyint.com/Cerebellopontine-angle-primitive-neuroectodermal-tumor-mimicking-trigeminal-schwannoma/>

## CASE HISTORY

A 21-year-old gentleman presented with numbness of right side of the face for 1 month, and diplopia for 1 week. Neurological examination showed numbness in right V1, V2 distribution, and paresis of right VI nerve. Rest of the examination yielded normal findings. He had an MRI scan done 2 months previously which showed a homogeneously enhancing mass restricted to right CPA. However, in view of, the progression of signs and neurological examination, MRI was repeated which despite a time lapse of just a month showed the progression of disease, with the lesion now extending to the cavernous sinus. It now showed abnormal signal intensity, measuring 3.4 cm × 3 cm × 3 cm, with superior extension into the Meckel's cave and inferior extension up to the foramen ovale. A few hyperintense signals were noted within this lesion on T1-weighted images with mild postcontrast enhancement. Mass effect was also noted with compression of adjacent midbrain with a slight deviation to the left, which was not present in the initial imaging. This progression in size and extension of the tumor had occurred in the span of just 2 months [Figure 1].

This led to suspicion of a different pathology in the CPA other than trigeminal schwannoma, and an intraoperative frozen section was requested.

The patient underwent right retrosigmoid craniotomy, and the lesion was found to have a malignant appearance. Tissue sent for intraoperative frozen section was also suggestive of a high-grade neoplasm. The tumor in the CPA was completely excised, but the part extending to the cavernous sinus was left behind.



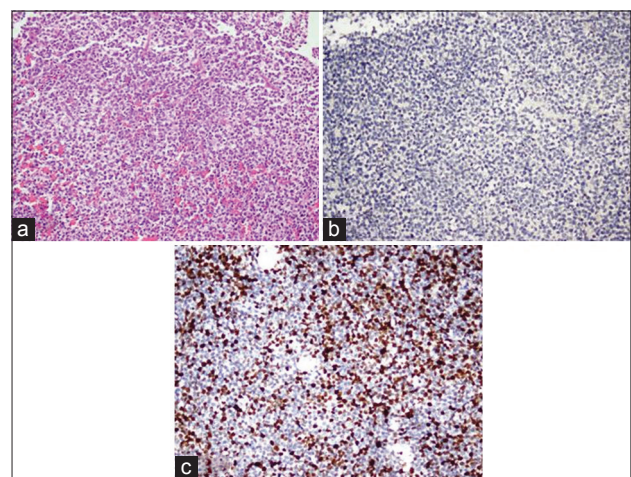
**Figure 1:** (a) T1-weighted magnetic resonance image showing iso- to hypo-intense lesion in the right cerebellopontine angle region extending into the right temporal lobe. (b) The lesion showing homogeneous enhancement on T1-weighted postcontrast image. (c) T2-weighted image showing grossly hypointense signal with areas of hyperintensity

The patient recovered well with a new onset ipsilateral Grade II facial weakness. On histopathology, the lesion was composed of sheets of neoplastic cells having round to ovoid hyperchromatic nuclei with variation in size and scant cytoplasm. Inward vessels were seen in between the sheets of neoplastic cells. Brisk mitotic activity was noted. Periodic acid–Schiff ± diastase stain highlights the presence of glycogen in the neoplastic cells. Immunohistochemical stains performed showed the cells to be positive for CD1010 (Mic-2) and focally positive for neuron-specific enolase. On the other hand, glial fibrillary acidic protein, leukocyte common antigen, Pan B (CD21), Pan T (CD3), Tdt, cytokeratin AE1/AE3, CD56, and synaptophysin tested negative. These findings confirmed a diagnosis of PNET [Figure 2].

Postoperative MRI showed residual lesion in the cavernous sinus. Computed tomography chest, abdomen, and pelvis did not show any peripheral disease. Spinal axis MRI was done which was negative for drop metastasis. The patient was started on chemotherapy with vincristine sulfate, and cisplatin was also added to the regimen. He also had multiple cycles of radiotherapy. The patient's condition worsened after 6 months and repeated MRI showed the extensive progression of disease. After a detailed discussion with the patient and his family, he was placed on palliative care.

## DISCUSSION

The term PNET was first used in 1983 in an attempt to help to differentiate and categorize an unusual group of quite undifferentiated brain tumors.<sup>[8]</sup> PNETs are highly malignant neoplasms with small cells on histology, mostly found in pediatric age group and



**Figure 2:** (a) Sheets of undifferentiated primitive appearing round cells (H and E, ×400). (b) Negative in tumor cells (inset; positive external control on the same slide) (GFAP immunostain, ×100). (c) A very high proliferative index (MiB-1 immunostain, ×200 magnification)

in young adults.<sup>[2]</sup> It was thought to be derived from multipotential cells arising from the primitive neural tube, and therefore, was collectively classified as PNET, but a consensus could not be reached regarding the term, and it was argued that pathological entities such as pineoblastoma, ependymblastoma, and retinoblastoma could not be justified under the single term of PNET.<sup>[12]</sup>

PNET can be further classified as central PNETs found in the brain or spinal cord, and peripheral PNETs found outside the CNS.

In CNS, extraaxial CPA medulloblastomas and other PNETs are rare neoplasms.<sup>[7]</sup> A recent article reported two cases of CPA medulloblastomas which were preoperatively diagnosed as vestibular schwannoma and petrosal meningioma on radiological basis. These cases are comparable to ours.<sup>[15]</sup>

Although the most common CPA tumor in patients presenting with facial hypesthesia and diplopia is trigeminal schwannoma, other tumors, such as vestibular schwannoma, meningioma, cavernoma, metastatic tumors to the region, or even lymphoma can also be found.<sup>[4,6,11,14,16]</sup> PNET has also been reported, and it comprises 0.1% of tumors primarily arising at CPA and IAM regions of brain. Most of these are metastatic PNET from peripheral site.<sup>[3]</sup> We report a case of primary CPA PNET with no evidence of disease peripherally.

This rare presentation of the CPA tumor is important with regards to the differential diagnoses, due to the fact that most small sized CPA tumors are usually considered to be vestibular or trigeminal schwannomas, and may be left without surgery. However, as in our case, the rapid progression of symptoms aroused suspicion and imaging was repeated which helped decide an urgent intervention. We would, therefore, recommend early repeat imaging after initial diagnosis of even apparently benign lesions, as an unusual pathology can never be entirely excluded. Moreover, a high index of suspicion should always prompt an intraoperative frozen section or smear to help decide further management.

## Financial support and sponsorship

Nil.

## Conflicts of interest

There are no conflicts of interest.

## REFERENCES

1. Akay KM, Erdogan E, Izci Y, Kaya A, Timurkaynak E. Medulloblastoma of the cerebellopontine angle – Case report. *Neurol Med Chir (Tokyo)* 2003;43:555-8.
2. Allen JC, Epstein F. Medulloblastoma and other primary malignant neuroectodermal tumors of the CNS. The effect of patients' age and extent of disease on prognosis. *J Neurosurg* 1982;57:446-51.
3. Bederson JB, von Ammon K, Wichmann WW, Yasargil MG. Conservative treatment of patients with acoustic tumors. *Neurosurgery* 1991;28:646-50.
4. Brackmann DE, Bartels LJ. Rare tumors of the cerebellopontine angle. *Otolaryngol Head Neck Surg (1979)* 1980;88:555-9.
5. Erdem A, Ugur HC, Diren B. False-positive findings on magnetic resonance imaging mimicking vestibular schwannoma. Case illustration. *J Neurosurg* 2000;92:733.
6. Fukaya R, Yoshida K, Ohira T, Kawase T. Trigeminal schwannomas: Experience with 57 cases and a review of the literature. *Neurosurg Rev* 2010;34:159-71.
7. Gaffney CC, Sloane JP, Bradley NJ, Bloom HJ. Primitive neuroectodermal tumours of the cerebrum. Pathology and treatment. *J Neurooncol* 1985;3:23-33.
8. Hart MN, Earle KM. Primitive neuroectodermal tumors of the brain in children. *Cancer* 1973;32:890-7.
9. Kalamarides M, Dewolf E, Couvelard A, Shahidi A, Bouccara D, Cyna-Gorse F, et al. Extraaxial primitive neuroectodermal tumor mimicking a vestibular schwannoma: Diagnostic and therapeutic difficulties. Report of two cases. *J Neurosurg* 2001;94:612-6.
10. Louis DN, Ohgaki H, Wiestler OD, Cavenee WK, Burger PC, Jouvet A, et al. The 2007 WHO classification of tumours of the central nervous system. *Acta Neuropathol* 2007;114:97-109.
11. Moffat DA, Saunders JE, McElveen JT Jr, McFerran DJ, Hardy DG. Unusual cerebello-pontine angle tumours. *J Laryngol Otol* 1993;107:1087-98.
12. Rubinstein LJ. A commentary on the proposed revision of the World Health Organization classification of brain tumors for childhood brain tumors. *Cancer* 1985;56 7 Suppl: 1887-8.
13. Simmons MA, Luff DA, Banerjee SS, Ramsden RT. Peripheral primitive neuroectodermal tumour (pPNET) of the cerebellopontine angle presenting in adult life. *J Laryngol Otol* 2001;115:848-52.
14. Smyth MD, Pitts L, Jackler RK, Aldape KD. Metastatic spinal ependymoma presenting as a vestibular schwannoma. Case illustration. *J Neurosurg* 2000;92 2 Suppl: 247.
15. Spina A, Boari N, Gagliardi F, Franzin A, Terreni MR, Mortini P. Review of cerebellopontine angle medulloblastoma. *Br J Neurosurg* 2013;27:316-20.
16. Yoshida K, Kawase T. Trigeminal neurinomas extending into multiple fossae: Surgical methods and review of the literature. *J Neurosurg* 1999;91:202-11.