

Effect of 0.05% topical cyclosporine for the treatment of symptomatic subepithelial infiltrates due to adenoviral keratoconjunctivitis

Ilkay Kilic Muftuoglu¹, Yonca A. Akova², Sirel G. Gungor³

¹Department of Ophthalmology, Istanbul Training and Research Hospital, Istanbul 34098, Turkey

²Department of Ophthalmology, Bayindir Kavaklidere Hospital, Ankara 06490, Turkey

³Department of Ophthalmology, Başkent University, Ankara 06490, Turkey

Correspondence to: Yonca A. Akova. Department of Ophthalmology, Bayindir Kavaklidere Hospital, Atatürk Bulvarı No: 201 06250 Kavaklidere, Ankara 06490, Turkey. yoncaakova@yahoo.com

Received: 2014-07-29 Accepted: 2015-07-07

DOI:10.18240/ijo.2016.04.26

Muftuoglu IK, Akova YA, Gungor SG. Effect of 0.05% topical cyclosporine for the treatment of symptomatic subepithelial infiltrates due to adenoviral keratoconjunctivitis. *Int J Ophthalmol* 2015;9(4):634–635

Dear Sir,

I am Yonca A. Akova, MD-from the Department of Ophthalmology, Bayindir Kavaklidere Hospital, Turkey. I wrote this letter to evaluate the efficacy of 0.05% topical cyclosporine A (CsA) eye drops (Restasis Allergan, Irvine, USA) in symptomatic patients with recurrent subepithelial infiltrates (SEIs) due to adenoviral keratoconjunctivitis following steroid eye drops tapering or discontinuation.

During the natural course of epidemic keratoconjunctivitis, some patients develop SEIs and those may persist for several months to years and cause visual impairment, halos and glare in a subset of patients^[1]. Histopathologic studies suggest that SEIs are composed of lymphocytes, histiocytes and fibroblasts and are thought to occur as a result of delayed immune response to viral antigens in the corneal stroma^[2]. This hypothesis is supported by good response to topical steroid therapy, however undesirable complications like cataract, glaucoma and microbial superinfections may occur with prolonged use of topical steroids and also relapse may occur after tapering or discontinuation of steroids^[1]. Recently, few reports that have shown the efficacy of topical CsA in various concentrations on SEIs have been published^[3-7].

Eighteen eyes of 13 patients who used topical steroid eye drops for SEIs after epidemic keratoconjunctivitis and became symptomatic after steroid eye drops tapering or

discontinuation were included in this study. None of the patients received topical steroids in the acute stage of conjunctivitis; they were only given to patients with symptomatic SEIs in the chronic phase the disease. We administered topical 0.05% CsA eye drops 4 times a day in addition to loteprednol etobonate (LE) 3 times a day (3wk) and LE was tapered weekly and therapy was continued with topical 0.05% CsA for 6mo. Restasis therapy was discontinued if the patients were asymptomatic. If symptoms were markedly increased after discontinuation, the therapy was extended to 12mo. For subjective evaluation, patients' symptoms were graded by using a symptom questionnaire with a score varying between 0-3 (0: none; 1: mild, 2: moderate; 3: severe). The images of SEIs before treatment and after 3mo of therapy were analyzed with an image analysis and processing software program called ImageJ (1.44p, Wayne Rasband, National Institutes of Health, Bethesda, MD, USA). The number of SEI was counted and the area of SEI was measured in terms of pixels and its ratio to the entire corneal area was determined as the percentage. Figure 1A and 1B show the anterior segment photograph and image of SEIs in a patient.

Wilcoxon signed-rank test was used to compare the pre- and post-treatment data. *P* value of <0.05 was considered statistically significant.

There were 9 females (69.2%) and 4 males (30.8%) with a mean age of 34.2±17.6y (range 17-57y). The mean duration of follow up was 17.8±8.6mo (range 14-23mo). The degree of symptoms after treatment was significantly reduced (*P*<0.05 for all symptoms). The severity of discomfort was scored as moderate in 1 of 13 patients and mild in 2 (15.38%) following the treatment. Ten patients (76.9%) reported having no discomfort. One patient (7.7%) noticed mild halo/glare sensation while none had photophobia at the end of treatment period. The score of subjective evaluation of visual improvement was statistically significant after treatment (*P*<0.05). The mean BCVA was 0.17±0.20 (logMAR) at first month and 0.12±0.29 (logMAR), at 6mo (*P*<0.05). Seventeen of 18 eyes (94.4%) gained two or more lines of Snellen BCVA after treatment, in 1 eye (5.6%) BCVA increased only one line. Three eyes (16.7%) had an attack presenting with severe redness, discomfort, tearing and visual disturbance while receiving topical 0.05% CsA, and all of the symptoms disappeared with LE administration for 2wk. After cessation

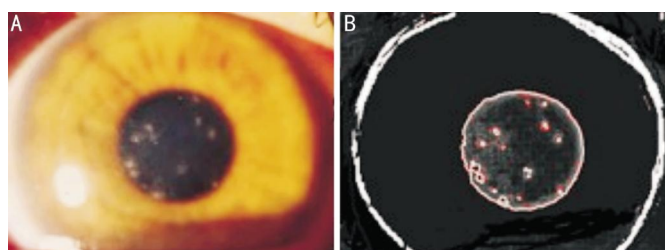


Figure 1 Images of a patients with subepithelial infiltrates A: Anterior segment photography of a patient showing subepithelial infiltrates around the pupil border taken by a digital camera; B: Analysis of the subepithelial infiltrates by a software in the same eye.

of the topical 0.05% CsA treatment, 2 of 18 eyes (11.1%) showed recurrence at seven and eight months, respectively. Topical 0.05% CsA therapy was restarted and extended to 1y in those eyes. The number of SEIs and percentage of SEIs area were decreased from 13.45 ± 3.28 to 3.25 ± 2.14 ($P<0.05$) and $17.76\pm 12.45\%$ to $5.36\pm 2.35\%$ ($P<0.05$) respectively.

In our study, symptoms in patients with SEIs including discomfort, halo/glare and photophobia significantly decreased with topical 0.05% CsA therapy. These symptoms were scored as mild or none by 76.9%, 100%, and 100% of patients following treatment, respectively. In addition to symptomatic relief, the number of SEIs and percentage of SEIs area decreased in the ratio of 76.9% and 69.7%, respectively. These results suggested that the commercially available form of topical 0.05% CsA treatment was effective and well tolerated in eyes with symptomatic and steroid dependent.

SEIs may resolve spontaneously or with topical steroid therapy without leaving permanent subepithelial scarring in the cornea, but similar to our patients, subset of patients may need to have topical steroids however, prolonged use of steroids may cause serious complications such as steroid-induced glaucoma, cataract formation and secondary infections^[1,3].

Recently, the efficacy of topical CsA in different concentrations for the treatment of SEIs has been reported in a number of studies^[3,5-7]. The largest series of patients received topical CsA for the treatment of SEIs was reported by a German group^[6]. They treated 70 eyes of 48 patients with 2% CsA four times a day at the beginning and reduced the frequency of 2% CsA depending on resolution of the SEIs. Forty eyes responded well, 16 eyes showed no change and the therapy was stopped in 4 eyes because of severe intolerance to 2% CsA therapy. Complete cure was achieved without recurrence in 10 eyes. Levinger *et al*^[7] treated 9 steroid resistant or steroid responder patients with 1% CsA eye drops twice daily. Sixty-six percent of patients showed clinical improvement, while thirty-four percent remained stable^[7]. To the best of our knowledge, there has been only one report regarding the efficacy of commercially available topical CsA 0.05%, which is a lower concentration than the preparations previously used for this indication in the

literature^[5]. This group used topical 0.05% CsA in 16 patients (22 eyes) with SEIs who had been previously treated with topical steroids without any improvement or had to stop topical steroids secondary to intraocular pressure elevation. 0.05% CsA was administered four times for the first 15d, and then 2 times a day for next 15d. Eighteen eyes (81.9%) showed clinical improvement while SEIs did not completely disappear in 4 eyes^[5]. Although we found similar results compare to those of eyes, we evaluated the number and the percentage of SIEs using an image analysis program to have objective results, whereas they made corneal subepithelial scoring according to the number of SEI seen in biomicroscopic examinations.

There were some limitations of our study. The evidence of efficacy of topical 0.05% CsA was not based on a controlled trial and the number of patients was small. Prospective, double-masked, placebo controlled further studies are needed to show the efficacy of topical CsA in different concentrations. Also we could not clearly state that the initial improvement in symptoms was only due to topical 0.05% CsA treatment, it could be due to either LE or topical 0.05% CsA. However we thought that the anti-inflammatory effect of topical 0.05% CsA might reduce the need for topical steroids and made contributions to the symptomatic relief of patients during the follow-up without having the risk of steroid treatment side effects.

In conclusion, our study found that topical 0.05% CsA seemed to be safe and effective in patients with symptomatic SEI who were resistant to steroid eye drops tapering or discontinuation. It should be kept in mind that in some cases, the duration of topical 0.05% CsA therapy may need to be extended.

ACKNOWLEDGEMENTS

Conflicts of Interest: Muftuoglu IK, None; Akova YA, None; Gungor SG, None.

REFERENCES

- 1 Gordon YJ, Araullo-Cruz T, Romanowski EG. The effects of topical nonsteroidal anti-inflammatory drugs on adenoviral replication. *Arch Ophthalmol* 1998;116(7):900-905.
- 2 Lund OE, Stefani FH. Corneal histology after epidemic keratoconjunctivitis. *Arch Ophthalmol* 1978;96(11):2085-2088.
- 3 Hillenkamp J, Reinhard T, Ross RS, Bohringer D, Carlsburg O, Roggendorf M, De Clerc E, Sundmacher R. Topical treatment of acute adenoviral keratoconjunctivitis with 0.2% cidofovir and 1% cyclosporine: a controlled clinical pilot study. *Arch Ophthalmol* 2001;119 (10):1487-1491.
- 4 Jeng BH, Holsclaw DS. Cyclosporine A 1% eye drops for the treatment of subepithelial infiltrates after adenoviral keratoconjunctivitis. *Cornea* 2011; 30(9):958-961.
- 5 Cetinkaya A, Akova YA, Dursun D, Pelit A. Topical cyclosporine in the management of shield ulcers. *Cornea* 2004;23(2):194-200.
- 6 Reinhart T, Godehardt E, Phahl HG, Sundmacher R. Local cyclosporin A in nummuli after keratoconjunctivitis epidemica. A pilot study. *Ophthalmologica* 2000;97(11):764-768.
- 7 Levinger E, Slomovic A, Sansanayudh W, Bahar I, Slomovic AR. Topical treatment with 1% cyclosporine for subepithelial infiltrates secondary to adenoviral keratoconjunctivitis. *Cornea* 2010;29(6):638-640.