



Image-2.MRI in Hematology

# Intrathecal Methotrexate-Induced Posterior Reversible Encephalopathy Syndrome (PRES)

## İntratekal Metotreksat İlişkili Posterior Reversible Ensefalopati Sendromu (PRES)

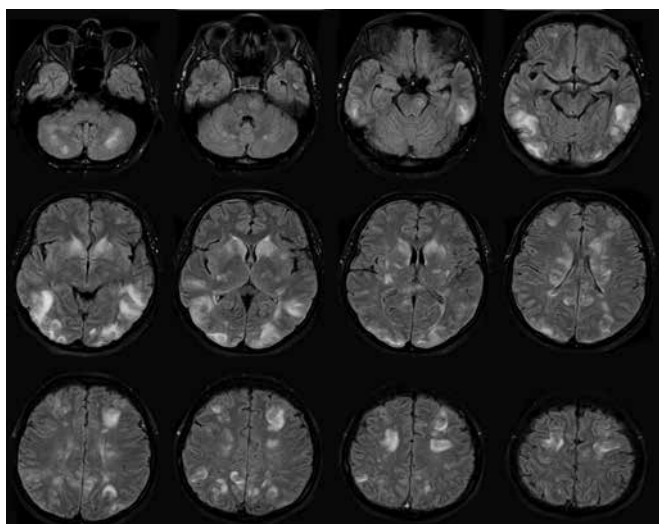


Figure 1a. MRI FLAIR images show bilateral multiple subcortical and cortical hyperintense lesions.

Tülay Güler<sup>1</sup>, Özden Yener Çakmak<sup>1</sup>, Selami Koçak Toprak<sup>2</sup>, Seda Kibaroglu<sup>1</sup>, Ufuk Can<sup>1</sup>

<sup>1</sup>Başkent University School of Medicine, Department of Neurology, Ankara, Turkey

<sup>2</sup>Başkent University School of Medicine, Department of Hematology, Ankara, Turkey

Address for Correspondence: Tülay Güler, M.D.,  
Başkent University School of Medicine, Department of Neurology, Ankara, Turkey  
Phone: +90 312 212 68 68 E-mail: drtulis@yahoo.com

Received/Geliş tarihi : December 04, 2012  
Accepted/Kabul tarihi : February 18, 2013

Posterior reversible encephalopathy syndrome (PRES) is an acute neuroradiological diagnosis presenting with headache, vomiting, seizure, abnormalities of the mental status, and visual disturbances associated with a breakdown in cerebral vasculature regulation. It has a unique neuroradiological pattern of symmetrical parietooccipital vasogenic edema [1]. The most common causes of this syndrome are sudden arterial hypertension, preeclampsia, eclampsia, uremia, immunosuppressive drugs, and cancer chemotherapies such as cyclosporine, tacrolimus, L-asparaginase, vincristine, gemcitabine, cytarabine, and cisplatin, typically used in cases of hematopoietic malignancies [2,3,4,5,6,7]. Intrathecal methotrexate-induced PRES in an adult is exceedingly rare [8].

A 43-year-old woman was admitted to gynecology with metrorrhagia. Cervical cancer was diagnosed and radical hysterectomy with lymph node dissection was performed. Final pathology and immunohistochemical analyses revealed B-cell phenotype malign lymphoma, which is consistent with Burkitt lymphoma. A chemotherapy treatment protocol with R-Hyper CVAD, consisting of rituximab, cyclophosphamide, vincristine, adriamycin, and dexamethasone plus 12 mg of intrathecal methotrexate without preservative, was then started. Twelve days after chemotherapy she had severe analgesic-irresponsive headache, nausea, motor agitation, and cooperation failure. Her vital signs and laboratory findings were normal. Cranial computed tomography revealed hypodense areas due to edema in the bilateral cerebral hemispheres, predominantly in the posterior regions. Magnetic resonance imaging (MRI) of the brain showed

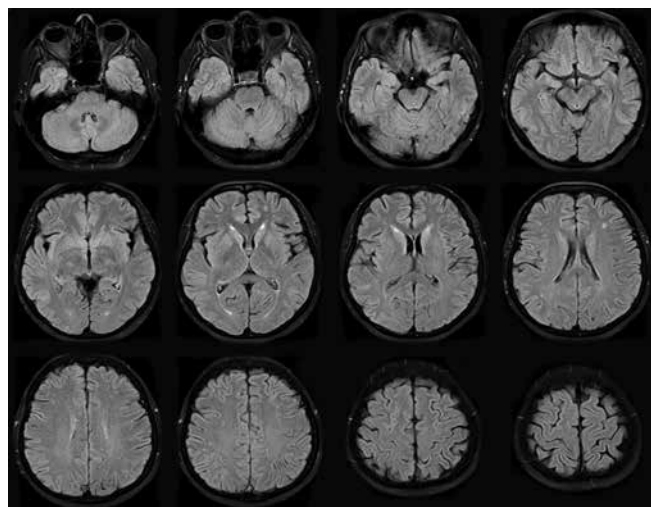


Figure 1b. MRI images 3 weeks after developing PRES revealed significant improvement.

multiple confluent hyperintense lesions in T2-weighted and fluid-attenuated inversion recovery (FLAIR) sequences (Figure 1a), with no contrast enhancement in T1-weighted sequences. PRES was diagnosed and she was admitted to the intensive care unit (ICU) because of decreased alertness and agitation. Intrathecal methotrexate treatment was discontinued. On the second day in the ICU her blood pressure rose and was then normalized by diltiazem infusion. On the third day in the ICU, myoclonic jerks were seen in all extremities. Levetiracetam was started. Myoclonic symptoms were no longer observed. After treatment she had no neurological symptoms. Three weeks later, cranial MRI showed significantly improved brain lesions (Figure 1b). The 6-month follow-up was uneventful. Informed consent was obtained.

During chemotherapy for hematopoietic malignancies, possible causes of neurological symptoms (cerebrovascular disease, metabolic disturbances, neoplasia, and infections) must be excluded by clinical, biological, and imaging findings. During chemotherapy, various types of anticancer drugs are administered, and it is difficult to identify which drug induces PRES. In our case, intrathecal methotrexate treatment was stopped, and the patient's symptoms were relieved and did not reoccur while her treatment was continued with other anticancer drugs.

In treatment, the causal factor must be discontinued. The treatment of overdose of intrathecal methotrexate is dilution and removal from the cerebrospinal fluid with specific antidotal therapy. Leucovorin and anti-inflammatory agents are useful [9]. Although PRES is usually reversible with patient recovery and resolution of the imaging findings, it might be recurrent or result in permanent damage [10,11].

**Key words:** Posterior reversible encephalopathy syndrome (PRES), Methotrexate, Magnetic resonance imaging, Fluid-attenuated inversion recovery

**Anahtar Kelimeler:** Arka geri dönüşümlü ensefalopati sendromu (PRES), Ensefalopati, Metotreksat, Manyetik rezonans görüntüleme, Sıvı zayıflatılmış dönüşüm kazanımı (FLAIR)

## References

- Hinchey J, Chaves C, Appignani B, Breen J, Pao L, Wang A, Pessin MS, Lamy C, Mas JL, Caplan LR. A reversible posterior leukoencephalopathy syndrome. *N Engl J Med* 1996;334:494-500.
- Bartynski WS. Posterior reversible encephalopathy syndrome, part 1: fundamental imaging and clinical features. *AJNR Am J Neuroradiol* 2008;29:1036-1042.
- Bartynski WS. Posterior reversible encephalopathy syndrome, part 2: controversies surrounding pathophysiology of vasogenic edema. *AJNR Am J Neuroradiol* 2008;29:1043-1049.
- Bartynski WS, Zeigler ZR, Shaddock RK, Lister J. Pretransplantation conditioning influence on the occurrence of cyclosporine or FK-506 neurotoxicity in allogeneic bone marrow transplantation. *AJNR Am J Neuroradiol* 2004;25:261-269.
- Burnett MM, Hess CP, Roberts JP, Bass NM, Douglas VC, Josephson SA. Presentation of reversible posterior leukoencephalopathy syndrome in patients on calcineurin inhibitors. *Clin Neurol Neurosurg* 2010;112:886-891.
- Russell MT, Nassif AS, Cacayorin ED, Awwad E, Perman W, Dunphy F. Gemcitabine-associated posterior reversible encephalopathy syndrome: MR imaging and MR spectroscopy findings. *Magn Reson Imaging* 2001;19:129-132.
- Tsukamoto S, Takeuchi M, Kawajiri C, Tanaka S, Nagao Y, Sugita Y, Yamazaki A, Kawaguchi T, Muto T, Sakai S, Takeda Y, Ohwada C, Sakaida E, Shimizu N, Yokote K, Iseki T, Nakaseko C. Posterior reversible encephalopathy syndrome in an adult patient with acute lymphoblastic leukemia after remission induction chemotherapy. *Int J Hematol* 2012;95:204-208.
- Aradillas E, Arora R, Gasperino J. Methotrexate-induced posterior reversible encephalopathy syndrome. *J Clin Pharm Ther* 2011;36:529-536.
- Vezmar S, Becker A, Bode U, Jaehde U. Biochemical and clinical aspects of methotrexate neurotoxicity. *Chemotherapy* 2003;49:92-104.
- Hagemann G, Ugur T, Witte OW, Fitzek C. Recurrent posterior reversible encephalopathy syndrome (PRES). *J Hum Hypertens* 2004;18:287-289.
- Antunes NL, Small TN, George D, Boulad F, Lis E. Posterior leukoencephalopathy syndrome may not be reversible. *Pediatr Neurol* 1999;20:241-243.