

Evaluation of choroidal and retinal thickness measurements in adult hemodialysis patients using spectral-domain optical coherence tomography

Avaliação de medidas de coróide e espessura da retina em pacientes em hemodiálise adultos usando tomografia de coerência óptica de domínio espectral

ALI KAL¹, OZNUK KAL², FATMA CORAK EROGLU¹, OZLEM ÖNER³, CEM KUCUKERDONMEZ³, GÜRSEL YILMAZ⁴

ABSTRACT

Purpose: To assess the effect of hemodialysis on retinal and choroidal thicknesses using spectral-domain optical coherence tomography (SD-OCT).

Methods: In this prospective interventional study, 25 hemodialysis patients (17 male, 8 female) were enrolled. All participants underwent high-speed, high-resolution SD-OCT ($\lambda=840$ nm; 26.000 A-scans/s; 5 μ m resolution) before and after hemodialysis. Choroidal thickness was measured perpendicularly from the outer edge of the retinal pigment epithelium to the choroid-sclera boundary at the fovea and at five additional points: 500 μ m and 1000 μ m nasal to the fovea and 500 μ m, 1000 μ m, and 1500 μ m temporal to the fovea. Two masked physicians performed the measurements. Choroidal and retinal thicknesses before and after hemodialysis were compared.

Results: The median choroidal thicknesses before and after hemodialysis were 182 μ m (range, 103-374 μ m) and 161 μ m (range, 90-353 μ m), respectively ($P<0.001$). The median retinal thicknesses were 246 μ m (range, 179-296 μ m) before and 248 μ m (range, 141-299 μ m) after hemodialysis ($P>0.05$). Systolic arterial pressure, diastolic arterial pressure, mean arterial pressure, heart rate, and ocular perfusion pressure significantly decreased after hemodialysis ($P<0.001$). Intraocular pressure did not vary significantly ($P=0.540$).

Conclusion: Hemodialysis seems to cause a significant decrease in choroidal thickness, whereas it has no effect on retinal thickness. This significant decrease in choroidal thickness might be due to the extensive fluid absorption in hemodialysis, which could result in decreased ocular blood flow.

Keywords: Choroidal thickness; Hemodialysis; Optical coherence tomography

RESUMO

Objetivo: Avaliar o efeito da hemodiálise (HD) na espessura da retina (RT) e na espessura da coróide (CT) usando tomografia de coerência óptica de domínio espectral (SD-OCT).

Método: Neste estudo prospectivo intervencionista foram incluídos 25 pacientes em HD (17 homens e 8 mulheres). Todos os participantes foram submetidos a SD-OCT com dispositivo de alta resolução ($\lambda=840$ nm; 26.000 A-scans/seg e resolução de 5 μ m), antes e após HD. A CT foi medida perpendicularmente a partir da borda externa do epitélio pigmentar da retina até o limite coróide-esclera na fóvea e em mais de 5 pontos localizados 500 μ m nasal à fóvea, 1.000 μ m nasal à fóvea; 500 μ m temporal à fóvea, 1.000 μ m temporal à fóvea, e 1.500 μ m temporal à fóvea. Dois médicos realizaram as medidas sem o conhecimento do diagnóstico. Os dados da CT e RT, antes e após a HD foram comparados.

Resultados: As CTs medianas antes e após a HD foram 182 μ m (variação de 103-374 μ m) e 161 μ m (variação de 90-353 μ m), respectivamente ($p<0,001$). A RT foi 246 μ m (variação de 179-296 μ m) antes e 248 μ m (variação de 141-299 μ m) após a HD ($p>0,05$). A pressão arterial sistólica, pressão arterial diastólica, as médias de pressão arterial média, frequência cardíaca e pressão de perfusão ocular diminuíram significativamente após HD ($p<0,001$). A pressão intraocular não alterou significativamente ($p=0,540$).

Conclusão: A HD parece causar uma redução significativa da CT, e não ter efeito sobre a RT. Esta redução significativa da CT pode ser devida à grande absorção de fluido durante a HD, o que pode resultar numa diminuição do fluxo sanguíneo ocular.

Descritores: Espessura da coróide; Hemodiálise; Tomografia de coerência óptica

INTRODUCTION

Hemodialysis is the diffusion of molecules in solution across a semipermeable membrane through an electrochemical concentration gradient. The main objective of hemodialysis is to repair the intracellular and extracellular fluid environment. This is accomplished by the transport of solutes such as urea from the blood into the dialysate and by the transport of solutes such as bicarbonate from the dialysate into the blood^(1,2). Hemodialysis is required for the survival of patients with renal failure and end-stage renal disease (ESRD) by filtering the blood, it corrects the excessive accumulation and abnormal distribution of solutes in body fluids⁽³⁾. Thus, changes in the systemic hemodynamic and metabolic parameters associated with hemodialysis may affect ocular fluid dynamics and composition, blood vessels, tissues of the retina, the choroid, and the optic nerve⁽⁴⁻⁶⁾.

The choroid provides oxygen and nutrients to the outer layers of the retina as well as the visible pigmentation of the fundus. The choroidal vessels can expand and contract easily, so that changes in intraocular or extraocular vascular pressure can affect the choroidal thickness⁽⁷⁾. Because the choroid plays an important role in the pathophysiology of many retinal diseases, it is important to understand the anatomic structure and functional status of the choroid⁽⁸⁾. Optical coherence tomography (OCT) is a noninvasive, interferometric optical imaging technique that provides high-resolution cross-sectional images of the retina using the reflectivity of light waves^(9,10).

Evaluation of the choroid using spectral-domain optical coherence tomography (SD-OCT) was recently reported to be valuable because choroidal change has been associated with the pathogenesis of ocular diseases, such as central serous chorioretinopathy, age-related

Submitted for publication: November 26, 2015

Accepted for publication: March 6, 2016

¹ Department of Ophthalmology, School of Medicine, Baskent University, Konya, Turkey.

² Department of Nephrology, School of Medicine, Baskent University, Konya, Turkey.

³ Department of Ophthalmology, School of Medicine, Izmir University, Izmir, Turkey.

⁴ Department of Ophthalmology, School of Medicine, Baskent University, Ankara, Turkey.

Funding: No specific financial support was available for this study.

Disclosure of potential conflicts of interest: None of the authors have any potential conflict of interest to disclose.

Corresponding author: Ali Kal. Department of Ophthalmology. Faculty of Medicine - Baskent University - Konya - 42080 - Turkey - E-mail: dralikal@yahoo.com

Approved by the following research ethics committee: Baskent University (# 050.01.08.01-890).

macular degeneration, diabetic retinopathy, as well as in eyes with tilted optic discs, the healthy pediatric population, and pregnant women⁽¹¹⁻¹⁶⁾.

A recent study showed a significant increase in choroidal thickness after hemodialysis, whereas several other studies have shown a significant decrease in choroidal thickness after hemodialysis⁽¹⁷⁻²⁰⁾.

In this study, we investigated the changes in retinal and choroidal thicknesses before and after high-ultrafiltration-volume hemodialysis in patients with ESRD.

METHODS

STUDY DESIGN

Twenty-five non-diabetic ESRD patients (17 male, 8 female) undergoing hemodialysis in the Hemodialysis Unit of the Baskent University Faculty of Medicine were enrolled in this prospective study. The study was approved by the ethics committee of the Baskent University Faculty of Medicine. The research adhered to the tenets of the Declaration of Helsinki, and a detailed written informed consent form was obtained prior to each individual's participation in the study. The inclusion criteria were a best corrected visual acuity exceeding 20/200; no history of chronic ocular diseases, such as glaucoma, uveitis, age-related macular degeneration, retinal artery/vein occlusion, or diabetic retinopathy; no family history of glaucoma; and the presence of non-diabetic ESRD treated by hemodialysis with an ultrafiltration volume >2000 mL because of high interdialytic weight gain. The exclusion criteria were the presence of an ocular disease that prevented the examination of the cornea, lens, and retina; an ocular surgery and/or laser treatments and/or intravitreal injection of the eye; spherical equivalent refractive errors more than ± 3.0 diopters; and axial length between 22 mm and 24 mm. The subjects underwent a 3- to 4-h hemodialysis session three times weekly using a high-performance dialyzer at a blood flow rate of 250-300 mL/min and a standardized dialysate flow rate of 500 mL/min. A bicarbonate-containing dialysis solution was used during the hemodialysis. The causes of ESRD in the twenty-five patients included polycystic kidney disease (n=3), chronic glomerulonephritis (n=3), hypertensive nephropathy (n=13), renal amyloidosis due to familial Mediterranean fever (n=2), renal excision due to renal cancer (n=2), and chronic renal failure of unknown etiology (n=2).

All patients underwent a detailed ophthalmic examination that included visual acuity testing; refraction assessments using an auto refractometer; biomicroscopy; intraocular pressure measurement with Goldman applanation tonometry; fundus examination; and choroidal and retinal thickness measurements using OCT just before and after their hemodialysis sessions. One eye per patient was randomly selected for OCT measurement. Randomization was done using a random number generator. To obtain clear images and minimize the effect of axial length on choroidal thickness, measurements with a refractive error higher than 1 diopter were excluded from the study⁽²¹⁾.

MEASUREMENT OF RETINAL/CHOROIDAL THICKNESS

Choroidal thickness measurements were performed by the same experienced technician just before and immediately after hemodialysis using a high-speed, high-resolution SD-OCT device ($\lambda=840$ nm; 26,000 A-scans/s; 5 μ m axial resolution). The results were analyzed using Optovue RTVue software version 3.5 (Optovue Inc., Fremont, CA). The retinal image was obtained after the patient was correctly positioned; the OCT device was pushed toward the eye while the patient maintained fixation. The scan pattern followed the retinal cross line, which consisted of two orthogonally oriented 6 mm lines that contained 1024 A-scans. By automatically inverting the image, the chorioretinal interface became adjacent to the zero delay. The retinal cross-line scan had an average of 32 frames, 16 per direction, without tracking⁽²²⁾. All basal OCT scans were performed at the same time of the day to minimize diurnal fluctuations⁽²³⁾. Choroidal thickness was measured perpendicularly from the outer edge of the retinal pigment

epithelium to the choroid-sclera boundary at the fovea and at five more points located at the fovea; 500 μ m and 1000 μ m nasal to the fovea and 500 μ m, 1000 μ m, and 1500 μ m temporal to the fovea (Figure 1). Choroidal thickness measurements were performed by two masked physicians (AK and CK). The average of the three measurements was taken; the differences between readings of the masked physicians were found to be within 10 μ m of the mean. The interexaminer reproducibility of the choroidal thickness measurements was assessed by measuring the intraclass correlation coefficient (ICC).

STATISTICAL ANALYSIS

Statistical analyses were performed using the Statistical Package for the Social Sciences (SPSS) version 11.0 (SPSS Inc, Chicago, IL, USA). The Wilcoxon test was used to compare the systemic hemodynamic and ocular variables before and after hemodialysis in each group. Differences between the groups were analyzed using the Mann-Whitney U test. The intraclass correlation coefficient (ICC) was calculated to quantify the reproducibility of manual re-measurements of the choroidal and retinal thicknesses in cases of alignment errors. The ocular perfusion pressure (OPP) was calculated using the following formula: $OPP=2/3 \times (\text{mean arterial pressure} - \text{intraocular pressure})$. The mean arterial pressure (MAP) was calculated using the following formula: $MAP=\text{diastolic arterial pressure} - 1/3 \times (\text{systolic arterial pressure} - \text{diastolic arterial pressure})$. Differences resulting in *P* values of <0.05 were considered statistically significant.

RESULTS

General patient information is presented in table 1. The median choroidal thickness at the fovea decreased significantly during hemodialysis; changing from 182 μ m (range, 103-374 μ m) to 161 μ m (range, 90-353 μ m) ($P<0.001$). Moreover, significant differences in median choroidal thicknesses were found before and after hemodialysis at all points where measurements were taken ($P<0.001$ for all) (Figure 2).

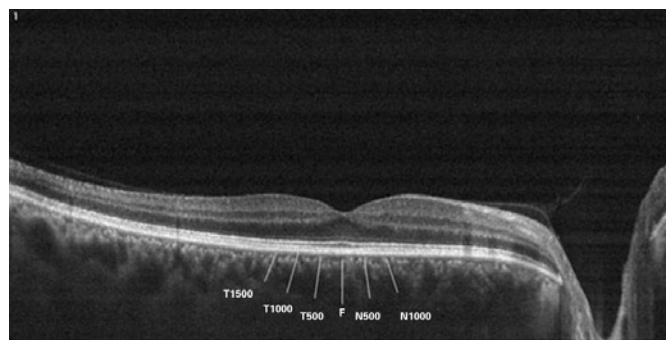


Figure 1. T-1500, choroidal thickness at 1500 μ m temporal to the fovea; T-1000, choroidal thickness at 1000 μ m temporal to the fovea; T-500, choroidal thickness at 500 μ m temporal to the fovea; F, choroidal thickness at the fovea; N-500, choroidal thickness at 500 μ m nasal to the fovea; N-1000, choroidal thickness at 1000 μ m nasal to the fovea; N-1500, choroidal thickness at 1500 μ m nasal to the fovea.

Table 1. General patient information

Age	Mean \pm SD	Range
Sex	44.6 \pm 12.7	20-60
Male	17.0 (68%)	
Female	8.0 (32%)	
HD duration (months)	42.8	8.0-76.0
Ultrafiltration volume (mL)	3136.0 \pm 578.0	2000-4500

HD= hemodialysis; SD= standard deviation.

However, hemodialysis did not cause a significant decrease in median retinal thickness (246 μm [range, 179-296 μm] before versus 248 μm [range, 141-299 μm] after hemodialysis; [$P=0.12$]). The interexaminer ICCs for the choroidal and retinal thicknesses were 0.918 (95% confidence interval [CI], 0.908-0.982) and 0.922 (95% CI, 0.906-0.979), respectively. The ICC was greater than 0.90 for measurements taken at all points. Figure 3 shows a comparison of the median choroidal and retinal thicknesses measured by two different observers before and after hemodialysis. Systolic arterial pressures (SAPs), diastolic arterial pressures (DAPs), MAPs, intraocular pressures (IOPs), heart rates, and OPPs before and after hemodialysis are presented table 2.

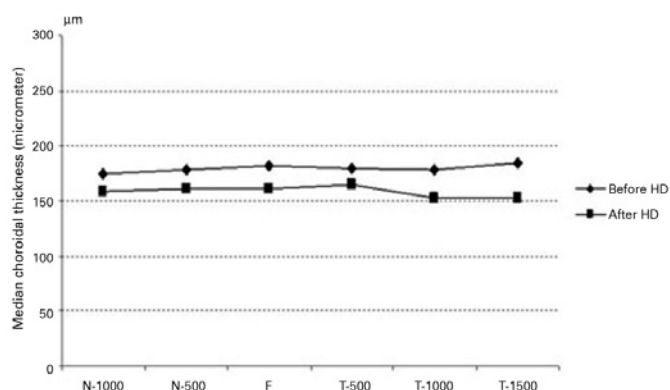


Figure 2. Median choroidal thickness measurements before and after hemodialysis.

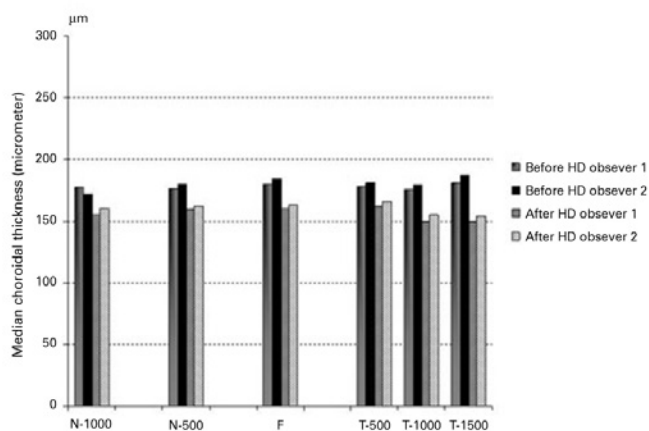


Figure 3. Comparison of choroidal measurements taken before and after hemodialysis by two different observers.

Table 2. Effect of hemodialysis on systemic and ocular parameters

	Before HD mean \pm SD	After HD mean \pm SD	P value
IOP (mmHg)	16.8 \pm 3.0	16.7 \pm 3.6	0.540
Heart rate (beats/min)	77.2 \pm 5.4	74.2 \pm 5.1	<0.001
Blood pressure (mmHg)			
Systolic	131.6 \pm 13.1	119.0 \pm 10.7	<0.001
Diastolic	82.6 \pm 11.1	70.8 \pm 9.3	<0.001
Mean	98.6 \pm 10.6	87.2 \pm 9.1	<0.001
Ocular perfusion pressure	48.9 \pm 8.5	41.4 \pm 7.3	<0.001

HD= hemodialysis; mmHg= millimeters of mercury; SD= standard deviation.

Decreases in heart rate, SAP, DAP, MAP, and OPP were statistically significantly ($P<0.001$), but the change in IOP was not statistically significant ($P=0.540$).

DISCUSSION

In this current study, choroidal thickness measurements taken at six different points decreased significantly during hemodialysis, but foveal retinal thickness did not change. These findings could be the result of choroidal changes associated with hypertension and fluid retention in renal failure patients. Decreased plasma colloidal osmotic pressure due to decreased serum protein levels and increased hydrostatic pressure associated with hypertension may also alter the hemodynamics in the retinal capillaries. Prior to hemodialysis, fluid retention causes a decrease in plasma colloidal osmotic pressure due to the increased plasma volume. Because this decrease produces a colloidal osmotic gradient between the plasma and interstitial volume, water passes from the interstitial fluid into the plasma⁽²⁴⁾. Changes in MAP affect the blood velocity and retinal blood flow positively, and hemodialysis leads to changes in systemic circulatory parameters such as hematocrit, systemic blood pressure (SBP), and the amount of fluid circulation in ESRD patients. The main mechanism driving diminished retinal blood flow during hemodialysis is hypothesized to be related to the amount of fluid removed during hemodialysis. Retinal blood flow and the amount of fluid removed by hemodialysis were found to be negatively correlated⁽⁶⁾. Because the aim of hemodialysis is to correct the abnormal distribution of bodily fluids, ocular hemodynamics are expected to be affected by this rearrangement. In one study, researchers reported several hemodialysis-related changes, including decreased visual acuity, IOP, corneal thickness, and basal tear secretion; however, the authors found no significant change in retinal thickness using SD-OCT⁽⁴⁾. The authors concluded that the shifting of water from the interstitial fluid into the plasma results in a drop in tear secretion, aqueous production, and corneal hydration. In another study, researchers reported that the IOP, OPP, and SAP did not vary significantly in ESRD patients during hemodialysis⁽²⁵⁾. We also did not observe a significant change in IOP; however, OPP, SAP, DAP, and MAP decreased significantly. In another study, researchers found decreases in both the systolic and diastolic blood flow velocities of the ophthalmic artery, central retinal artery, central retinal vein, and nasal and temporal posterior ciliary arteries of both eyes after hemodialysis⁽²⁶⁾. Their study was conducted using color Doppler imaging. We consider that a loss of interstitial fluid and a decrease in ocular blood flow were the two underlying causes of the significant decrease in choroidal thickness detected in this current study.

In a recent study, researchers reported that choroidal thickness increased and SBP decreased after a hemodialysis session⁽¹⁷⁾. They proposed that the increase in choroidal thickness may be associated with choroidal autoregulatory control of ocular hemodynamics; a shifting of fluid and molecules between the plasma and choroidal interstitium. On the other hand, other researchers have reported a significant decrease in choroidal thickness after hemodialysis⁽¹⁸⁻²⁰⁾. They assert that ultrafiltration-dependent hypovolemia, the removal of intravascular and interstitial fluid due to raised plasma colloid osmotic pressure^(18,19), and a reduction in the area of the choroidal vasculature⁽²⁰⁾ may cause the decrease in choroidal thickness. Our results are similar to the results of these studies. In one of these studies, it was reported that the decrease in choroidal thickness following hemodialysis was higher in patients with diabetes than in patients without diabetes. The authors stated that this decrease was due to a damage to the choroidal vessels in patients with diabetes⁽¹⁹⁾.

With the availability of SD-OCT devices, high-resolution images are now available. This gives the clinician enough information to evaluate the choroid more accurately^(8,27). As a highly vascular ocular structure, the choroid is directly influenced by the IOP and OPP⁽²⁷⁾; therefore, real-time, high-definition images of the choroid could help us

demonstrate the real-time vascular status of this tissue *in vivo*. A group of researchers found an age-correlated decrease in retinal thickness in all quadrants in hemodialysis patients compared with healthy controls⁽²⁸⁾.

There were some limitations to our study. Serum osmolarity, plasma colloid serum osmotic pressure, and anterior segment parameters were not measured. These parameters could also be correlated with choroidal thickness changes.

In conclusion, we found no retinal thickness changes and significant choroidal thickness changes following hemodialysis in patients with ESRD. Because the choroid has little autoregulation, blood flow can be affected by changes in the perfusion pressure and choroidal thickness can be changed as a result of these effects. Further randomized trials with larger patient groups and additional systemic parameters could shed more light on this issue.

REFERENCES

1. Depner TA. Prescribing hemodialysis: a guide to urea modeling. Boston: Kluwer Academic; 1991.
2. Locatelli F, Manzoni C, Di Filippo S. The importance of convective transport. *Kidney Int Suppl* 2002;(80):115-20.
3. Evans RD, Rosner M. Ocular abnormalities associated with advanced kidney disease and hemodialysis. *Semin Dial*. 2005;18(3):252-7.
4. Jung JW, Yoon MH, Lee SW, Chin HS. Effect of hemodialysis (HD) on intraocular pressure, ocular surface, and macular change in patients with chronic renal failure. Effect of hemodialysis on the ophthalmologic findings. *Graefes Arch Clin Exp Ophthalmol*. 2013; 251(1):153-62.
5. Levy J, Tovbin D, Lifshitz T, Zlotnik M, Tessler Z. Intraocular pressure during haemodialysis: a review. *Eye*. 2005;19(12):1249-56.
6. Nagaoka T, Takeyama Y, Kanagawa S, Sakagami K, Mori F, Yoshida A. Effect of haemodialysis on retinal circulation in patients with end stage renal disease. *Br J Ophthalmol*. 2004;88(8):1026-9.
7. Maruko I, Iida T, Sugano Y, Ojima A, Sekiryu T. Subfoveal choroidal thickness in fellow eyes of patients with central serous chorioretinopathy. *Retina*. 2011;31(8):1603-8.
8. Manjunath V, Taha M, Fujimoto JG, Duker JS. Choroidal thickness in normal eyes measured using Cirrus HD optical coherence tomography. *Am J Ophthalmol*. 2010;150(3): 325-9.
9. McCourt EA, Cadena BC, Barnett CJ, Ciardella AP, Mandava N, Kahook MY. Measurement of subfoveal choroidal thickness using spectral domain optical coherence tomography. *Ophthalmic Surg Lasers Imaging*. 2010;41Suppl:S28-33.
10. Sander B, Larsen M, Thrane L, Hougaard JL, Jørgensen TM. Enhanced optical coherence tomography imaging by multiple scan averaging. *Br J Ophthalmol*. 2005;89(2): 207-12.
11. Maruko I, Iida T, Sugano Y, Furuta M, Sekiryu T. One-year choroidal thickness results after photodynamic therapy for central serous chorioretinopathy. *Retina*. 2011;31(9): 1921-7.
12. Yamazaki T, Koizumi H, Yamagishi T, Kinoshita S. Subfoveal choroidal thickness after ranibizumab therapy for neovascular age-related macular degeneration: 12-month results. *Ophthalmology*. 2012;119(8):1621-7.
13. Kim JT, Lee DH, Joe SG, Kim JG, Yoon YH. Changes in choroidal thickness in relation to the severity of retinopathy and macular edema in type 2 diabetic patients. *Invest Ophthalmol Vis Sci*. 2013;54(5):3378-84.
14. Ozcimen M, Sakarya Y, Goktas S, Sakarya R, Ivackic IS, Yener HI, Erdogan E. Evaluation of peripapillary choroidal and retinal nerve fiber layer thickness in eyes with tilted optic disc. *Arq Bras Oftalmol*. 2014;77(6):368-72.
15. Tenlik A, Gurağaç FB, Güler E, Dervişoğulları MS, Totan Y. Choroidal thickness measurement in healthy pediatric population using Cirrus HD optical coherence tomography. *Arq Bras Oftalmol*. 2015;78(1):23-6.
16. Goktas S, Basaran A, Sakarya Y, Ozcimen M, Kucukaydin Z, Sakarya R, Basaran M, Erdogan E, Alpfidan I. Measurement of choroid thickness in pregnant women using enhanced depth imaging optical coherence tomography. *Arq Bras Oftalmol*. 2014;77(3):148-51.
17. Jung JW, Chin HS, Lee DH, Yoon MH, Kim NR. Changes in subfoveal choroidal thickness and choroidal extravascular density by spectral domain optical coherence tomography after haemodialysis: a pilot study. *Br J Ophthalmol*. 2014;98(2):207-12.
18. Ulas F, Dogan U, Keles A, Ertilav M, Tekce H, Celebi S. Evaluation of choroidal and retinal thickness measurements using optical coherence tomography in non-diabetic haemodialysis patients. *Int Ophthalmol*. 2013;33(2):533-9.
19. Ishibazawa A, Nagaoka T, Minami Y, Kitahara M, Yamashita T, Yoshida A. Choroidal Thickness Evaluation Before and After Hemodialysis in Patients With and Without Diabetes. *Invest Ophthalmol Vis Sci*. 2015;56(11):6534-41.
20. Yang SJ, Han YH, Song GI, Lee CH, Sohn SW. Changes of choroidal thickness, intraocular pressure and other optical coherence tomographic parameters after haemodialysis. *Clin Exp Optom*. 2013;96(5):494-9.
21. Fujiwara T, Imamura Y, Margolis R, Slakter JS, Spaide RF. Enhanced depth imaging optical coherence tomography of the choroid in highly myopic eyes. *Am J Ophthalmol*. 2009; 148(3):445-50.
22. Branchini L, Regatieri CV, Flores-Moreno I, Baumann B, Fujimoto JG, Duker JS. Reproducibility of choroidal thickness measurements across the three spectral domain optical coherence tomography systems. *Ophthalmology*. 2012;119(1):119-23.
23. Tan CS, Ouyang Y, Ruiz H, Sadda SR. Diurnal variation of choroidal thickness in normal, healthy subjects measured by spectral domain optical coherence tomography. *Invest Ophthalmol Vis Sci*. 2012;53(1):261-6.
24. Tokuyama T, Ikeda T, Sato K. Effects of haemodialysis on diabetic macular leakage. *Br J Ophthalmol*. 2000;84(12):1397-400.
25. Barbosa CP, Stefanini FR, Penha F, Góes MA, Draibe SA, Canziani ME, Paranhos Junior A. Intraocular pressure and ocular perfusion during hemodialysis. *Arq Bras Oftalmol*. 2011;74(2):106-9.
26. Tosun O, Davutluoglu B, Arda K, Boran M, Yarangumeli A, Kurt A, Ozkan D. Determination of the effect of a single hemodialysis session on retrobulbar blood hemodynamics by color Doppler ultrasonography. *Acta Radiol*. 2007;48(7):763-7.
27. Manjunath V, Goren J, Fujimoto JG, et al. Analysis of choroidal thickness in age-related macular degeneration using spectral-domain optical coherence tomography. *Am J Ophthalmol*. 2011;152(4):663-8.
28. Pahor D, Gracner B, Gracner T, Hojs R. Optical coherence tomography findings in haemodialysis patients. *Klin Monbl Augenheilkd*. 2008;225(8):713-7.
29. Usui S, Ikuno Y, Miki A, Matsushita K, Yasuno Y, Nishida K. Evaluation of the choroidal thickness using high-penetration optical coherence tomography with long wavelength in highly myopic normal-tension glaucoma. *Am J Ophthalmol*. 2012;153(1):10-6.