



This is a repository copy of *The neuropathological basis of anxiety in Parkinson's disease*.

White Rose Research Online URL for this paper:

<https://eprints.whiterose.ac.uk/162465/>

Version: Accepted Version

Article:

Overton, P.G. orcid.org/0000-0003-4334-261X and Coizet, V. (2020) The neuropathological basis of anxiety in Parkinson's disease. *Medical Hypotheses*. ISSN 0306-9877

<https://doi.org/10.1016/j.mehy.2020.110048>

Article available under the terms of the CC-BY-NC-ND licence (<https://creativecommons.org/licenses/by-nc-nd/4.0/>).

Reuse

This article is distributed under the terms of the Creative Commons Attribution-NonCommercial-NoDerivs (CC BY-NC-ND) licence. This licence only allows you to download this work and share it with others as long as you credit the authors, but you can't change the article in any way or use it commercially. More information and the full terms of the licence here: <https://creativecommons.org/licenses/>

Takedown

If you consider content in White Rose Research Online to be in breach of UK law, please notify us by emailing eprints@whiterose.ac.uk including the URL of the record and the reason for the withdrawal request.



eprints@whiterose.ac.uk
<https://eprints.whiterose.ac.uk/>

The neuropathological basis of anxiety in Parkinson's disease

Paul G. Overton ¹ and Veronique Coizet ²

¹ Department of Psychology, University of Sheffield, Sheffield, S10 2TP, UK

² Institut des Neurosciences de Grenoble, Centre de Recherche Inserm U.836, Site Santé La Tronche, 38042 GRENOBLE Cedex 9, France

Abstract

Evidence suggests that 24.5%–46.7% (mean 31%) of patients with Parkinson’s disease experience an anxiety disorder, a much higher prevalence than in controls. Anxiety does not appear to be a consequence of diagnosis or the motoric symptoms of the disorder and can manifest as Generalised Anxiety Disorder, phobias or panic attacks. At present, the neural underpinnings of anxiety disorders in Parkinson’s disease is unknown. Here, we make the novel proposal that the superior colliculus (SC), one component of a rapid, reflexive threat detection system in the brain, consisting of the colliculus, pulvinar and amygdala, becomes hyper-responsive to sensory stimuli following dopamine denervation of the striatum in Parkinson’s disease. This in turn leads to heightened responses to existing threat-related stimuli (giving rise to phobias and panic attacks), and heightened responses to anticipated threats (giving rise to Generalised Anxiety Disorder). This proposal is supported by a range of evidence, in particular elevated visual responses in the SC in an animal model of Parkinson’s disease and in Parkinson’s disease itself. Also facilitated saccadic eye movements (prosaccades, express saccades and fixational saccades) and increased distractibility in Parkinson’s disease, both of which involve the SC. Identifying one potential locus of change in the brain in Parkinson’s disease relevant to anxiety gives a potential target for interventions to combat a non-motor symptom that has a substantial negative effect on quality of life in the disorder.

Introduction

Parkinson's disease is a progressive neurodegenerative disorder caused by the loss of dopamine-containing neurons primarily within the substantia nigra pars compacta of the midbrain [1,2]. The disease is typically characterised by a classical syndrome of bradykinesia, tremor, and muscular rigidity [3,4]. Research has tended to focus on these motor symptoms of Parkinson's disease, however a number of non-motor symptoms are now also recognised to be part of the disorder [5]. The most common non-motor symptoms include anxiety, depression, psychosis, sleep problems, impulse control disorders and sensory changes [5-7].

Anxiety in Parkinson's disease

In terms of anxiety, a recent meta-analysis [8] suggests that 24.5%– 46.7% (mean 31%) of Parkinson's patients experience an anxiety disorder, meeting the criteria of the Diagnostic and Statistical Manual of the American Psychiatric Association, or accepted cut off points on validated anxiety scales. Of the disorders present, Generalised Anxiety Disorder is the most frequently reported (14.1%), then social phobia (13.8%) and clinically relevant anxiety not meeting criteria for any specific anxiety diagnoses (anxiety NOS, 13.3%). Agoraphobia (8.6%), other phobias (13.0%) and panic disorder (6.8%) are also present and a number of patients (31%) exhibit more than one anxiety disorder. These prevalence rates far exceed those of similarly aged individuals without Parkinson's disease. For example, the overall prevalence of anxiety disorders has been reported to be 5.5% in people over the age of 65 years (compared with 7.3% in subjects of all ages) in the United States [9], and 3.5-5.5% (6.5% for all ages) in a Canadian study [10]. Unsurprisingly, anxiety has a significant negative impact on quality of life in people with Parkinson's disease [11].

Anxiety frequently develops before the motor symptoms [e.g. 12], suggesting that anxiety may not simply represent a psychological response to the difficulties of adapting to the

diagnosis of Parkinson's disease, or the motor consequences of the disorder but may instead relate to the neurobiological underpinnings of the disorder itself. That said, there is evidence of a relationship between anxiety in Parkinson's disease and the medication given to treat the motor symptoms, and indeed it has been claimed that antiparkinsonian drugs may have a role in the pathogenesis of the anxiety in the disorder [13]. For example, Lang [14] reported that 5/26 late-stage Parkinson's patients developed anxiety symptoms *de novo* when pergolide (a dopamine agonist) was added to their treatment. Likewise, Vasquez et al. [15] found a clear cut relationship of panic disorder with higher doses of levodopa (but not other drugs).

Although not universally the case, anxiety symptoms appear to be more strongly associated with 'off' periods rather than 'on' periods of the medication cycle [16]. In a double blind placebo controlled trial, Maricle et al. [17] found that anxiety levels fell during a levodopa infusion, followed by a precipitous increase in anxiety over the next 2.5 hours. Racette et al. [18] found off-period anxiety in 62 out of 1,063 early-stage Parkinson's patients, and in a recent systematic review, van der Velden et al. [19] report that 81.8% to 88% of fluctuations in anxiety are associated with off periods, with the remaining 12% to 18.2% related to on periods or fluctuating independently of the motor state. Vasquez et al. [15] go so far as to suggest that anxiety (in their case panic attacks) could be considered part of an abstinence syndrome from levodopa.

Anxiety and its neurobiological basis

If, as has been suggested, anxiety in Parkinson's disease does not represent a response to the difficulties of adapting to the diagnosis of Parkinson's disease, or the motor consequences of the disorder, but instead relates to the neurobiological underpinnings of the disorder [12], a question arises as to what aspect(s) of the pathological process that give rise to Parkinson's

disease are involved in generating anxiety in the condition? – A question that is currently unanswered. Our main hypothesis (see later) is directly related to that. However, to contextualise that hypothesis more fully, we must first consider the nature of anxiety and the neurobiological basis (or bases) of anxiety itself. With respect to anxiety, most definitions agree that anxiety is related to both fear and to threat. According to the Diagnostic and Statistical Manual of Mental Disorders, Fifth Edition (DSM-5; [20]), “Fear is the emotional response to real or perceived imminent threat, whereas anxiety is anticipation of future threat” or in the case of phobias, an “excessive or unreasonable” response to perceived threat (see also [21-23]). Fear and anxiety are normal reactions to real or imagined threat and are not themselves pathological. However, when fear and anxiety are recurrent and persistent, and interfere with the quality of life, then an anxiety disorder exists [24].

Although the types of anxiety reported in Parkinson’s disease - Generalised Anxiety Disorder, phobias and panic disorder - are phenomenologically different and have different triggers, there are clear, unifying relationships between them. Phobias normally involve an initial traumatic learning experience, which becomes associated by classical conditioning with the object of the phobia [24]. In contrast to the external signal that triggers a phobic response, it has been proposed that panic relates to internal rather than external signals [25], and may represent the inappropriate activation of an alarm system more usually associated with separation in childhood [26]. Once an initial panic attack has taken place, internal stimuli around at the time will become conditioned to the panic attack (unconditioned stimulus), triggering future attacks if those stimuli are encountered again via classical conditioning [24]. The links to classical conditioning and stimulus-related triggers are not the only features that unite these anxiety disorders. Panic attacks and phobias are often co-morbid [e.g. 27]. Indeed, when the physiological responses during panic attacks and the exposure to feared objects in phobias are compared, the similarities are more apparent than the differences, and it has been

argued that they represent the activation of one and the same underlying anxiety response [28]. LeDoux [24] adds Generalised Anxiety Disorder to phobias and panic disorder, concluding that all three probably relate to the same underlying brain system.

So, the question is – what is that brain system? Given the clear relationship between anxiety and threat, it may be useful to look firstly at the brain system(s) responsible for threat detection. The amygdala is critically involved in an organism's response to sources of danger, as evidenced by a large number of neurobiological and neuroimaging studies [e.g. 29-34]. To be able to respond to danger quickly and reflexively, humans and infra-human mammals have evolved a direct pathway to the amygdala that bypasses the primary sensory cortices. Functional evidence for the existence of such a pathway comes from patients with striate cortex lesions, who are unable to consciously experience a visual stimulus presented to their blind visual field – 'blindsight'. In response to fear-related stimuli, blindsight patients show enhanced amygdala activation which covaries with activity in the superior colliculus and pulvinar [35].

The superior colliculus (SC) is a visual (superficial layers) and multimodal (deep layers) sensory structure in the midbrain which is intimately linked to eye movements and attentional focus [e.g. 36]. Although an evolutionarily ancient subcortical structure [37], evidence suggests that the structure possesses relatively sophisticated processing abilities, for example in primates for the detection of some high level visual features such as faces [38,39], a source of potential threat. Coupled with the finding that disinhibition of the SC in monkeys elicits defensive behaviour [40], and bilateral lesions of the SC induce impaired recognition of a threatening stimulus (rubber snake model) in infant monkeys [41], the colliculus appears to be the visual 'front end' of a threat detection and response system. This is reinforced by the observation that activating the colliculus elicits cardiovascular alerting (pressor) responses [42] and cells in the colliculus exhibit vigorous response to looming stimuli [43]. Collicular responses to potentially

threatening stimuli are also found in the human SC. For example, fearful (vs neutral) faces produce activation in the human colliculus [44] as do snake-related stimuli [45].

The superior colliculus projects to the pulvinar [46], where some neurons in the primate also preferentially respond to snakes and faces, in particular angry faces [47]. Likewise, fearful (vs neutral) faces and snake-related stimuli also produce activation in the human pulvinar [44,45]. Given that the pulvinar projects to the amygdala [48], it has been suggested that the SC, pulvinar and amygdala constitute a functional network concerned with the non-conscious perception threat-related facial stimuli [44,49,50]. The collicular pathway appears to provide rapid analysis of the emotional attributes of stimuli, offering a ‘low road’ of affective visual stimuli to the amygdala without routing through the cortex [51]. Fearful (threatening) images passing through the colliculus and pulvinar would elicit fast amygdalar activation, which, in turn, would trigger autonomic and behavioural responses [24]. Following threatening and traumatic events, amygdala responsivity and associated vigilance may be abnormally enhanced, as observed in disorders such as phobias [52], leading to an anxiety disorder. By the same token, other processes which enhance activity in this network may also similarly lead to an anxiety disorder. It is this possibility that leads us to our central hypothesis.

Hypothesis

In Parkinson’s disease, the SC becomes hyper-responsive to sensory stimuli, leading to abnormally intense responses to threatening stimuli that are currently experienced (giving rise to phobias and panic), and to higher levels of baseline activity that drive the threat circuit in the absence of a current eliciting stimulus (giving rise to free-floating, generalised anxiety).

Collicular function and dysfunction in Parkinson's disease

We have previously reported [53] that visual responses in the intermediate and deep layers of the rat SC are facilitated following partial or total lesions of dopaminergic neurons in the substantia nigra pars compacta (once the colliculus is disinhibited). Responses are faster, larger in amplitude and last longer compared to those in control rats. Baseline activity in the absence of visual stimulation is also elevated. More recently, we have extended this finding to de novo, drug naïve Parkinson's patients [54]. Using blood oxygen level-dependent (BOLD) functional magnetic resonance imaging, we measured visual responses in the SC to achromatic checkerboards with luminance contrasts varying from 1% to 9%. Compared to controls, Parkinson's patients exhibited a larger BOLD response at low contrast, which saturated at high contrast (Figure 1). This effect was still present 2 and 6 months after the start of anti-Parkinsonian medication.

Elevating collicular activity in the mouse increases panic-related behaviour during the confrontation with a snake [55]. While we are unaware of any studies that have deliberately tested Parkinson's patients for their responses to snakes or other biologically relevant threats, Parkinson's patients often 'freeze' as they approach a doorway or an object in their path [56,57]. Under natural conditions, abrupt freezing is a normal response to rapid visual detection of threatening stimuli, including peripheral and looming objects and dangerous objects in one's path [58]. The SC-pulvinar visual system in humans is responsive to such stimuli (e.g. looming objects; [59]). In Parkinson's disease, collicular hyper-responsiveness may lead mildly threatening stimuli like those signalling enclosure (e.g. a doorway) to elicit responses appropriate for a more significant threat (freezing) [58].

Further evidence for collicular hyper-responsiveness in Parkinson's disease comes from studies of saccadic eye movements. Visually triggered saccades (sometimes called reflexive or automatic saccades) are initiated by the sudden appearance of a visual stimulus and involve the

SC [60,61]. In prosaccade tasks where subjects have to make such saccades to visual targets, Parkinson's patients have been described as 'hyper-reflexive' [62-64]. Hence, patients have been reported to be significantly faster in their saccadic reaction times than controls, without affecting accuracy [63,65,66]. This effect is present when the patients are medicated [66] or unmedicated [63,65]. Patients have also been reported to benefit more than controls from the effects of cues as to the direction of the upcoming saccadic target [62,64], and to make more express (short latency) saccades [65,67], and fixational saccades [68], saccadic types in which the colliculus plays a particular role [69,70].

As well as playing a role in eye movement generation, the SC also has a particular role to play in the detection of unexpected phasic stimuli [36]; i.e., the colliculus not only organises responses to sensory stimuli – for example saccades – but is also exclusively involved in detecting certain classes of stimuli. Consistent with this role, work in a range of species has shown that collicular lesions lead to a decrease in 'distractibility' (rat [71]; monkey [72]). In humans, disconnecting the colliculus from the controlling influence of the prefrontal cortex leads to an increase in distractibility [73], suggesting that the structure's function of detecting unexpected (distracting) stimuli is preserved in humans. Parkinson's patients have been reported to make more saccades to distracter stimuli and non-target stimuli than controls [64,74], again suggesting that the SC is hyper-responsive to sensory stimuli in Parkinson's disease.

Distractibility in the aforementioned studies in rats, monkeys and humans concerns the detection of non-threatening stimuli, to which the agent would normally make an orienting response. Likewise, visually triggered reflexive saccades initiated by the sudden appearance of a visual stimulus orient the eyes towards the stimulus. However, the colliculus is considered to have a dual functional role, where it not only organises orienting responses, but also organises escape responses to threat [36,40,75]. Hyper-reflexivity and increased distractibility in

Parkinson's disease coupled with the hypothesised exaggeration in the response to threat suggests that sensory hyper-responsivity in Parkinson's disease sensitises both aspects of collicular function.

Conclusion and next steps

Evidence reviewed above suggests that in Parkinson's disease, subsequent to the loss of dopamine from the striatum, the SC becomes hyper-responsive to sensory stimuli, as evidenced by elevated visual responses (and baseline activity) in the rat SC following lesions of the nigrostriatal dopamine system [53], increased collicular activation by low contrast stimuli in Parkinson's patients [54], as well as hyper-reflexivity in the generation of reflexive saccades to visual targets [e.g. 65], increased levels of express saccades/fixational saccades [e.g. 67,68], and increased distractibility to unexpected visual stimuli [e.g. 74]. How striatal dopamine denervation translates into collicular hyper-responsivity has yet to be empirically determined. However, the striatum projects to the SNr, which then sends a GABAergic projection to the SC [76,77], and hence there may be some alteration in the ongoing regulation of the SC by this inhibitory pathway.

Given that the SC, pulvinar and amygdala have been proposed to constitute a functional network concerned with the non-conscious perception threat-related stimuli [e.g. 49], and anxiety's close relationship with threat (anxiety being the anticipation of future threat, or a disproportionate response to existing threat), an enhanced responsivity in a circuit mediating threat responses following elevated responding in the SC could be sufficient to generate anxiety. That would manifest as phobic/panic attacks to sensory triggers and/or generalised, free-floating anxiety in the absence of explicit triggers caused by elevated baseline activity in the threat circuit. A natural question however is why - since our imaging data [54] and the

saccadic hyper-reflexivity findings [e.g. 65,66] suggest that the colliculus is hyper-responsive in both medicated and unmedicated patients with Parkinson's disease – is anxiety worse in the unmedicated state [e.g. 15]? The answer may lie at the level of the amygdala. Although evidence is scant, resting activity levels in the amygdala have been reported to be higher in some Parkinson's patients off medication ([78]; however, see [79]), whilst amygdala activity appears to be suppressed in the medicated state (amygdala-derived event-related potentials to fearful faces are absent; [80]). Anti-parkinsonian medication may thus be able to turn off or turn down responses in a critical part of the threat detection system, thus blocking the effects of elevated afferent input.

In conclusion, we have reviewed considerable evidence in support of the contention that enhanced activity in a circuit mediating threat responses following elevated sensory responsivity in the SC could generate anxiety on Parkinson's disease. However, the hypothesis still lacks a direct test. Amongst the possible predictions of the collicular hypothesis that could be tested is whether the SC responds vigorously to threatening stimuli in Parkinson's patients. A number of threat paradigms exist that could be used to test that possibility, for example shooting paradigms [e.g. 81], and the elevated (virtual) plank [82]. More work is also required to elucidate the status of the amygdala in Parkinson's disease, both in medicated and unmedicated patients, using paradigms focusing on resting state activity and responses to threat. Confirming enhanced amygdala activity in unmedicated Parkinson's patients and suppressed amygdala activity in medicated Parkinson's patients would have important theoretical consequences. Evidence at the moment is both scant and somewhat contradictory.

Finally, what implications does our hypothesis that anxiety in Parkinson's disease arises (at least in part) from a hyper-responsive SC, the sensory front-end of the unconscious threat detection system, have for therapy? Evidence suggests that the SC receives extensive noradrenergic [83] and serotonergic [84] innervation. Noradrenaline and 5-HT have

predominantly inhibitory actions on collicular visual responses [85,86]. Hence it may be possible to turn down collicular responsiveness by the use of drugs targeting noradrenaline and 5-HT-mediated transmission in the SC. In that regard it is interesting that tricyclic antidepressants (which affect noradrenaline and 5-HT) and Selective Serotonin Uptake Inhibitors are both effective against anxiety in Parkinson's disease [e.g. 87].

Conflicts of interest

The authors have no conflicts of interest to disclose.

Disclosures

The authors have no financial conflicts of interest to disclose.

FIGURE 1: Effects of increasing luminance contrast and dopaminergic treatment on collicular responses to achromatic checkerboard stimuli at varying levels of luminance contrast in patients with Parkinson's disease. Left panel: Average variations (\pm standard error of the mean [SEM]) in the blood oxygenation level-dependent (BOLD) signal in the superior colliculi according to luminance contrast changes (versus fixation; right and left hemispheres combined) in de novo, drug naïve patients with Parkinson's disease (N = 22) and matched controls. Right panel: Average variations (\pm SEM) of the BOLD signal in the superior colliculi according to luminance contrast changes (versus fixation; right and left hemispheres combined) in Parkinson's patients (N = 8) at 2 and 6 months after starting levodopa or dopamine agonist treatment, and controls. Modified from [54] with permission from John Wiley & Sons.

Experimental details: Twenty-three de novo Parkinson's disease patients (age = 57.27 ± 2.24 years; 17 males; one female patient did not complete the scan) and 23 age-matched healthy controls (age = 55.54 ± 2.01 years; 13 males) took part. All patients had received a recent diagnosis (≤ 1 year) of Parkinson's disease, and were not taking antiparkinsonian treatment at the time of the initial scan. MRI acquisitions were performed using a whole-body 3-T MRI scanner (Achieva; Philips Medical Systems, Best, the Netherlands) equipped with a 32-channel SENSE head coil. Participants were presented with a series of achromatic checkerboards with 4 levels of luminance contrast (1%, 3%, 5%, and 9%), flashing at a frequency of 4 Hz on a grey background, presented to each hemifield in turn across sessions. For functional scans, a standard gradient echo planar imaging sequence was used (repetition time = 2,000 ms; echo time = 30 ms, flip angle = 80° , matrix size = 128×144 , field of view = 192×216). High-resolution structural images were also acquired and used for manual delineation of the SC and other regions of interest. Parkinson's disease patients who had started L-dopa or dopamine

agonist treatment after completing the first scan (N=8), were scanned a second and a third time respectively, 2 and 6 months after antiparkinsonian treatment onset.

References

- [1] Obeso, J. A., Rodriguez-Oroz, M. C., Rodriguez, M. et al. (2000). Pathophysiology of the basal ganglia in Parkinson's disease. *Trends Neurosci*, 23(10 Suppl), S8-S19.
- [2] Moore, R. Y. (2003). Organization of midbrain dopamine systems and the pathophysiology of Parkinson's disease. *Parkinsonism Relat Disord*, 9(Suppl 2), S65-71.
- [3] Stern, M. B. (1988). The clinical characteristics of Parkinson's disease and parkinsonian syndromes: diagnosis and assessment. In: (eds. M. B. Stern, Hurtig, H.I.) *The comprehensive management of Parkinson's disease*. PMA Publishing Company: New York, pp 3-50.
- [4] Gelb, D. J., Oliver, E., & Gilman, S. (1999). Diagnostic criteria for Parkinson disease. *Arch Neurol*, 56(1), 33-39.
- [5] Gallagher, D. A., Lees, A. J., Schrag, A. (2010). What are the most important nonmotor symptoms in patients with Parkinson's disease and are we missing them? *Mov Disord*, 25(15), 2493-2500.
- [6] Chaudhuri, K. R., Healy, D. G., Schapira, A. H. (2006). Non-motor symptoms of Parkinson's disease: diagnosis and management. *Lancet Neurol*, 5(3), 235-245.
- [7] Chaudhuri, K. R., Schapira, A. H. (2009). Non-motor symptoms of Parkinson's disease: dopaminergic pathophysiology and treatment. *Lancet Neurol*, 8(5), 464-474.
- [8] Broen, M. P, Narayan, N. E., Kuijf, M. L., Dissanayaka, N. N., Leentjen, A. F. (2016). Prevalence of anxiety in Parkinson's disease: A systematic review and meta-analysis. *Mov Disord*, 31(8), 1125-33.
- [9] Regier, D. A., Boyd, J. H., Burke, J. D. Jr, et al. (1988). One-month prevalence of mental disorders in the United States: based on five epidemiologic catchment area sites. *Arch Gen Psychiatry*, 45(11), 977-86.

- [10] Bland, R. C., Newman, S.C., Orn, H. (1988). Prevalence of anxiety disorders in the elderly in Edmonton. *Acta Psychiatr Scand Suppl*, 338, 57–63.
- [11] Kuhlman, G. D., Flanigan, J. L., Sperling S. A., Barrett M. J. (2019). Predictors of health-related quality of life in Parkinson's disease. *Parkinsonism Relat Disord*, 65, 86-90.
- [12] Weisskopf, M. G., Chen, H., Schwarzschild, M. A., Kawachi, I., Ascherio, A. (2003). Prospective study of phobic anxiety and risk of Parkinson's disease. *Mov Disord*, 18(6), 646-51.
- [13] Walsh, K., Bennett, G. (2001). Parkinson's disease and anxiety *Postgrad Med J*, 77(904), 89–93.
- [14] Lang, A. E., Quinn, N., Brincat, S., et al. (1982). Pergolide in late-stage Parkinson's disease. *Ann Neurol*, 12(3), 243–7.
- [15] Vazquez, A., Jimenez-Jimenez, F. J., Garcia-Ruiz, P., et al. (1993). "Panic attacks" in Parkinson's disease: a long-term complication of levodopa therapy. *Acta Neurol Scand*, 87(1), 14–18.
- [16] Richard, I. H. (2005). Anxiety disorders in Parkinson's disease. *Adv Neurol*, 96, 42-55.
- [17] Maricle, R. A., Nutt, J. G., Valentine, R. J., et al. (1995). Dose-response relationship of levodopa with mood and anxiety in fluctuating Parkinson's disease: a double-blind, placebo-controlled study. *Neurology*, 45(9), 1757–60.
- [18] Racette, B. A., Hartlein, J. M., Hershey, T., Mink, J. W., Perlmutter, J. S., Black, K. J. (2002). Clinical features and comorbidity of mood fluctuations in Parkinson's disease. *J Neuropsychiatry Clin Neurosci*, 14(4), 438-42.
- [19] van der Velden, R. M. J., Broen, M. P. G., Kuijf, M. L., Leentjens, A. F. G. (2018). Frequency of mood and anxiety fluctuations in Parkinson's disease patients with motor fluctuations: A systematic review. *Mov Disord*, 33(10), 1521-1527.

- [20] American Psychiatric Association (2013). *Diagnostic and statistical manual of mental disorders* (5th ed.). American Psychiatric Publishing: Arlington, VA.
- [21] Barlow, D. (2002). *Anxiety and its disorders: the nature and treatment of anxiety and panic* (2nd ed.). Guilford Press: New York.
- [22] Horwitz, A.V. (2013). *Anxiety: A short history*. Johns Hopkins University Press: Baltimore.
- [23] Sadock, B. J., Sadock, V. A., Ruiz P. Kaplan and Sadock's synopsis of psychiatry: Behavioral Sciences/Clinical Psychiatry. 11th edition. Philadelphia: Wolters Kluwer; 2015.
- [24] LeDoux, J. E. (1996). *The Emotional Brain*. Simon & Schuster: New York, NY.
- [25] Margraf, J., Ehlers, A., Roth, W. T. (1986). Biological models of panic disorder and agoraphobia--a review. *Behav Res Ther*, 24(5), 553-67.
- [26] Klein, D. F. (1993). False suffocation alarms, spontaneous panics, and related conditions. An integrative hypothesis. *Arch Gen Psychiatry*, 50(4), 306-17.
- [27] Katerndahl, D. A. (2000). Predictors of the development of phobic avoidance. *J Clin Psychiatry*, 61(8):618-23.
- [28] Öhman, A. (1992) Fear and anxiety as emotional phenomena: Clinical, phenomenological, evolutionary perspectives, and information-processing mechanisms. In: (eds. Lewis, M., Haviland, J. M.). *Handbook of the emotion*. Guilford; New York, pp 511-536.
- [29] Gloor, P., Olivier, A., Quesney, L. F. (1981) The role of the amygdala in the expression of psychic phenomena in temporal lobe seizures. In: Ben-Ari Y. (ed) *The Amygdaloid Complex*. Elsevier/North Holland: New York, pp 489–507.
- [30] Davis, M., Whalen, P. J. (2001). The amygdala: vigilance and emotion. *Mol Psychiatry*, 6(1), 13-34.

- [31] Halgren, E. (1992). Emotional neurophysiology of the amygdala within the context of human cognition. In J. P. Aggleton (ed.), *The amygdala: Neurobiological aspects of emotion, memory, and mental dysfunction*. Wiley-Liss: New York, pp 191–228.
- [32] LeDoux J. (1998). Fear and the brain: where have we been, and where are we going? *Biol Psychiatry*, 44(12), 1229-38.
- [33] Phan, K. L., Wager, T., Taylor, S. F., Liberzon, I. (2002). Functional neuroanatomy of emotion: a meta-analysis of emotion activation studies in PET and fMRI. *Neuroimage*, 16(2), 331-48.
- [34] Zald, D. H. (2003). The human amygdala and the emotional evaluation of sensory stimuli. *Brain Res Brain Res Rev*, 41(1), 88-123.
- [35] Morris, J. S., de Gelder, B., Weiskrantz, L., Dolan, R. J. (2001). Differential extrageniculostriate and amygdala responses to presentation of emotional faces in a cortically blind field. *Brain*, 124(6), 1241–1252.
- [36] Dean, P., Redgrave, P., Westby, G. W. (1989). Event or emergency? Two response systems in the mammalian superior colliculus. *Trends Neurosci*, 12(4), 137-147.
- [37] Butler, A. B. (2008) Evolution of brains, cognition, and consciousness. *Brain Res Bull*, 75(2-4), 442–449.
- [38] Nguyen, M. N., Matsumoto, J., Hori, E. et al. (2014). Neuronal responses to face-like and facial stimuli in the monkey superior colliculus. *Front. Behav Neurosci*, 8, 85.
- [39] Nguyen, M. N., Nishimaru, H., Matsumoto, J. et al. (2016) Population coding of facial information in the monkey superior colliculus and pulvinar. *Front Neurosci*, 10, 583.
- [40] DesJardin, J. T., Holmes, A. L., Forcelli, P. A., et al. (2013). Defense-like behaviors evoked by pharmacological disinhibition of the superior colliculus in the primate. *J Neurosci*, 33(1),150–5.

- [41] Maior, R. S., Hori, E., Barros, M. et al. (2011). Superior colliculus lesions impair threat responsiveness in infant capuchin monkeys. *Neurosci Lett*, 504(3), 257 – 260.
- [42] Keay, K. A., Dean, P., Redgrave, P. (1990). N-methyl D-aspartate (NMDA) evoked changes in blood pressure and heart rate from the rat superior colliculus. *Exp Brain Res*, 80(1), 148-56.
- [43] Westby, G. W., Keay, K. A., Redgrave, P., Dean, P., Bannister, M. (1990). Output pathways from the rat superior colliculus mediating approach and avoidance have different sensory properties. *Exp Brain Res*, 81(3), 626-38.
- [44] Liddell, B. J., Brown, K. J., Kemp, A. H. et al. (2005). A direct brainstem-amygdala-cortical 'alarm' system for subliminal signals of fear. *Neuroimage*, 24(1), 235-43.
- [45] Almeida, I., Soares, S. C, Castelo-Branco, M. (2015). The distinct role of the amygdala, superior colliculus and pulvinar in processing of central and peripheral snakes. *PLoS One*, 10(6), e0129949.
- [46] Benevento, L. A., Fallon, J. H. (1975). The ascending projections of the superior colliculus in the rhesus monkey (*Macaca mulatta*). *J Comp Neurol*, 160(3), 339–361.
- [47] Van Le, Q., Isbell, L. A., Matsumoto, J. et al. (2013). Pulvinar neurons reveal neurobiological evidence of past selection for rapid detection of snakes. *Proc Natl. Acad Sci U.S.A.*, 110(47), 19000–19005.
- [48] Jones, E. G., Burton, H. (1976) A projection from the medial pulvinar to the amygdala in primates. *Brain Res*, 104(1), 142-7.
- [49] Morris, J. S., Öhman, A., Dolan, R. J. (1999). A subcortical pathway to the right amygdala mediating ‘unseen’ fear. *Proc Natl Acad Sci USA*, 96(4), 1680–1685.
- [50] Williams, L. M. et al. (2006). Mode of functional connectivity in amygdala pathways dissociates level of awareness for signals of fear. *J Neurosci*, 26(36), 9264–9271.

- [51] Tamietto, M., & de Gelder, B. (2010). Neural bases of the non-conscious perception of emotional signals. *Nat Rev Neurosci*, 11(10), 697–709.
- [52] Nakataki, M., Soravia, L. M., Schwab, S. et al. (2017). Glucocorticoid administration improves aberrant fear-processing networks in spider phobia. *Neuropsychopharmacology*, 42(2), 485-494.
- [53] Rolland, M., Carcenac, C., Overton, P.G., Savasta, M., Coizet, V. (2013). Enhanced visual responses in the superior colliculus and subthalamic nucleus in an animal model of Parkinson's disease. *Neuroscience*, 252, 277-88.
- [54] Moro, E., Bellot, E., Meoni, S. et al. (2020). Visual dysfunction of the superior colliculus in de novo Parkinsonian patients. *Ann Neurol*, 87(4), 533-546.
- [55] Almada, R. C., Coimbra, N. C. (2015). Recruitment of striatonigral disinhibitory and nigrothalamic inhibitory GABAergic pathways during the organization of defensive behavior by mice in a dangerous environment with the venomous snake *Bothrops alternatus* (Reptilia, Viperidae). *Synapse*, 69(6), 299-313.
- [56] Azulay, J. P., Mesure, S., Blin, O. (2006). Influence of visual cues on gait in Parkinson's disease: contribution to attention or sensory dependence? *J Neurol Sci*, 248(1-2), 192-5.
- [57] Okuma, Y. (2006). Freezing of gait in Parkinson's disease. *J Neurol*, 253(Suppl 7), vii27-32.
- [58] Soares, S. C., Maior, R. S., Isbell, L. A., Tomaz, C., Nishijo, H. (2017). Fast detector/first responder: interactions between the superior colliculus-pulvinar pathway and stimuli relevant to primates. *Front Neurosci*, 11, 67.
- [59] Billington, J., Wilkie, R. M., Field, D. T., Wann, J. P. (2011). Neural processing of imminent collision in humans. *Proc Biol Sci*, 278(1711), 1476-81.
- [60] Hanes, D. P., Wurtz, R. H. (2001). Interaction of the frontal eye field and superior colliculus for saccade generation. *J Neurophysiol*, 85(2), 804-15.

- [61] Schiller, P. H., Sandell, J. H., Maunsell, J. H. (1987). The effect of frontal eye field and superior colliculus lesions on saccadic latencies in the rhesus monkey. *J Neurophysiol*, 57(4), 1033-49.
- [62] Pollux, P. M. J., Robertson, C. (2001). Voluntary and automatic visual spatial shifts of attention in Parkinson's disease: An analysis of costs and benefits. *J Clin Exp Neuropsychol*, 23(5), 662–670.
- [63] Briand, K. A., Hening, W., Poizner, H., Sereno, A. B. (2001). Automatic orienting of visuospatial attention in Parkinson's disease. *Neuropsychologia*, 39(11), 1240–1249.
- [64] Fielding, J., Georgiou-Karistianis, N., White, O. (2006). The role of the basal ganglia in the control of automatic visuospatial attention. *J Int Neuropsychol Soc*, 12(5), 657-67.
- [65] Roll, A., Wierzbicka, M. M., Wolf, W. (1996). The "gap paradigm" leads to express-like saccadic reaction times in Parkinson's disease. *Exp Brain Res*, 111(1), 131-138.
- [66] Kingstone, A., Klein, R., Morein-Zamir, S., Hunt, A., Fisk, J., Maxner, C. (2002). Orienting attention in aging and Parkinson's disease: distinguishing modes of control. *J Clin Exp Neuropsychol*, 24(7), 951-67.
- [67] Chan, F., Armstrong, I. T., Pari, G., Riopelle, R. J., Munoz, D. P. (2005). Deficits in saccadic eye-movement control in Parkinson's disease. *Neuropsychologia*, 43(5), 784–796.
- [68] Otero-Millan, J., Schneider, R., Leigh, R. J., Macknik, S. L., Martinez-Conde, S. (2013). Saccades during attempted fixation in parkinsonian disorders and recessive ataxia: from microsaccades to square-wave jerks. *PLoS One*, 8(3), e58535.
- [69] Edelman, J. A., Keller, E. L. (1996). Activity of visuomotor burst neurons in the superior colliculus accompanying express saccades. *J Neurophysiol*, 76(2), 908-26.
- [70] Hafed, Z. M., Goffart, L., Krauzlis, R. J. (2009). A neural mechanism for microsaccade generation in the primate superior colliculus. *Science*, 323(5916), 940–943.

- [71] Goodale, M. A., Foreman, N. P., Milner, A. D. (1978). Visual orientation in the rat: a dissociation of deficits following cortical and collicular lesions. *Exp Brain Res*, 31(3), 445-57.
- [72] Milner, A. D., Foreman, N. P., Goodale, M. A. (1978). Go-left go-right discrimination performance and distractibility following lesions of prefrontal cortex or superior colliculus in stump-tail macaques. *Neuropsychologia*, 16(4), 381-90.
- [73] Gaymard, B., Francois, C., Ploner, C.J., Condy, C., Rivaud-Pechoux, S. (2003). A direct prefrontotectal tract against distractibility in the human brain. *Ann Neurol*, 53: 542-5.
- [74] Henderson, T., Georgiou-Karistianis, N. et al. (2011). Inhibitory control during smooth pursuit in Parkinson's disease and Huntington's disease. *Mov Disord*, 26(10), 1893-9.
- [75] Sahibzada, N., Dean, P., Redgrave, P. (1986). Movements resembling orientation or avoidance elicited by electrical stimulation of the superior colliculus in rats. *J Neurosci*, 6(3), 723-33.
- [76] Hopkins, D. A., Niessen, L. W. (1976). Substantia nigra projections to the reticular formation, superior colliculus and central gray in the rat, cat and monkey. *Neurosci Lett*, 2(5), 253-9.
- [77] Chevalier, G., Thierry, A. M., Shibasaki, T., Féger, J. (1981) Evidence for a GABAergic inhibitory nigrotectal pathway in the rat. *Neurosci Lett*, 21(1), 67-70.
- [78] Huang, P., Xuan, M., Gu, Q. et al. (2015). Abnormal amygdala function in Parkinson's disease patients and its relationship to depression. *J Affect Disord*, 183, 263-8.
- [79] Tessitore, A., Hariri, A. R., Fera, F. et al. (2002). Dopamine modulates the response of the human amygdala: a study in Parkinson's disease. *J Neurosci*, 22(20), 9099-103.
- [80] Yoshimura, N., Kawamura, M., Masaoka, Y., Homma, I. (2005). The amygdala of patients with Parkinson's disease is silent in response to fearful facial expressions. *Neuroscience*, 131(2), 523-34.

- [81] Hashemi, M. M., Gladwin, T. E., de Valk, N. M., et al. (2019) Neural dynamics of shooting decisions and the switch from freeze to fight. *Sci Rep*, 9, 4240.
- [82] Ehgoetz Martens, K. A., Ellard, C.G., Almeida, Q. J. (2015). Virtually-induced threat in Parkinson's: Dopaminergic interactions between anxiety and sensory-perceptual processing while walking. *Neuropsychologia*, 79(Pt B), SI 322-331.
- [83] Lindvall, O., Bjorklund, A. (1974) The glyoxylic acid fluorescence histochemical method: a detailed account of the methodology for the visualization of central catecholamine neurons. *Histochemistry*, 39(2), 97-127.
- [84] Parent, A., Descarries, L., Beaudet, A. (1981). Organization of ascending serotonin systems in the adult rat brain. A radioautographic study after intraventricular administration of [3H]5-hydroxytryptamine. *Neuroscience*, 6(2), 115-38.
- [85] Tan, H., Mooney, R. D., Rhoades, R. W. (1999). Effects of norepinephrine upon superficial layer neurons in the superior colliculus of the hamster: in vitro studies. *Visual Neurosci*, 16(3), 557-70.
- [86] Dommett, E. J., Overton, P. G., Greenfield, S. A. (2009). Drug therapies for attentional disorders alter the signal-to-noise ratio in the superior colliculus. *Neuroscience*, 164(3), 1369-76.
- [87] Sawada, H., Umemura, A., Kohsaka, M. et al. (2018). Pharmacological interventions for anxiety in Parkinson's disease sufferers. *Expert Opin Pharmacother*, 19(10), 1071-1076.

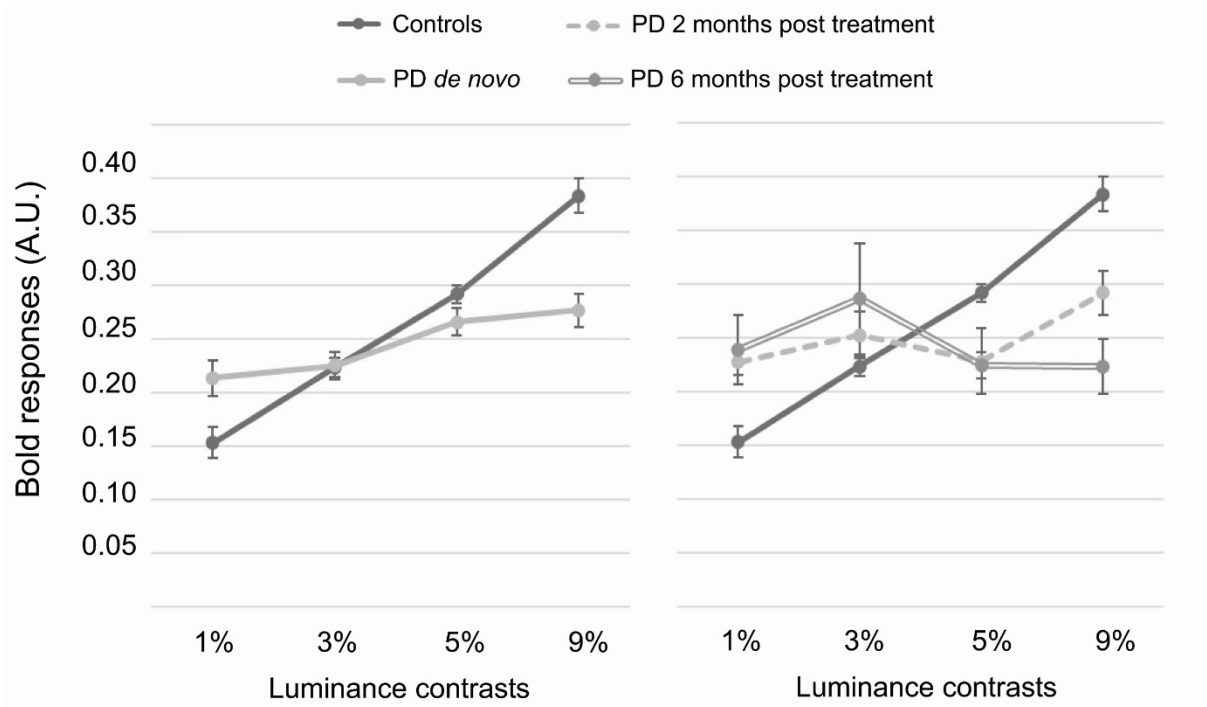


Figure 1