



Acta Veterinaria-Beograd 2018, 68 (3), 361-372

UDK: 599.731.4-147.14

DOI: 10.2478/acve-2018-0030

Case report

SKULL BONE ANATOMY OF THE YOUNG COMMON HIPPOPOTAMUS (*Hippopotamus amphibius*)

ZORIĆ Zoran¹, LOZANČE Olivera^{1*}, MARINKOVIĆ Darko², BLAGOJEVIĆ Miloš¹, NEŠIĆ Ivana¹, DEMUS Natalija³, ĐORĐEVIĆ Milena¹

¹Department of Anatomy, Faculty of Veterinary Medicine, University of Belgrade, Bulevar oslobođenja 18, 11000 Beograd, Republic of Serbia; ²Department of Pathology, Faculty of Veterinary Medicine, University of Belgrade, Bulevar oslobođenja 18, 11000 Beograd, Republic of Serbia; ³Lviv National University of Veterinary Medicine and Biotechnologies named after S.Gzhytskyj, Pekarska Street 50, 79010 Lviv, Ukraine

(Received 18 May, Accepted 26 June 2018)

Hippopotamidae family is nowadays represented by two species within two different genera: pygmy hippopotamus (*Choeropsis liberiensis*) and common hippopotamus (*Hippopotamus amphibius*). The common hippopotamus has a very unique anatomy, and the shape of the body, especially the head is adapted for a semi-aquatic life style. The morphological examination and description of the gross anatomical features of the hippopotamus skull is described in this paper. The shape of the skull is adapted for the amphibian way of life. Their eyes, ears and nostrils are placed high on the roof of the skull which allows these organs to remain above the surface of the water while the animal is being submerged underwater. The skull is massive, but the brain case (*neurocranium*) is extremely small compared with the *splanchnocranium* and complete head. The dental formula of the common hippopotamus is: incisors (I) 2/2, canines (C) 1/1, premolars (P) 3-4/3-4 and molars (M) 3/3. Incisors and canine teeth are formed in the shape of tusks and are used for threat or “demonstration of power” among animals when vigorously fighting. Incisor teeth grow continuously and are twice bigger in males than in females.

Key words: anatomy, hippopotamus, morphology, skull

INTRODUCTION

Hippopotamidae family is nowadays represented by two species within two different genera: pygmy hippopotamus (*Choeropsis liberiensis*) and common hippopotamus (*Hippopotamus amphibius*). Common hippopotamus (*Hippopotamus amphibius*) is one of the largest land mammals, and the heaviest of the *Artiodactyla* which can weigh up to 3000kg. Today it inhabits rivers, lakes and wetlands of the sub-Saharan Africa. A number of these animals also live in Zoological gardens throughout the world. This

*Corresponding author: e-mail: olivera@vet.bg.ac.rs

animal species is listed in the International Union for the Conservation of Nature (IUCN) Red List of Threatened Species as Vulnerable to Extinction. Common hippopotamus has a very unique anatomy, and the shape of its body, especially the head is adapted for the semi-aquatic life style. Their eyes, ears and nostrils are placed high on the roof of the skull which allows these organs to remain above the surface of the water while the animal is being submerged. There are few studies on the skull of the common hippopotamus, and they are related to the evolution of ontogeny of the skull [1], dentition and ageing [2,3], and osteological features of the skull [4-7]. The skull is massive, but the brain case (*neurocranium*) is extremely small compared with *splanchnocranium* and complete head. From the dorsal view, the skull of the common hippopotamus has the appearance of the hourglass with wide caudal and rostral parts and a narrow middle part (maxillary region). As mentioned, its shape is adapted for the amphibious way of life, and the eyes (orbits) of the hippopotamus are on the roof of the skull, positioned laterally. Their massive jaw is capable of a 150 degree mouth opening. Dental formula of the common hippopotamus is: incisors (I) 2/2, canines (C) 1/1, premolars (P) 3-4/3-4 and molars (M) 3/3. Incisors and canine teeth are formed in the shape of tusks and are used for threat or “demonstration of power” among animals when vigorously fighting. Incisor teeth grow continuously and are twice bigger in males than in females. The crowned premolars and bunodont molars are used for the mastication of the food [2,3,8].

CASE PRESENTATION

A 1-year-old, female common hippopotamus died suddenly in Belgrade Zoo garden as the result of a rare congenital heart anomaly - Single left coronary artery (LCA) [9]. After complete necropsy and histopathological examination, the carcass was submitted to the Department of Anatomy at the Faculty of Veterinary Medicine, University of Belgrade. Maceration of the skeletal remains was performed and dry bone samples were examined. Since very scanty literature data are available, the morphological examination and description of the gross anatomical features of the hippopotamus skull is described in this paper.

The skull of this young common hippopotamus was massive with a dominant *splanchnocranium* compared to the brain case (*neurocranium*). As in other animal species, bones of the common hippopotamus are divided in bones which form the cranium – the brain case (*ossa cranii*) and other bones which are form the oral, nasal and pharyngeal cavity as well as the facial skeleton (*ossa faciei*).

Cranial bones are: occipital bone (*os occipitale*), sphenoidal bone (*os sphenoidale*), ethmoid bone (*os ethmoidale*), interparietal bone (*os interparietale*), parietal bone (*os parietale*), frontal bone (*os frontale*), and temporal bone (*os temporale*). The cranial cavity (*cavum cranii*) in the common hippopotamus consists of the aboral (Figure 1), dorsal - roof of the skull (Figure 2), lateral (Figure 3) and ventral part - basis of the skull (Figure 4).

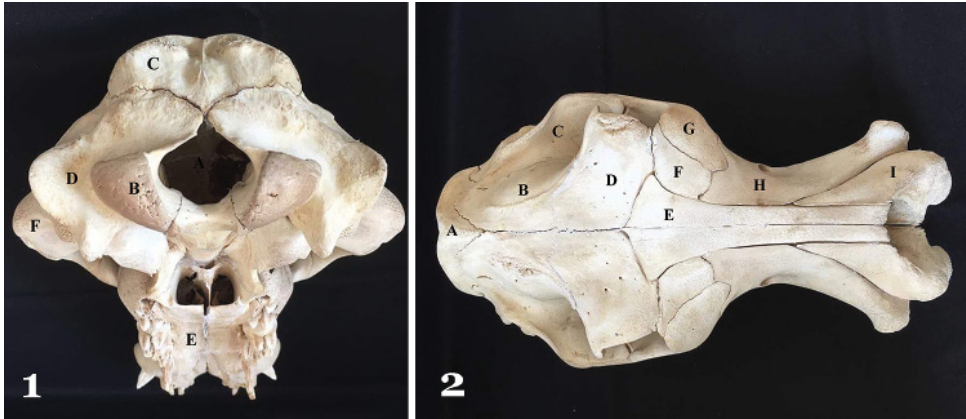


Figure 1. A – Foramen magnum; B – Condylus occipitalis; C – Os occipitale (squama occipitalis); D – Os occipitale (partes laterales); E – Palatum durum; F – Os temporale (Processus zygomaticum)

Figure 2. A – Os occipitale; B – Os parietale; C – Os temporale; D – Os frontale; E – Os nasale; F – Os lacrimale; G – Os zygomaticum; H – Maxilla; I – Os incisivum

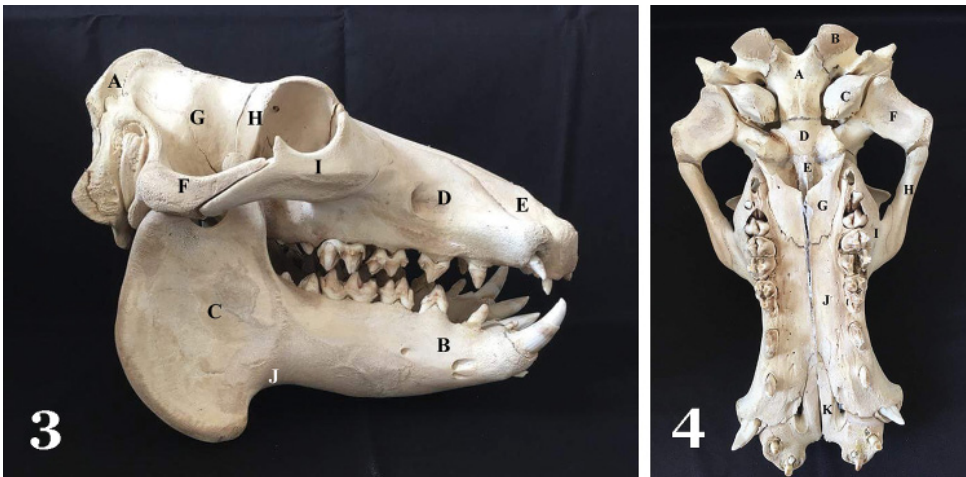


Figure 3. A – Os occipitale; B – Corpus mandibulae; C – Ramus mandibulae; D – Maxilla; E – Os incisivum; F – Os temporale (processus zygomaticus); G – Os parietale; H – Os zygomaticum (processus temporalis); I – Incisura vasorum facialium

Figure 4. A – Os occipitale (basis occipitalis); B – Condylus occipitalis; C – Bulla tympani; D – Os sphenoidale; E – Vomer; F – Os temporale (processus zygomaticus); G – Os palatinum; H – Os zygomaticum (processus temporalis); I – Maxilla; J – Processus palatinus maxillae; K – Processus palatinus ossis incisivi

The occipital bone forms the aboral part of the skull, while the parietal, interparietal, frontal and occipital bone form the roof of the skull. The lateral part of the skull is formed by the temporal bone while the part of occipital bone and sphenoidal bone form the basal part of the skull. The occipital bone of the common hippopotamus consists of two lateral parts and one basal part, and it closes the cranial cavity from

the aboral side and only small part of this bone forms the roof of the skull. In the hippopotamus this bone communicates with the parietal, temporal and sphenoidal bones. The squamous part of the occipital bone (*squama occipitalis*) builds up a plate-like vertically positioned aboral part of the bone with a notable nuchal ridge (*crista nuchae*). This ridge divides this bone on its larger ventral part which closes the cranial cavity from the aboral side, and dorsal horizontal, smaller part which is fused with interparietal bone and which forms small aboral part of the roof of the skull. In the middle of the squamous part of the occipital bone a rough external occipital protuberance (*protuberantia occipitalis externa*) is present, and on the dorsal side of the same part of the occipital bone an external sagittal crest (*crista sagittalis externa*) is notable. The lateral parts of the occipital bone (*partes laterales*) are situated laterally and ventrally from the squamous part of the occipital bone, and a well differentiated articular occipital condyle (*condylus occipitalis*) is developed for the connection to the first neck vertebra. *Foramen magnum* is positioned between these two condyles and has a notch on the dorsal side, while the paracondylar processes is situated laterally from the occipital condyles. Between the paracondylar process and the occipital condyle, on the lateral part of the occipital bone, the hypoglossal canal (*canalis n. hypoglossi*) is present. The basal part of the occipital bone (*pars basilaris*), median unpaired bone, is situated in the base of the skull and it communicates (the cartilaginous communication) cranially with the corpus of the sphenoid bone (*basisphenoid*), caudally it forms the ventral part of the *foramen magnum*. On the ventral part of the basal part of the occipital bone two small bony protrusions (*tubercula muscularia*) are present [4-6,10,11].

The sphenoid bone (*os sphenoidale*) is the median unpaired bone of the rostral part of the base of the skull which consists of median unpaired body (*corpus*), paired wings (*alae*), and paired pterygoid processes (*processus pterygoideus*). As mentioned, caudally this bone communicates with the basal part of the occipital bone, and rostrally with the *vomer*. The wings (*alae*) of the sphenoid bone are situated laterally from the body of this bone and are connected with it by cartilaginous bond. Rostrally they are connected with the sagittal lamina of the palatine bone and the base of the pterygoid bone. The ethmoid foramen (*foramen ethmodale*) is present on the orbital part of the pterygoid processes. On the rostral part, near the nasal cavity, the sphenoid bone communicates with the unpaired ethmoid bone (*os ethmoidale*) which separates the cranial and nasal cavity [5,6,10,11].

The ethmoid bone in the hippopotamus communicates with the *vomer*, presphenoid bone (*os presphenoidale*) and palatine bones, while its rostral part is situated between the orbital parts of the frontal bones. Similar to other mammal species the ethmoid bone consists of the bony laminae (cribrous, perpendicular, orbital, roof and basal), as well as ethmoturbinat bones. The *Lamina cribrosa*, the most aboral part of ethmoid bone is in the form of a very thin perforated bony plate which is positioned transversally and separates the cranial and nasal cavity. The cranial concave side of this bone is divided with a crest (*crista galli*) on two parts or fossae (*fossa ethmoidalis*). The *Lamina*

perpendicularis s. mediana is situated medially and represents the caudal part of the nasal septum which lays all the way to the *crista galli* [10,11].

The interparietal bone (*os interparietale*) of this young common hippopotamus was situated in the aboral part of the roof of the skull and it was already fused with the occipital bone [5].

The parietal bone (*os parietale*), a paired, well developed bone which forms most of the roof of the skull was positioned rostrally of the interparietal bone. Both parietal bones were joined together in the medial plane and were communicating rostrally with the frontal bones, laterally with the temporal bones, aborally with the occipital and interparietal bones and ventrally with the sphenoid bone. Well visible *linea temporalis* represents the border line to the temporal fossa. *Crista sagitalis externa* was not notable, although it was described to be well defined in adult animals [5,4].

Paired rectangular frontal bones (*Ossa frontalia*) were joining together in the medial plane and these bones were positioned rostrally from the parietal bones (Figure 5). Frontal bones formed concave forehead and the rostral part of the roof of the skull. Rostrally they were communicating with the nasal and lacrimal bones and aborally with parietal bones, and also they were communicating with ethmoid, sphenoid as well as palatine bones and maxilla. On the frontal bones of the common hippopotamus squamous and orbital part were distinguished while nasal part was undeveloped. Squamous part of the frontal bone (*squama frontalis*) was forming the osseous base of the forehead, and its outer medial part was concave while its lateral part (close to the orbit) was extremely developed and emphasized above the frontal surface and it is forming massive osseous convex dome shaped dorsal part of the orbit. One of the notable characteristics of the skull of the common hippopotamus was the convex smooth supra-orbital ridge that formed upper margin of the orbit which projected from the surface of the skull, allowing the eyes to remain above the surface of the water while the animal is being submerged under the water. Low osseous crest - *linea temporalis*, which is the prolongation of the *linea temporalis* of the parietal bone, was separating frontal bone from the parietal fossa. Internal lamina (*lamina interna*) of the frontal bone formed the rostral part of the roof of the skull. It was concave and had impressions of the brain gyri (*impressiones digitate*). Also, this lamina partly formed the aboral part of the nasal cavity. As described in other mammals, the frontal sinus (*sinus frontalis*) was situated between external and internal lamina of the frontal bone. In the common hippopotamus lateral part of the frontal bone forms the zygomatic process (*processus zygomaticus*) towards the zygomatic bone, but it does not reach the zygomatic arch (*arcus zygomaticus*), and supraorbital foramen (*foramen supraorbitale*) and is not visible in this animal species. The orbital part of the frontal bone formed the most part of the medial wall of the orbit and *margo orbitalis* divided this part from the squamous part. Its surface is smooth and slightly convex [4-6,10,11].

Laterally from the frontal bone, paired temporal bones (*os temporale*) were situated and it formed the largest part of the lateral part of the roof of the skull. This bone

communicated caudally with occipital, cranially with the zygomatic, dorsally with the parietal and ventrally with the sphenoid bone. Although it is positioned laterally from the frontal bone, it was not communicating with this bone, similarly to domestic mammals. It was articulating with the mandible and it was forming cartilaginous connection with hyoid bone. This bone consisted of squamous part, petrous part and tympanic part. The squamous part (*pars squamosa*) was the largest part of the temporal bone which outer convex surface formed the temporal fossa (*fossa temporalis*). Massive laterally bended zygomatic process (*processus zygomaticus*) was positioned on the ventral part of the squamous part of the temporal bone, and this part represented the widest part of the skull of the common hippopotamus, which could be important for craniometry. This process was joining with the temporal part of the zygomatic bone forming the well-developed zygomatic arch. Large and spacious articular surface for the articulation with the mandible was situated on the ventral part of the zygomatic arch. Petrous part (*pars petrosa*) of the temporal bone was covered laterally with the caudal part of the *pars squamosa* of the temporal bone. Caudally it was communicating with the occipital bone, dorsally and rostrally with the parietal bone and rostrally and laterally with the tympanic part of the temporal bone. Massive, ventrally oriented mastoid process (*processus mastoideus*) was situated towards the occipital bone, while on the ventral part of the well-developed tympanic bulla there was short styloid process (*processus styloideus*) present, which connects to the hyoid bone. Between the mastoid and styloid process outer opening of the facial channel (*foramen stylomastoideum*) was positioned and facial nerve is emerging through this opening to the facial surface. Inner acoustic opening (*porus acusticus internus*) which leads to the internal acoustic meatus (*meatus acusticus internus*) was positioned on the medial surface of this bone. The most prominent part of the tympanic part of the temporal bone was outer osseous acoustic meatus (*meatus acusticus externus*) with the outer acoustic opening (*porus acusticus externus*). This meatus had ventro-medial direction and leads to the inner ear cavity (*cavum tympani*). The thin-walled, round to conical, spacious osseous tympanic bulla (*bulla tympanica*), part of the temporal bone, was forming the cavity of the inner ear (*cavum tympani*). Foramen orbitorotundum was well developed [4-6,10,11].

Facial bones in common hippopotamus are: nasal bone (*os nasale*), lacrimal bone (*os lacrimale*), zygomatic bone (*os zygomaticum*), maxillary bone (*maxilla*), incisive bone (*os incisivum*), palatal bone (*os palatinum*), pterygoid bone (*os pterygoideum*), vomer (vomer), ventral nasal conchal bone (*os conche nasalis ventralis*), mandible (*mandibula*) and hyoid bone (*os hyoideum*).

Nasal bones, that are paired, long, narrow plane bones, which slightly widened on the aboral part, were placed rostrally of frontal bones. Two nasal bones were contacting in the medial plane forming dorsal wall of the nasal cavity. Laterally these bones were communicating with maxilla and lacrimal bones, and aborally with frontal bones. Their facial surface was slightly concave, while on the inner surface, towards nasal cavity, they were forming internal osseous ridge (*crista ethmoidalis*) for the purpose of connection of the dorsal nasal conchal bone (*os conchae nasalis dorsalis*). As mentioned

by other authors, rostral free part of the nasal bone, as well as *incisura nasoincisiva*, was not present in this animal, hence these bones, together with the incisive bone, are forming quite large bony opening of the nasal cavity (*apertura nasi ossea*) [4,5].

Laterally, in the aboral part of the nasal bone, small paired lacrimal bone (*os lacrimale*) was placed, forming the part of the rostral orbital wall, as well as dorsolateral outer part of the face. This bone was communicating with frontal, zygomatic and maxillary bones. Small lacrimal fossa (*fossa sacci lacrimalis*) was placed on the orbital surface of zygomatic bone and on the bottom of this fossa opening for the lacrimal canal (*canalis lacrimalis*) was notable. *Bula lacrimalis* was well developed with notable lacrimal sinus, similarly to ruminants. Orbital ridge (*margo orbitalis*) was separating the orbital from the facial surface.

Large zygomatic bone (*os zygomaticum*) was placed ventrolaterally from the lacrimal bone, and this bone had massive convex process which is extending towards parietal bone and communicating with its process (*processus temporalis*) forming the massive zygomatic arch. Distance between two zygomatic arches was the widest facial diameter. This bone had characteristic long crest which formed the roof of the maxillary fossa, as described by Lucy *et al.* (2017) [5].

Maxillary bone (*maxilla*) was massive paired bone placed ventral to the lacrimal bone which was forming the lateral walls of the face and nasal cavity, and also contained canine, premolar and molar teeth. This bone was communicating with almost all facial bones, and also with frontal bones. Both maxillary bones were conjoined together by their palatal processes, while dorsally nasal bones separated these two paired bones. Maxilla in this young common hippopotamus had well developed body of the bone (*corpus*), alveolar process (*processus alveolaris*), zygomatic process (*processus zygomaticus*) and palatal process (*processus palatinus*). Body of the maxilla represented the largest part of this bone and it is containing maxillary sinus (*sinus maxillaris*). Large infraorbital opening (*foramen infraorbitale*) was notable on the facial surface aborally from the orbit, and this opening represented outer opening of the infraorbital channel (*canalis infraorbitalis*) which was placed in the level of the third premolar tooth, although Lucy *et al.* (2017) described multiple infraorbital foramina (placed in the level of the second premolar tooth) as well as multiple infraorbital channels in adult animal. Caudal, pterygopalatal surface of maxilla (*facies pterygopalatina*) formed well defined osseous tuber (*tuber maxillare*) which together with vertical part of the palatal bone formed narrow fossa (*fossa pterygopalatina*) with three large openings: dorsal (*foramen maxillare*) which led to infraorbital channel, middle (*foramen sphenopalatinum*) which led to nasal cavity, and ventral (*foramen palatinum caudale*) which led to palatal channel which was extending all to the margin with incisive bones. Nasal surface of the maxilla (*facies nasalis*) was concave and formed the largest part of the lateral wall of the nasal cavity. It contained osseous lacrimal sulcus (*sulcus lacrimalis*) which was caudally transforming in the osseous lacrimal channel (*canalis lacrimalis*). Ventrally from the lacrimal sulcus, conchal ridge (*crista conchalis*), which acts as a connection place for the osseous ventral nasal concha (*os conchae nasalis ventralis*), was situated. Ventral nasal concha, thin paper-

like spirally shaped bone which formed the osseous base of the ventral nasal concha (*concha nasalis ventralis*), was connected to the medial maxillary ridge (*crista conchalis*) and was convoluted dorsally – clockwise. Maxilla of the common hippopotamus, as in other mammals, had alveolar process (*processus alveolaris*) which in this young animal had one large alveoli for the canine tooth and five alveoli for the premolar and molar teeth (*alveoli dentales*), although in adult animals one large alveoli for the canine tooth and seven to eight alveoli for the premolar and molar teeth are present [5,8]. Characteristic feature in maxilla of the common hippopotamus is the large osseous tuber above the canine tooth – *eminentia canina*, which was also present in this young animal. Palatinal process (*processus palatinus*) is fusing to the same process of the opposite side in the medial plane forming the osseous part of the hard palate (*palatum durum osseum*) [5,11].

Rostrally from the maxilla, paired incisive bone (*os incisivum*) was located and this bone formed the extremely massive rostral part of the upper jaw with two large dental alveoli for the upper incisor teeth. Body (*corpus*) of the incisive bone was the most massive part of this bone with characteristic apical part in form of large rounded rough tuber (*eminentia incisiva*) was notable above the central incisor tooth. Palatinal process (*processus palatinus*) of incisive bone was like in other mammals in form of well developed thin, bony, dorso-ventrally flattened plate, which was forming rostral part of the osseous base of the hard palate. Both palatinal process were communicating in the medial plane forming long narrow fissure (*fissura interincisiva*), while their lateral ridge was separated from the maxilla and nasal part of incisive bone by wide oval – shaped opening (*fissura palatina*) [2,3,5,11].

Beside the palatinal process of the incisive bone and palatinal process of the maxilla, aboral wall of the osseous basis of the hard palate was also formed by paired palatine bone (*os palatinum*). Both these bones, similarly to incisive bone and maxilla, were fused in the medial plane (*lamina horizontalis*). Aborally, sagittal part of the palatine bone (*lamina sagittalis s. perpendicularis*) formed lateral walls of the nasal part of the pharyngeal cavity. Aboral part of this bone was forming pterygoid process of the palatine bone (*processus pterygoideus*) which is partly situated between the pterygoid process of the sphenoid and pterygoid bones. Caudal part of this bone was forming the pterygopalatine fossa (*fossa pterygopalatina*).

Vomer (*vomer*) is unpaired, thin, elongated bony plate which was extending from the base of the skull rostrally. It was located between the palatine bones. On its dorsal side this bone had narrow sulcus in which medial lamina of the ethmoid bone (*lamina medialis ossis ethmoidalis*) and bony part of the nasal septum were positioned. Rostrally, vomer was communicating with the dorsal side of the palatine processes of the incisive and maxillary bones, aborally it was communicating with palatine and pterygoid bones and with its caudal part, which was widened in form of the wings (*ala vomeris*), was communicating with the body of the sphenoid bone, making the border between bones of the base of the skull and the other facial bones. Vomer is also connecting with caudal part of the nasal cavity floor making the aboral separation of the nasal choanae.

Beside vomer, pterygoid bone (*os pterygoideum*) is unpaired, short, wide square shaped bone, located on the medial side of the vertical part of the palatine bone, on the margin of the rostral part of the base of the skull and facial bones. Beside, the palatine bone was also communicating with vomer and sphenoid bone.

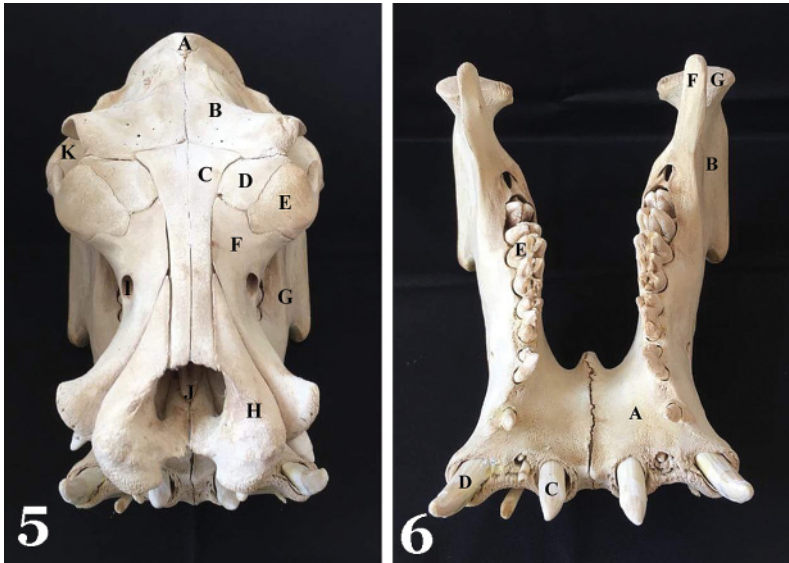


Figure 5. A – Os occipitale; B – Os frontale; C – Os nasale; D – Os lacrimale; E – Os zygomaticum; F – Maxilla; G – Corpus mandibulae; H – Os incisivum; I – Foramen infraorbitale; J – Vomer; K – Orbita

Figure 6. A – Corpus mandibulae; B – Ramus mandibulae; C – Dens incisivum; D – Dens caninus; E – Dens molaris; F – Processus coronoideus; G – Processus condylaris

Mandible (*mandibula*) was the massive powerful osseous base of the lower jaw in common hippopotamus (Figure 6). Two halves were forming this bone which were not fused in the animal of this age. It had articular connection with the temporal bones allowing a 150 degree opening of the jaw. Mandible consisted of body (*corpus mandibulae*), and plate like aboral vertical part – branch of the mandible (*ramus mandibulae*) (Figure 7). Incisive part (*pars incisiva*) and molar part (*pars molaris*) were distinguished on the mandibular body. Massive, extremely wide incisive part of mandible had two flat and wide surfaces - tongue surface and lip surface. In the alveolar ridge two alveoli for the incisive teeth and one for canine tooth were present on the each side. Molar part of mandible (*pars molaris*) had lateral and medial surface and two ridges. Two large and one small openings (*foramina mentalia*) were present on the lateral mandibular surface. Inter-alveolar space (*margo interalveolaris seu diastema*) between canine tooth and first and second premolar tooth was short, which, according to the literature, wasn't case in adult animals [5]. Mandibular body was extremely wide, massive and powerful ventrally rounded. Left and right molar part were forming mandibular space (*spatium mandibulae*) which is wide, spacious trapezoid shaped. Mandibular branch

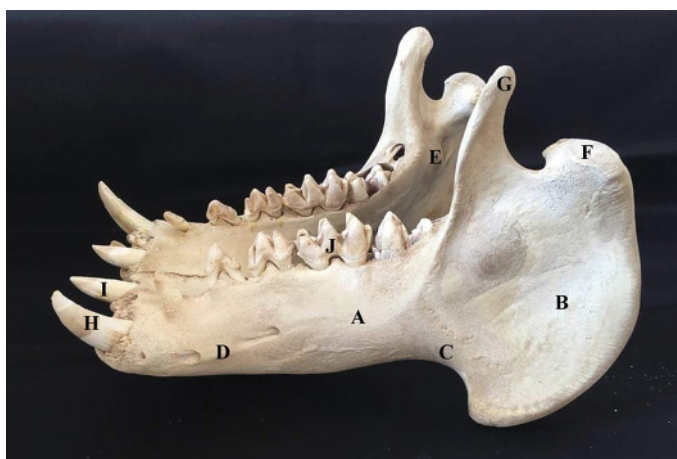


Figure 7. A – Corpus mandibulae; B – Ramus mandibulae; C – Incisura vasorum facialis; D – Foramen mentale; E – Foramen mandibulae; F – Processus condylaris; G – Processus coronoideus; H – Dens caninus; I – Dens incisivum

had characteristic ventrolateral extension and it was separated from the mandibular body with deep rounded vascular notch (*incisura vasorum facialis*). Both fossas of the mandibular branch – masseter and pterygoid (*fossa masseterica et fossa pterygoidea*) were flat and spacious. On the dorsal medial part of the mandibular branch, close to condylar and coronoid processes (*processus condylaris et processus coronoideus*), spacious mandibular opening (*foramen mandibulare*) was located. Caudal ventral part of the mandibular branch was bended dorsally forming well expressed, convex, caudal mandibular angle (*angulus mandibulae*) [2,3,5,11].

Authors' contributions

Preparation of a skull bone of the hippopotamus was done by ZZ, LO, MD, BM, NI and ĐM. MD was involved in complete necropsy and hystopathological examination. description of anatomical features of cranial bones was performed by ZZ, LO and MD and description of anatomical features of facial bones was performed by BM, NI, DN and ĐM. The manuscript was written by ZZ, LO, MD and ĐM. All authors read and approved the final manuscript.

Declaration of conflicting interests

The author(s) declared no potential conflicts of interest with respect to the research, authorship, and/or publication of this article.

REFERENCES

1. Weston EM: Evolution of ontogeny in the hippopotamus skull: using allometry to dissect developmental change. *Biological Journal of the Linnean Society*. 2003, 80: 625-638.
2. Hooijer DA: On the supposed hexaprotodont milk dentition in *Hippopotamus amphibios* L. *Zool. Med. Museum Leiden* 1942, 24: 187-196.
3. Laws RM: Dentition and ageing of the hippopotamus. *African Journal of Ecology*. 1968, 6: 19-52.
4. Leidy J: On the osteology of the head of *Hippopotamus* and a description of the osteological characters of a new genus of Hippopotamidae. *Jour. Acad. Nat. Sci. n.s.* 1952, 2(3): 207-234
5. Lucy KM, Indu VR, Leena C, Fathima R, George C, Patki HS, Surjith S, Anneth AJ: Gross anatomy of the skull of the hippopotamus (*Hippopotamus amphibios*). *Indian Journal Of Animal Research*, 2017, B-3277: 1-3, DOI:10.18805/ijar.v0i0F.7659
6. O'Leary MA: Basicranial anatomy of extant Artiodactyla. *Bulletin American Museum Of Natural History*, 2016, 409: 44-48
7. Orliac MJ, Guy F, Lebrun R: Osteological connections of the petrosal bone of the extant Hippopotamidae *Hippopotamus amphibios* and *Choeropsis liberiensis*. *MorphoMuseum Anatomy Atlas Journal* 2016, 1: 1-6
8. Walzer C, Stalder G: Hippopotamidae (*Hippopotamus*). In *Fowler's Zoo and Wild Animal medicine*, edited by Miller RE and Fowler ME, volume 8, Elsevier Saunders, 2015.
9. Marinković D, Aničić M, Özvegy J, Lozanče O, Aleksić-Kovačević S: *Single Left Coronary Artery in a Common Hippopotamus* (*Hippopotamus amphibios*). Programme and Abstract Book of the Third Joint European Congress of the ESVP, ESTP and the ECVP »Cutting Edge Pathology«, Lyon, France, 30th August – 2nd September, 2017, p. 142 (ESVP/ECVP Proceedings, *Journal of Comparative pathology* vol. 158, p.148, 2018.)
10. Nickel R, Schummer A, Seiferle, E: *The Anatomy of Domestic Animals-Vol.1*. Verlag Paul Parey, Berlin, Hamburg, 1986.
11. Dyce KM, Sack WO, Wensing CJG: *Textbook of veterinary anatomy*, fourth edition, Saunders Elsevier, 2010.

KOSTI GLAVE NILSKOG KONJA (*Hippopotamus amphibius*) STAROG GODINU DANA

ZORIĆ Zoran, LOZANČE Olivera, MARINKOVIĆ Darko, BLAGOJEVIĆ Miloš, NEŠIĆ Ivana, DEMUS Natalija, ĐORĐEVIĆ Milena

Familija *Hippopotamidae* je danas predstavljena sa dve vrste u okviru dva različita roda: patuljasti nilski konj (*Choeropsis liberiensis*) i običan nilski konj (*Hippopotamus amphibius*).

Nilski konj ima specifične anatomske karakteristike, naročito oblik tela i glave, koje predstavljaju adaptaciju na polu-vodeni način života. Ovim radom su obuhvaćena morfološka ispitivanja i opis anatomske osobenosti lobanje mladog nilskog konja.

Oblik lobanje je prilagođen za duži boravak u vodi. Oči, uši i nozdrve su postavljene visoko na krovu lobanje što omogućava ovim organima da ostanu van vode dok je životinja u nju uronjena. Glava je masivna dok je lobanjska duplja mala u poređenju sa kostima lica i kompletnom glavom. Zubna formula nilskog konja je: sekutići (I) 2/2, očnjaci (C) 1/1, prekutnjaci (P)3-4/3-4 i kutnjaci (M) 3/3. Sekutići i očnjaci su oblika kljove i koriste se za pretnju i «demonstraciju» moći među životinjama u surovim okršajima. Zubi sekutići rastu neprekidno i dvostruko su veći kod mužjaka u odnosu na ženke.