

DE GRUYTER
OPENBull Vet Inst Pulawy 59, 505-509, 2015
DOI:10.1515/bvip-2015-0075

Efficiency of modified therapeutic protocol in the treatment of some varieties of canine cardiovascular dirofilariasis

Predrag Stepanović¹, Tamara Ilić², Nikola Krstić³, Sanda Dimitrijević²¹Department of Equine, Small Animal, Poultry, and Wild Animal Diseases, ²Department of Parasitology,³Department of Radiology and Radiation Hygiene, Faculty of Veterinary Medicine,
University of Belgrade, 11000 Beograd, Serbia
pedja@vet.bg.ac.rs

Received: July 12, 2015

Accepted: November 26, 2015

Abstract

The paper presents clinical diagnostic approaches and therapeutic effects of a specific protocol for the treatment of dogs with cardiovascular dirofilariasis in the Belgrade City (Serbia) territory. The study involved 50 privately owned dogs of different breeds, gender, and age, all showing signs of cardio – respiratory disorders. In addition to a general physical examination, blood tests were done to detect microfilaria and adult forms, and X-ray, ECG, and echocardiography were performed as well. At the first examination, 34 out of 50 examined dogs were positive for microfilaria and adult forms. Because of a lack of drug used as „the golden standard“ in dirofilariasis treatment, it involved a combination of doxycycline (10 mg/kg) and ivermectin (6 µg/kg) supported with Advocate – Bayer spot-on. After six months, the first control was performed while continuing treatment with the aforesaid protocol, and the second control was performed after 12 months. Of the 34 treated dogs, all were negative for microfilaria, as early as after the first six months of the treatment (100%). One dog was positive for adult forms of the parasite after six and 12 months. In echocardiography and X-ray examination after 12 months, six dogs showed evident chronic changes. At controls conducted at sixth month and at one year, the implemented therapy was successful in 97.05% (33/34) of primarily infected dogs.

Keywords: dog, cardiovascular dirofilariasis, *Dirofilaria immitis*, drug therapy.

Introduction

The cause of cardiovascular dirofilariasis in dogs is the nematode *Dirofilaria immitis* which leads to a significant functional damage of the canine heart and therefore has a higher pathological significance than other types of filariae (*D. repens* and *Acanthocheilonema*, syn. *Dipetalonema reconditum*). *D. repens* can also cause infections in humans, so it is important to diagnose accurately the type of the genus *Dirofilaria* (7, 19, 24). Cardiovascular dirofilariasis leads to clinical signs of "right heart insufficiency" with haemoglobinuria and possible cardio respiratory collapse (11, 25). Symptoms develop gradually, starting with chronic cough, which leads to a moderate or severe dyspnea and general weakness. Different lung sounds can be heard in the caudal lobes, while heart auscultation can reveal a split second heart tone. Later on, congestive heart failure results in the formation of

ascites and oedema of the extremities. At this stage anorexia, weight loss, and dehydration develop. On the right side of the chest, heart murmurs can be heard as the result of tricuspid valvular insufficiency and cardiac arrhythmia, which is the most common consequence of atrial fibrillation. Death is mainly due to cachexia or respiratory distress after thromboembolism (10). Laboratory diagnosis of dirofilariasis involves the detection and identification of microfilaria in the peripheral blood (8, 27), performance of immunological tests (13, 20, 23), and molecular diagnostic methods (5, 9, 26). If dogs manifest symptoms and the results of blood tests are negative, then radiography of the thorax should be performed (15). When clinical and radiological signs indicate a high intensity infection, then echocardiography is the procedure of choice (4). In the final stages of heart disease, echocardiography and electrocardiography may indicate the degree of myocardial damage (15). Based on these results, an

insight into the degree of pathological changes is attained and symptomatic therapy can be applied in order to improve the cardiopulmonary circulation and lung aeration (4, 15). In the treatment of this very extensive infection in privately owned dogs, we opted for the "soft kill" approach, according to modified protocols by Mc Call *et al.* (16) and Bazzochi *et al.* (4), published by Grandi *et al.* (10), which provides a smaller chance for thromboembolic insults compared to other protocols (4, 15, 16). In this study we have shown the effects of treatment of dogs with diagnosed cardiovascular dirofilariasis during a two-year period (2012–2013). The aim of the present study was to evaluate efficacy of the modified therapeutic protocol reported by Grandi *et al.* (10) in 2010, (involving a combination of ivermectin and doxycycline, modified with combination of imidoclopride and moxidectin) on the varieties *D. immitis* found on the territory of republic of Serbia (26). We decided to use this combination due to a lack of drug available in our country, despite the guidelines given by the American Heartworm Society (1). Detection of microfilaria in the peripheral blood of the tested dogs was performed after concentration of the blood samples by the modified Knott's test. Determination of *D. immitis* was based on morphological characteristics. The test sensitivity was low (about 60%), which means that diagnosis can be established in a little more than half of infected patients (14). In 30% of the dogs circulating microfilariae cannot be found (due to the host immune response to microfilariae, and as a result of the administration of drugs or microfilaricidal treatment the number is too small to be detected). A negative test result for the detection of microfilariae in the peripheral blood of the animal does not exclude infection (25). Therefore, the lately used PCR method is highly sensitive (mf 4/mL) and specific for *D. immitis* and *D. repens* (18). The antigen tests for *D. immitis* as quick "one-step ELISA" are highly specific (100%) and there is no possibility of cross-reactions with other antigens of the parasite (*D. repens*, species of the genus *Dipetalonema*). The test detects the adult forms of the parasite, based on antigens produced only by females (antigens of the uterus), and provides information on the intensity of infection (3). From the clinical standpoint, it is important that the results of laboratory diagnosis of *D. immitis* can be obtained only six months after the cessation of the first season of mosquitoes. Therefore, a routine control of clinically healthy dogs is done in April, *i.e.* six months after the cessation of the mosquito season in north hemisphere. Imaging is primarily useful in the clinical assessment of the damage to the lung tissue, but it cannot assess the intensity of the parasitic infection (28). Changes in the electrical activity of the heart muscle during ECG recordings are manifested as alterations to the right of the electrical axis of the heart, as well as in the occurrence of atrial fibrillations, which appear in the final stages of the disease (6). Echocardiographic

imaging offers direct images of the heart cavities and associated blood vessels, visualisation of parasites in the right ventricle and atrium of the heart, the *v. cava caudalis*, the main pulmonary artery and both pulmonary arteries. The parasite is visualised as a double line parallel shadow floating in the right ventricle of the heart or in the lumen of blood vessels (29). Ultrasound of the heart is required to specify the degree of infection by adult parasites and clearly define the cardiac effects of pulmonary hypertension, which directly affects the choice of treatment and determines the prognosis. Following successful treatment, there is a massive destruction of a large number of parasites, which results in pulmonary thromboembolism. A moderate degree of the latter can go clinically unapparent, although more often a respiratory distress syndrome is manifested, which in some cases can be life-threatening to the infected dog.

The aim of the studies was to evaluate clinical diagnostic approaches and therapeutic effects of a specific protocol for the treatment of dogs with cardiovascular dirofilariasis in the Belgrade City (Serbia) territory.

Material and Methods

The study was conducted on 50 dogs from the Belgrade area that showed cardio – respiratory disorders. All examined dogs were of a known origin and spent at least several hours outdoors on a daily basis. The surveyed dogs were of different breeds, age groups (from 1 to 15 years), and genders. All dogs were submitted to general clinical and parasitological examination, X-ray, ECG, and echocardiography. Blood was sampled directly from the *v. cephalica antebrachii*. The blood samples were analysed with a diagnostic technique for the detection and determination of microfilaria (modified Knott's test) and were screened for antigen-binding forms of adult *D. immitis*. Serological testing for circulating *D. immitis* antigen was performed with the commercial kits for the detection of adult forms (Vetall CHW Ag test kit, Witness[®] Dirofilaria Symbiotic Europe, France) according to the manufacturer's specifications. Chest X-ray diagnosis was conducted on the basis of recordings made in left lateral (LL) and dorsoventral (DV) projections. Electrocardiographic examination was performed on a 12-lead ECG "Cardiax" apparatus. Echocardiography of the patients was used for the purpose of assessing the degree of infection and blood flow in the pulmonary artery and right ventricle lumen. Once the diagnosis of the disease was determined, treatment was started in all dogs for 12 months and involved the application of a combination of doxycycline at a dose of 10 mg/kg (Doxycycline tabs. 100 mg) and ivermectin at a dose of 6 µg/kg (Promectin salt. inves 1%, Spain). Drugs were administered according to the modified protocol

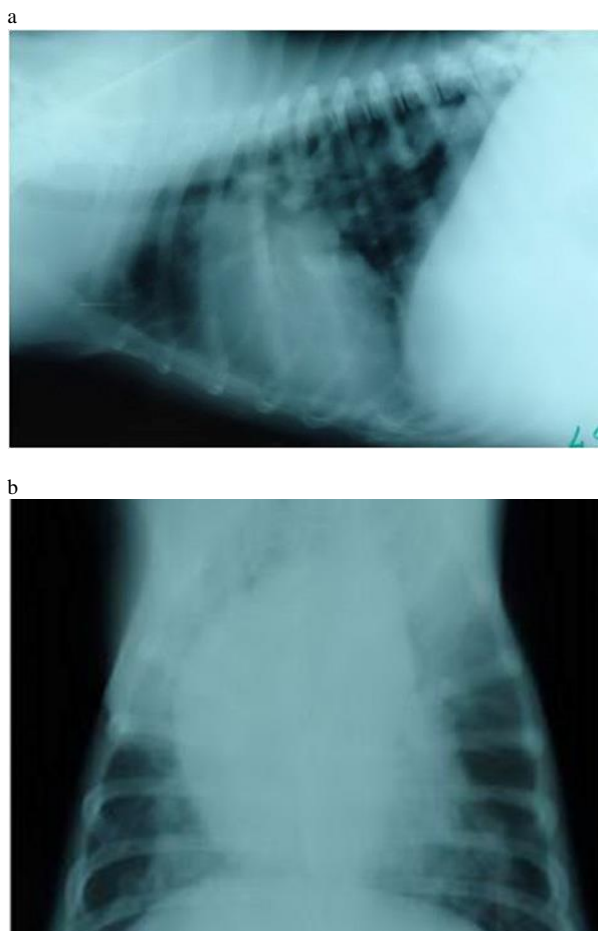
published by Grandi *et al.* (10). In addition, the Advocate - Bayer "spot-on" formulation was regularly applied as a preventative for the cohabitant healthy dogs. The protocol also included strict rest for the animals during the treatment, as in the above-mentioned protocols. All dogs were treated on the first day with a "spot-on" formulation-Advocate, Bayer, and thereon on a regular basis during all 12 months. At the beginning of the treatment, prednisolone was administered in a therapeutic concentration (2 mg/kg) on the 1st, 3rd, 5th, and 9th day, in order to prevent the development of vasculitis and allergic reactions after necrosis of microfilariae due to the first application of ivermectin. The treatment started with administration of doxycycline for the first 30 d (1 × 10 mg/kg) in order to eliminate endo-symbiotic *Wolbachia* bacteria. The filaricidal part of the treatment consisted of Promectin given once every 15 d in a dose of 6 µg/kg for one year.

After the first six months the dogs were examined for the presence of the adult forms of *Dirofilaria immitis*, and the check-up was repeated once again six months later. If both controls were negative, it was assumed that the animal was cured. The treatment was well-tolerated by all dogs. An improvement of tolerance to physical activity was observed as early as three weeks from the beginning of the treatment (cheerful behaviour, awareness, alertness, improved appetite, and better general condition).

Results

The analysis involved all the data relating to the presence of adult *D. immitis* antigens at the time of examination (CHW 0), after six months (CHW 6), and after one year (CHW 12), as well as the data on the presence of microfilaria in the blood (MF 0), after six months (MF 6), and after one year (MF 12). Characteristic changes were marked on radiographs and echocardiographs at the first examination (Ro 0 and Echo 0) and at the end of the treatment, *i.e.* after one year (Ro 12 and Echo 12). Using a modified Knott's test at the first blood analysis (MF 0), microfilariae were found in the peripheral blood in 68.0% (50/34) of dogs with cardio-respiratory disorders. From this moment, we operated with 34 dogs with confirmed *D. immitis* infection. Two other control examinations (MF 6 and MF 12) revealed that none of the dogs had microfilariae in the blood. During the first antigen testing (CHW 0), 47.05% of dogs were negative (16/34). After six months (CHW 6), 20.58% of dogs were still positive (7/34). After 12 months of treatment (CHW 12), one dog was still positive to adult *D. immitis* antigens. Radiography of the thorax taken at the beginning of the treatment (Ro 0) revealed inflammatory lesions of the vascular tree and perivascular pulmonary parenchyma in 35.29% of dogs (12/34). The findings included

enlargement of the pulmonary artery, pulmonary uneven shadows, and right cardiomegaly. Pulmonary oedema was detected in 14.70% of dogs (5/34). In control echocardiograms and roentgenograms (LL projection) taken 12 months after the start of the treatment (Ro 12), only six dogs showed chronic alterations (17.64%). In other dogs, a significant improvement or complete absence of clinical symptoms was observed. Radiographic signs of altered lungs shadow in these dogs were visible mainly in the diaphragmatic lobes as irregular and uneven chronic inflammatory lesions of the vascular tree and perivascular lung parenchyma. A total of 11.76% (4/34) dogs died before the scheduled annual veterinary check-up. Death was not caused by the treatment or the presence of adult forms of *D. immitis*. Necropsies confirmed other causes (tumours of parenchymal organs or surgery).



Figs 1a and 1b. LL and DV views of the lungs of a female American Staffordshire terrier, 5-year-old, with radiological changes characteristic of dirofilariasis (Ro 0)

Echocardiographic changes on the right side of the heart and pulmonary arteries, which are characteristic of dirofilariasis, were evident during the first examination (Echo 0) in 29.41% of dogs (10/34). After a year (Echo 12), the changes were recorded in 17.64% of dogs (6/34).

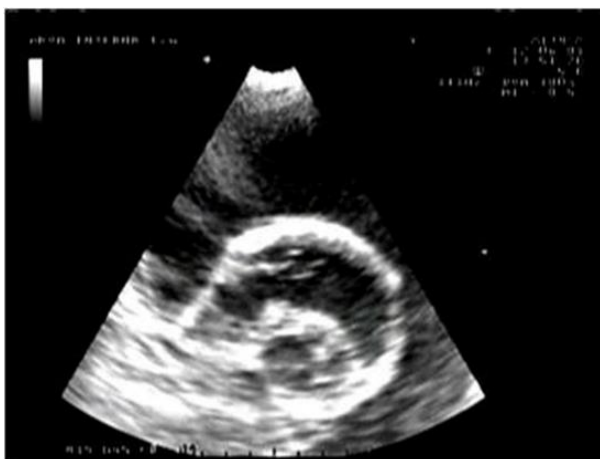

Fig. 2. Echocardiogram of a dog with strong hydro pericardium and clearly visible adult forms of *Dirofilaria* in the lumen of the right ventricle and pulmonary artery - Caval syndrome (Echo 0)

The examined electrocardiograms mainly revealed physiological values, while a small number of patients showed sinus rhythm tachycardia. A shift of the electrical axis to the right was observed in 41.17% of dogs (14/34). Of 10 dogs which had irregularities on the first echo examination, four expressed AV-block II degree, which constituted 71.42% of the total number of dogs with ECG changes detected, and two dogs had atrial fibrillations, which was 35.71% of the total number of dogs in which ECG changes were observed.

Discussion

Because of poor availability of specific drug in our country, we decided to implement a different treatment protocol from the one recommended by the American Heartworm Society (AHS) Guidelines (1). The only drug currently registered for adulticide therapy against canine heartworm is the arsenic derivative melarsomine dihydrochloride (Immiticide, Merial), but the treatment is often followed by severe pulmonary thrombosis following the death of the entire worm population in a short period (12). It only affects adult *Dirofilaria* and its L₅ developmental stage. It is a common opinion that this product should not be used in dogs that have already expressed the caval syndrome due to a high risk of embolisation (17). Destruction of the end symbiotic bacteria (*Wolbachia*) with antibiotic treatment (doxycycline, 10 mg/kg, twice a day for four weeks) is of great importance for a successful treatment (10, 21). Better results have been obtained with a combination of doxycycline and ivermectin (15, 26), but the true mechanism of synergism is still unknown. It is believed that doxycycline destroys the end symbiotic bacteria (AHS 2014) and ivermectin causes somatic degeneration of the parasite (10). The AHS (2012, 2014) recommends a year-round administration of chemoprophylactic drugs to prevent heartworm disease. Before the start of the preventive treatment, it is compulsory to check whether the animal is infected

with the adult forms of the parasite. For this reason it is of utmost importance to test yearly all dogs in the district regions for the presence of microfilaria (2). The obtained results are part of a clinical study aiming to show the importance of various diagnostic procedures in the evaluation of the degree of *Dirofilaria* infection in dogs, as well as to present one of the therapeutic protocols used to treat cardiovascular dirofilariasis (22). In endemic areas such as the territory of Belgrade (18), during clinical anamnesis, supported with the necessary epizootic information, a reasonable suspicion of cardiovascular dirofilariasis may be put forward. We tried to modify the previous treatment protocols in order to evaluate whether bi-weekly ivermectin intervals in combination with doxycycline and Advocate could lead to elimination of the parasite in naturally infected dogs with lower occurrence of thromboembolism. According to our investigation, the microfilaricidal effect was shown in 100% of dogs on six-month check-up. It is in coherence with the results reported by Venco *et al.* (29). The continuous administration of ivermectin was also found to be efficacious against adult parasites, as was demonstrated by Grandi *et al.* (10). In our study, adulticide effect was observed after six months in 20.58% of dogs (7/34), and after 12 months it was found in 97.05% of dogs (33/34). The continuous administration of ivermectin in our study was also discovered to be efficacious against all stages of the parasites, as it was shown by Venco *et al.* (29), and McCall *et al.* (17), who treated experimentally infected dogs. This protocol has demonstrated a significant effect of a combination of doxycycline and ivermectin with imidoclopride and moxidectin (Advocate, Bayer), against all stages of the parasites, including mature worms, in naturally infected dogs. Necropsy of four dogs, which died before the scheduled annual veterinary check-up, (but after six months of treatment) showed that this treatment regimen resulted in 100% adulticide effect on the worm population. One dog which remained positive after a year's treatment was a 5-year-old female Bernese mountain dog. We recommend this protocol in moderate to mild infections. In persistent cases when dogs have adult parasites after 12 months of therapy, arsenic derivatives were unavoidable. We also recommend for all dog-owners from the tested area to twice a year subject their dogs to serological tests for the presence of the filarias (*Dirofilaria* spp. and *Dipetalonema reconditum*), with a view to protect the health of people and animals. Furthermore, we recommend to treat healthy dogs from this area with combination of imidoclopride and moxidectin (Advocate, Bayer) once a month in the mosquito season.

Conflict of Interests Statement: The authors declare that they have no financial or non-financial conflict of interests in publication of this article.

Animal Rights Statement: The study was reviewed and approved by Animal Ethic Committee of the Faculty of Veterinary Medicine, University of Belgrade, Serbia.

Acknowledgements: This work was financed by the Ministry of Education and Science of the Republic of Serbia, within Projects TR31084 and 173001.

References

- American Heartworm Society (AHS): Current Canine Guidelines for the Prevention, Diagnosis and Management of Heartworm (*Dirofilaria immitis*) Infection in Dogs. (Revised, 2014).
- Atkins C.E., Miller M.W.: Is there a better way to administer Heartworm adulticidal therapy? *Vet Med* 2003, 98, 310–317.
- Badertscher R.R., Losonsky J.M., Paul A.J., Kneller S.K.: Two dimensional echocardiography for diagnosis of dirofilariasis in nine dogs. *J Am Vet Med Assoc* 1988, 193, 843–846.
- Bazzocchi C., Mortarino M., Grandi G., Kramer L.H., Genchi C., Bandi C., Genchi M., Sacchi L., Mc Call J.W.: Combined ivermectin and doxycycline treatment has microfilaricidal and adulticidal activity against *Dirofilaria immitis* in experimentally infected dogs. *Int J Parasitol* 2008, 38, 1401–1410.
- Ciocan R., Darabus G.H., Jacso O., Fok E.: Detection of *Dirofilaria* spp. in dogs by PCR. *Bull UASVM Vet Med* 2010, 67, 40–44.
- Di Saco B., Venzoni A.: Clinical classification of heartworm disease for the purpose of adding objectivity to the assessment of therapeutic efficacy of adulticidal drug in the field. In: *Proceedings of Heartworm Symposium of American Heartworm Society*, edited by Otto G.H., Batavia, 1992, pp. 209–214.
- Dimitrijević S., Tasić A., Tasić S., Adamović V., Ilić T., Miladinović-Tasić N.: Filariasis in dogs in Serbia. In: *Proceedings of the first European Dirofilaria days*, edited by Genchi C., Rinaldi L., Cringoli G., Zagreb, Croatia, 2007, p. 201.
- Genchi C., Venco L., Genchi M.: Guideline for the laboratory diagnosis of canine and feline *Dirofilaria* infections. *Mappe Parassitol* 2005, 8, 139–144.
- Gioia G., Lecova L., Genchi M., Ferri E., Genchi C., Mortarino M.: Highly sensitive multiplex PCR for simultaneous detection and discrimination of *Dirofilaria immitis* and *Dirofilaria repens* in canine peripheral blood. *Vet Parasitol* 2010, 172, 160–163.
- Grandi G., Quintavalla C., Mavropoulou A., Genchi M., Gnudi G., Bertoni G., Kramer L.: A combination of doxycycline and ivermectin is adulticidal in dogs with naturally acquired heartworm disease (*Dirofilaria immitis*). *Vet Parasitol* 2010, 169, 347–351.
- Kitagawa H., Sasaki Y., Isihara K.: Canine *Dirofilaria* hemoglobinuria: changes in right heart hemodynamics and heartworm migration from pulmonary artery toward right atrium following beta - blocker administration. *Jpn J Vet Sci* 1987, 49, 1081–1086.
- Kramer L., Grandi G., Leoni M., Passeri B., McCall J., Genchi C., Mortarino M., Bazzocchi C.: Wolbachia and its influence on the pathology and immunology of *Dirofilaria immitis* infection. *Vet Parasitol* 2008, 158, 191–195.
- Köse M., Erdoğan M.: Serological screening of canine heartworm (*Dirofilaria immitis*) infections in Turkey. *Berl Munch Tierarztl Wochenschr* 2012, 125, 503–508.
- Magnis J., Lorentz S., Guardone L., Grimm F., Magi M., Naucke J.T., Deplazes P.: Morphometric analyses of canine blood microfilariae isolated by the Knott's test enables *Dirofilaria immitis* and *D. repens* species-specific and *Acanthocheilonema* (syn. *Dipetalonema*) genus-specific diagnosis. *Parasit Vectors* 2013, 6, 48–52.
- Mc Call J.W.: The safety-net story about macro cyclic lactone heartworm preventatives: a review, an update and recommendations. *Vet Parasitol* 2005, 133, 197–206.
- Mc Call J.W., Genchi C., Kramer L., Guerrero J., Dzimianski M.T., Supakorndej P., Mansour A.M., Mc Call S.D., Supakorndej N., Grandi G., Carson B.: Heartworm and Wolbachia: therapeutic implications. *Vet Parasitol* 2008, 158, 204–214.
- Mc Call J.W., Kramer L., Genchi C., Guerrero J., Dzimianski M.T., Supakorndej P., Carson B.: Effects of doxycycline on early infections of *Dirofilaria immitis* in dogs. *Vet Parasitol* 2011, 176, 361–367.
- Miodrag J.: *Prilog poznavanju dijagnostike, terapije i profilakse dirofilarioze pasa na teritoriji Grada Beograda*, Academic specialisation (on post graduate course for pathology and therapy of small animals) Faculty of Veterinary Medicine. University of Belgrade, Serbia. 2012.
- Morchón R., Carretón E., González-Miguel J.: Heartworm disease (*Dirofilaria immitis*) and their vectors in Europe - new distribution trends. *Front Physiol* 2012, 3: 196.
- Razi Jalali H.M., Mosallanejad B., Avizeh R.: *Dirofilaria immitis* infection in a Dachshund dog: diagnosis and treatment. *Iranian J Vet Sci Technol* 2011, 3, 49–56.
- Rossi M.I., Paiva J., Bendas A., Mendes-de-Almeida F., Knackfuss F., Miranda M., Guerrero J., Fernandes O., Labarthe N.: Effects of doxycycline on the endosymbiont Wolbachia in *Dirofilaria immitis* (Leidy, 1856) naturally infected dogs. *Vet Parasitol* 2010, 174, 119–123.
- Tai C.T., Huang P.H.: Echocardiographic assessment of right heart indices in dogs with elevated pulmonary artery pressure associated with chronic respiratory disorders, heartworm disease, and chronic degenerative mitral valvular disease. *Veterinami Med* 2013, 58, 613–620.
- Taraneh Ö., Gülay V.: Seroprevalence of *Dirofilaria immitis* in stray dogs in Istanbul and Izmir. *Turk J Vet Anim Sci* 2005, 29, 785–789.
- Tasić A., Ilić T., Dimitrijević S.: Epizootiological characteristics of dirofilariosis. In: *Dirofilariosis of dogs and cats. Proceedings of Serbian Association of Small Animal Practitioners*. Belgrade, Serbia, 2010, p. 6.
- Tasić A., Rossi L., Tasić S., Miladinović-Tasić N., Ilić T., Dimitrijević S.: Survey of canine dirofilariosis in Vojvodina. *Serbia. Parasitol Res* 2008, 103, 1297–1302.
- Tasić A., Tasić-Otašević S., Gabrielli S., Miladinović-Tasić N., Ignjatović A., Dornević J., Dimitrijević S., Cancrini G.: Canine dirofilariosis in two non-investigated areas of Serbia: epidemiological and genetical aspects. *Vector-Borne Zoon Dis* 2012, 12, 1031–1035.
- Tasić A.: *Ispitivanje prevalencije filarioza pasa u nekim područjima Vojvodine*. PhD Dissertation. Belgrade University. Belgrade, 2005.
- Venco L., Genchi C., Vigevani Colson P., Kramer L.: Relative utility of echocardiography, radiography, serologic testing and microfilariae counts to predict adult worm burden in dogs naturally infected with heartworms. In: Seward LE, Knight DH, Eds: *Recent Advances in Heartworm Disease*. Symposium '01. American Heartworm Society. Batavia, Illinois, 2003, pp 111–124.
- Venco L., Mc Call J.W., Guerrero J., Genchi C.: Efficacy of long term monthly administration of ivermectin on the progress of naturally acquired heartworm infections in dogs. *Vet Parasitol* 2004, 124, 259–268.

