

DIAGNOSIS, ANESTHESIA AND OPERATIVE REPAIR OF URINARY BLADDER RUPTURE IN FOALS

KOVAČ M *, TOTH J *, SCHÜTTERT B *, TAMBUR Z **, KULIŠIĆ Z*** and MIHAILOVIĆ M. ***

** Tierklinik Hochmoor Von Braunstr. 10, 48712 Gecher-Hochmoor, Germany, ** Institute of Microbiology, Military Medical Academy, Belgrade, Crotravska 17 Yugoslavia and *** Faculty of Veterinary Medicine, Belgrade, Bul. JNA 18, Yugoslavia*

(Received 14. July, 2000)

This study describes methods for the diagnosis, anesthesia and operative repair in 4 neonatal foals with urinary bladder rupture. Diagnosis was based on case history, clinical signs, changes in serum chemistry analyses (hyponatremia, hyperkalemia, hypochloremia, metabolic acidosis and increased serum creatinine and urea nitrogen levels), abdominocentesis, ultrasound and electrocardiographs.

As electrolyte abnormalities and acid-base derangement can lead to the development of cardiac arrhythmia during general anesthesia, surgical treatment of urinary bladder rupture in neonatal foals should be performed when the animal's condition has been stabilized. This includes infusion of physiological saline solution, 5 % glucose infusion with insulin (0.1U/kg) and 1.4% sodiumdrgencarbonate.

Key words: urinary bladder rupture, diagnosis, anesthesia, operative repair

INTRODUCTION

The most common cause of uroperitoneum (i.e. urine in the peritoneal cavity) in neonatal foals is urachus patens and ruptured urinary bladder. Bladder rupture is mainly seen in male foals, although it also occurs in females. The postulated mechanism for the occurrence of a ruptured bladder is high intraluminal pressure, during parturition (Ronney, 1971; Fenger, 1988). Some foals, may however develop the urinary bladder defect secondary to trauma or septicemia and cystitis (Richardson, 1985).

In selected cases, conservative management (i.e. abdominal drainage, correction of metabolic disturbances) may be beneficial in small bladder tears (Gibson, 1992). However, the risk of peritonitis, continued leakage of urine, and ascending urinary tract infection with this option makes surgical repair of ruptured urinary bladders the preferred method of treatment.

There are currently no large-scale clinical reports of urinary bladder rupture in neonatal foals. This paper describes our methods for the exact diagnosis, the anesthesia and the operative technique in foals with ruptured bladder.

MATERIAL AND METHODS

Medical records of foals with ruptured urinary bladder admitted to the Veterinary Clinic, Hochmoor (Germany) were reviewed. This study involved 4 foals (3 males, 1 female) of different breeds (Holstein 3, Standardbred 1).

The diagnosis of urinary bladder rupture in the foals investigated was made on the basis of case history, clinical signs, complete blood and serum chemistry analyses (packed cell volume, total plasma protein, white blood cells, potassium, sodium, chloride, creatinine and blood urea concentrations), abdominocentesis, ultrasound and electrocardiographs.

Laboratory diagnosis:

Electrolyte, creatinine and blood urea nitrogen concentration were measured using an automated spectrophotometry system (VetLyteTest Analyser, IDEXX Inc, USA). Packed cell volume and white blood cells were determined on an automated cell counter (OBC Vet-Autoreader, IDEXX Inc., USA). Blood gas analyses (Base excess) were determined using the "AVL Compact 2 Blood Gas Analyse" machine.

Ultrasound examination of the abdomen was carried out with the foal in the standing position, with an ultrasound frequency of 7 MHz (Kranzbühler Ultraschall, Germany).

Electrocardiographic (ECG) changes were also monitored (Hellige EG-51, Germany) closely in the treated foals. The ECG was recorded with the standard Einthoven and Goldberger limb leads method (Speed: 25 mm/s; Deflection 1 cm = 1 mV).

Descriptive statistics (performed with the following software: "Statistic Analyses System") were used to evaluate quantitative parameters before and after preoperative management.

RESULTS

Case history and clinical signs

After rupture foals usually become obvious at 1 to 4 days old (with an average age of 2.5 days), showing the following symptoms: mild colic, depression and anorexia. Distention of the abdomen was also present. Such foals usually had a lordotic posture, with the rear limbs placed caudally.

In three of the foals no urination had been seen from the day they were born, until they were brought to the clinic. Only one foal showed streaming urine, but decreased volume of micturation.

On referral to Veterinary Clinic Hochmoor the heart rate of the foals averaged 104 (s.d. +/- 25) beats/min. Body temperature was between 38.4 - 39.1°C.

Blood and Serum Chemistry

On admission to the clinic initial examination (before preoperative treatment) showed the foals to have: severe hyponatremia, hypochloremia and hyperkalemia as well as elevated packed cell volume (Table 1). The foals also had a decreased base excess (i.e. metabolic acidosis) and increased serum creatinine and urea nitrogen levels (Table 1). The severity of these changes related to the duration of uroperitoneum.

Table 1. Hematology and serum biochemical values before surgery of foals with urinary bladder rupture

| Parameter | Before preoperative treatment | | After preoperative treatment | |
|---|-------------------------------|------|------------------------------|------|
| | X | SD | X | SD |
| Packed cell volume (l/l) | 0.43 | 0.03 | 0.36 | 0.03 |
| Total plasma protein (g/L) | 60.54 | 8.52 | 51.45 | 7.40 |
| Base Excess of Blood (mmol/L) | -3.23 | 0.23 | 0.62 | 1.05 |
| White blood cells (x10 ³ /fil) | 9.51 | 2.88 | 8.90 | 1.91 |
| Sodium (mEq/L) | 114.65 | 6.54 | 129.34 | 6.78 |
| Potassium (mEq/L) | 6.79 | 1.56 | 5.12 | 0.55 |
| Chloride (mEq/l) | 87.54 | 3.14 | 97.45 | 4.32 |
| Blood urea nitrogen (mg/dl) | 51.32 | 2.34 | 44.45 | 3.43 |
| Creatinine (mg/dl) | 2.98 | 0.64 | 2.45 | 0.46 |

Ultrasound findings in all cases showed a large volume of fluid in the abdomen.

The diagnosis of ruptured urinary bladder was confirmed through abdominocentesis. Varying quantities of clear to turbid yellow fluid were obtained. Elevated potassium and creatinine levels were observed in the peritoneal fluid.

The ECG findings in foals with ruptured bladder were as follows (Figure 1): sinus tachykardia with a broad QS-wave (0.11-0.14 sec) and a very large (0.6-0.9 mV) negative T-wave.

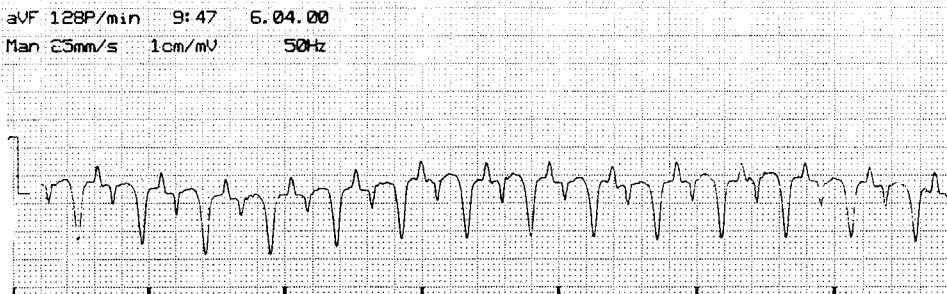


Figure 1. ECG findings in a 2 day-old foal with ruptured urinary bladder

Preoperative treatment

Prior to surgical correction of the ruptured bladder, we concentrated our management of uroperitoneum patients on correction of the electrolyte and acid-base disturbances. Physiological saline solution (0.9 % NaCl) was given i.v. (3 ml/kg/h) in order to restore serum sodium and chloride concentrations to

normal and to reduce the high serum potassium concentration. Three foals with severe hyperkalemia were also given 5% glucose (1 ml/kg/h) i.v. and insulin 0.1 U/kg s.c. One foal with severe metabolic acidosis received 1.4% sodiumhydrogencarbonate (NaHCO_3), at 1 mmol/kg BW.

Blood and serum biochemical analyses after this preoperative treatment are shown in Table 1. Despite preoperative treatment, our patients still had somewhat elevated potassium, creatinine and urea concentrations prior to surgery.

In two foals the uroperitoneum was drained before surgery using a sump drain.

Anesthesia

After preanesthetic medication with diazepam at 0.05 mg/kg i.v., anesthesia was induced with ketamine (2 mg/kg i.v). Following endotracheal intubation and positioning in dorsal recumbency on a thick foam pad, each foal was connected to a small animal breathing circuit and anesthesia machine (Stephan GmbH.-Medicinetchnik; Germany) equipped with a precision vaporizer and ventilator. Anesthesia was maintained with 1.1 % halothane in oxygen. Initial oxygen flow rate for the first 20 minutes of anesthesia was 8 l/min. After 20 minutes this was reduced to 6 l/min. Heart rate, blood-gas analyses and invasive (direct) mean blood pressure were monitored during anesthesia. The blood pressure was monitored through catheterisation of the arteria facialis and connection with "Blood Pressure Couplers -EXP HG-02" (Hungary).

The mean blood pressure of foals during anesthesia was 74 mmHg (SD. 15.43).

Surgery

Surgical urinary bladder rupture was repaired according to the usual methods (Hackett, 1984; Adams and Fessler, 2000). A ventral midline skin incision, 15-20 cm long, was made rostral to the prepuce or mammae and continued forward along the midline forming an ellipse around the umbilicus. The abdomen was entered on the midline through the linea alba rostral to the umbilicus and the incision continued caudally around the urachal stump to free the stump from the body wall. The umbilical vein and arteries were ligated and transected and the bladder exposed by traction on the umbilical remnants.

The urinary bladder was then examined in order to determine the location and size of the tear.

In our 4 foals the ruptures were treated at the dorsal (3 cases) or craniodorsal aspect (1 cases) of the urinary bladder. The bladder was stabilized with cystic force and closed with 3.5 Dexon-suture in a Cushing pattern for the first layer and a continuous Lembert pattern for the second layer. The sutures did not penetrate the mucosa of the bladder. After the tear had been repaired, the urachus was transected and removed and the bladder was closed.

The urinary bladder was distended with saline solution to check for any leakage. The peritoneal cavity was leveraged with sterile physiological 0.9% NaCl-solution in order to remove residual urine. In two foals a soft urinary catheter was placed in the bladder for 24 to 48 hours to facilitate drainage. Bactericidal antibiotic therapy (ampicillin 30 mg/kg body weight i.m. every 12 hours) was given to all foals.

Three foals survived the operation as well as the postoperative treatment. These foals responded well to treatment and were clinically normal on follow-up examination after 2 months.

A further foal with a ruptured urinary bladder and severe hyperkalemia (potassium concentration of 7.59 mEq/L) went into heart arrhythmia during anesthesia and died during the operation. Prior to operation this foal had received only short preoperative management (i.e. treated without glucose and insulin).

DISCUSSION

Rupture of the urinary bladder occurs sporadically in foals. The reported frequency in foals ranges from 0.2-2.5 % (Hackett, 1984). Ruptured bladder causes chemical peritonitis. Clinical signs are often nonspecific, making early diagnosis difficult. In our investigation, affected foals had a distended abdomen, colic, hypovolemia, electrolyte alterations, central nervous system depression and metabolic acidosis.

According to our observations, the laboratory analyses (hyponatremia, hypochloremia, hyperkalemia, increased concentration of creatinine and urea) correlated well with the diagnosis of ruptured bladder. Elevation of serum creatinine concentration is more consistent than blood urea in foals with bladder rupture (Fenger, 1998). Hypochloremia develops in long-standing acidosis with renal exchange of chloride ions for bicarbonate. It is well known, that serum electrolyte changes become more evident as uroperitoneum progresses (Gentzky and Jagemoser, 1985; Stickle et al., 1990, Edwards, 1995).

Generally, the combination of clinical signs and laboratory analyses is highly suggestive of ruptured bladder. However, during early stages of disease these serum abnormalities may not be present. If the diagnosis is in doubt, abdominocentesis can be used to confirm uroperitoneum. A ratio of peritoneal fluid creatinine to serum creatinine greater than 2:1 confirms the presence of urine in the abdomen (Gentzky and Jagemoser, 1985; Morley and Desnoyers, 1992).

In some animals tears in the dorsal bladder wall can be visualized with ultrasound (Richardson, 1985). The primary ultrasound finding in our investigation was the large volume of free fluid in the abdomen.

Other diagnostic methods can be used. For example, contrast cystography through to the instillation of sterile dye solution of fluorescein or methylene blue into the bladder via a catheter and subsequent detection of the dye in the abdominal fluid confirms a tear in the bladder (Hackett, 1984). Cystoscopy of the bladder in female foals is also possible with small-diameter endoscopes and is useful in confirming bladder ruptures (Fenger, 1985). Radiography of the abdomen may also reveal free fluid in the abdomen (Ronney, 1971).

Preoperative medical therapy should focus on stabilizing the patient for anesthesia and surgery in order to reduce the risk of perioperative complications. It is well known, that the surgical repair of the ruptured bladder is not an emergency. The correction of metabolic disturbances, however, is an emergency. In particular hyperkalemia may cause life-threatening cardiac arrhythmia. Normotonic physiologic saline is indicated for hyponatremia, hypochloremia and hyperkalemia. The infusion fluid should not contain potassium, i.e. Ringer-fluid infusion is contraindicated. In addition, to reduce the potassium serum concentration, one can also give a 5% glucose infusion (or dextrose) and insulin s.c. This increases

potassium movement from the serum into the cells (Richardson, 1985). In our preoperative management, 3 foals were treated in this way. One foal with a bladder rupture was not treated with glucose and insulin, and therefore still had high potassium levels. It went into cardiac arrhythmia and died.

The restoration of hydration status and relief of severe abdominal distention before surgery also helps in decreasing the anesthetic risk to the animal. Rapid removal of large volumes of fluid (via drainage through a percutaneous catheter) without prior re-establishment of the normal circulating volume, should be avoided, as this induces abrupt changes in the cardiovascular status of the animal. Peritoneal dialysis can also be used to correct electrolyte disturbances before surgery in foals (Kritchevsky, 1984).

Therapy should be directed toward the pathophysiologic events that occur during bladder rupture and also toward preventing or alleviating the complications. All foals should also be examined for concurrent medical problems such as septicemia, failure in the passive transfer of immunoglobulins, pneumonia and enteritis (Adams et al., 1988). These problems should be treated before proceeding with surgical correction of the ruptured bladder.

Special attention during treatment of these foals should be given to the anesthesia. Foals are at high risk during anesthesia, especially with respect to hypoventilation, hypotension and cardiac arrhythmia. Foals less than 3 months of age respond differently to anesthesia and surgery than do adult horses (Trim, 1990). Xylazine (alfa-2-adrenergic agonist) should be avoided in foals less than 2 weeks old, because of its depressive effect on cardiopulmonary function. However, extremely small doses (0.15 to 0.2 mg/kg i.v.), together with diazepam may be used for preanesthetic sedation before induction of anesthesia with halothane or ketamine (Carter et al., 1990). Induction of anesthesia may be also accomplished with halothane without prior sedation via the anesthetic mask. Healthy foals may be safely anesthetized with either isoflurane or halothane, but isoflurane is probably safer in compromised individuals (Steffey et al. 1990).

Monitoring ECG and blood pressure allows early and immediate treatment of potentially life-threatening cardiovascular changes. Advanced AV-block may develop and can be successfully reversed through the infusion of dopamine at 6-7 $\mu\text{g}/\text{kg}/\text{min}$ (Whitton and Trim, 1985). In foals the myocardial contractility and baroreceptor function is decreased, so cardiac output is largely governed by heart rate. Consequently, bradycardia (i.e. dependent on potassium concentration) can produce significant changes in cardiovascular function.

The postoperative period focuses on preventing and treating secondary complications. Optimal therapy of the ruptured bladder includes systemic antibiotic treatment, pain control and general systemic support. The therapeutic regimen should include systemic antibiotic treatment, assurance of adequate serum immunoglobulin concentrations, maintenance of homeostasis (i.e. nutrition, acid-base balance, fluids, electrolytes) and anti-inflammatory drugs. Initially broad-spectrum bactericidal antibiotic therapy should be given due to the relative inefficiency of the immunological system of neonates. Systemically administered nonsteroidal anti-inflammatory drugs such as flunixin meglumine relieve pain and diminish the adverse effects of inflammation. Since nonsteroidal, anti-inflammatory drugs have been incriminated as a contributing factor in the gastric ulcer syndrome of foals, long therapy at high doses should be avoided.

The prognosis for foals with uncomplicated bladder ruptures is good, but the prognosis after correction of bladder rupture also depends on its location, magnitude and duration prior to surgical intervention.

REFERENCES

1. Adams SB, Fessler JF, 2000. Atlas of Equine Surgery, WB. Saunders Company, Philadelphia.
2. Adams R, Koterba AM, Brown MP, 1988. Exploratory celiotomy for gastrointestinal disease in neonatal foals: A review of 20 cases. *Equine Vet J*, 20, 54.
3. Carter SW, Robertson SA, Steel CJ, 1990. Cardiopulmonary effects of xylazine sedation in the foal. *Equine Vet J*, 22, 384.
4. Edwards RB, 1995. Laparoscopic repair of bladder rupture in a foal. *Vet Sur.*, 24, 60-63.
5. Fenger CK, 1998. Neonatal and Perinatal Diseases. In *Equine Internal Medicine*, ed. Reed S, Saunders Company, Philadelphia, 938-956.
6. Gentzky RM, Jagemoser WA, 1985. Physical and clinical pathological findings associated with experimentally induced rupture of the equine urinary bladder. *Can Vet, J*, 26, 391-395.
7. Gibson KT, 1992. Conservative management of uroperitoneum in a gelding. *JAVMA*, 200, 1692-1694.
8. Hackett RP, 1984. Rupture of the urinary bladder in neonatal foals. *Compend Cont Educ Pract Vet*, 6, S488-S492.
9. Kritchevsky JE, 1984. Peritoneal dialysis for presurgical management of ruptured bladder in a foal. *JAVMA*, 185, 81-82.
10. Morley PS, Desnoyers M, 1992. Diagnosis of ruptured urinary bladder in a foal by the identification of calcium carbonate crystals in the peritoneal fluid. *JAVMA*, 200, 1515-1517.
11. Ronney JR 1971. Rupture of urinary bladder in the foal. *Vet. Pathol.*, 8, 445.
12. Richardson D.W. 1985. Urogenital problems in the neonatal foal. *Vet Clin North Am Equine Pract*, 1, 179.
13. Steffey EP, Willits N, Wong P. 1990. Clinical investigation of halothane and isoflurane for induction and maintenance of foal anesthesia. *J Vet Pharmacol Ther*, 14, 300.
14. Stickle RL, Wilcock BP, Huseman JL 1975. Multiple ureteral defects in a Belgian foal. *Vet Med Small Anim. Clin.*, 70, 819.
15. Trim CM, 1990. General Anesthesia. in *Equine Medicine and Surgery ed. Colahan. Fifth Ed. Mosby, St. Louis.* 280.
16. Whitton DL, Trim CM, 1985. Use of dopamine hydrochloride during heart block in four foals. *JAVMA*, 187, 1357-1361.

**DIJAGNOZA, ANESTEZIJA I OPERATIVNI ZAHVAT KOD RUPTURE MOKRAĆNE BEŠIKE
NOVOROĐENE ŽDREBADI**

KOVAČ M, TOT H, SCHÜTTERT B, TAMBUR Z, KULIŠIĆ Z. i MIHAILOVIĆ M.

SADRŽAJ

Ova studija opsuje dijagnostikovanje, anesteziju i operativni tretman pri rupturi mokraćne bešike novorođene ždrebadi. Dijagnoza je zasnovana na istoriji bolesti, kliničkim simptomima, promenama u serumu ustanovljenim biohemijskim analizama (hiponatrijemija, hipokalijemija, hipohloremija, metabolička acidoza sa porastom nivoa serumskog kreatinina i ureje), abdominocintezi, ultrazvuku i elektrokardiografiji.

Kao što poremećaji elektrolita i acido-bazne ravnoteže mogu dovesti do pojave srčane aritmije u toku opšte anestezije, hirurški tretman rupture bešike kod novorođene ždrebadi može biti primenjen kada je stabilizovano zdravstveno stanje životinje. Ovo uključuje infuziju fiziološkog rastvora, 5% glukoze sa insulinom (0,1 U/kg) i 1,4% Na-bikarbonat.