

UMass Chan Medical School

eScholarship@UMassChan

COVID-19 Publications by UMMS Authors

2020-10-01

American Neurotology Society, American Otological Society, and American Academy of Otolaryngology - Head and Neck Foundation Guide to Enhance Otologic and Neurotologic Care During the COVID-19 Pandemic

Elliott D. Kozin
Harvard Medical School

Et al.

Let us know how access to this document benefits you.

Follow this and additional works at: <https://escholarship.umassmed.edu/covid19>



Part of the [Health Services Administration Commons](#), [Infectious Disease Commons](#), [Otolaryngology Commons](#), [Otorhinolaryngologic Diseases Commons](#), [Patient Safety Commons](#), and the [Virus Diseases Commons](#)

Repository Citation

Kozin ED, Remenschneider AK, Blevins NH, Jan TA, Quesnel AM, Chari DA, Kesser BW, Franck KH, Marchioni D, Barker FG, Carter B, Jackler RK, Welling D, Lee DJ. (2020). American Neurotology Society, American Otological Society, and American Academy of Otolaryngology - Head and Neck Foundation Guide to Enhance Otologic and Neurotologic Care During the COVID-19 Pandemic. COVID-19 Publications by UMMS Authors. <https://doi.org/10.1097/mao.0000000000002868>. Retrieved from <https://escholarship.umassmed.edu/covid19/51>

Creative Commons License



This work is licensed under a [Creative Commons Attribution-NonCommercial 4.0 License](#)
This material is brought to you by eScholarship@UMassChan. It has been accepted for inclusion in COVID-19 Publications by UMMS Authors by an authorized administrator of eScholarship@UMassChan. For more information, please contact Lisa.Palmer@umassmed.edu.

American Neurotology Society Position Statement on Management of Otologic and Neurotologic Patients During the COVID-19 Pandemic

Authors: Elliott D. Kozin, MD*^{1,2}, Aaron K. Remenschneider, MD, MPH*^{1,2,3}, Nikolas H. Blevins, MD⁴, Taha A. Jan, MD⁴, Alicia M. Quesnel, MD^{1,2}, Divya A. Chari, MD^{1,2}, Bradley W. Kesser, MD⁵, Kevin H. Franck, PhD^{1,2,6}, Daniele Marchioni, MD⁷, Frederick G. Barker II, MD⁸, Bob Carter, MD, PhD⁸, Robert K. Jackler, MD⁴, D. Bradley Welling, MD, PhD^{1,2}, Daniel J. Lee, MD^{1,2}

*Contributed equally

Affiliations:

¹Department of Otolaryngology, Harvard Medical School, Boston, MA, USA;

²Department of Otolaryngology, Massachusetts Eye and Ear, Boston, MA, USA;

³Department of Otolaryngology, University of Massachusetts Medical School, Worcester, MA, USA;

⁴Department of Otolaryngology, Stanford University School of Medicine, Stanford CA, USA;

⁵Department of Otolaryngology, University of Virginia, Charlottesville, VA, USA;

⁶Department of Audiology, Massachusetts Eye and Ear, Boston, MA, USA;

⁷Otolaryngology Department, University Hospital of Verona, Verona, Italy;

⁸Department of Neurosurgery, Massachusetts General Hospital / Harvard Medical School Boston, MA, USA.

Journal: Accepted for publication in *Otology & Neurotology*, April 16th, 2020. *In press.*

Conflicts of Interest: None

Financial Disclosures: None

Keywords: Coronavirus, COVID, otolaryngology, ENT, otology, neurotology, mastoidectomy, craniotomy, aerosolization, endoscopic ear surgery, exoscope, protective personal equipment, PPE, FFP, PAPR, N95

Corresponding Author:

Daniel J. Lee

243 Charles Street

Boston, MA 02114

Daniel_Lee@meei.harvard.edu

ABSTRACT

The aims of this position statement are to provide guidance during the COVID-19 pandemic on 1) management of otologic and neurotologic patients in the office and operating room settings, and 2) optimal use of personal protective equipment. These recommendations are based on peer reviewed published articles, United States and international hospital policies on COVID-19, expert opinion, and recent rapid communications from Stanford University, Pennsylvania State University, the British Society of Otology, and the University of Antwerp. Access to otologic and neurotologic care during and after the COVID-19 pandemic is dependent upon adequate protection of providers within our subspecialty. Otolologists and associated staff are at high risk for COVID-19 disease transmission based on close contact with mucosal surfaces of the upper aerodigestive tract during diagnostic evaluation and therapeutic procedures. Given the risk of COVID-19 transmission, the need for physical (social) distancing, and conservation of essential personal protective equipment (PPE), all non-urgent clinic visits and elective procedures should be postponed. For urgent clinical and operative cases, risk assessment with knowledge and utilization of effective PPE is essential to reduce inadvertent infection of providers, staff, and patients.

INTRODUCTION

In 2019, a novel enveloped RNA betacoronavirus was identified in Wuhan, China, and later named severe acute respiratory syndrome coronavirus 2 (SARS-CoV-2) by the World Health Organization¹. The rapid global spread of coronavirus disease of 2019 (COVID-19) has been well documented in the lay press and medical literature. As of 10 April 2020, there are over 480,000 cases and 18,000 deaths attributable to COVID-19 in the United States alone². Particularly troublesome about the COVID-19 outbreak is the significant risk of disease transmission among medical providers³⁻⁸. There are several peer-reviewed and non-peer reviewed reports that highlight the risk of COVID-19 transmission from direct contact, droplets, and aerosolization of respiratory tract mucosa⁹⁻¹². Otolaryngologists and associated staff are believed to be at high risk for COVID-19 disease transmission based on their close contact with the upper aerodigestive tract during diagnostic evaluation and therapeutic procedures of the head and neck¹³⁻¹⁷. Importantly, there is evidence that individuals who are minimally symptomatic or asymptomatic may test positive and carry high viral loads¹⁸⁻²⁰. Currently, it is not clear to what degree these individuals may transmit COVID-19 to others. Thus, there is an urgent need to address and mitigate the risk of COVID-19 transmission for all patients, providers, and staff in otolaryngologic practices.

RELEVANCE OF COVID-19 TO OTOTOLOGY AND NEUROTOLOGY

There is a paucity of data on the risk of COVID-19 transmission during otologic and neurotologic practices and procedures. Consequently, guidance on case selection and PPE use is lacking. While other coronaviruses have been isolated from the middle ear in patients with otitis media with effusion,²¹⁻²³ there is no data on whether the respiratory mucosa lining the middle ear and mastoid air cell system is infected by SARS-CoV-2. However, given that the upper airway mucosa, including nasopharynx are involved, especially in the early stages of

SARS-CoV-2 infection, it is likely that the mucosal linings of the Eustachian tube, middle ear, and mastoid air cells may also be affected²⁴.

Similar to other aerosol-generating procedures, such as endonasal procedures^{25,26}, aerosolization of bone, mucosa and tympanic fluid has been shown to occur during mastoid and skull base drilling²⁷⁻³⁰. Powered and heat-generating instrumentation, such as otologic drills, ultrasonic dissectors, electrocautery, and lasers, may further aerosolize infectious particles³¹⁻³⁸. The spread of other viruses, including Ebola, SARS-CoV, Middle East respiratory syndrome coronavirus (MERS), has been associated with aerosol-generating medical procedures^{36,39-42}. Taken together, there may be a risk of viral transmission when performing otologic and neurotologic procedures in the clinic and operating room in patients infected with SARS-CoV-2.

The following position statement supported by the American Neurotology Society provides guidance for otologists/neurotologists involved in the care of patients with otologic and neurotologic disease during the COVID-19 pandemic. These recommendations are based on available published literature, national and international hospital policies on COVID-19, expert opinion as well as recent rapid communications by Stanford University, Pennsylvania State University, the British Society of Otolaryngology, and others^{17,24,43,44}. As our current understanding of COVID-19 is evolving on a weekly basis, diagnostic and treatment algorithms will change during this crisis. Ultimately, physicians should provide management options based on individual patient factors, local hospital policies and resources, and available PPE.

COVID-19 RISK ASSESSMENT IN OTOLOGIC AND NEUROTOLOGIC PRACTICES

A multitude of factors must be incorporated into the assessment of a patient's risk for having COVID-19, including 1) formal COVID-19 testing, 2) COVID-19 symptomatology 3) history of contact with COVID-19 positive patients, and 4) travel to high risk locations. With the increased availability of COVID-19 testing, many states and hospitals are routinely screening patients. Surgeons should be aware of the limited sensitivity/specificity of current COVID-19

testing, especially in infected but asymptomatic patients⁴⁵⁻⁴⁸. Some US-based centers advocate for two independent rounds of testing performed 24 hours apart prior to any non-emergent procedure. Other centers have an “expiration date” on testing due to the fact that a patient may become COVID-19 positive after testing is complete. Further, emerging studies from Europe and Asia have indicated multi-modality testing, such as the inclusion of chest imaging as part of the COVID-19 screening pathway⁴⁹⁻⁵³. The importance of symptoms, history of contact with COVID-19, and travel is controversial given findings of asymptomatic COVID positive patients and widespread community acquisition of COVID-19¹⁸⁻²⁰. Nevertheless, clinical and travel history remain important to identify high risk patients.

Based on the changing landscape of COVID-19 transmission, including infectious capacity of asymptomatic patients, as well as evolving COVID-19 testing paradigms, we advocate stratifying patients into two categories for the purposes of risk stratification:

- **High risk patients**
 - Positive COVID-19 test result
 - Symptomatic patients⁵⁴, including person under investigation (PUI) for COVID-19
 - Inability to test and evaluate symptoms for COVID-19
- **Intermediate risk patients**
 - Negative COVID-19 test result
 - Asymptomatic patient with no COVID-19 testing

In high risk patients, management of all non-emergent otologic and neurotologic conditions should be postponed until the patient has recovered by symptom resolution and testing. In intermediate risk patients, clinicians should proceed with evaluation and treatment of patients based upon their own judgement and clinic/hospital regulations. Notably, a low risk category is purposely omitted given the limitations and variability of current COVID-19 testing in the United States, which may be in part due to multiple factors, such as testing modality, variation in swabbing technique, timing of testing, and viral load of testing location (e.g. nasopharynx vs.

sputum)^{47,55,56}. As COVID-19 testing evolves, these categories of patients will likely change with the categorization of low risk patients. If there is any question about veracity of testing (especially in the case of a symptomatic patient), patients should be managed as high risk.

OTOLOGIC AND NEUROLOGIC OFFICE-BASED VISITS AND PROCEDURES

The risk of COVID-19 transmission in the office setting is based on several factors, including routine examination of the head and neck, instrumentation of mucosal surfaces, and viral load of the upper airway in COVID-19 positive patients^{9,57,58}. Given the risk of COVID-19 transmission, the need for physical (social) distancing, and conservation of essential PPE, all non-urgent visits should be postponed. Elective visits may resume upon consensus between local/state officials and medical professionals. In the meantime, documentation of the reasons for delay and ongoing discussions with patient and family are essential. Clinicians may consider establishing a mechanism for individual case review as needed until elective visits are again permitted.

Patient Flow and Personal Protective Equipment

All patients should be screened by phone or before entering the office to prevent transmission to fellow patients, clinical office staff, and providers. Waiting room seating arrangements may be adjusted to increase distance between chairs. Schedulers should consider staggering appointments to minimize patient crowding. Multiple visitors with adult patients should be discouraged or limited to one accompanying adult. Clinics should maintain universal precautions for all patients and associated visitors. Patients should cover their mouths and noses in the clinic setting, such as with a homemade mask or surgical mask, as is now the recommendation by state and federal agencies. Patients may be given masks upon entering the clinic, if supplies are available.

Office Triage of Otologic and Neurotologic Diagnoses

The following recommendations provide examples of diagnoses for which in-person clinic visits should be considered. The list is not meant to be exhaustive. The experience and discretion of the otologist / neurotologist may determine reasons for such visits to be done in a different timeframe.

Diagnoses Requiring an “Urgent” Clinic Visit

- Unilateral sudden sensorineural hearing loss
- Bilateral sudden sensorineural hearing loss
- Ménière's disease with intractable vertigo and/or drop attacks
- Acute pediatric or adult otitis media refractory to systemic / topical antibiotics
- Auricular hematoma
- Cerebrospinal fluid leak
- Chronic ear disease and new onset facial nerve paralysis, intractable otalgia or suspicion of intracranial complication (e.g. sigmoid sinus thrombosis, epidural or brain abscess)
- Lateral skull base neoplasm (e.g. schwannoma and meningioma) with significant new growth, brainstem compression, hemorrhage, or acute neurologic deterioration
- Acute facial paralysis, if features atypical for Bell's Palsy
- Intractable otalgia associated with otitis externa unresponsive to topical and systemic antibiotics
- Otogenic skull base osteomyelitis
- Essential postoperative care (e.g. packing or suture removal, if cannot be done locally)

Diagnoses that May be Delayed up to 3 months

- Chronic otitis media with progressive symptoms
- Uncomplicated cholesteatoma

Diagnoses that May be Delayed Greater than 6 months

- Chronic/dry tympanic membrane perforation
- Chronic hearing loss
- Chronic dizziness
- Otosclerosis
- Routine chronic ear follow up
- Tinnitus (Consider telemedicine visit)

Evaluation of High Risk Patients in Clinic

In the case of COVID-19 high risk patients, providers and associated staff should wear an N95 or filtering face piece 2 (FFP2) mask, face shield, gown and gloves, as well as hair and shoe covers (Table 1). Occlusive goggles should be considered if face shields are incompatible with use of the binocular microscope. Powered air purifying respirator (PAPR) may also be used if the provider has an inadequate N95 / FFP2 fit or there is considerable risk for aerosolization during an in-office otologic procedure. PPE should be available for all clinic staff involved with patient care.

Otologic office procedures should be performed with as few staff present as possible, ideally by the practitioner alone and in a room dedicated for this purpose. While the risk for aerosolization during a standard otologic exam is likely to be lower than nasal or oral cavity exams, *otologists and neurotologists are well aware of the propensity for ear canal instrumentation to elicit coughing due to stimulation of Arnold's nerve cough reflex.* This could

produce an unexpected plume of potentially infectious droplets. Aerosolization may also occur through instrumentation of infected tissue, including suction of middle ear effusions. Thus, instrumentation of the ear may be considered potentially aerosol-generating.

Evaluation of Intermediate Risk Patients in Clinic

Clinicians should be up to date on definitions of “COVID-19 negative” test status as there are high false negative rates on certain types of testing⁴⁵⁻⁴⁸. If there is any question regarding COVID-19 results, full precautions, as described above, should be used. In intermediate risk patients, clinicians should use their judgement on the implementation of PPE (Table 1). At a minimum, the provider should wear exam gloves and surgical mask with standard hand washing before and after the exam. This may provide protection if the patient had a false negative test or under the scenario that the provider is COVID-19 positive, but asymptomatic. While intermediate risk patients may reasonably have a medical interview with a surgical mask, given the limitations of current testing, close proximity to patients during physical exams, and potential for aerosolization during in-office otologic procedures, clinicians should consider “upstaging” to high risk PPE.

Special clinic considerations

1. Designate a single room, microscope, and audiology booth for known COVID-19 positive patients and use an approved cleaning protocol after each use.
2. Gloves and gown should be used for microscopic examination of the supine patient as inadvertent contact between the examiner’s arm and the patient is likely.
3. External auditory canal and mastoid bowl debridement should be trialed with non-suction instrumentation, such as cerumen loop and alligator forceps, if possible. Fluids can be cleaned with cotton wicks instead of suction.

4. If suctioning is indicated, the suction control hole should be taped closed to reduce aerosolization through this opening.
5. Similar to all otologic instruments, suction tubing should be changed after every patient.
6. Nasopharyngoscopy and other instrumentation of the upper airway should be avoided if possible, as this is a high risk procedure^{9,26} If an upper airway procedure is absolutely necessary, then PPE including either N95 respirator with face shield or PAPR, as well as gown, gloves and hair covering should be used, and non-aerosolizing techniques for nasal decongestion and anesthesia should be considered.
7. Many clinics stock compounded powdered medications for treating the wet mastoid bowl. The use of an insufflator in clinic would also risk aerosolizing potentially infectious droplets. As an alternative, the patient can be given or prescribed a bulb insufflator to use at home with proper instruction. Painting the cavity using a cotton swab and a long-acting agent like gentian violet may be a viable interim alternative.

Sudden Sensorineural Hearing Loss and Bell's Palsy

For idiopathic sudden sensorineural hearing loss, given the unknown risk of systemic steroids with COVID-19 outcomes, clinicians may consider intratympanic (IT) steroid therapy, which has non-inferior outcomes⁵⁹. Clinicians should weigh the immunosuppressive risk of systemic steroids against the repeat visits and instrumentation necessary for IT steroid injections. Treatment of Bell's Palsy with oral steroids should be decided in the context of patient history, including COVID-19 status, and potential for exposures in the home or work environment.

Audiometry

In times of purposefully reducing elective in-person visits during the COVID-19 pandemic, clinicians may consider the use of self-directed hearing screeners (e.g. smart phone or tablet

applications) that estimate air-conduction thresholds. At home hearing screens may identify patients who may not need a comprehensive audiometric work-up because they do not have hearing loss or their known hearing loss is stable⁶⁰. Qualities of reliable hearing screening include platforms that include:

- Continuously monitor ambient noise levels to either halt the self-test when noise levels are too high or mark the data from the test as potentially impacted by ambient noise
- Continuously monitor patient attention during testing and report the reliability of threshold data
- Use transducers (headphones or earphones) that have quantified and reliable sound output across tested frequencies and intensities
- Either provide effective masking or limit results that could be affected by sounds crossing over from a transducer on one ear to the other
- Have user experiences that engage patients throughout the length of the hearing tests

Commercial platforms that meet these qualities include Shoebox (Toronto, CA), Mimi (Berlin DE), HearX (Pretoria SA) and others. These systems vary in the degree to which they provide comprehensive reports that can be imported into medical records. Screen-captured images that may be inserted into physician notes can serve as documentation.

Telemedicine Technology and Limitations

Consideration should be given to the implementation of telemedicine visits wherever feasible. New patient histories and established patient progress can be assessed via telemedicine. High risk patients with established diagnoses can be monitored and in person visits can be arranged when indicated. As the practice of telemedicine is new to many otologists / neurotologists, this trial period will determine how applicable the technology is to our practice. Specifically, hearing impaired patients may find remote clinical assessment particularly challenging⁶¹ and may benefit from live closed captioning technology during the virtual

encounter. Further, providers should be familiar with the regulations governing the practice of telemedicine, including necessary documentation and billing, that vary institutionally and from state to state.

OPERATING ROOM GUIDANCE AND PERSONAL PROTECTIVE EQUIPMENT

Given risk of COVID-19 transmission, need for physical distancing, and demands for conservation of essential PPE, all elective otologic/neurotologic procedures should be postponed. The following list is intended to provide examples of diagnoses for which surgical intervention should be considered in the defined time range. The list is not meant to be exhaustive, and the experience and discretion of the otologist / neurotologist may determine reasons for such cases to be done in a different timeframe.

Diagnoses Necessitating Emergent Operative Management

- Coalescent mastoiditis
- Otogenic sigmoid sinus thrombosis, epidural abscess, brain abscess
- Postoperative abscess not responsive to systemic antibiotics
- Cerebellopontine angle tumor with rapid neurological deterioration and/or threatened brainstem herniation

Diagnoses Necessitating Urgent Operative Management within 1-4 weeks

- Chronic ear disease associated with acute facial nerve paresis or paralysis
- Temporal bone malignancy
- Impending cochlear ossification (e.g. from bacterial meningitis) requiring cochlear implant surgery
- Explantation of grossly infected auditory implant not responding to conservative therapy

- Temporal bone trauma with vascular or severe facial nerve injury
- Cerebrospinal fluid leak associated with lateral skull base defect – timing of surgery may depend on etiology and chronicity of the CSF leak

Diagnoses Necessitating Operative Management within 3 months

- Cholesteatoma with symptomatic otic capsule erosion (e.g. sound- or pressure-evoked vertigo)
- Cholesteatoma with active infection not responding to ototopical and oral antibiotics
- Prelingual deafness in an infant / cochlear implantation
- Pediatric and adult recurrent otitis media, chronic serous otitis / ventilation tubes
- Incapacitating vertigo resulting in risk of injury from falling (e.g. drop attacks)

Diagnoses that Operating Room Management Can Potentially be Delayed 6 or More Months

- Tympanic membrane perforation or retraction
- Chronic Eustachian tube dysfunction patient / transnasal Eustachian tube balloon dilation (high risk procedure given the potential for viral load in the nasopharynx^{9,26})
- Uncomplicated chronic ear disease (e.g. attic cholesteatoma)
- Otosclerosis / stapedectomy
- Conductive hearing loss / bone conduction implantation
- Adult bilateral severe to profound hearing loss / cochlear implantation
- Pediatric or adult single-sided severe to profound hearing loss / cochlear implantation
- Pediatric post-lingual severe to profound hearing loss / cochlear implantation
- Superior canal dehiscence syndrome
- Growing cerebellopontine angle tumors without significant brainstem compression or intracranial sequelae
- Uncomplicated lateral skull base encephalocele

Pre-Operative Risk Assessment

Patients with urgent otologic or neurotologic conditions should be tested for SARS CoV-2 prior to any planned procedure to assist in stratifying risk category and use of appropriate PPE. Surgery on patients testing positive for SARS CoV-2-19 should be considered only for imminently life-threatening conditions. Similar to any other co-morbidity, surgeons should also be aware of how the COVID positivity may influence overall surgical risk, including general anesthesia and surgery. Oxygen requirements and complexity of respiratory pathology should be incorporated into surgical decision making and discussion with the anesthesia team, Further, as in the clinic-setting, COVID-19 transmission in the operating room may be associated with instrumentation of mucosal surfaces, (e.g. mastoid and middle ear) and the known high viral load of the upper airway⁹. Powered instrumentation, such as high-speed drills, are known to result in aerosolization of particles and, potentially, virus^{27,31-38}. Indeed, otologic and skull base surgery are likely as hazardous (or possibly more so given longer exposure times) to surgical team members as airway procedures. Thus, the appropriate level of PPE should be provided.

Personal Protective Equipment for High Risk Patients in the Operating Room

In the case of a high risk patient, we recommend the use of PPE that includes an N95 / FFP2 respirator with full face shield for all members of the operating room team⁶² (Table 2 and Table 3). Theoretically, an N95 / FFP2 with a face shield or airtight goggles should form a complete barrier to any aerosolized particles; *however, protection depends upon a 'perfect fit' for the surgeon and associated personnel*. Additional PPE should include waterproof gown and gloves, as well as hair and shoe covers (Table 2). Given high risk nature of otolaryngologic procedures, surgeons must advocate for necessary equipment for *all* operating room staff, including the scrub technicians, nurses and anesthesia team.

The use of a powered air purifying respirator (PAPR) with N95 mask⁶² may provide critical protection in the case of ill-fitting N95 / FFP2 respirator and potentially wide distribution of aerosolized infectious particulate due to powered instrumentation. Providers should be aware that bony dissection with powered instruments may create a plume of particulate that has been documented in otology and other fields, such as orthopedic surgery^{25,27-30,63}. A plume of bone dust and associated soft tissue may make a simple face-shield inadequate during otologic drilling although additional research is needed on this point. PAPR devices are diverse and may consist of a hood alone, a hood and upper body suit or an entire body suit with ventilation. All PAPRs involve air filtration through the hood and are cumbersome and unfamiliar to most otologists and neurotologists. Therefore, an equipment in-service covering both donning and doffing techniques should occur long before emergent surgical cases necessitate their use. An understanding of local PAPR models, coverage extent and availability is essential. *While hospitals may have limited access to certain equipment, such as PAPR, use of PPE should be dictated by patient and provider safety, not equipment availability.* We acknowledge that the highest level of PPE may not always be available in every practice setting. Clinicians should consider transfer of COVID-19 positive patients for emergent surgery to centers with necessary PPE. Last, it is incumbent upon all surgical staff to sincerely commit to learn the appropriate donning and doffing of advanced PPE, as uninformed use alone may lead to contamination and unintended infection⁶⁴⁻⁶⁷.

Intermediate Risk Patients in the Operating Room

Given the limited reliability of COVID-19 testing results, clinicians should use their clinical judgement on the implementation of PPE for intermediate risk patients. At a minimum, the provider should wear standard surgical PPE, including surgical mask, face shield, waterproof gown and gloves, as well as hair and shoe covers (Table 2). As discussed above, clinicians should be up to date on definitions of “COVID-19 negative” status, which are often

institution dependent. If there is any question regarding formal COVID-19 results, full precautions, as described for high risk patients above, should be used.

Special Surgical Considerations in Undergoing Otologic Procedures

1. Surgeons should consider performing a “PPE timeout” as part of the standard operative checklist. There should be a discussion regarding patient COVID-19 testing status, risk of possible transmission (e.g. droplets) and availability of appropriate PPE equipment for OR staff. A “PPE timeout” may help to ensure that the entire operative team is coordinated regarding possible transmission risks and necessary precautions.
2. A binocular surgical microscope can be challenging to use with PAPR or face shields (Fig.1A) and alternatives, based on surgeon discretion, may include:
 - a. **Goggles** rather than a face shield with N95 and complete head, face and neck protection during microscopic-assisted dissection. (Swim goggles may be considered if surgical goggles are not available.)
 - b. **Surgical loupes** for magnification under PPE
 - c. **Rigid endoscopes** may be utilized as an alternative to traditional microscopy during *transcanal* cases^{68,69} for improved visualization when using a face shield or PAPR. Heads-up surgery (the surgeon’s head is positioned up and looking forward) utilizes a Hopkins rod telescope or exoscope and high-resolution video monitor rather than the binocular microscope⁷⁰⁻⁷³. Endoscopic techniques may also decrease the need for powered instrumentation.
 - d. **Extracorporeal digital microscope (exoscope)** can be utilized as an alternative to the microscope during mastoidectomy or craniotomy approaches for heads-up dissection and improved visualization⁷² when using a face shield or PAPR (Fig. 2)
3. A barrier/drape should be hung between the surgical field and anesthesia.

4. A sterile barrier curtain (“microscope tent”) may be created around the surgical field and incorporated with the microscope (or exoscope) drape to reduce dispersion of debris during drilling (Fig. 1). One may consider running a dedicated suction through the tented area. There are various permutations that could be trialed⁷⁴.
5. When possible, the use of manual approaches, such as curettage or use of a manual perforator, should be considered, but only if the surgeon is facile with these techniques. One could also consider using a staged approach, such as decompression with curettage for acute mastoiditis, and then a second procedure for traditional mastoidectomy.
6. Aerosolization of biological materials may occur during microsuction. Consider occlusion of the microsuction control hole (using sterile occlusive tape and/or bone wax) during dissection to reduce aerosolization of surgical debris. The type of suction, such as open or closed suction loops, should be discussed with operating room staff to minimize possible exposure.
7. Given that aerosolization of viable pathogens (including virus) may also occur during electrocautery and generation of surgical smoke, consideration should be given to using additional local vasoconstriction and cold techniques during soft tissue dissection³¹⁻³⁵.
8. For urgent lateral skull base tumor cases, a retrosigmoid or middle fossa craniotomy (instead of a translabyrinthine craniotomy) should be chosen, if possible, to reduce bony drilling and exposure to middle ear mucosa.
9. Procedures should be carried out by the most experienced surgeons to mitigate risk to staff and ensure minimal OR time. Only senior trainees who are essential towards completion of these cases should be allowed in the room.
10. All non-anesthesia providers, e.g. surgical staff, should remain outside the operating room during endotracheal intubation and extubation to avoid exposure to upper airway aerosols. Operating in a negative pressure room is ideal, if available. Team members

should consider waiting outside the OR for equivalent time for air exchange to occur following intubation.

11. Other equipment that may cause additional distribution of aerosolized particles (e.g. air-powered warming blankets and portable suction) may be minimized.

Future Considerations

In the near future, we must consider: 1) methods of triaging delayed clinic visits and operating room cases, 2) timing of clinic re-opening for elective conditions and 3) “Low Risk” stratification following the incorporation of next generation COVID-19 testing (e.g. serum antibody testing). For example, otologists / neurotologists will need to develop algorithms on how to manage patients who have ‘recovered’ from COVID-19, if evidence emerges to suggest they are protected against subsequent COVID-19 reinfection. Furthermore, “low risk” patient groups should include individuals residing in areas where the virus is no longer endemic. At the current time, adequate data for specific recommendations on these subjects are still lacking.

SUMMARY

There is good reason to believe that the mucosa of the Eustachian tube, middle ear and mastoid can shed viral particles in a patient with COVID-19 infection. Aerosols created by manipulations of the middle ear or mastoid may present a significant risk for exposure of healthcare workers to COVID-19. The highly infectious nature of this virus therefore demands that otologic surgeons delay all but the most urgent procedures until public health authorities indicate that sufficient mitigation of the pandemic has been achieved. Otologists / neurotologists should insist on maximal PPE when operating in the middle ear or mastoid of a COVID-19 infected patient or patient under investigation. As some individuals may be asymptomatic, strong consideration should be given to routine testing for COVID-19 before undertaking middle ear or mastoid procedures. The potential for false negative test results may merit a repeat test

and/or operating under the assumption of infection until we have a better understanding of the biology of the disease. When otologic procedures are undertaken, aerosol spread should be limited as much as possible, and alternatives to the customary use of powered drills and open microsuction should be considered. Ultimately, additional studies are needed to understand the risk of transmission of COVID-19 to otologists and neurotologists during instrumentation or manipulation of the middle ear, mastoid, and lateral skull base. In the absence of quantitative data regarding aerosolization and infectious spread of viral particles, care must be taken to appropriately triage patients and minimize the risk of exposure to health care providers.

Acknowledgements: We would like to thank Dr. John Carey, M.D. for his thoughtful review of the manuscript. We would also like to thank Dr. Renata Knoll, M.D. for her expert support with manuscript preparation.

Table 1: Personal Protective Equipment for Clinic Evaluation without Procedures

COVID Risk	PPE Required
<p>High Risk Patient</p> <ul style="list-style-type: none"> • Positive COVID-19 testing • Person under investigation • Emergent scenario with “unknown” symptoms and / or inability to test 	<ul style="list-style-type: none"> • N95 or FFP2 respirators • Wrap-around eye protection, such as goggles or non-ventilating eye shield • Waterproof gown • Waterproof gloves • Head and shoe covers • Powered Air Purifying Respirator (PAPR) (if improper N95/FFP2 fit) • Coverage for the neck (if not already integral to the other PPE)
<p>Intermediate Risk Patient</p> <ul style="list-style-type: none"> • Negative COVID-19 testing* • Asymptomatic patient with no COVID-19 testing 	<ul style="list-style-type: none"> • Surgical mask for patient • Surgical mask for provider and clinical staff • Waterproof gloves

* Providers should be aware of the sensitivity/specificity of institutional COVID-19 testing as there are reports of high rates of false negative rates with certain testing modalities. Patients may ultimately become low risk pending updates in COVID testing guidelines.

Table 2: Personal Protective Equipment for Procedures in the Clinic and Operating Room

COVID Risk	PPE Required
<p>High Risk Patient</p> <ul style="list-style-type: none"> • Positive COVID-19 testing • Person under investigation • Emergent procedure with “unknown” symptoms and / or inability to test 	<ul style="list-style-type: none"> • Powered Air Purifying Respirator (PAPR) (if available) • N95 or FFP2 respirators • Wrap-around eye protection, such as goggles or non-ventilating eye shield • Waterproof gown • Waterproof gloves • Head and shoe covers • Coverage for the neck (if not already integral to the PAPR)
<p>Intermediate Risk Patient</p> <ul style="list-style-type: none"> • Negative COVID-19 testing* • Asymptomatic patient with no COVID-19 testing 	<ul style="list-style-type: none"> • N95 or FFP2 respirators • Wrap-around eye protection, such as goggles or non-ventilating eye shield • Waterproof gown • Waterproof gloves • Head and shoe cover

* Providers should be aware of the sensitivity/specificity of institutional COVID-19 testing as there are reports of high rates of false negative rates with certain testing modalities. Patients may ultimately become low risk pending updates in COVID testing guidelines.

Table 3: Personal Protective Equipment (PPE) Terms

Term	Definition
<i>Personal Protective Equipment (PPE)</i>	<ul style="list-style-type: none"> • General term to describe equipment worn to minimize transmission of infectious particles
<i>Surgical mask</i>	<ul style="list-style-type: none"> • Used in the operating room and loosely covers the nose and mouth • May protect against droplet transmission • Do not prevent aerosol transmission • Not generally reusable
<i>Respirator</i>	<ul style="list-style-type: none"> • Tight fitting masks that provide a facial seal • Fit testing necessary to guarantee appropriate sizing among available respirators • Generally designed to prevent two-way transmission – filtering both inflow and outflow of air • Protects against both droplets and aerosols • Classified by the federal government based on their percentage of filtration and air leakage • For COVID-19, the most commonly used respirators are N95 / and filtering face piece 2 (FFP 2). (Differences in name come from regulatory agencies in the United States and Europe.) • Generally, N95 and filtering face piece (FFP) 2 masks filter at least 94% of particulate • Respirators are generally reusable with a small degradation in efficacy, if sanitized appropriately
<i>Powered air purifying respirator (PAPR)</i>	<ul style="list-style-type: none"> • Specific type of respirator that actively circulates and filters air around an individual's face • PAPR styles vary and may include a simple hood, a full head and shoulder cover or a body suit. • The most widely available PAPR hoods have minimal protection for the neck and attach loosely beneath the chin, requiring a secondary surgical mask / N95 respirator beneath the hood. • PAPR hood is generally reusable but must be carefully cleaned between uses • PAPR is indicated if available N95/FFP2 respirators do not provide complete seal during individual fit testing

Figures

Figure 1. Binocular surgical microscopy with powered air purifying respirator (PAPR) during left ear mastoid surgery. A. Use of a PAPR with microscopy is possible but can be challenging due to the increased distance to the ocular eyepieces. **B and C.** A “tent” incorporated with the microscope drape can be created to reduce broad dispersion of surgical debris during drilling with ports for both hands and a flap for instruments that can be passed from across the table (A similar approach can also be utilized with an exoscope.) *Photos courtesy of Dr. Hilary Brodie, Dr. Rodney Diaz and Dr. Doron Sagiv, University of California, Davis.*

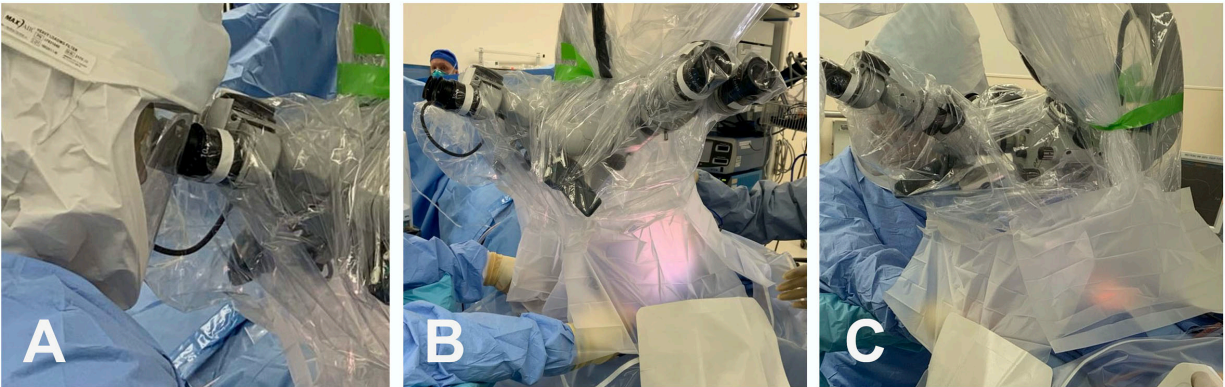
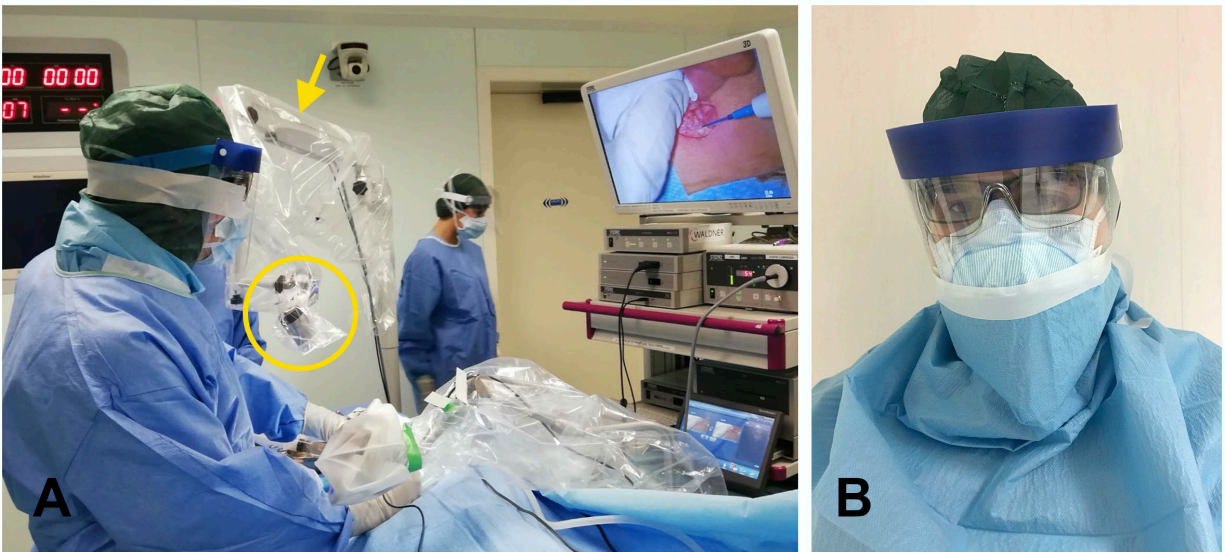


Figure 2. Exoscope with Personal Protective Equipment (PPE). Exoscope used with full PPE during a postauricular approach for a right ear mastoid abscess extending intracranially to the middle fossa. An exoscope (extracorporeal digital microscope) was used in place of a binocular microscope. An exoscope has a similar focal length as the microscope and enables “heads up” surgery without the concerns of using a face shield or PAPR with binocular eyepieces. **A.** Three-dimensional (3D) 4K extracorporeal exoscope (highlighted by yellow circle) and fiberoptic delivered light source is mounted to a manually operated articulating arm (yellow arrow). Note that a separate drape was placed to partially enclose the surgical site around the exoscope to minimize aerosolization. **B.** Filtering face piece 2 (FFP2) mask (similar to N95) and surgical mask, full head, face, and eye protection (over eyeglasses and under shield) with additional gowning around the neck and taped to the shield. *Courtesy of Professor Daniele Marchioni, MD, Verona, Italy.*



References:

1. WHO: Naming the coronavirus disease (COVID-19) and the virus that causes it. Available at: [https://www.who.int/emergencies/diseases/novel-coronavirus-2019/technical-guidance/naming-the-coronavirus-disease-\(covid-2019\)-and-the-virus-that-causes-it](https://www.who.int/emergencies/diseases/novel-coronavirus-2019/technical-guidance/naming-the-coronavirus-disease-(covid-2019)-and-the-virus-that-causes-it). Accessed 22 Mar 2020.
2. CDC: Cases in U.S. Available at: <https://www.cdc.gov/coronavirus/2019-ncov/cases-updates/cases-in-us.html>. Accessed 10 Apr 2020.
3. Chang, Xu H, Rebaza A, Sharma L, Dela Cruz CS. Protecting health-care workers from subclinical coronavirus infection. *Lancet Respir Med* 2020; 8:e13.
4. Li Q, Guan X, Wu Pet al. Early Transmission Dynamics in Wuhan, China, of Novel Coronavirus-Infected Pneumonia. *N Engl J Med* 2020.
5. Remuzzi A, Remuzzi G. COVID-19 and Italy: what next? *Lancet* 2020.
6. Wang D, Hu B, Hu Cet al. Clinical Characteristics of 138 Hospitalized Patients With 2019 Novel Coronavirus-Infected Pneumonia in Wuhan, China. *JAMA* 2020.
7. Wu Z, McGoogan JM. Characteristics of and Important Lessons From the Coronavirus Disease 2019 (COVID-19) Outbreak in China: Summary of a Report of 72314 Cases From the Chinese Center for Disease Control and Prevention. *JAMA* 2020.
8. COVID-19: protecting health-care workers. *Lancet* 2020; 395:922.
9. Zou L, Ruan F, Huang Met al. SARS-CoV-2 Viral Load in Upper Respiratory Specimens of Infected Patients. *N Engl J Med* 2020; 382:1177-1179.
10. Cheung JC, Ho LT, Cheng JV, Cham EYK, Lam KN. Staff safety during emergency airway management for COVID-19 in Hong Kong. *Lancet Respir Med* 2020.

11. Chavez S, Long B, Koyfman A, Liang SY. Coronavirus Disease (COVID-19): A primer for emergency physicians. *Am J Emerg Med* 2020.
12. Ferioli M, Cisternino C, Leo V, Pisani L, Palange P, Nava S. Protecting healthcare workers from SARS-CoV-2 infection: practical indications. *Eur Respir Rev* 2020; 29.
13. Werner M, Carey R, Albergotti W, Lukens J, Brody R. (In press). Impact of the COVID-19 Pandemic on the Management of Head and Neck Malignancies. *Otolaryngol Head Neck Surg* 2020.
14. Cui C, Yao Q, Zhang Det al. (In press). Approaching Otolaryngology Patients during the COVID-19 Pandemic. *Otolaryngol Head Neck Surg* 2020.
15. Cheng X, Liu J, Li Net al. (In press). Otolaryngology Providers Must Be Alert for Mild and Asymptomatic COVID-19 Patients. *Otolaryngol Head Neck Surg* 2020.
16. Balakrishnan K, Schechtman S, Hogikyan NDet al. (In press). COVID-19 Pandemic: What every Otolaryngologist – Head & Neck Surgeon Needs to Know for Safe Airway Management. *Otolaryngol Head Neck Surg* 2020.
17. Saadi RA, Bann DV, Patel VA, Goldenberg D, May J, Isildak H. A commentary on safety precautions for otologic surgery during the COVID-19 pandemic. *Otolaryngol Head Neck Surg* 2020; In press.
18. Rothe C, Schunk M, Sothmann Pet al. Transmission of 2019-nCoV Infection from an Asymptomatic Contact in Germany. *N Engl J Med* 2020; 382:970-971.
19. Li R, Pei S, Chen Bet al. Substantial undocumented infection facilitates the rapid dissemination of novel coronavirus (SARS-CoV2). *Science* 2020.

20. Mizumoto K, Kagaya K, Zarebski A, Chowell G. Estimating the asymptomatic proportion of coronavirus disease 2019 (COVID-19) cases on board the Diamond Princess cruise ship, Yokohama, Japan, 2020. *Euro Surveill* 2020; 25.
21. Pitkaranta A, Jero J, Arruda E, Virolainen A, Hayden FG. Polymerase chain reaction-based detection of rhinovirus, respiratory syncytial virus, and coronavirus in otitis media with effusion. *J Pediatr* 1998; 133:390-394.
22. Pitkaranta A, Virolainen A, Jero J, Arruda E, Hayden FG. Detection of rhinovirus, respiratory syncytial virus, and coronavirus infections in acute otitis media by reverse transcriptase polymerase chain reaction. *Pediatrics* 1998; 102:291-295.
23. Wiertsema SP, Chidlow GR, Kirkham LA et al. High detection rates of nucleic acids of a wide range of respiratory viruses in the nasopharynx and the middle ear of children with a history of recurrent acute otitis media. *J Med Virol* 2011; 83:2008-2017.
24. Jackler R. COVID-19 and Ear Surgery. Available at: https://www.entnet.org/sites/default/files/uploads/covid-19_and_ear_surgery_rk_jackler_stanford.pdf. Accessed 29 Mar 2020.
25. Workman AD, Welling DB, Carter B et al. Endonasal instrumentation and aerosolization risk in the era of COVID-19: simulation, literature review, and proposed mitigation strategies. *Int Forum Allergy Rhinol* 2020.
26. Patel ZM, Fernandez-Miranda J, Hwang PH et al. Precautions for endoscopic transnasal skull base surgery during the COVID-19 Pandemic. *Neurosurgery* 2020.

27. Scott A, De R, Sadek SA, Garrido MC, Courteney-Harris RG. Temporal bone dissection: a possible route for prion transmission? *J Laryngol Otol* 2001; 115:374-375.
28. Hilal A, Walshe P, Gendy S, Knowles S, Burns H. Mastoidectomy and trans-corneal viral transmission. *Laryngoscope* 2005; 115:1873-1876.
29. Lannigan FJ, Jones NS, von Schoenberg MV. An avoidable occupational hazard during mastoid surgery. *J Laryngol Otol* 1989; 103:566.
30. Norris BK, Goodier AP, Eby TL. Assessment of air quality during mastoidectomy. *Otolaryngol Head Neck Surg* 2011; 144:408-411.
31. Okoshi K, Kobayashi K, Kinoshita K, Tomizawa Y, Hasegawa S, Sakai Y. Health risks associated with exposure to surgical smoke for surgeons and operation room personnel. *Surg Today* 2015; 45:957-965.
32. Bree K, Barnhill S, Rundell W. The Dangers of Electrosurgical Smoke to Operating Room Personnel: A Review. *Workplace Health Saf* 2017; 65:517-526.
33. Alp E, Bijl D, Bleichrodt RP, Hansson B, Voss A. Surgical smoke and infection control. *J Hosp Infect* 2006; 62:1-5.
34. Limchantra IV, Fong Y, Melstrom KA. Surgical Smoke Exposure in Operating Room Personnel: A Review. *JAMA Surg* 2019.
35. Elmashae Y, Koehler RH, Yermakov M, Reponen T, Grinshpun SA. Surgical Smoke Simulation Study: Physical Characterization and Respiratory Protection. *Aerosol Sci Technol* 2018; 52:38-45.
36. Judson SD, Munster VJ. Nosocomial Transmission of Emerging Viruses via Aerosol-Generating Medical Procedures. *Viruses* 2019; 11.

37. Garden JM, O'Banion MK, Bakus AD, Olson C. Viral disease transmitted by laser-generated plume (aerosol). *Arch Dermatol* 2002; 138:1303-1307.
38. Michailidis L, Kotsanas D, Orr Eet al. Does the new low-frequency ultrasonic debridement technology pose an infection control risk for clinicians, patients, and the clinic environment? *Am J Infect Control* 2016; 44:1656-1659.
39. Tran K, Cimon K, Severn M, Pessoa-Silva CL, Conly J. Aerosol generating procedures and risk of transmission of acute respiratory infections to healthcare workers: a systematic review. *PLoS One* 2012; 7:e35797.
40. Funk DJ, Kumar A. Ebola virus disease: an update for anesthesiologists and intensivists. *Can J Anaesth* 2015; 62:80-91.
41. Seto WH. Airborne transmission and precautions: facts and myths. *J Hosp Infect* 2015; 89:225-228.
42. Zumla A, Hui DS. Infection control and MERS-CoV in health-care workers. *Lancet* 2014; 383:1869-1871.
43. Topsakal V, Rompaey VV, Kuhweide Ret al. (In press). Prioritizing otological surgery during the COVID-19 Pandemic. *B-ENT* 2020.
44. BSO: Guidance for undertaking otological procedures during COVID-19 pandemic. Available at: <https://www.entuk.org/guidance-undertaking-otological-procedures-during-covid-19-pandemic>. Accessed 29 Mar 2020.
45. CDC. Real-time rt-pcr panel for detection 2019- novel coronavirus 2020. Available at: https://www.who.int/docs/default-source/coronaviruse/uscdcr-pcr-panel-for-detection-instructions.pdf?sfvrsn=3aa07934_2. Accessed 29 Mar 2020.

46. Pang J, Wang MX, Ang IY, et al. Potential Rapid Diagnostics, Vaccine and Therapeutics for 2019 Novel Coronavirus (2019-nCoV): A Systematic Review. *J Clin Med* 2020; 9.
47. Yang Y, Yang M, Shen C, Wang F, Yuan J, Li J. Evaluating the accuracy of different respiratory specimens in the laboratory diagnosis and monitoring the viral shedding of 2019-nCoV infections. *medRxiv* 2020.
48. Wang W, Xu Y, Gao R, et al. Detection of SARS-CoV-2 in Different Types of Clinical Specimens. *JAMA* 2020.
49. Ye Z, Zhang Y, Wang Y, Huang Z, Song B. Chest CT manifestations of new coronavirus disease 2019 (COVID-19): a pictorial review. *Eur Radiol* 2020.
50. Ai T, Yang Z, Hou H, et al. Correlation of Chest CT and RT-PCR Testing in Coronavirus Disease 2019 (COVID-19) in China: A Report of 1014 Cases. *Radiology* 2020:200642.
51. Long C, Xu H, Shen Q, et al. Diagnosis of the Coronavirus disease (COVID-19): rRT-PCR or CT? *Eur J Radiol* 2020; 126:108961.
52. Xie X, Zhong Z, Zhao W, Zheng C, Wang F, Liu J. Chest CT for Typical 2019-nCoV Pneumonia: Relationship to Negative RT-PCR Testing. *Radiology* 2020:200343.
53. Li Y, Xia L. Coronavirus Disease 2019 (COVID-19): Role of Chest CT in Diagnosis and Management. *AJR Am J Roentgenol* 2020:1-7.
54. CDC: Symptoms of Coronavirus. Available at: <https://www.cdc.gov/coronavirus/2019-ncov/symptoms-testing/symptoms.html>. Accessed 15 Apr 2020.

55. Wang Y, Kang H, Liu X, Tong Z. Combination of RT-qPCR testing and clinical features for diagnosis of COVID-19 facilitates management of SARS-CoV-2 outbreak. *J Med Virol* 2020.
56. Dong X, Cao YY, Lu XX et al. Eleven faces of coronavirus disease 2019. *Allergy* 2020.
57. Yu F, Yan L, Wang Net al. Quantitative Detection and Viral Load Analysis of SARS-CoV-2 in Infected Patients. *Clin Infect Dis* 2020.
58. To KK, Tsang OT, Leung WSet al. Temporal profiles of viral load in posterior oropharyngeal saliva samples and serum antibody responses during infection by SARS-CoV-2: an observational cohort study. *Lancet Infect Dis* 2020.
59. Rauch SD, Halpin CF, Antonelli PJet al. Oral vs intratympanic corticosteroid therapy for idiopathic sudden sensorineural hearing loss: a randomized trial. *JAMA* 2011; 305:2071-2079.
60. Thompson GP, Sladen DP, Borst BJH, Still OL. Accuracy of a Tablet Audiometer for Measuring Behavioral Hearing Thresholds in a Clinical Population. *Otolaryngology–Head and Neck Surgery* 2015; 153:838-842.
61. West JS, Franck KH, Welling DB. Providing health care to patients with hearing loss during COVID-19 and physical distancing. *Laryngoscope Investigative Otolaryngology* 2020:1-3.
62. Roberge MR, Vojtko MR, Roberge RJ, Vojtko RJ, Landsittel DP. Wearing an N95 respirator concurrently with a powered air-purifying respirator: effect on protection factor. *Respir Care* 2008; 53:1685-1690.

63. Makovicka JL, Bingham JS, Patel KA, Young SW, Beauchamp CP, Spangehl MJ. Surgeon Personal Protection: An Underappreciated Benefit of Positive-pressure Exhaust Suits. *Clin Orthop Relat Res* 2018; 476:1341-1348.
64. Chughtai AA, Chen X, Macintyre CR. Risk of self-contamination during doffing of personal protective equipment. *Am J Infect Control* 2018; 46:1329-1334.
65. Suen LKP, Guo YP, Tong DW, et al. Self-contamination during doffing of personal protective equipment by healthcare workers to prevent Ebola transmission. *Antimicrob Resist Infect Control* 2018; 7:157.
66. Mumma JM, Durso FT, Ferguson AN, et al. Human Factors Risk Analyses of a Doffing Protocol for Ebola-Level Personal Protective Equipment: Mapping Errors to Contamination. *Clin Infect Dis* 2018; 66:950-958.
67. Kwon JH, Burnham CD, Reske KA, et al. Assessment of Healthcare Worker Protocol Deviations and Self-Contamination During Personal Protective Equipment Donning and Doffing. *Infect Control Hosp Epidemiol* 2017; 38:1077-1083.
68. Kozin ED, Kiringoda R, Lee DJ. Incorporating Endoscopic Ear Surgery into Your Clinical Practice. *Otolaryngol Clin North Am* 2016; 49:1237-1251.
69. Tarabichi M, Marchioni D, Presutti L, Nogueira JF, Pothier D. Endoscopic transcanal ear anatomy and dissection. *Otolaryngol Clin North Am* 2013; 46:131-154.
70. Levy ML, Day JD, Albuquerque F, Schumaker G, Giannotta SL, McComb JG. Heads-up intraoperative endoscopic imaging: a prospective evaluation of techniques and limitations. *Neurosurgery* 1997; 40:526-530; discussion 530-521.

71. Yu D, Sackllah M, Woolley C, Kasten S, Armstrong T. Quantitative posture analysis of 2D, 3D, and optical microscope visualization methods for microsurgery tasks. *Work* 2012; 41 Suppl 1:1944-1947.
72. Smith S, Kozin ED, Kanumuri VV et al. Initial Experience with 3-Dimensional Exoscope-Assisted Transmastoid and Lateral Skull Base Surgery. *Otolaryngol Head Neck Surg* 2019; 160:364-367.
73. Garneau JC, Laitman BM, Cosetti MK, Hadjipanayis C, Wanna G. The Use of the Exoscope in Lateral Skull Base Surgery: Advantages and Limitations. *Otol Neurotol* 2019; 40:236-240.
74. BSO: Mastoidectomy in the COVID Era – The 2 Microscope Drape Method to Reduce Aerosolization. Available at:
<https://www.entuk.org/sites/default/files/Mastoidectomy%20in%20the%20COVID%20Era%20-%20The%202.pdf>. Accessed 15 Apr 2020.