



Research Article

Morphology of the rat's brain in four vessels model of ischemic stroke after administration of carbamylated darbepoetin

Tverskoy Alexey Vladimirovich*, Pavel D. Kolesnichenko, Olesya V. Shcheblykina, Narine S. Gorbunova, Vitaliy N. Morozov, Tatyana S. Mukhina

ABSTRACT

Aim: The aim was the study of the cerebroprotective effect of carbamylated darbepoetin in a four-vessel model of rat brain ischemia-reperfusion. **Materials and method:** Various parts of rat brain were studied in the four-vessel ischemia-reperfusion model in the treatment with carbamylated darbepoetin. The animals were divided into four groups: Intact, pseudo-operated, with a four-vessel model of ischemia without treatment, and a triple preliminary administration of carbamylated darbepoetin. Animals in the third and fourth groups were intraperitoneally injected with carbamylated darbepoetin at a dose of 100 µg/kg at an interval of 3 days. **Results:** The carotid arteries were isolated, and then the electrocoagulation of the vertebral arteries at the level of the C2-C3 segments of the spinal cord, after which the common carotid arteries were bandaged. The onset of ischemia was controlled with a decrease in the amplitude on the electroencephalogram. **Conclusion:** The study of the hippocampus and the cerebral cortex after the experiment was performed on days 1 and 3. A massive preconditioning cerebroprotective effect of carbamylated darbepoetin in the fourth group of animals and massive ischemic changes of the hippocampal and cortical neurons in the third group were revealed. These were manifested by karyopyknosis, karyorrhexis, and violation of stratification of CA1-CA3 layers of the hippocampus.

KEY WORDS: Carbamylated darbepoetin, Cerebral ischemia, Four vessels model, Reperfusion, Hippocampus

INTRODUCTION

It is known that hypoxic condition is one of the most common causes of cell death and damage. This is due to the presence of conservative mechanisms of the regulation of oxygen homeostasis and homeostasis. One of these systems, associated with a cascade of hypoxia-inducible factor, leads to the synthesis of erythropoietin (EPO), which is a glycoprotein with a molecular weight of the order of 30.4 kDa.^[1,2] This molecule is best known as a positive regulator of erythropoiesis, which is mainly produced in the kidneys in response to a decrease in the partial pressure of oxygen. However, the spectrum of the physiological effects of EPO is quite wide and allows us to consider it as an agent with a universal cytoprotective directivity.

The cascades initiated by them lead to an increase in the resistance of cells to damage, which has been proven on models of ischemia in almost all organs.^[3-5] With ischemic lesions of different organs, EPO causes angiogenic, antioxidant, anti-inflammatory, and antiapoptotic effects,^[6,7] which leads to a reduction in the area of damage.^[8] The implementation of the cellular effects of EPO occurs when it binds to two receptors (EPO receptor – [R]), resulting in the formation of a homodimer. The latter leads to the activation of many intracellular factors, among which the main role in cytoprotection is removed by Akt, which inactivates caspases, resulting in damage to mitochondria, disruption of cellular homeostasis, and initiation of apoptosis.^[9] At the same time, due to the activation of a large number of secondary mediators, EPO is able to cause the development of such negative effects as an increase in endothelin production, an increase in tissue renin concentration, a change in the balance of prostaglandins in the vascular tissue,

Access this article online

Website: jprsolutions.info

ISSN: 0975-7619

Department of Human Anatomy, Department of Human Anatomy of the Medical Institute, Federal State Autonomous Educational Institution of Higher Professional Education (Belgorod State National Research University) (NRU BelSU), Pobedy St. 85, Belgorod, 308015, Russia

***Corresponding author:** Tverskoy Alexey Vladimirovich, Department of Human Anatomy of the Medical Institute, Federal State Autonomous Educational Institution of Higher Professional Education (Belgorod State National Research University) (NRU BelSU), Pobedy St. 85, Belgorod, 308015, Russia. E-mail: tverskoy@bsu.edu.ru

Received on: 02-08-2018; Revised on: 04-09-2018; Accepted on: 06-10-2018

stimulation of angiogenesis, and proliferation of smooth muscle cells.^[10,11] Carbamylated darbepoetin is fundamentally different from drugs based on EPO, combining the best qualities of the drugs of previous generations.^[12,13]

Aim

The aim was the study of the cerebroprotective effect of carbamylated darbepoetin in a four-vessel model of rat brain ischemia-reperfusion.

MATERIALS AND METHODS

The material of the study was 40 rats of the Wistar line, which were divided into four groups. The first group consisted of 10 intact animals, the second group included 10 pseudo-operated animals, and Groups 3 and 4 consisted of 10 rats with a 4-min four-vascular model of cerebral ischemia without prior administration of darbepoetin and its administration, respectively. When modeling a four-vessel model of cerebral ischemia in the field of the operating field, the scalp was removed with the help of a depilation cream followed by treatment with an antiseptic. Then, a small incision of soft tissues was made along the middle line of the neck and the muscles were moved apart by blunt dissection. The right and left common carotid arteries were isolated. The tracheal tube, the thyroid gland, was pushed aside to open the access to the vertebral column. Coagulation of vertebral arteries was carried out at the level of C2-C3 segments of the spinal cord. Then, overlapping the lumen of the carotid arteries, the electroencephalography (EEG) was recorded. This was the main criterion for an adequately implemented methodology. Blood flow in the pool of carotid arteries was restored after 4 min, after which the wound was layer-by-layer sutured; the operating field was treated with an antiseptic solution. EEG was performed using an EEG MP150 EEG100C. The neurological deficit is a consequence of cerebral ischemia and is accompanied by a change in the standard neurological status (paresis, plegia, impaired sensitivity, dizziness, etc.).^[14]

To assess the neurological status of rats, the following methods were used:

1. A grading school of McGraw's stroke assessment in the modification of IV Gannushkina.^[14] Within the group of rats with signs of neurologic deficiency was divided into animals with mild, moderate, and severe symptoms of neurologic deficiency. If the animal had several signs of a neurological deficit, the points were summed up.
2. Infrared activity monitor: "Infrared activity monitor" includes a two-dimensional square frame and an infrared ray system for detecting movements of an animal. IR Actimeter allows you to perform testing of voluntary motor activity, the number and

duration of hitching episodes, stereotyped motions, and research behavior in the "perforated field" model under daylight and nighttime conditions. ActiTrack software allows you to analyze the trajectory of an animal's movement (distance, speed, and time spent in certain zones). To assess the orienting-research behavior, the installation of Panlab Harvard Apparatus LE 8825 was used.

The animals were withdrawn from the experiment 24 and 72 h after the start of the study. For the morphological study, the brain was taken; it was fixed in 10% neutral buffered formalin for 24–48 h. Thereafter, the preparation was subjected to standard wiring on a Leica TP 1020 apparatus, poured into paraffin, slices 4–5 μm thick, and stained with hematoxylin and eosin and toluidine blue in Nissl's modification using standard protocols and procedures on Leica EG 1150 H, Leica RM 2245, and Leica Autostainer XL.

Immunohistochemical reactions were performed with glial fibrillary acidic protein (GFAP) antibodies (clone EP672Y, CellMarque), NSE (clone MRQ55, CellMarque), p53 (clone DO7, CellMarque), and Ki 67 (clone NE14, Biogenex). The streptavidin-biotin method (LSAB Kit) was used, as diaminobenzidine as the chromogen. Unmask antigens were made by heating in citrate buffer (pH 6.0) for 40 min at a temperature of 93–95°C. The immunohistochemical study was performed in the immunohistochemistry department of the Belgorod Regional Pathoanatomical Bureau (TS Mukhina). The photoprotocols were performed on the MiraxDesk scanner (Carl Zeiss Microimaging GmbH, Germany), the Nikon Eclipse Ni microscope with the Nis-Elements BR 4.60.00 software. Statistical calculations were carried out with the help of Statistica 10.0.

Experimental

At the beginning of the experiment, all animals were randomized according to the degree of resistance to hypoxia. In the study, animals with average stability indicators participated. Animals in the fourth group were intraperitoneally injected with carbamylated darbepoetin at a dose of 100 mcg/kg at an interval of 3 days. To achieve the goal, a four-vessel model of total cerebral ischemia was used. Rats were anesthetized with Zoletil at a dose of 60 mg/kg and chloral hydrate intraperitoneally at a dose of 150 mg/kg, after which surgery was performed. The criterion for an adequately performed procedure was the level of decrease in EEG amplitude [Figure 1]. The episode of ischemia was 4 min. After removal of the clip from the common carotid arteries and suturing of the operating wound, restoration of the blood flow of the brain was confirmed with a repeated EEG [Figure 2], and then, neurological disorders were recorded. The animals

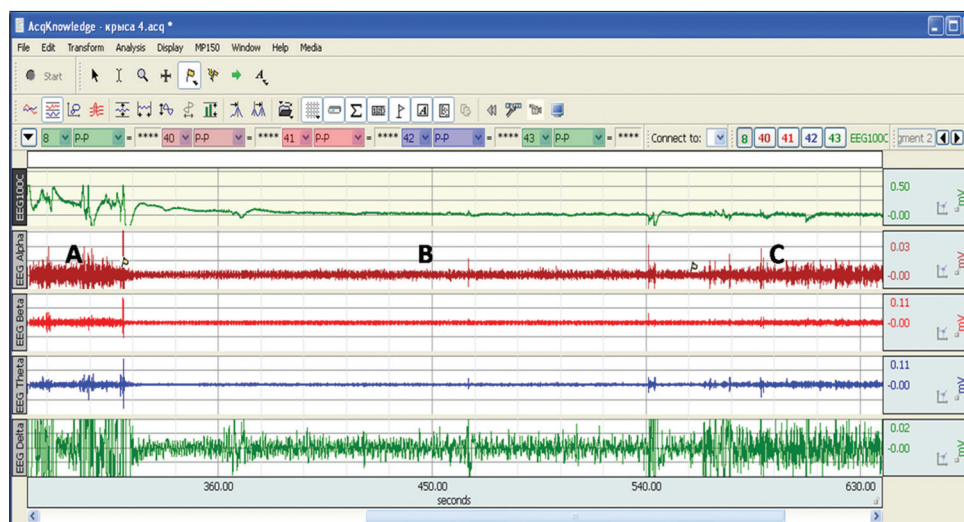


Figure 1: Electroencephalogram before total ischemia (a), during ischemia (b), and after ischemia (c)

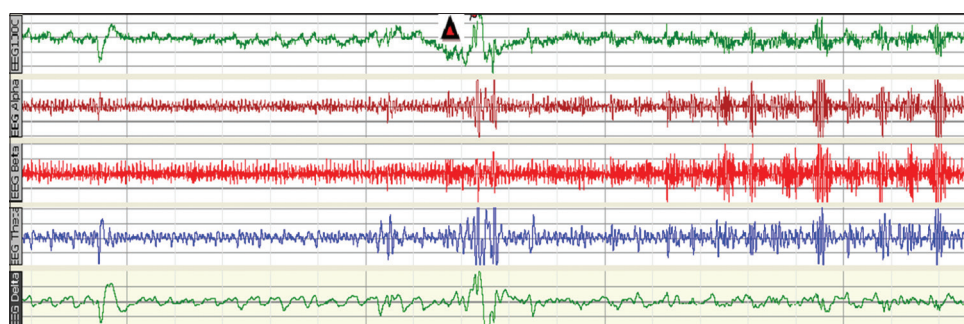


Figure 2: Electroencephalogram during reperfusion of the brain (after total ischemia; the arrow point time of starting)

were withdrawn from the experiment 24 and 72 h later with a morphological study of the brain. In groups of intact and pseudo-operated animals, carbamylated darbepoetin was not administered, as well as in the third group with 4-min total ischemia.

In the first and second groups, neurologic symptoms were absent. In the histological examination of the brain, there were no specific features in the structure of the neurons of the CA1-CA3 regions of the hippocampus, gyrus dentatus, frontal cortex, and parietal lobe.

In rats in the third group, after 4-min total ischemia, massive neurologic disorders were observed, which almost completely disappeared by the end of the 1st day. They were manifested by paresis, paralysis, lethargy, and slowing movements. By the end of the 3rd day, the symptoms of the nervous system were absent.

When examining by the microscope, the brain of rats of the third group, massive perivascular and pericellular edema, fullness of small vessels and capillaries of brain substance, as well as vascular plexuses were detected. In the dentate gyrus neurons, in the regions of the CA1-CA3 hippocampus, pronounced degenerative changes of the majority of neurons characterized

by subtotal disorganization of their layers, partial cellular depopulation are revealed [Figures 3 and 4]. Changes in the nuclei of neurons were recorded in the form of swelling, fuzziness of contours, karyopyknosis, and karyorrhexis. Polymorphic changes of the chromatophilic substance in the form of focal chromatography, lumpy condensation, and fuzziness of the structure of the apical dendrites of pyramidal neurons of the cerebral cortex were also revealed [Figure 5]. These changes were clearly visible both in the staining of hematoxylin and eosin and in the use of toluidine blue according to the Nissl method.^[15-17] In one case, the paraventricular gliosis focus was recorded.

In immunohistochemical studies in animals of the third group in areas of the brain with the greatest sensitivity to hypoxia and massive changes in the visual color, there was a lack of expression with antibodies to NSE and p53. In this case, the reaction with antibodies to GFAP is positive, with a slight decrease in the number of glial cells and their processes [Figures 5 and 6].

In the fourth group of animals, the pronounced neuroprotective effect of carbamylated darbepoetin was revealed, which was manifested by the preservation of the neuronal layers of the hippocampus and the cerebral cortex, the presence of single

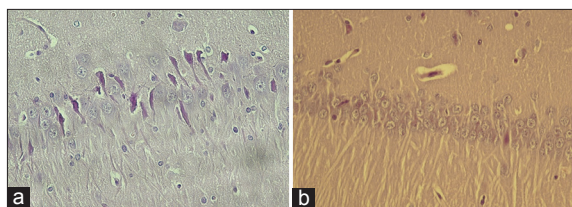


Figure 3: Neuronal degeneration of CA1 area of the hippocampus without carbamylated darbepoetin (a) and after its administration (b) hematoxylin and eosin. a, b \times 400

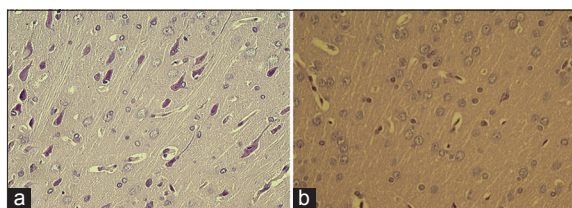


Figure 4: Neuronal degeneration of cerebral cortex without carbamylated darbepoetin (a) and after its administration (b) hematoxylin and eosin. a, b \times 400

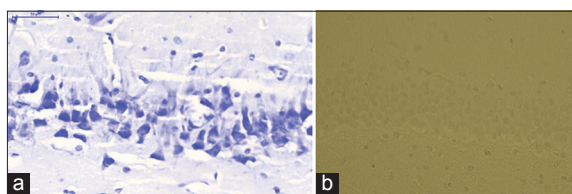


Figure 5: Neuronal degeneration of CA1 area of the hippocampus without carbamylated darbepoetin (a) and negative reaction with NSE antibodies (b) Nissl reaction (a) and IHC reaction with NSE antibodies. a, b \times 400

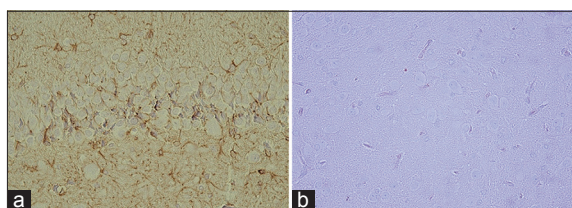


Figure 6: Glial fibrillary acidic protein-positive reaction in the third group (a) and p53 negative reaction (b) \times 400

neurons with obvious signs of ischemic damage and degeneration. However, these changes were observed against a background of perivascular and pericellular edema expressed by the embolism of small vessels and capillaries of the brain substance and its vascular plexuses [Figures 3b and 4b].

CONCLUSION

1. A four-vessel model of total cerebral ischemia is technically complex but an adequate technique for investigating ischemic brain damage.
2. Carbamylated darbepoetin has an evident neuroprotective effect.
3. The preconditioning effect of carbamylated darbepoetin on the microcirculatory bed is not revealed.

4. Negative immunohistochemical reaction with NSE, GFAP, and p53 was identified in brain areas with ischemic lesions such as CA1-CA3 fields of hippocampus.

REFERENCES

1. Semenza GL. Oxygen homeostasis. Wiley interdisciplinary. Syst Biol Med 2010;2:336-61.
2. Stockmann C, Fandrey J. Hypoxia-induced erythropoietin production: A paradigm for oxygen-regulated gene expression. Clin Exp Pharmacol Physiol 2006;33:968-79.
3. Reznikov KM, Gorbunova NS, Kolesnichenko PD, Tverskoy AV, Bashkatova DA, Nikitina VA. Search of new pharmaceuticals on the basis of darbepoetin in the treatment of ischemic stroke (review of literature). Res Result 2017;3:125-36.
4. Shabelnikova AS, Peresyphkina AA, Gubareva VO, Levkova EA, Dolzhikov AA, Nikolaev SB, *et al.* Pharmacological preconditioning by recombinant erythropoietin as the possibility of increasing the stability of tissue of the retina to reperfusion ischemia in experiment. Res Result 2016;2:25-9.
5. Alehin SA, Kolmykov DI, Pokrovskii MV. Human recombinant erythropoietin gradient dosage influence on ischemic and reperfusion liver injury. Res Result 2015;1:9-12.
6. Burger D, Xenocostas A, Feng QP. Molecular basis of cardioprotection by erythropoietin. Curr Mol Pharmacol 2009;2:56-69.
7. Zhu L, Bai X, Wang S, Hu Y, Wang T, Qian L, *et al.* Recombinant human erythropoietin augments angiogenic responses in a neonatal rat model of cerebral unilateral hypoxia-ischemia. Neonatology 2014;106:143-8.
8. El Hasnaoui-Saadani R, Marchant D, Pichon A, Escoubet B, Pezet M, Hilfiker-Kleiner D, *et al.* Epo deficiency alters cardiac adaptation to chronic hypoxia. Respir Physiol Neurobiol 2013;186:146-54.
9. Rusai K, Prókai A, Szebeni B, Fekete A, Treszl A, Vannay A, *et al.* Role of serum and glucocorticoid-regulated kinase-1 in the protective effects of erythropoietin during renal ischemia/reperfusion injury. Biochem Pharmacol 2010;79:1173-81.
10. Fisher JW. Erythropoietin: Physiology and pharmacology update. Exp Biol Med (Maywood) 2003;228:1-4.
11. Kimáková P, Solár P, Solárová Z, Komel R, Debeljak N. Erythropoietin and its angiogenic activity. Int J Mol Sci 2017;18: E1519.
12. Shukurov RP, Hamitov RR, Kryazhevskih IS. Carbamylated Darbepoetin 9c-Depo, a Method for its Preparation and its use as a Medicament with Cytoprotective Action. "Pharmapark LLC" Assignee. Russian Federation Patent RF0002575773; 2013.
13. Catlin DH, Breidbach A, Elliott S, Gaspy J. Comparison of the isoelectric focusing patterns of darbepoetin alfa, recombinant human erythropoietin, and endogenous erythropoietin from human urine. Clin Chem 2002;48:2057-9.
14. Gannushkina IW. Cerebral circulation in different types circulatory hypoxia of the brain. Vestn Ross Akad Med Nauk 2000;9:22-7.
15. Tverskoy A.V., Dolzhikov A.A., Bobintsev I.I., Kryukov A.A., Belykh A.E. Morphological changes in the neurons of the CA1 areas and CA3 hippocampal criss under chronological immobilization stress (morphometric study). Kursk Scientific Pract West Man, 2014; 3: 37-41.
16. Dolzhikov AA, Tverskoi AV, Bobintsev II, Kriukov AA, Belykh AE. Morphometric study of hippocampal neurons in chronic immobilization stress. Res Result 2015;4:62-5.
17. Tverskoi AV, Morozov VN, Petrenko AA, Mukhina TS, Parichuk AS. Morphological characteristics of the rats brain under hypergravity. Drug Invent Today 2017;19:30-2.

Source of support: Nil; Conflict of interest: None Declared