



DR. NEVENA SKROZA (Orcid ID : 0000-0003-4478-5404)

DR. NICOLETTA BERNARDINI (Orcid ID : 0000-0002-6295-3574)

DR. SIMONE MICHELINI (Orcid ID : 0000-0002-3374-7384)

Article type : Letter to Editor

**A late onset widespread skin rash in a previous Covid-19 infected patient:
viral or multidrug effect?**

Authors: N. Skroza MD¹, N. Bernardini MD, PhD¹, V. Balduzzi MD¹, A. Mambrin MD¹, A. Marchesiello MD¹, S. Michelini MD¹, E. Tolino MD¹, I. Proietti MD, PhD¹, C. Di Cristofano MD², V. Petrozza MD², C. Potenza MD¹

Affiliation: ¹Dermatology Unit “D. Innocenzi”, Polo Pontino, Sapienza University of Rome, Rome, Italy

²Pathology Unit, Dept of Medical-Surgical Sciences and Bio-Technologies, Sapienza University of Rome, I.C.O.T, Polo Pontino, Latina, Italy

Corresponding author: Nevena Skroza, MD.

Dermatology Unit “Daniele Innocenzi” Dept of Medical-Surgical Sciences and Bio-Technologies, Sapienza University of Rome Fiorini Hospital

Via Firenze snc Polo Pontino, 04019 Terracina, Italy.

Email: nevena.skroza@uniroma1.it

Tel: +39 0773 708531 Fax : +39 0773 708399

This article has been accepted for publication and undergone full peer review but has not been through the copyediting, typesetting, pagination and proofreading process, which may lead to differences between this version and the [Version of Record](#). Please cite this article as [doi: 10.1111/JDV.16633](https://doi.org/10.1111/JDV.16633)

This article is protected by copyright. All rights reserved

Key words: COVID-19, skin manifestation, infection, adverse drug reaction, urticarial vasculitis, SARS-CoV-2

Conflict of interest: none to declare

Founding source: none to declare

Acknowledgement: the patient in this manuscript has given written informed consent to the publication of his case details

Dear Editor,

in the end of 2019, a series of pneumonia cases emerged in China, with clinical presentations greatly resembling viral pneumonia, caused by Covid-19 or SARS-CoV-2¹.

Currently, several clinicians described an increasingly cases of coronavirus-positive patients reporting skin problems, either in early stage of infection or as late onset manifestation²⁻⁴.

Recently, Dr. Sebastiano Recalcati analyzed the cutaneous involvement in 148 COVID-19 patients hospitalized in the Lecco Hospital, Lombardy, Italy⁵.

Among them, 18 patients developed cutaneous involvement with erythematous rash, urticaria and chickenpox-like vesicles⁵.

In light of these data, in the absence of a related histological analysis, it is not possible to determine whether these clinical manifestations are attributable to direct viral action or to other factors.

We report a patient with a history of Covid-19 infection and a late onset cutaneous eruption, after healing.

A 47-year-old auxiliary hospital worker, with a history of hypertension and impaired glucose tolerance, in service at a hospital located in one of the Italian Covid-19 red zones, had a syncope during his work shift, so urgent CT scan was performed.

The radiological report showed, unexpectedly, pulmonary ground-glass opacifications, mainly involving the right lower lobe.

Consequently, nasopharyngeal and oropharyngeal swabs were performed for Covid-19 on March 25, 2020: the tests were positive for SARS-CoV-2.

Pertinent laboratory results on admission revealed only elevated RCP (2,11 mg/dl).

Supportive, antibiotic, antiviral and anticoagulant (Ceftriaxon, Lopinavir/Ritonavir, Hidroxicloroquina, Enoxaparin) care were carried with good clinical response.

Neither high fever nor severe respiratory symptoms were noticed.

Firstly on April 2, and once again on April 4, the control swabs were negative, therefore, given his health status, the patient was discharged from hospital on April 8, 2020.

Four days later, patient reported appearance of persistent, progressive, erythematous and itchy lesions, with cranio-caudal displacement.

Symptoms get worse quickly, so he went to E.R. where he was given intravenous steroid and antihistamine agent, with mild benefit.

Blood test revealed an increased in white blood cells ($22,27 \times 10^3/\text{ul}$) especially in neutrophils ($19,52 \times 10^3/\text{ul}$).

Dermatologic consultation revealed multiple, raised erythematous wheals, alone or in cluster, some of them with central purple hyperpigmentation, predominantly localized on head, trunk and upper arms. (Fig. 1a)

Patient complained of intense itching.

A diagnosis of suspected urticarial vasculitis has been made.

In attempt to rule out if this clinical manifestation was linked to viral reactivation, nasopharyngeal and oropharyngeal swabs were executed again, resulting negative for SARS-CoV2.

The blood test for autoimmune disease was negative (ANA, ENA screening, ANCA, antiphospholipid, C3,C4).

Punch biopsy was performed and histological examination revealed orthokeratotic hyperkeratosis, spongiosis, focal vacuolar degeneration of basal keratinocytes and focal lymphocytic exocytosis. Slight inflammatory lymphomonuclear infiltrate of superficial dermis with minimal perivascular neutrophilic component was observed, with occasional aspects of vessel wall damage. (Fig. 1b)

Thus, the histopathologic diagnosis of a plausible adverse drug reaction was established.

Therefore, the patient was treated as Urticarial Vasculitis due to adverse drug reaction with tapering Prednisone, Bilastine and Pantoprazole with prior authorization of diabetes specialist, given the evidence of recent onset diabetes mellitus.

After 7 days patient presented a complete symptom remission.

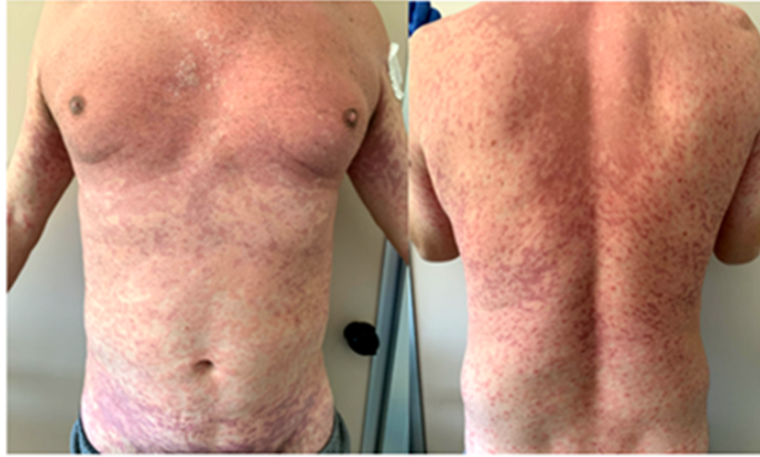Currently, cases of different COVID-19-related skin manifestations are frequently described⁶⁻⁷.

We recognize the limitations of this single case report; however further experiences are required to distinguish how often skin involvement is closely related to virus and how frequently it could be related to anti Covid-19 multidrug treatment.

References

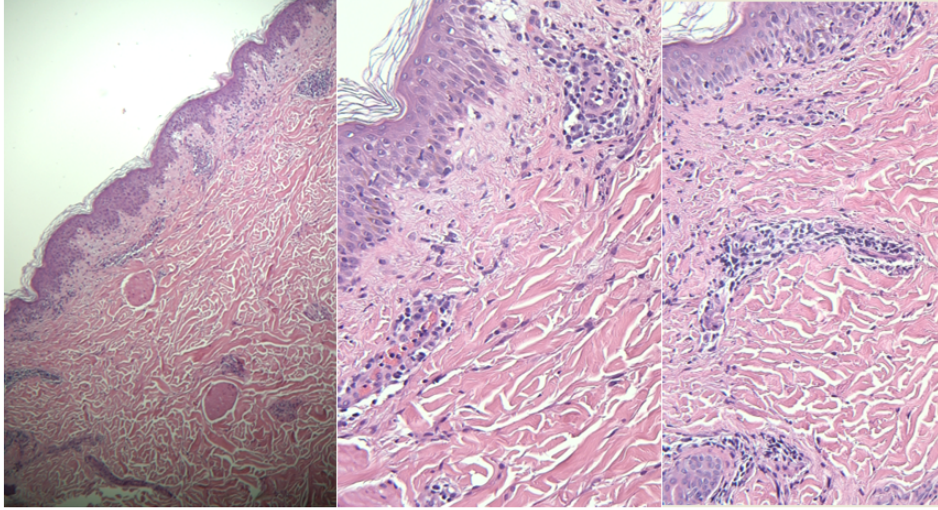
1. Huang C, Wang Y, Li X, Ren L, Zhao J, Hu Y, Zhang L, et al. Clinical features of patients infected with 2019 novel coronavirus in Wuhan, China. *Lancet*. 2020 Feb 15;395(10223):497-506.
2. Joob B, Wiwanitkit V. Various forms of skin rash in COVID-19 : a reply. *J Am Acad Dermatol*. 2020 Apr 10.
3. Estébanez A, Pérez-Santiago L, Silva E, Guillen-Climent S, García-Vázquez A, Ramón MD. Cutaneous manifestations in COVID-19: a new contribution. *J Eur Acad Dermatol Venereol*. 2020 Apr 1.
4. Henry D, Ackerman M, Sancelme E, Finon A, Esteve E. Urticarial eruption in COVID-19 infection. *J Eur Acad Dermatol Venereol*. 2020 Apr 15.

5. Recalcati S. Cutaneous manifestations in COVID-19: a first perspective. *J Eur Acad Dermatol Venereol.* 2020 Mar 26.
6. Mahé A, Birckel E, Krieger S, Merklen C, Bottlaender A distinctive skin rash associated with Coronavirus Disease 2019 ? L.J *Eur Acad Dermatol Venereol.* 2020 Apr 1.
7. Fernandez-Nieto D, Ortega-Quijano D, Segurado-Miravalles G, Pindado-Ortega C, Prieto-Barrios M, Jimenez-Cauhe J. Comment on: Cutaneous manifestations in COVID-19: a first perspective. Safety concerns of clinical images and skin biopsies. *J Eur Acad Dermatol Venereol.* 2020 Apr 15.



jdV_16633_f1a.tif

Figure 1a: clinical pictures



jdV_16633_f1b.tif

Figure 1b: histology pictures