



## A Successful Root Canal Therapy of a Maxillary First Molar With 3 Separate Root Canals in the Mesio Buccal Root: Case Report

Hamed Karkehabadi<sup>1</sup>, Masoumeh Ramezani<sup>2\*</sup>, Hossein Samiei<sup>3</sup>

### Abstract

**Introduction:** An important issue in treatment planning and endodontic treatment is to deal with sophisticated internal dental morphology. Deviations from normal anatomy in maxillary molars are usually related to the number of canals in mesio buccal root. Although unusual anatomy is not uncommon in maxillary molars, the occurrence of 3 separate canals with distinct orifices and apical foramina (as we see in this case) is extremely rare. Getting familiar with this unusual anatomy helps clinicians to treat patients more efficiently with less chance of failure.

**Case Presentation:** This case report describes a successful endodontic management of an uncommon variation of the maxillary first molar with a third mesio buccal canal. The tooth had a deep carious lesion and the pulp was irreversibly damaged causing pain on the left side of the face. The periodontium was normal. The tooth received root canal treatment and 400 mg ibuprofen was prescribed every 6 hours for 2 to 3 days. The patient remained asymptomatic and the 3-month follow-up radiograph revealed normal periodontium.

**Conclusions:** Inability to identify and treat additional canals that are very common in the MB root of maxillary first molar could lead to treatment failure.

**Keywords:** Root canal therapy, Maxillary first molar, Dental pulp cavity, Additional canals, Mesio buccal root

### \*Correspondence to

Masoumeh Ramezani,  
Dental Caries Prevention  
Research Center, Qazvin  
University of Medical  
Sciences, Bahonar Blvd.,  
Qazvin, Iran.  
Tel: +98-28 33353064,  
Fax: +98-28 33353066,  
Email:  
m269\_ramezani@yahoo.com

Received February 1, 2018

Accepted March 5, 2018

Published March 15, 2018



**Citation:** Karkehabadi H, Ramezani M, Samiei H. A successful root canal therapy of a maxillary first molar with 3 separate root canals in the mesio buccal root: case report. *Avicenna J Dent Res.* 2018;10(1):31-34. doi: 10.15171/ajdr.2018.07.

### Introduction

The knowledge of the complexity of internal morphologic variations is of significant importance in treatment planning and endodontic therapy (1). A precise understanding of morphologic variations of root canal would help in decreasing the chance of missed canal during treatment and hence increased the success rate of treatment would be anticipated (2).

A major reason for root canal therapy failure is the existence of not detected extra roots or root canals (3). The maxillary first molar is so complex regarding root and canal morphology (4). The anatomy and morphology of the maxillary first molar have been reviewed over and over and the conclusion was that this tooth has various anatomic configurations (5). The upper permanent first molar usually has 3 or 4 canals (6), but many reports of more complex root canal system (e.g. 5 or more canals) can be found in the literature (1,5,6).

Some root canal systems have more complexity than others: a sample of this system is observed in the MB root of the permanent maxillary first molar (7-9). In all of the studies, the MB root canal of the permanent maxillary first molar is the most complex (6). Weine et

### Highlights

- ▶ Maxillary first molar with three distinct canal in mesio buccal root was successfully treated.
- ▶ Failure to locate additional canals in the mesio buccal root of maxillary molar is a major cause of failure in these teeth.

al (9) noticed that failures associated with the MB root of the permanent maxillary first molar will endanger the success of endodontic therapy. The MB canal space can vary from a simple, single canal to multiple canals with anastomoses or isthmus areas woven throughout the root length (10, 11). The most common anatomic variation in permanent maxillary first molar is the presence of a second MB (mesio palatal) canal (12). Weine et al (9) found that teeth with 4 canals were more frequent than those with 3 canals (51.5% versus 48.5%). The occurrence of MB2 is reported to be between 53%- to 93% in different studies (13). Besides these anatomic variations, a third MB canal (MB3) is rarely reported (14). Several studies have reported that the permanent maxillary first molar has 5 root canals, 3 of which were present in the MB root (15, 16). Kottoor et al (15, 17) reported root canal therapy

<sup>1</sup> Endodontics Department, Dentistry School, Hamedan University of Medical Sciences, Hamedan, Iran. <sup>2</sup>Dental Caries Prevention Research Center, Qazvin University of Medical Sciences, Qazvin, Iran. <sup>3</sup>Endodontics Department, Dentistry School, Qazvin University of Medical Sciences, Qazvin, Iran.

of permanent maxillary first molar using cone beam computed tomography (CBCT) that had 7 and 8 canals respectively.

Investigating root canal anatomy, Vertucci described an octoploid classification pattern (18-20).

To the best of our knowledge, the current case report is the first one reporting 3 distinct canals (Vertucci type VIII) in the mesiobuccal root of maxillary first molar in the Iranian population. The canals extended all the way to the apex separately with separate apical foramina that were determined by reading 3 separate working lengths confirmed by apex locator. DB and P roots had type I canal configuration that is the most predominant form.

### Case Presentation

A 50-year-old male patient referred to the department of Endodontics (Hamedan University of Medical Science, Hamedan, Iran) with a complaint of spontaneous dental pain on the left side of the face. On clinical examination, tooth 14 had a carious lesion and the adjacent teeth appeared intact. In spite of some bone loss around the tooth, periodontal probing was within normal limits due to gingival recession.

The pulp vitality testing revealed severe sensitivity to cold (Roeko Endo-Frost; Roeko, Langenau, Germany) and heat (using heated gutta-percha) and increased threshold in response to electronic pulp tester (Gentle Pulse; Parkell Inc., Edgewood, NY, USA) in comparison to the control teeth. No sensitivity to palpation and percussion was reported and tooth mobility was within normal physiologic limits.

The preoperative periapical radiograph exhibited a deep carious lesion in tooth 14 with severe bone loss distal to the tooth (Figure 1). The diagnosis was symptomatic irreversible pulpitis and normal periapical periodontium. The treatment plan was RCT, restoration and follow up of tooth 14.

After explaining the treatment procedure to the patient, an informed consent was obtained.

Following local infiltration of anesthetic solution (1.8 mL of 0.2% lidocaine with 1/80,000 epinephrine) (Darupakhsh, Tehran-Iran), rubber dam isolation was used. The carious lesion was removed using #2 round carbide bur in a low-speed handpiece and the access cavity was prepared with a long cylindrical diamond bur (837-014). Initially, the MB, DB and P canals was identified, then a careful probing with DG16 endodontic explorer (Hu-Friedy, Chicago, IL, USA) led to localization of MB2 canal and probing with #6 K-file (Mani Inc-Japan) in the groove between MB1 and MB2 canal, the third canal in the MB root was identified (Figure 2).

An apex locator (Root ZX, Morita, USA) was used to ensure that the third canal has been found and no perforation of the pulpal floor has occurred.

Initial working lengths of all five canals were provisionally determined by the electronic apex locator

(Root ZX-Morita-USA) and were confirmed by a radiograph (Figure 3). According to the obtained working lengths and the clinical appearance, it was revealed that 3 canals were present with 3 separate orifices and 3 separate apical foramina (Vertucci type VIII canal configuration).

Canals were instrumented using ProTaper rotary files (Dentsply, Maillefer, Ballaigues, Switzerland) and 5.25% NaOCl solution was employed for irrigation.

Apical preparation of the P canal was accomplished up to size F3 and in MB1, MB2, and MB3 up to F1 and in DB canal to F2, respectively. Coronal flaring was performed by SX Protaper rotary file.

Smear layer was removed using 10 mL of 17% EDTA for 1 minute followed by 10 mL of 5.25% NaOCl. After choosing the master apical gutta-percha cone, a radiograph image was taken and the root canals were obturated with gutta percha (Gapadent, China) and AH26 sealer (Dentsply –Maillefer, Ballaigues, Switzerland) in the lateral condensation technique. Cavit (Golchai, Iran) was used as a temporary coronal restoration (Figure 4). 400 mg Ibuprofen was prescribed (Loghman, Iran) every 6 hours for 2 to 3 days for the patient and he was referred to the restorative department for restorative treatment.

The patient remained asymptomatic and the periodontium was normal during the 3-month follow-up period (Figure 5).

### Discussion

The complexities and variation in dental anatomy play a critical role in endodontic therapy, therefore, special attention should be paid during treatment. In the permanent maxillary first molar, root canal aberration

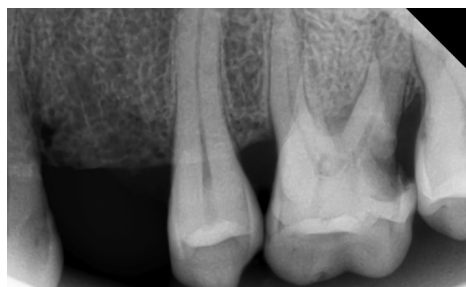

Figure 1. Initial Radiograph of the Left Maxillary First Molar.

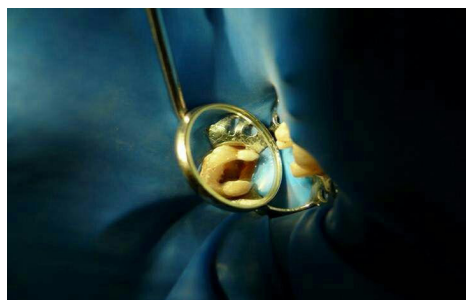


Figure 2. Three Orifices of the Mesiobuccal Canals.

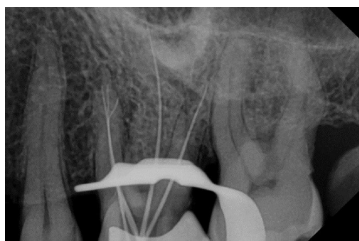


Figure 3. Radiograph for Determination of Working Length.

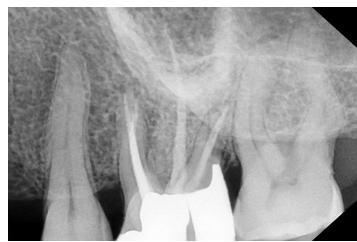


Figure 5. Three-Month Follow-up Radiographs.

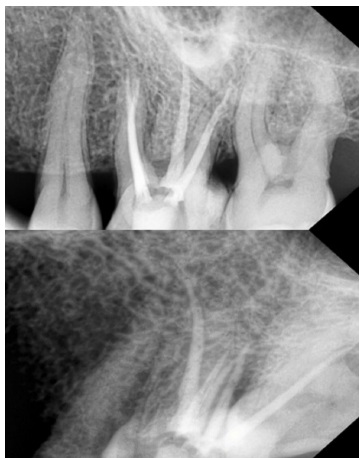

Figure 4. Post Obturation Radiograph.

is not uncommon and despite the fact that root canal therapy has achieved high success rates, the MB root is yet facing a substantial number of treatment failures owing to the difficulty of detecting and filling MB2 and/or MB3 canals (18,21,22). Among teeth referred for retreatment, the occurrence of missed roots or canals was reported to be 42% (23).

The occurrence of mesiopalatal canal in mesiobuccal root of permanent maxillary first molar has been reported to be between 53% to 93% but case reports of MB3 canal are so rare in the literature (13). In a study on 140 extracted maxillary first molars, only one had 3 canals in the mesiobuccal root (24).

Racial diversity must be regarded in the evaluation of the anatomy and morphology of human dentition (25). In a study on the Iranian population by Rouhani et al (26), all canal systems of Vertucci's classification were observed in the mesiobuccal root of the permanent maxillary first molar except 3 distinct canals (type VIII) and the most prevalent form of canal system was type I (46.4%). In another study by Naseri et al (27), the dominant canal configuration in mesiobuccal root of maxillary first molar was type VI (34.8% female, 36.8% male) followed by type II, I, IV and V. Type VII and VIII root canal systems were not noticed. In a systematic review by Naseri et al (25) the most common canal configuration in the mesiobuccal root of maxillary first molar was type I (38.55%) followed by type II, IV, V and III. The occurrence of 3 distinct canals (type VIII) in the mesiobuccal root of maxillary

first molar was reported to be 0%.

A study by Goga et al (28) indicated the limitation of conventional radiography in creating two-dimensional images of the tooth and superimposition of roots and canals in multi-rooted teeth which leads to difficulty in detecting additional canals. Therefore, multiple-angled radiographs before, during and after treatment are needed to facilitate observation of the canals (15, 17). Recently, CBCT is employed to detect anatomic variation and additional canals (29).

Generally, use of the surgical operating microscope (SOM) and/or loops in different clinical studies has increased the localization of MB2 (6), however, identification of the MB3 canal reported in the current study was made without SOM.

The furcation concavity of the MB root leads to small thickness of dentine in that area (30), therefore, the clinician should be careful while preparing MB canals particularly MB2 and MB3 to avoid strip perforation or upcoming fracture (31).

Removal of smear layer is an important step in the process of cleaning root canals especially in necrotic cases (32). The impact of irrigation using 5.25% NaOCl and 17% EDTA is proven in eliminating the smear layer, cleaning inaccessible canal surfaces that the endodontic instruments cannot reach and allowing the flow-back of sealer in the dentinal tubules (33).

## Conclusions

This case report highlights this important point that clinicians must always have the diversity of root canal morphology in their mind. Inability to identify and treat additional canals that are not unusual in MB root of maxillary first molar would lead to treatment failure.

## Authors' Contribution

Study concept and design: HK and MR. Analysis and interpretation of data: MR and HS. Drafting of the manuscript: MR. Critical revision of the manuscript for important intellectual content: HK, MR and HS. Statistical analysis: HS.

## Ethical Statement

Informed consent was obtained from the patient for being included in this study.

## Conflict of Interest Disclosures

The authors declare that they have no conflict of interests.

## References

1. Badole GP, Warhadpande MM, Shenoi PR, Lachure C, Badole SG. A rare root canal configuration of bilateral maxillary first molar with 7 root canals diagnosed using cone-beam computed tomographic scanning: a case report. *J Endod.* 2014;40(2):296-301. doi: [10.1016/j.joen.2013.09.004](https://doi.org/10.1016/j.joen.2013.09.004).
2. Ahmed HM, Abbott PV. Accessory roots in maxillary molar teeth: a review and endodontic considerations. *Aust Dent J.* 2012;57(2):123-31; quiz 248. doi: [10.1111/j.1834-7819.2012.01678.x](https://doi.org/10.1111/j.1834-7819.2012.01678.x).
3. Slowey RR. Radiographic aids in the detection of extra root canals. *Oral Surg Oral Med Oral Pathol.* 1974;37(5):762-72.
4. Degerness RA, Bowles WR. Dimension, anatomy and morphology of the mesiobuccal root canal system in maxillary molars. *J Endod.* 2010;36(6):985-9. doi: [10.1016/j.joen.2010.02.017](https://doi.org/10.1016/j.joen.2010.02.017).
5. Ma L, Yu J, Sun JJ. [Maxillary first molar with three mesiobuccal root canals: a case report]. *Hua Xi Kou Qiang Yi Xue Za Zhi.* 2011;29(1):102-3.
6. Cleghorn BM, Christie WH, Dong CC. Root and root canal morphology of the human permanent maxillary first molar: a literature review. *J Endod.* 2006;32(9):813-21. doi: [10.1016/j.joen.2006.04.014](https://doi.org/10.1016/j.joen.2006.04.014).
7. Alrahabi M, Sohail Zafar M. Evaluation of root canal morphology of maxillary molars using cone beam computed tomography. *Pak J Med Sci.* 2015;31(2):426-30. doi: [10.12669/pjms.312.6753](https://doi.org/10.12669/pjms.312.6753).
8. Vertucci FJ. The endodontic significance of the mesiobuccal root of the maxillary first molar. *US Navy Med.* 1974;63(5):29-31.
9. Weine FS, Healey HJ, Gerstein H, Evanson L. Canal configuration in the mesiobuccal root of the maxillary first molar and its endodontic significance. *Oral Surg Oral Med Oral Pathol.* 1969;28(3):419-25.
10. Schilder H. Filling root canals in three dimensions. *Dent Clin North Am.* 1967;7:23-44.
11. Schilder H. Cleaning and shaping the root canal. *Dent Clin North Am.* 1974;18(2):269-96.
12. Hiebert BM, Abramovitch K, Rice D, Torabinejad M. Prevalence of Second Mesiobuccal Canals in Maxillary First Molars Detected Using Cone-beam Computed Tomography, Direct Occlusal Access, and Coronal Plane Grinding. *J Endod.* 2017;43(10):1711-5. doi: [10.1016/j.joen.2017.05.011](https://doi.org/10.1016/j.joen.2017.05.011).
13. Bhargav K, Ravichandra R, Jyothi M, Charan Teja GV. Management of anatomical aberrations in maxillary first molars. *Int J Contemp Med Res.* 2017;4(2):387-9.
14. Nayak G, Singh KK, Shekhar R. Endodontic management of a maxillary first molar with three roots and seven root canals with the aid of cone-beam computed tomography. *Restor Dent Endod.* 2015;40(3):241-8. doi: [10.5395/rde.2015.40.3.241](https://doi.org/10.5395/rde.2015.40.3.241).
15. Kottoor J, Velmurugan N, Sudha R, Hemamalathi S. Maxillary first molar with seven root canals diagnosed with cone-beam computed tomography scanning: a case report. *J Endod.* 2010;36(5):915-21. doi: [10.1016/j.joen.2009.12.015](https://doi.org/10.1016/j.joen.2009.12.015).
16. Ferguson DB, Kjar KS, Hartwell GR. Three canals in the mesiobuccal root of a maxillary first molar: a case report. *J Endod.* 2005;31(5):400-2.
17. Kottoor J, Velmurugan N, Surendran S. Endodontic management of a maxillary first molar with eight root canal systems evaluated using cone-beam computed tomography scanning: a case report. *J Endod.* 2011;37(5):715-9. doi: [10.1016/j.joen.2011.01.008](https://doi.org/10.1016/j.joen.2011.01.008).
18. Vertucci FJ. Root canal anatomy of the human permanent teeth. *Oral Surg Oral Med Oral Pathol.* 1984;58(5):589-99.
19. Vertucci FJ, Gegauff A. Root canal morphology of the maxillary first premolar. *J Am Dent Assoc.* 1979;99(2):194-8.
20. Vertucci FJ. Root canal morphology of mandibular premolars. *J Am Dent Assoc.* 1978;97(1):47-50.
21. Favieri A, Barros FG, Campos LC. Root canal therapy of a maxillary first molar with five root canals: case report. *Braz Dent J.* 2006;17(1):75-8. doi: [10.1590/S0103-64402006000100017](https://doi.org/10.1590/S0103-64402006000100017).
22. Fogel HM, Peikoff MD, Christie WH. Canal configuration in the mesiobuccal root of the maxillary first molar: a clinical study. *J Endod.* 1994;20(3):135-7. doi: [10.1016/s0099-2399\(06\)80059-2](https://doi.org/10.1016/s0099-2399(06)80059-2).
23. Hoen MM, Pink FE. Contemporary endodontic retreatments: an analysis based on clinical treatment findings. *J Endod.* 2002;28(12):834-6. doi: [10.1097/00004770-200212000-00010](https://doi.org/10.1097/00004770-200212000-00010).
24. Neelakantan P, Subbarao C, Ahuja R, Subbarao CV, Gutmann JL. Cone-beam computed tomography study of root and canal morphology of maxillary first and second molars in an Indian population. *J Endod.* 2010;36(10):1622-7. doi: [10.1016/j.joen.2010.07.006](https://doi.org/10.1016/j.joen.2010.07.006).
25. Naseri M, Kharazifard MJ, Hosseinpour S. Canal Configuration of Mesiobuccal Roots in Permanent Maxillary First Molars in Iranian Population: A Systematic Review. *J Dent (Tehran).* 2016;13(6):438-47.
26. Rouhani A, Bagherpour A, Akbari M, Azizi M, Nejat A, Naghavi N. Cone-beam computed tomography evaluation of maxillary first and second molars in Iranian population: a morphological study. *Iran Endod J.* 2014;9(3):190-4.
27. Naseri M, Safi Y, Akbarzadeh Baghban A, Khayat A, Eftekhar L. Survey of Anatomy and Root Canal Morphology of Maxillary First Molars Regarding Age and Gender in an Iranian Population Using Cone-Beam Computed Tomography. *Iran Endod J.* 2016;11(4):298-303. doi: [10.22037/iej.2016.8](https://doi.org/10.22037/iej.2016.8).
28. Goga R, Chandler NP, Oginni AO. Pulp stones: a review. *Int Endod J.* 2008;41(6):457-68. doi: [10.1111/j.1365-2591.2008.01374.x](https://doi.org/10.1111/j.1365-2591.2008.01374.x).
29. Pais ASG, Fontana CE, De Martin AS, de Carvalho EB, Bueno CEDS. Location of three canals in the mesiobuccal root of the maxillary first molar. *Rev Sul-bras Odontol.* 2012;9(3):322-7.
30. de Freitas JV, Baratto-Filho F, Coelho BS, Tomazinho FSF, Crozeta BM, de Sousa Neto MD, et al. Efficacy of Different Cone-beam Computed Tomographic Protocols in the Identification of Mesiobuccal Canals of Maxillary First Molars: A Tomographic and Ex Vivo Study. *J Endod.* 2017;43(5):810-5. doi: [10.1016/j.joen.2016.12.011](https://doi.org/10.1016/j.joen.2016.12.011).
31. Yoshioka T, Kikuchi I, Fukumoto Y, Kobayashi C, Suda H. Detection of the second mesiobuccal canal in mesiobuccal roots of maxillary molar teeth ex vivo. *Int Endod J.* 2005;38(2):124-8. doi: [10.1111/j.1365-2591.2004.00918.x](https://doi.org/10.1111/j.1365-2591.2004.00918.x).
32. Ballal NV, Varghese J. Smear layer removal from root canal system. *Saudi Endod J.* 2017;7(3):204. doi: [10.4103/sej.sej\\_31\\_17](https://doi.org/10.4103/sej.sej_31_17).
33. Calt S, Serper A. Time-dependent effects of EDTA on dentin structures. *J Endod.* 2002;28(1):17-9. doi: [10.1097/00004770-200201000-00004](https://doi.org/10.1097/00004770-200201000-00004).