

Scientific Foundation SPIROSKI, Skopje, Republic of Macedonia  
 Open Access Macedonian Journal of Medical Sciences. 2020 Feb 05; 8(C):52-54.  
<https://doi.org/10.3889/oamjms.2020.4199>  
 eISSN: 1857-9655  
 Category: C - Case Reports  
 Section: Case Report in Internal Medicine



# Disseminated Melioidosis Presenting with Community-Acquired Pneumonia: A Presentation Not to be Missed – A Case Report

Shaun Wayn Paul<sup>1</sup>, Khasnur Abd Malek<sup>1\*</sup>, Alan Basil Peter<sup>2</sup>, Sabrihahakim Sidek<sup>2</sup>

<sup>1</sup>Department of Primary Care Medicine, Faculty of Medicine, Universiti Teknologi MARA, Selayang Campus, Jalan Prima Selayang 7, 68100 Batu Caves, Selangor, Malaysia; <sup>2</sup>Department of Radiology, Faculty of Medicine, Universiti Teknologi MARA, Sungai Buloh Campus, Jalan Hospital, 47000 Sungai Buloh, Selangor, Malaysia

## Abstract

**BACKGROUND:** Melioidosis commonly presents with pneumonia and is associated with a high mortality rate. This case report discussed a case of confirmed disseminated melioidosis. The case focused on the chronological clinical progressions of melioidosis which initially masqueraded as community-acquired pneumonia (CAP) and subsequently developed into septicemia. This case report aims to create awareness among the primary care doctors working in a potentially endemic area for melioidosis to be vigilant of its non-specific presentation.

**CASE REPORT:** We report a case of an 80-year-old man who was treated for CAP and presented with unresolved fever and subsequently sepsis. A contrast-enhanced computed tomography showed disseminated lesions of varying sizes in the lungs, liver, spleen, and blood cultures grew *Burkholderia pseudomallei*. A pigtail drainage catheter was inserted into the liver abscess. In addition, the patient received a 46-day course of intravenous ceftazidime and a 4-month maintenance regime of oral trimethoprim-sulfamethoxazole and oral doxycycline.

**CONCLUSION:** Completion of antimicrobial treatment resulted in resolution of clinical signs and abscesses on imaging.

**Edited by:** Igor Spiroski  
**Citation:** Paul SW, Malek KA, Peter AB, Sidek S. Disseminated Melioidosis Presenting with Community-Acquired Pneumonia: A Presentation Not to be Missed – A Case Report. Open Access Maced J Med Sci. 2020 Feb 05; 8(C):52-54. <https://doi.org/10.3889/oamjms.2020.4199>  
**Keywords:** Disseminated melioidosis; Pneumonia; Abscesses; Sepsis  
**\*Correspondence:** Khasnur Abd Malek, Department of Primary Care Medicine, Faculty of Medicine, Universiti Teknologi MARA, Selayang Campus, Jalan Prima Selayang 7, 68100 Batu Caves, Selangor, Malaysia. Mobile: +6012-6448367. Fax: +603-61264888. E-mail: drkhasnurabdmalek@gmail.com  
**Received:** 16-Dec-2019  
**Revised:** 09-Jan-2020  
**Accepted:** 29-Jan-2020  
**Copyright:** © 2020 Shaun Wayn Paul, Khasnur Abd Malek, Alan Basil Peter, Sabrihahakim Sidek  
**Funding:** This research did not receive any financial support  
**Competing Interest:** The authors have declared that no competing interest exists  
**Open Access:** This is an open-access article distributed under the terms of the Creative Commons Attribution-NonCommercial 4.0 International License (CC BY-NC 4.0)

## Introduction

Melioidosis is a clinical disease caused by *Burkholderia pseudomallei*. It is a great mimicker of many clinical conditions and commonly presents as community-acquired pneumonia (CAP) [1]. This is worrying as melioidosis presenting with pneumonia is associated with a high mortality rate. Since CAP is a common condition managed in primary care, it is imperative for the doctors to understand the clinical presentation of melioidosis presenting with pneumonia. Early recognition of melioidosis is the cornerstone of management as timely diagnosis and treatment are crucial in preventing mortality. We report a case of melioidosis which presented as CAP and subsequently developed sepsis.

## Case Report

An 80-year-old man with controlled diabetes mellitus (HbA1c = 5.8%) and hypertension was brought

to the emergency department due to unresolved high-grade fever of 4 weeks. One month ago, he was treated for CAP in an outpatient setting. He presented with fever, dyspnea, and cough and clinical examination showed minimal crackles in both his lung bases, with a normal chest X-ray and blood investigations. Despite completing 7 days of oral amoxicillin/clavulanate and 3 days of azithromycin, his symptoms persisted. There were no symptoms to suggest other sources of infection. At week 4 of illness, his symptoms worsened.

On admission, he was toxic looking. His temperature was 38.8°C, blood pressure was 139/95 mmHg, respiratory rate was 16 breaths per minute, and heart rate was 100 beats per minute and oxygen saturation was 97% on room air. There were coarse bibasal crackles. Other systemic examinations were not significant. Initial blood investigations showed a white cell count of  $12.9 \times 10^9/L$  and C-reactive protein (CRP) of 160 mg/dL, with normal hemoglobin, platelet, and supine chest radiograph findings. Blood cultures were sent. Serological screening for hepatitis B and C virus and human immunodeficiency virus were negative. A working diagnosis of partially treated pneumonia was made and intravenous tazocin 4.5 g

QID was commenced. Despite this, he remained febrile at 38.0–39.1°C.

The patient's clinical condition worsened 3 days later. Blood investigations revealed white cell count of  $14.9 \times 10^9/L$ , CRP of 210 mg/dL, and platelet of  $66 \times 10^9/L$ . Intravenous noradrenaline was initiated for a hypotensive episode. Now, his blood culture grew Gram-negative bacilli, identified as *B. pseudomallei*. His antibiotic was changed to intravenous ceftazidime 2 g TDS. Over 2 days, his fever resolved and his clinical findings improved.

Initial investigation with an abdominal ultrasound revealed an ovoid hypoechoic lesion with minimal solid components and no significant internal vascularity in segment VI of the liver, which measured 3.5 cm × 4.4 cm × 3.7 cm. Figure 1 illustrates the hypoechoic lesion within the liver.

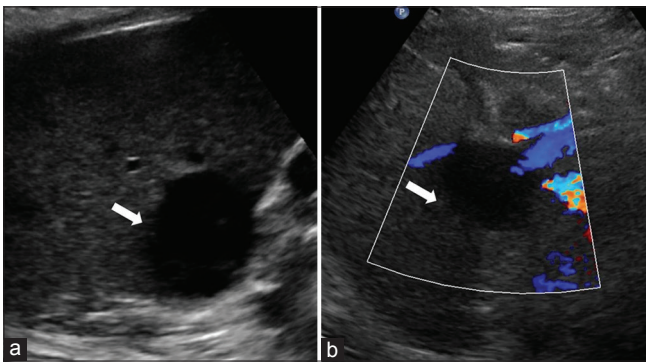


Figure 1: Ultrasound images (axial view) of the liver showing a segment VI liver abscess (bold white arrows) with minimal solid components within

Subsequently, a contrast-enhanced computed tomography (CT) of the thorax, abdomen, and pelvis showed disseminated abscesses of varying sizes in the liver and spleen with cavitation in the right lung. The largest abscess was in segment VI liver, which measured 3.9 cm × 2.8 cm × 4.3 cm. Multiple small abscesses were observed in the spleen. Small cavitating lesions were seen in the upper and middle lobes of the right lung, with

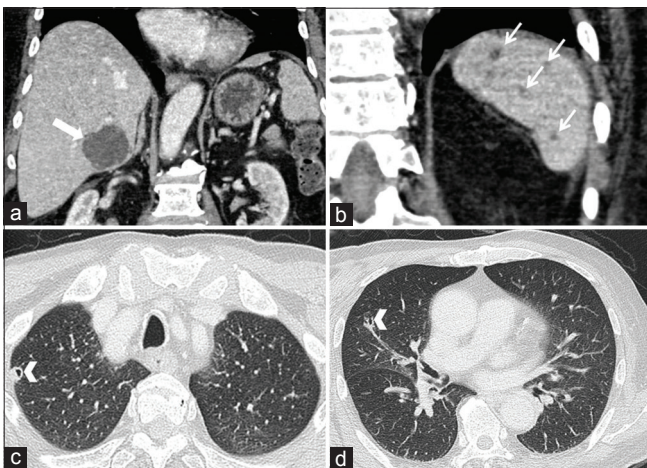


Figure 2: (a) Contrast-enhanced computed tomography scan of the abdomen revealed a segment VI liver abscess (bold white arrow), (b) with multiple small abscesses in the spleen (narrow white arrows). (c and d) Cavitating lung lesions were observed in the upper and middle lobes of the right lung (arrowheads)

the largest measuring 0.8 cm × 0.9 cm. Figure 2 illustrates the findings of the CT thorax, abdomen, and pelvis.

A pigtail drainage catheter insertion into the liver abscess yielded thick yellowish pus. He completed 46 days of intravenous ceftazidime and 4-month maintenance regime of oral trimethoprim-sulfamethoxazole and oral doxycycline. The latest ultrasound of the abdomen showed resolving liver abscess, with a size of 1.1 cm × 1.1 cm (Figure 3).

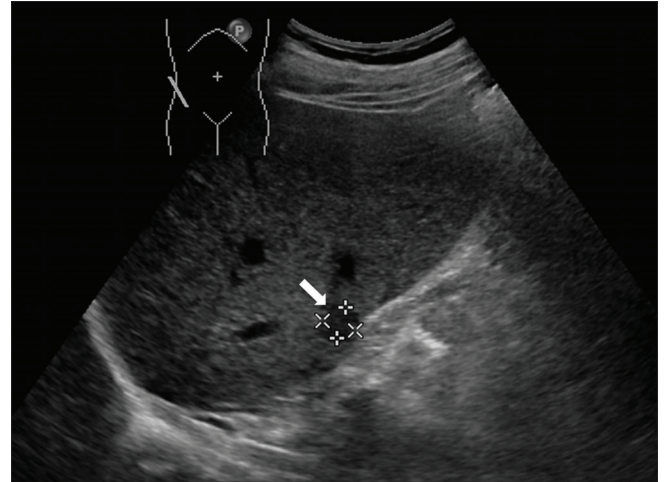


Figure 3: Axial view of an ultrasound image of the liver which showed almost complete resolution of the segment VI abscesses (bold white arrow) following administration of intravenous ceftazidime and percutaneous drainage

The patient had a complete resolution of symptoms and is currently well and healthy.

## Discussion

Melioidosis is an infectious disease caused by the environmental saprophyte *B. pseudomallei*, a Gram-negative bacillus. It is endemic in the South and Southeast Asian region [2]. Melioidosis infection is not a notifiable disease, hence, its exact true incidence worldwide is not known. Locally, reports have identified many cases originating from the southern state of Malaysia [3] as well as in Kuala Lumpur [1]. This case report illustrates a case of disseminated melioidosis with positive blood culture and multiple abscesses within internal organs.

Melioidosis may display a wide array of clinical features, ranging from asymptomatic to clinical conditions such as pneumonia, encephalomyelitis, musculoskeletal-related infections, and genitourinary infections [2]. Indeed, the lungs are the most commonly affected organ in patients with melioidosis [4], [5]. Upper lobe involvement is the most common, classical radiological finding in melioidosis presenting with pneumonia and has been frequently reported [4], [5]. So much so, that when a case of upper lobe pneumonia is identified within a melioidosis endemic area, physicians should consider melioidosis as one of

their differential diagnoses [6]. Patients with melioidosis presenting with acute or subacute pneumonia tend to deteriorate due to the development of bacteremia and subsequently septic shock. These findings are similar to the clinical presentation and progression of our patient. In our case, the right upper lobe and middle lobe cavitating lesions (Figure 2) were shown on CT scan but were not seen on chest radiograph. This could be explained possibly by the small size of the lung lesions which may not be visualized on a chest radiograph. Furthermore, significant radiographic findings may be observed in the later stage of the illness [2].

This opportunistic organism, *B. pseudomallei*, tends to cause infection in those with diabetes mellitus and is the most common factor observed in Malaysia [7]. Other medical conditions such as chronic kidney disease and excessive alcohol consumption have also been implicated [2], [8]. Exposure to contaminated water or soil in an occupation related to the agriculture industry and to a smaller extent in farming, fishing, and forestry activities has also been reported [2], [5], [7], [8]. Our patient had two predisposing factors; an underlying immunocompromised state and a contact with possibly contaminated soil and freshwater. The former relates to his underlying diabetes mellitus and the latter accounts for the frequent fishing at an abandoned mining pool.

## Conclusion

This case highlights the need for the clinicians working in a potentially endemic area for melioidosis to be vigilant of its non-specific clinical presentation. When dealing with cases of CAP with upper lobe involvement, a high level of caution would need to be exercised during disease follow-up and monitoring.

## Acknowledgment

The authors would like to thank the infectious disease specialists and other multidisciplinary team

members from University Teknologi MARA, Malaysia, who were involved in the management of this patient while he was in the ward as well as in the outpatient setting. We would like to thank the patient for his consent.

## References

1. Kingsley PV, Leader M, Nagodawithana NS, Tipre M, Sathiakumar N. Melioidosis in Malaysia: A review of case reports. *PLoS Negl Trop Dis*. 2016;10(12):0005182. <https://doi.org/10.1371/journal.pntd.0005182>  
PMid:28005910
2. Cheng AC, Currie BJ. Melioidosis: Epidemiology, pathophysiology, and management. *Clin Microbiol Rev*. 2005;18(2):383-416. <https://doi.org/10.1128/CMR.18.2.383-416.2005>  
PMid:15831829
3. Pagalavan L. Melioidosis: The Johor Bahru experience. *Med J Malaysia*. 2005;60(5):599-605.  
PMid:16515111
4. Alsaif HS, Venkatesh SK. Melioidosis: Spectrum of radiological manifestations. *Saudi J Med Med Sci*. 2016;4(2):74-8. <https://doi.org/10.4103/1658-631X.178286>  
PMid:30787702
5. Meumann EM, Cheng AC, Ward L, Currie BJ. Clinical features and epidemiology of melioidosis pneumonia: Results from a 21-year study and review of the literature. *Clin Infect Dis*. 2012;54(3):362-9. <https://doi.org/10.1093/cid/cir808>  
PMid:22057702
6. Currie BJ. Melioidosis: An important cause of pneumonia in residents of and travellers returned from endemic regions. *Eur Respir J*. 2003;22(3):542-50. <https://doi.org/10.1183/09031936.03.0006203>  
PMid:14516149
7. Nathan S, Chieng S, Kingsley PV, Mohan A, Podin Y, Ooi MH, et al. Melioidosis in Malaysia: Incidence, clinical challenges, and advances in understanding pathogenesis. *Trop Med Infect Dis*. 2018;3(1):25. <http://doi.org/10.3390/tropicalmed3010025>  
PMid:30274422.
8. Karunarathna AK, Mendis SA, Perera WP, Patabendige G, Pallewatte AS, Kulatunga A. A case report of melioidosis complicated by infective sacroiliitis in Sri Lanka. *Trop Dis Travel Med Vaccines*. 2018;4(1):12. <https://doi.org/10.1186/s40794-018-0073-5>  
PMid:30250746.