


# Radiographic scoring systems for psoriatic arthritis are insufficient for psoriatic arthritis mutilans: results from the Nordic PAM Study

Acta Radiologica Open  
9(4) 1–8  
© The Foundation Acta  
Radiologica 2020  
Article reuse guidelines:  
sagepub.com/journals-permissions  
DOI: 10.1177/2058460120920797  
journals.sagepub.com/home/arr  


Leena Laasonen<sup>1</sup>, Ulla Lindqvist<sup>2</sup>, Lars Iversen<sup>3</sup>, Leif Ejstrup<sup>4</sup>,  
Thorarinn Jonmundsson<sup>5</sup>, Mona Ståhle<sup>6</sup> and  
Bjorn Gudbjornsson<sup>5</sup> 

## Abstract

**Background:** Psoriatic arthritis mutilans (PAM) is the most severe phenotype of psoriatic arthritis (PsA).

**Purpose:** To describe the radiological features in PAM and explore whether existing scoring systems for radiological damage in psoriatic arthritis are applicable for PAM.

**Material and Methods:** Radiographs were scored according to the modified Sharp-van der Heijde (mSvdH) and the Psoriatic Arthritis Ratingen Score (PARS) systems for PsA.

**Results:** At inclusion, 55 PAM patients (49% women, mean age  $58 \pm 12$  years) had conventional radiographs of both hands and feet. A total of 869 PAM joints were detected and 193 joints with ankylosis. The mean total mSvdH score was  $213.7 \pm 137.8$  (41% of maximum) with a higher score for hands than for feet:  $136.6 \pm 90.1$  vs.  $79.1 \pm 60.9$ . However, the total score was relatively higher in the feet than in the hands when compared to the highest possible scoring (47% vs. 38% of max). The mean total PARS score was  $126.3 \pm 79.6$  (35% of max). Scoring for joint destruction was higher than for proliferation (22% vs. 11% of max). Strong correlation was found between mSvdH and PARS ( $r^2 = 0.913$ ). A significant correlation was found between scoring and duration of arthritis and the Health Assessment Questionnaire. History of smoking, BMI, and gender did not influence the scoring values.

**Conclusions:** The two scoring systems studied may not be ideal to indicate progression of PAM in advanced disease since they reach ceiling effects rather early. Therefore, reporting early signs suggestive of PAM, e.g. signs of pencil-in-cup deformities or osteolysis, is crucial. This would reveal the presence of PAM and might lead to improved treatment in order to minimize joint damage.

## Keywords

Psoriatic arthritis, mutilans, psoriasis, radiology, scoring systems

Received 3 November 2019; accepted 29 March 2020

## Introduction

Psoriatic arthritis (PsA) belongs to a group of inflammatory joint disorders frequently associated with enthesitis and dactylitis (1). PsA is classified as spondyloarthritis (SpA), which also includes axial SpA (previously named ankylosing spondylitis), reactive arthritis, enteropathic arthritis associated with inflammatory bowel diseases, and other undifferentiated arthritides. The prevalence of PsA is reported to be in the range of 0.2%–0.3% in the Nordic countries (2,3), whereas up

<sup>1</sup>Helsinki Medical Imaging Center, Helsinki University Central Hospital, Helsinki, Finland

<sup>2</sup>Department of Medical Sciences, Rheumatology, Uppsala University, Uppsala, Sweden

<sup>3</sup>Department of Dermatology, Aarhus University Hospital, Aarhus, Denmark

<sup>4</sup>Department of Rheumatology, Odense University Hospital, Odense, Denmark

<sup>5</sup>Centre for Rheumatology Research, University Hospital and Faculty of Medicine, University of Iceland, Reykjavik, Iceland

<sup>6</sup>Dermatology Division, Department of Medicine, Karolinska Institutet, Stockholm, Sweden

## Corresponding author:

Bjorn Gudbjornsson, Centre for Rheumatology Research, University Hospital, Reykjavik, Iceland.

Email: bjorngu@landspitali.is



to 30% of patients with psoriasis may have significant joint and muscle complaints (4,5).

The clinical presentation of PsA is multiform and was described in detail 1973 by Moll and Wright in a classical paper where they reported phenotypic characteristics of patients with PsA (6). They presented five main subtypes: oligoarthritis with less than four peripheral joints involved; polyarthritis that may mimic rheumatoid arthritis (RA); isolated involvement of the distal interphalangeal joints in hands and feet; axial involvement with inflammation in the small joints and ligaments of the spine and the sacroiliac joints; and finally the most severe phenotype, psoriatic arthritis mutilans (PAM). The fact that PsA presents in multiple forms may be the main reason for the delay in diagnosis, which in turn may delay effective modifying treatment. Early diagnosis of PsA is essential for the future wellbeing of the patient (7).

Internationally accepted diagnostic criteria for PsA are essentially lacking. Most frequently, the criteria proposed by Moll and Wright are used to confirm the diagnosis of PsA. The Group for Research and Assessment of Psoriasis and Psoriatic Arthritis (GRAPPA) subsequently put forward the CASPAR criteria for classification in clinical trials but these criteria are rarely used in clinical practice (8). For PAM specifically, no definite consensus has been established (9).

Characteristic clinical features of PAM include digital shortening, digital telescoping, and flail joints. The radiographic features consist of osteolysis or extended bone resorption, pencil-in-cup changes, joint subluxation, and, in some cases, ankylosis (10). The most important and defining radiological feature is osteolysis, which has been defined as bone resorption with >50% loss of joint surface on both sides of the joint (11). Notably, involvement of one small joint in the hands or feet is considered sufficient for the diagnosis of PAM.

In the present study, we describe the radiological features in 55 patients with PAM from the Nordic PAM Study (12–14) and we also evaluate two different scoring systems for radiological damage in PsA, to test whether they are applicable for PAM.

## Material and Methods

### Patients

In the Nordic PAM Study, 67 patients were identified in Sweden, Denmark, Norway, and Iceland. The diagnosis of PAM was confirmed according to the clinical findings by experienced rheumatologists and dermatologists. All patients had at least one joint with severe radiological destruction. Extended clinical data have been reported on this patient group in two publications

**Table 1.** Demographic data of 55 patients with PAM in whom radiographs of hands and feet were available for evaluation.

	PAM patients included in present study (n = 55)
Gender (female/male) (n)	27/28
Mean age (years)	58 ± 12
Age at onset of Pso (years)	26 ± 15
Age at onset of PsA (years)	32 ± 15
Disease duration Pso (years)	32 ± 15
Disease duration PsA (years)	27 ± 13
HAQ	0.96 ± 0.78
CRP (mg/L)	7.1 ± 9.0
BMI (kg/m <sup>2</sup> )	25.8 ± 5.8

Values are given as mean ± SD unless otherwise specified. BMI, body mass index; CRP, C-reactive protein; HAQ, Health Assessment Questionnaire; PAM, psoriatic arthritis mutilans; PsA, psoriatic arthritis; Pso, psoriasis.

(12,14). Complete plain radiographs of both hands and feet were available for evaluation in 55/67 patients; these 55 individuals constitute the patient population of the present study (Table 1).

### Collecting of radiographs

All radiographs were transferred digitally and collected at the Helsinki Medical Imaging Center where an experienced radiologist (LL), unaware of the demography of the individual patients, scored all radiographs. Among available scoring instruments, the Sharp-van der Heijde modified scoring method for PsA (mSvdH) (15,16) and the Psoriatic Arthritis Ratingen Score (PARS) (16) were applied. Mainly posterior–anterior projections were used, but in very deformed joints other projections could also be included when available.

### Radiographic assessment

The mSvdH method is based on assessing erosions and joint space narrowing in RA (16), but when applied for PsA also includes the distal interphalangeal joints (DIP) of the hands. Thus, the joint assessment for PsA includes 40 joints in the hands and 12 joints in the feet. Erosions are graded on a scale of 0–5 in the hands and 0–10 in the feet. Joint space narrowing is graded on a scale of 0–4. Thus, the maximum score for erosions is 200 for the hands and 120 for the feet, and for joint space narrowing 160 for the hands and 48 for the feet. The maximum scores are 320 for erosions, 208 for joint space narrowing, and therefore 528 points for the total score. Thus, maximum scores calculated for the hands and feet separately are 360 versus 168.

The PARS scoring method was developed specifically for the radiographic assessment of PsA (16,17).

In the hand, DIPs, thumb interphalangeal (IP) joint, proximal interphalangeal (PIP) joints, metacarpophalangeal (MCP) joints, wrists, and in the feet IP joints of the great toe, and metatarsophalangeal (MTP) joints II–V are assessed for destruction (destruction score [DS]) on a 6-point scale and proliferation (proliferation score [PS]) on a 5-point scale. The maximum DS score for the hands are 150 and for the feet 50, and the maximum PS is 120 for the hands and 40 for the feet. The combined maximum scores are thus 200 for DS and 160 for PS, with a total score of 360 for each patient.

### Correlation with clinical parameters

The total scores of mSvdH and PARS were also correlated to various clinical characteristics such as gender, duration of arthritis, the Health Assessment Questionnaire (HAQ), body mass index (BMI), and history of smoking.

### Data analysis

The data were processed and analyzed using R version 3.6.1 and RStudio version 1.2.1335 on a machine running Linux Mint 19.1 Tessa. The R package version 1.2.1 was used to read the data into RStudio, process it, and compute the sample mean of the variables of interest along with their sample SD. Furthermore, all plots based on the processed data were generated with R package ggplot2 version 3.2.1.

To determine the sample correlation between two variables and test the significance of the relationship, base R functions `cor` and `cor.test` were applied. The significance test of choice was the two-tailed Pearson's correlation test. The null hypothesis of such a test is that correlation between two variables is 0 and its test statistic is t-distributed.

Lastly, simple linear regression was performed on variables total mSvdH and total PARS, with total PARS as the dependent variable. As the regression was simple, the coefficient of determination  $r^2$ , which measures the proportion of variance in total PARS explained by total mSvdH, was reduced to the square of the correlation between total PARS and total mSvdH.

### Ethical issues

Written informed consent was obtained from all participants in the study. Bioethics Committees and Data Protection Authorities in all four countries approved the study protocol.

## Results

### Patient population

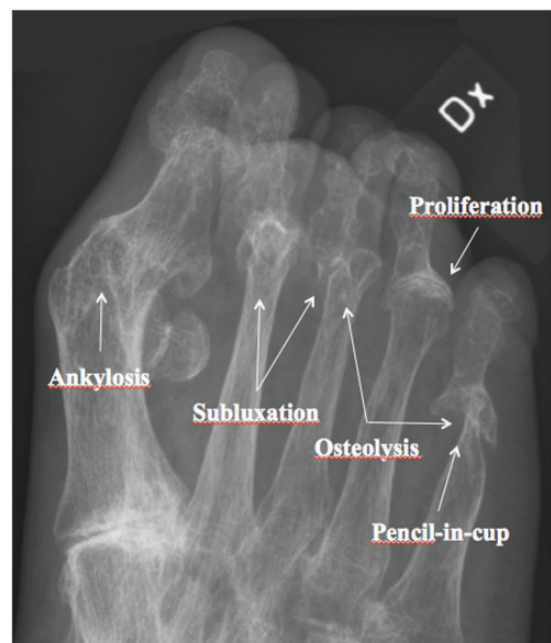Fifty-five patients with PAM (27 women, 28 men; mean age =  $58 \pm 12$  years) in the Nordic PAM Study had conventional radiographs of both hands and feet at the time point of inclusion in the study. Age, gender difference, and disease duration of psoriasis (Pso) and PsA (Table 1) were almost identical in the present study group as for the whole Nordic PAM Study group (12,14). Most patients ( $n = 51$ ) suffered from polyarticular disease, three had oligoarthritis, and one patient suffered from mono-articular disease.

Fig. 1 illustrates an example of the most common feature of PAM: osteolysis, pencil-in-cup, subluxation, proliferation and ankylosis, which may all be present in the same patient. In addition, Fig. 2 demonstrates the clinical and radiographic findings for another patient.

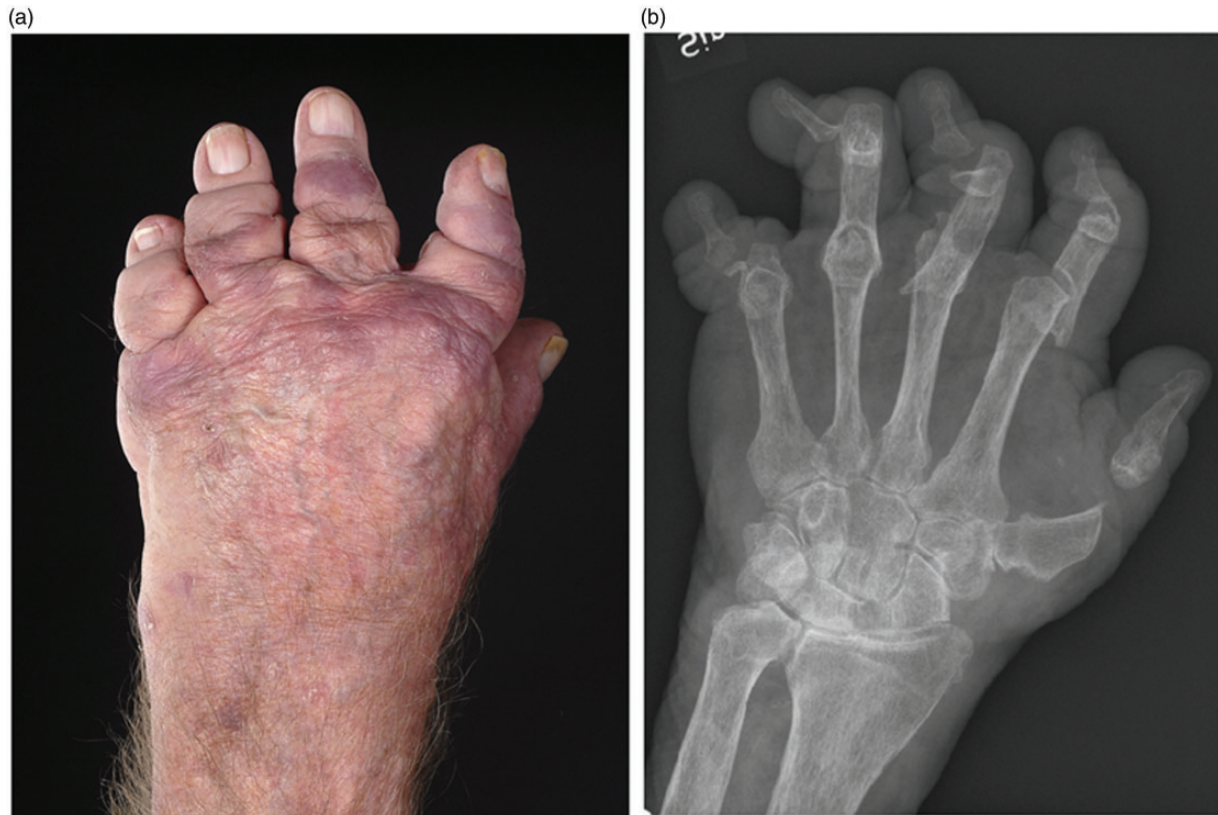### Results from mSvdH score

The mean total score evaluated by mSvdH was  $213.7 \pm 137.4$ ; that is, 41.4% of the highest possible score of 528 (Fig. 3). The total scores in the hands were higher than in the feet ( $136.6 \pm 90.1$  vs.  $79.1 \pm 60.9$ ) but when the scores were expressed as a percent of the possible maximum scores, the reverse was seen (37.8% of max scoring of 360 vs. 47.1% of 168).

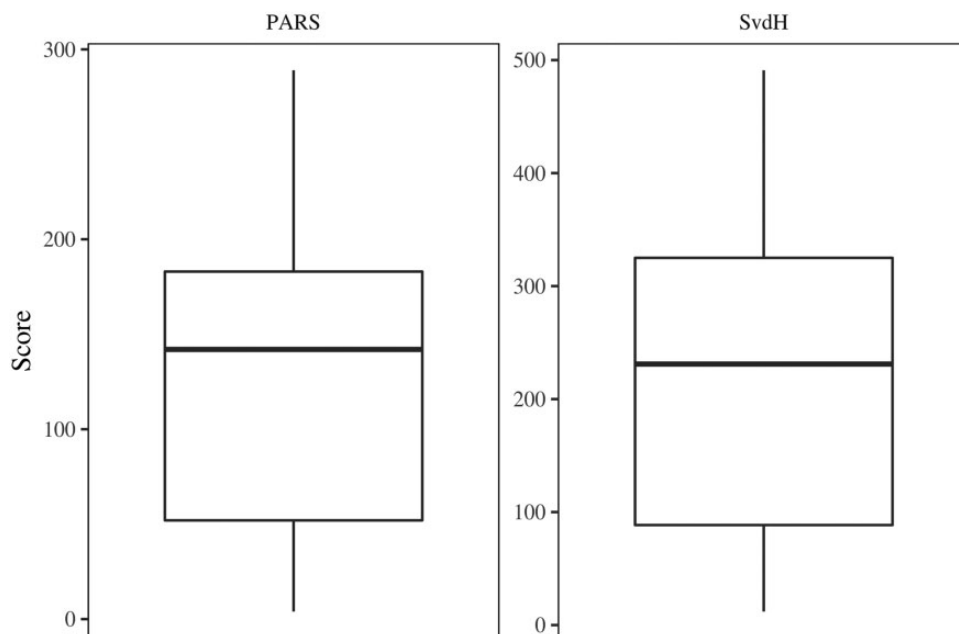
The number of joints that received maximal scores due to gross osteolysis and/or pencil-in-cup deformities



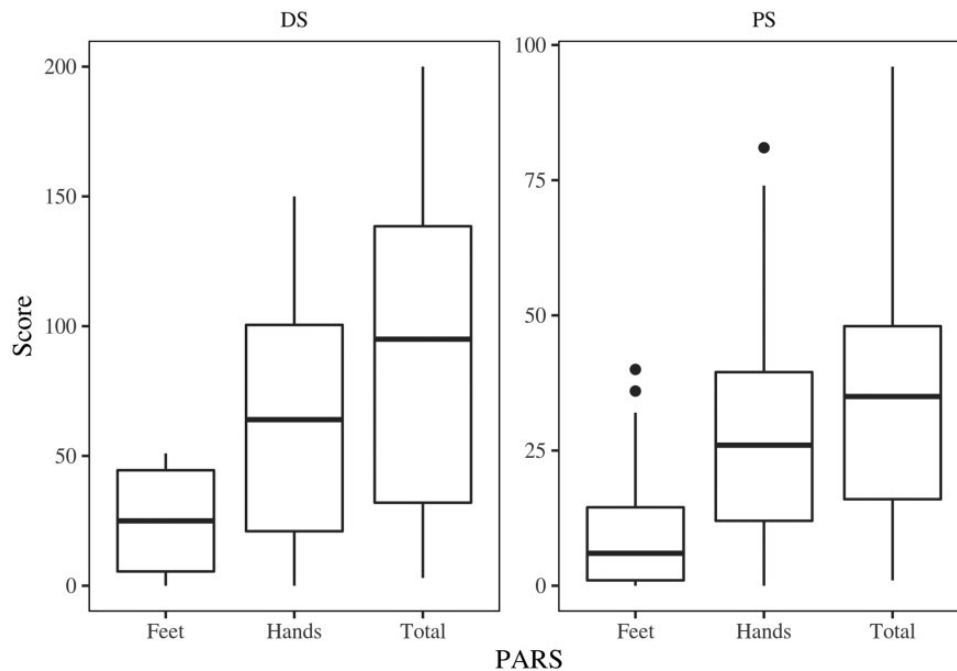
**Fig. 1.** Radiography of a 66-year-old female patient with psoriatic arthritis mutilans with a history psoriatic arthritis of 27 years with all the five classical sign of arthritis mutilans.



**Fig. 2.** A 66-year-old man with a 32-year history of PAM. His hands show classical sign of severe PAM deformity with shortening or digital telescoping of his fingers with flail joints (left), and the radiograph (right) shows profound osteolysis in several joints and pencil-in-cup deformities (MCP IV) of his hand with relative sparing changes of his wrists and no sign of ankylosis. PAM, psoriatic arthritis mutilans.



**Fig. 3.** Distribution of the total scores in 55 patients with PAM in the Nordic PAM study, evaluated by mSvdH (maximum scoring 360) and PARS (maximum scoring of 528) scoring systems for radiologic changes in hands and feet. The scores are shown in correlation to the highest possible score. PAM, psoriatic arthritis mutilans.



**Fig. 4.** Distribution of total Psoriatic Arthritis Ratingen Score in 55 patients with PAM in the Nordic PAM study; scores for destruction (max scores 200) and proliferation (max scores 160) for hands and feet are given separately. The scores are shown in correlation to the highest possible score. PAM, psoriatic arthritis mutilans.

was 306, of which 194 joints were found with classical pencil-in-cup deformity: 98 in the hands and 96 in the feet in 38 patients.

### Results from PARS

When evaluated according to PARS, the mean total score was  $126.3 \pm 79.6$  (max scoring = 360), or 35.1% of the highest possible scoring (Fig 3). In general, the PARS for destruction (DS) and proliferation (PS) are presented separately, in addition to the total score. There were higher scores for DS than for PS or  $44.8 \pm 39.2$  (22.4% of maximum 200) vs.  $18.3 \pm 19.1$  (11.4% of 160)

The scores were assessed for both destruction and proliferation for hands and feet separately. The DS in the hands was  $63.9 \pm 44.5$ , reflecting 42.5% of the maximal score of 150. The PS was  $28.3 \pm 21.1$  (23.6% of 120) and the total score was  $92.2 \pm 63.2$  (34.1% of 270). In the feet, DS was  $25.7 \pm 19.1$  (51.4% of 50), PS  $8.4 \pm 9.1$  (21.1% of 40), and the total score was  $34.1 \pm 26.0$  (34.9% of 90) (Fig. 4).

Fig. 5 demonstrates the correlation ( $r = 0.956$ ;  $P < 0.0001$ ) between the total scores of mSvdH and PARS in 55 patients with PAM and the total score of PARS was explained 91% by mSvdH ( $R = 913$ ).

### Correlation with clinical parameters

A significant correlation was found between the radiological severity of the disease by both scoring methods

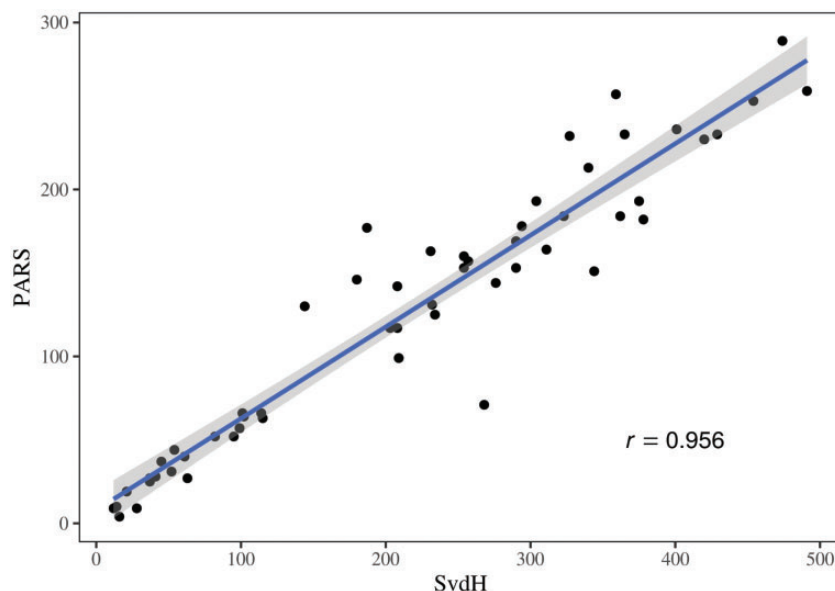
(mSvdH and PARS) and the duration of arthritis and the patient's age at onset of arthritis. The duration of psoriasis showed a higher correlation with PARS than with the mSvdH score. A significant correlation was also found between both scoring methods and the HAQ score (Table 2).

The mean mSvdH scores were found also to be similar in non-smokers ( $n = 32$ ; mSvdH =  $181.4 \pm 110$ ), in patients who had stopped smoking ( $n = 14$ ;  $204.1 \pm 147$ ), and in current smokers ( $n = 9$ ;  $169.0 \pm 85$ ). A weak correlation was observed with C-reactive protein (CRP) with both scoring systems but was only significant for PARS (Table 2). No correlation was found with the patient's age at the time of the study, or with the age at onset of psoriasis, BMI, or gender.

In addition to the joints included in the scoring systems, all peripheral joints, including the DIP and PIP joints of the feet, were analyzed for the presence of resorption of >50% of the joint surface on both sides of the joint space ("PAM joints") and ankylosis. A total of 869 PAM joints with >50% resorption were detected (28% of all examined joints; Table 3) and 193 joints with ankylosis; 112 (7.3%) in the hands and 78 (5.1%) in the feet. In addition, 74 operated joints were found in the small joints of hands and feet in these 55 patients with PAM.

### Discussion

In the present study, we have reviewed individual radiographs of patients participating in the Nordic



**Fig. 5.** The correlation between the Sharp-van der Heijde modified scoring method for psoriatic arthritis and Psoriatic Arthritis Ratingen Score in 55 patients with PAM in the Nordic PAM study. PAM, psoriatic arthritis mutilans.

**Table 2.** Pearson's correlation of radiographic scoring systems by the mSvdH and PARS in 55 patients with PAM with clinical findings.

	PARS	mSvdH
Onset of psoriasis	<b>-0.27*</b> (-0.5—-0.01)	-0.26 (-0.49—0.0)
Onset of arthritis	-0.37 (-0.58—-0.11)	<b>-0.4*</b> (-0.6—-0.15)
Duration of psoriasis	<b>0.42*</b> (0.17—0.6)	<b>0.36*</b> (0.1—0.57)
Duration of arthritis	<b>0.51*</b> (0.28—0.7)	<b>0.48*</b> (0.25—0.66)
HAQ	<b>0.52*</b> (0.28—0.7)	<b>0.51*</b> (0.26—0.69)
BMI	-0.13 (-0.39—0.14)	-0.21 (-0.45—0.05)
CRP	<b>0.34*</b> (0.07—0.57)	0.27 (-0.01—0.51)

Values in parentheses are 95% confidence intervals.

\*Significant difference ( $p < 0.05$ ).

BMI, body mass index; CRP, C-reactive protein; HAQ, Health Assessment Questionnaire; mSvdH, modified Sharp-van der Heijde score; PARS, Psoriatic Arthritis Ratingen Score.

PAM Study (12,14). However, we only included patients where radiographs of both hands and feet were available at time of inclusion for evaluation according to standard scoring methods. Notably, the demographic profile of the 55 patients analyzed herein was similar to the whole population in the Nordic PAM study.

Even though scoring of radiographs is mostly used for research purposes, it may be useful for everyday radiologists to be familiar with PsA scoring instruments and their limitations. These instruments may serve as valuable tools in the diagnostic process of PAM since radiographic change may precede clinical findings (18). All small joints in the hands and feet should be examined carefully and any suspected finding of destruction, osteolysis, or proliferation should be

reported to the clinician as potential indication for development of PAM. In advanced disease where structural abnormalities are expected, plain radiographs are useful. However, in early arthritis, magnetic resonance imaging (MRI) is the method of choice, as it detects minimal disease activity, such as synovitis in the small joints, osteitis or bone edema, and enthesitis, as well as dactylitis (19). However, MRI findings are less sensitive to distinguish between different rheumatic disorders. The most challenging task is to differentiate between early PsA and osteoarthritis (20). Interestingly, in arthritis mutilans, high bone edema scores have been found to correlate with high radiographic scores (21), but not with clinical variables reflecting disease activity. This suggests that bone damage may not necessarily be coupled to local joint inflammation in PsA but rather

**Table 3.** Distribution of severely destructed joints with > 50% destruction of the joint surface on both sides of the joint, i.e. classical “mutilans joints”, in 55 patients with PAM in the Nordic PAM study.

	Right	Left	Total	Joints (n)	Involved joints (%)
<b>Feet</b>					
DIP/IP	73	74	147	550	26.7
PIP	64	64	128	440	29.1
MTP	98	110	208	550	37.8
<b>Hands</b>					
DIP/IP	68	69	137	550	24.9
PIP	55	65	120	440	27.3
MCP	65	67	128	550	23.3

The number of assessed joints together with the percentage of affected joints is also presented.

DIP, distal interphalangeal joints; IP, interphalangeal; MCP, metacarpophalangeal joints; MTP, metatarsophalangeal; PAM, psoriatic arthritis mutilans; PIP, proximal interphalangeal.

reflective of systemic inflammation. Possibly supporting this notion is the correlation, albeit only weakly significant, between levels of CRP and radiographic scores in the present study. We have not been able to find an MRI study specifically focusing on PAM, which would be an interesting topic for future research.

The radiographic scoring methods used herein are well documented and validated. Tillett et al. (22) found that the mSvdH method is reliable and sensitive to change but is time-consuming. The PARS seems more sensitive for the detection of minimal change. The main advantage of PARS is that it scores the presence of proliferation, which is a hallmark of PsA. Therefore, we chose PARS as the second instrument. However, in our patients with PAM, destruction was more pronounced than proliferation. This is in contrast to the findings in the Swedish study of early PsA (23), where proliferation scores were higher than destruction scores. When osteolysis progresses, the degree of proliferation seems to diminish. In our patients with PAM, PARS correlated closer with the duration of PsA.

The two methods that we used cannot be directly compared in our study set-up as the maximum scores are quite different for the two methods—528 for mSvdH and 360 for PARS—but in correlation with other features a comparison is useful. The same problem arises when comparing destruction and proliferation scores (max 200 points vs. 160 points). We therefore evaluated the scoring in relation to the highest possible score. Another problem is that in advanced disease there is often a ceiling effect, which may require yet a different scoring method, e.g. the osteolysis score described by Jadon et al. (11). In this method, osteolysis is scored as blocks of bone. This could help in determining progression in severely deformed joints,

e.g. PAM and in clinical trials to follow-up on radiologic progression, while the method is not easily adapted for analysis of one single radiograph. Furthermore, mSvdH does not include all involved joints and four of our patients had only sign of PAM in their small joints of the feet, which are not included in these two scoring systems.

Our patient population was rather heterogeneous. Most patients had polyarticular disease. Additionally, the disease duration varied considerably, or up to 30 years for psoriasis and 26 years for the arthritis condition. Mutilans involvement was observed at all joint levels in the small joints in the present study. Even though DIP joints are frequently described as typically affected in PsA, there was only a slight predominance of destruction in the DIP joints of the hands, whereas the MTP joints were most frequently affected in the feet. Ankylosis was much less frequently reported in our patients, which is probably why it has not been regarded as a defining feature of PAM (24). We also analyzed the smoking habits of the patients, but smoking did not seem to be an important factor, which is an unexpected finding as smoking is considered a risk factor for arthritis and associates with worse treatment outcomes in PsA as well as in RA.

In conclusion, the two scoring systems studied, mSvdH and PARS, have limitations in advanced disease, as they reach the so-called ceiling effects relatively early. Therefore, they are probably not suitable to indicate progression of PAM in the individual patient. The scoring system described by Jodon (11), based on signs of osteolysis, may be more appropriate in this setting. Therefore, it is of high importance that radiologists report early signs suggestive of PAM, e.g. signs of pencil-in-cup deformities or osteolysis in any joint. Early reporting is crucial and should be mandatory. This would alert the clinician, accelerate the diagnosis, and hopefully lead to improved effective treatment in order to minimize joint damage resulting in PAM.

### Acknowledgments

The authors thank all patients who participated in the study; Thomas Ternowitz, Department of Dermatology, Stavanger University Hospital, Norway, for collecting Norwegian data; Kerstin Berg, Karolinska Institutet, Stockholm, Sweden, for data handling; and finally, NORDPSO for their economic support of the Nordic PAM Study.


### Declaration of conflicting interests

The author(s) declared no potential conflicts of interest with respect to the research, authorship, and/or publication of this article.

## Funding

The author(s) received no financial support for the research, authorship, and/or publication of this article.

## ORCID iD

Bjorn Gudbjornsson  <https://orcid.org/0000-0003-4631-6505>

## References

- Ritchlin CT, Colbert RA, Gladman DD. Psoriatic Arthritis. *N Engl J Med* 2017;376:957–970.
- Scotti L, Franchi M, Marchesoni A, et al. Prevalence and incidence of psoriatic arthritis: a systematic review and meta-analysis. *Semin Arthritis Rheum* 2018;48:28–34.
- Love TJ, Gudbjornsson B, Gudjonsson JE, et al. Psoriatic arthritis in Reykjavik, Iceland: Prevalence, demographics, and disease course. *J Rheumatol* 2007;34:2082–2088.
- Zachariae H, Zachariae R, Blomqvist K, et al. Quality of life and prevalence of arthritis reported by 5,795 members of the Nordic Psoriasis Associations. Data from the Nordic Quality of Life Study. *Acta Derm Venereol* 2002;82:108–113.
- Langley RG, Krueger GG, Griffiths CE. Psoriasis: Epidemiology, clinical features, and quality of life. *Ann Rheum Dis* 2005;64(Suppl. 2):18–23.
- Moll J. M., Wright V. Psoriatic arthritis. *Semin Arthritis Rheum* 1973;3:55–78.
- McHugh NJ. Verna Wright Lecture: Psoriatic Arthritis: the need for early intervention. *J Rheumatol Suppl* 2015;93:10–13.
- Taylor W, Gladman D, Helliwell P, et al. Classification criteria for psoriatic arthritis: Development of new criteria from a large international study. *Arthritis Rheum* 2006;54:2665–2673.
- Chandran V, Gladman DD, Helliwell, et al. Arthritis mutilans: a report from the GRAPPA 2012 annual meeting. *J Rheumatol* 2013;40:1419–1422.
- Haddad A, Johnson SR, Somaily M, et al. Psoriatic arthritis mutilans: clinical and radiographic criteria: A systematic review. *J Rheumatol* 2015;42:1432–1438.
- Jadon DR, Shaddick, Tillett W, et al. Psoriatic arthritis mutilans: characteristics and natural radiographic history. *J Rheumatol* 2015;42:1169–1176.
- Gudbjornsson B, Ejstrup L, Gran JT, et al. Psoriatic arthritis mutilans (PAM) in the Nordic countries: demographics and disease status. The Nordic PAM study. *Scand J Rheumatol* 2013;42:373–378.
- Laasonen L, Gudbjornsson B, Ejstrup L, et al. Radiographic development during three decades in a patient with psoriatic arthritis mutilans. *Acta Radiol Open*. 2015;4:2058460115588098.
- Lindqvist U, Gudbjornsson B, Iversen L, et al. Disease activity in and quality of life of patients with psoriatic arthritis mutilans: The Nordic PAM Study. *Scand J Rheumatol* 2017;46:454–460.
- van der Heijde DM. How to read radiographs according to the Sharp/van der Heijde method. *J Rheumatol* 1999;26:743–745.
- van der Heijde D, Sharp J, Wassenberg S, et al. Psoriatic arthritis imaging: a review of scoring methods. *Ann Rheum Dis* 2005;64(Suppl. II):61–64.
- Wassenberg S, Fischer-Kahle V, Her-Born G, et al. A method to score radiographic change in psoriatic arthritis. *J Rheumatol* 2001;60:156–166.
- Haroon M, Gallagher P, FitzGerald O. Diagnostic delay of more than 6 months contributes to poor radiographic and functional outcome in psoriatic arthritis. *Ann Rheum Dis* 2015;74:1045–1050.
- Poggenborg RP, Sørensen IJ, Pedersen SJ, et al. Magnetic resonance imaging for diagnosing, monitoring and prognostication in psoriatic arthritis. *Clin Exp Rheumatol* 2015;33(Suppl. 93):66–69.
- Braum LS, McGonagle, Bruns A, et al. Characterization of hand small joint arthropathy using high-resolution MRI – Limited discrimination between osteoarthritis and psoriatic arthritis. *Eur Radiol* 2013;23:1686–1693.
- Tan YM, Östergaard M, Doyle A, et al. MRI bone oedema scores are higher in the arthritis mutilans form of psoriatic arthritis and correlate with high radiographic scores for joint damage. *Arthritis Res Ther* 2009;11:R2.
- Tillett W, Jadon D, Shaddick G, et al. Feasibility, reliability, and sensitivity to change of four radiographic scoring methods in patients with psoriatic arthritis. *Arthritis Care Res* 2014;66:311–317.
- Geijer M, Lindqvist U, Husmark T, et al. The Swedish early psoriatic arthritis registry 5-year followup: Substantial radiographic progression mainly in men with high disease activity and development of dactylitis. *J Rheumatol* 2015;42:2110–2117.
- Acosta Felquer ML, FitzGerald O. Peripheral joint involvement in psoriatic arthritis patients. *Clin Exp Rheumatol* 2015;33(Suppl. 93):26–30.