

CASE REPORT

WILEY

Direction- and rate-dependent fractionation during atrial fibrillation persistence: Unmasking cardiac anisotropy?

Roeliene Starreveld MSc  | Natasja M. S. de Groot MD, PhD 

Department of Cardiology, Erasmus University Medical Center, Rotterdam, The Netherlands

CorrespondenceDr. Natasja M. S. de Groot, MD, PhD,
Department of Cardiology, EE-1993, Erasmus Medical Center, Doctor Molewaterplein 40, 3015 GD Rotterdam, The Netherlands.
Email: n.m.s.degroot@erasmusmc.nl**Funding information**

Biosense Webster, Grant/Award Number: ICD 783454; CVON-AFFIP, Grant/Award Number: 914728; NWO-Vidi, Grant/Award Number: 91717339; Medical Delta

Disclosures: None.**Abstract**

This human case is the first to illustrate morphological manifestations of direction- and rate-dependent anisotropic conduction in high-resolution unipolar atrial potentials. Premature impulses induced low-amplitude, fractionated extracellular potentials with exceptionally prolonged durations in a 76-year old longstanding persistent patient with atrial fibrillation (AF), demonstrating direction-dependency of anisotropic conduction. An increased pacing frequency induced presence of similar fractionated potentials, reflecting rate-dependent anisotropy and inhomogeneous, slow conduction. Pacing with different rates and from different sites could aid in identifying nonuniform anisotropic tissue and thus the substrate of AF.

KEYWORDS

anisotropy, atrial fibrillation, direction-dependency, fractionation, rate-dependency, surgical ablation

1 | INTRODUCTION

Due to the cable-like longitudinal arrangement of atrial myocardial fibers, electrical conduction is much faster in longitudinal direction than in transverse direction.¹ While cell geometry is a major determinant of anisotropy, mostly gap junction distribution determine whether propagation is continuous or discontinuous.² Altered gap junction distribution and formation of longitudinal collagenous septa between myocardial fibers result in discontinuous transverse propagation (“nonuniform anisotropy”) and increased susceptibility to reentrant tachyarrhythmias, such as atrial fibrillation (AF).^{3,4} In addition to gap junctions, myocytes can interact by ephaptic coupling, as shown in ventricular myocardium in experimental and modeling studies.^{5,6}

During nonuniform anisotropy, extracellular waveforms consist of more than one deflection (ie, fractionation), caused by asynchronous firing of two or more groups of cells that are separated by areas in which there is diminished or no cell-to-cell electrical coupling in the path of propagation.³ Extracellular waveform morphology can

therefore be used to detect anisotropic structural discontinuities that are proarrhythmic, such as areas of slowed conduction due to grossly irregular discontinuous propagation.³

Importantly, anisotropy is not a static property of cardiac tissue, but can be modulated by alterations in gap junctional conductance (ie, intercellular coupling), as demonstrated in multiple simulation and animal models.^{1,2,7,8} For example, Spach et al⁷ demonstrated anisotropy to be rate-dependent, with higher pacing rates resulting in a lower transverse conduction velocity in relation to longitudinal conduction velocity.² In addition, premature stimulation in nonuniform anisotropy resulted in decremental longitudinal conduction and block with zigzag transverse conduction, while this was not the case in uniform anisotropy (ie, direction-dependency).⁹

Although described in experimental studies, clear examples of these phenomena in patient data are rare. In this paper we present a case in which both the rate- and direction-dependency of anisotropy is demonstrated in a 76-year old patient with longstanding persistent AF.

This is an open access article under the terms of the Creative Commons Attribution-NonCommercial License, which permits use, distribution and reproduction in any medium, provided the original work is properly cited and is not used for commercial purposes.

© 2020 The Authors. *Journal of Cardiovascular Electrophysiology* Published by Wiley Periodicals LLC

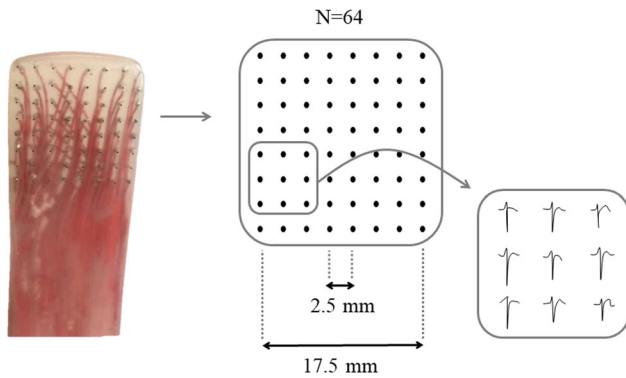


FIGURE 1 Epicardial mapping using a 64-electrode spatula. With eight rows of eight unipolar electrodes, having an interelectrode distance of 2.5 mm, the spatula covers a mapping area of 17.5×17.5 mm. During epicardial mapping extracellular potentials of atrial tissue are recorded.

2 | CASE REPORT

A 76-year old female with a history of longstanding persistent AF presented for mitral valve surgery and surgical radiofrequency ablation.

During surgery—before commencement to extra-corporeal circulation—epicardial mapping of the pulmonary vein (PV) area was performed with a 64-electrode spatula (mapping area 17.5×17.5 mm, interelectrode distances 2.5 mm) (Figure 1). A silver disc positioned inside the thoracic cavity served as indifferent electrode. Unipolar signals were stored on a hard disk after amplification (gain 1000), filtering (bandwidth 1-500 Hz), sampling (1 kHz), and analog to digital conversion (12 bits). The patient presented in AF but was cardioverted to sinus rhythm (SR).

During SR, with the spatula on the caudal PV area, several premature atrial complexes (PACs) occurred. During these PACs, morphology of atrial potentials changed considerably (Figure 2). Whereas high-amplitude, single atrial potentials of short durations were observed during SR beats, PACs induced low-amplitude and multiphasic (ie, fractionated) potentials, manifesting exceptional prolongation of potential duration.

After SR recordings, programmed electrical stimulation was performed using electrodes sutured to the right atrial appendage. With the spatula on the mid PV area, pacing was executed at cycle lengths of 600, 500, and 333 ms (corresponding with 100, 120, and 180 beats per minute, respectively). At a paced cycle length of

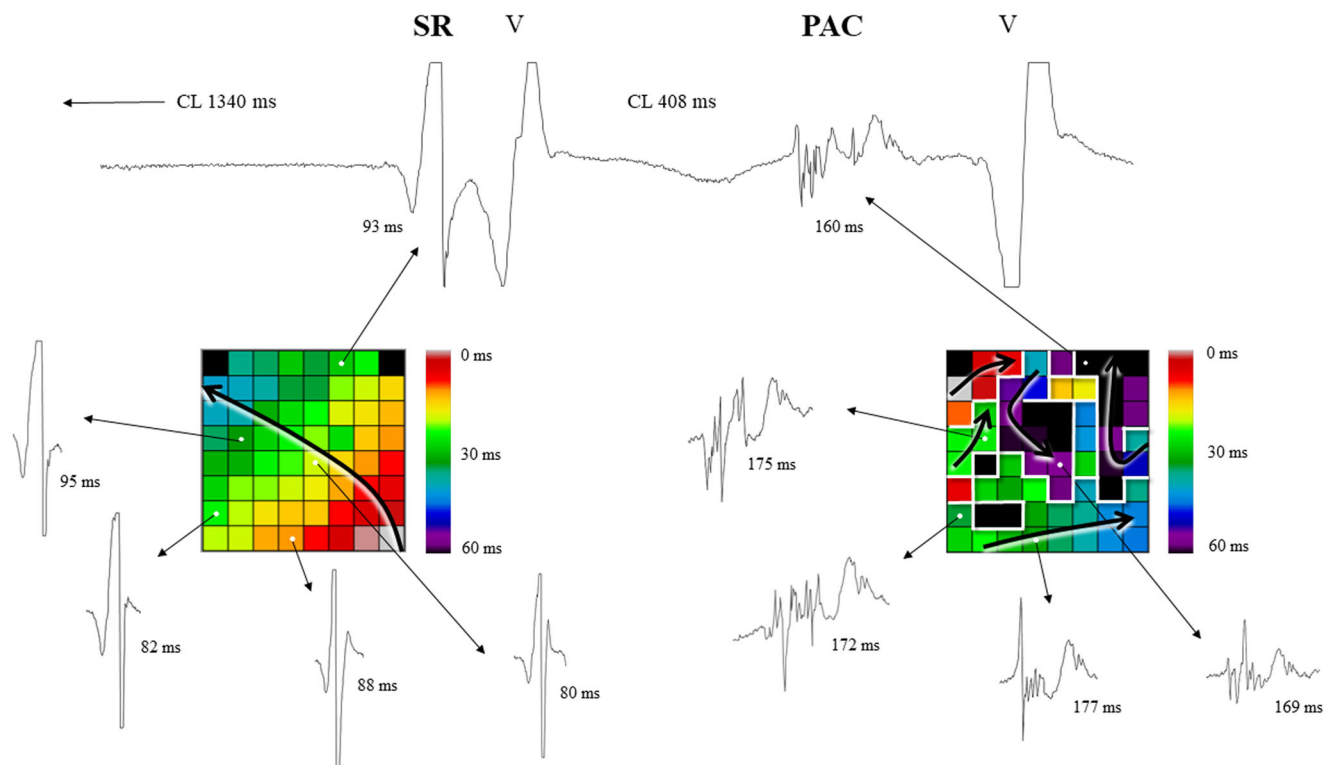


FIGURE 2 Premature atrial complex (PAC) causes unidirectional longitudinal block with corresponding low-amplitude, fractionated potentials with long duration. At the top, the electrode 6 tracing demonstrates one sinus rhythm (SR) beat followed by a ventricular far-field complex (V), together with one PAC with subsequent ventricular activation. During recordings the spatula was placed on the caudal pulmonary vein (PV) area. Color-coded activation maps of both the SR beat and PAC are shown. The SR impulse arises from the right-lower part of the mapping area and homogeneously propagates towards the left-upper part, whereas the PAC exhibits inhomogeneous and slow conduction around several lines of block (Δ local activation time ≥ 12 ms, visualized as thick white lines). The SR beat is characterized by high-amplitude, biphasic and smooth extracellular potentials with short duration (80-95 ms), whereas the PAC exhibits low-amplitude, multiphasic potentials with long duration (160-177 ms). CL, cycle length (ie, coupling interval of consecutive atrial impulses)

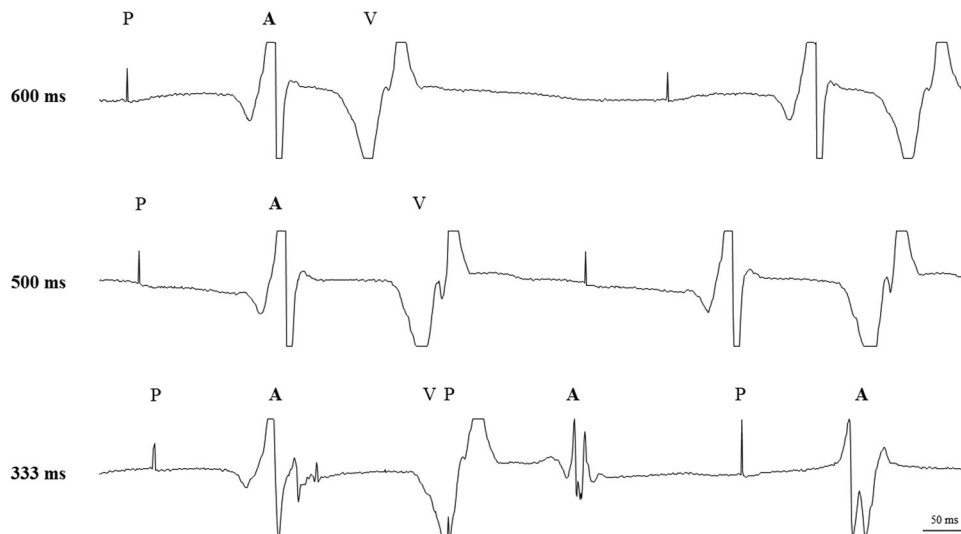


FIGURE 3 Pacing at shorter cycle length induces multiphasic fractionated potentials, due to a lower transverse conduction velocity in relation to longitudinal conduction velocity. With the spatula on the mid PV area, pacing from the right atrial appendage was performed. Three unipolar tracings of electrode 10 are shown, corresponding with pacing cycle lengths of 600, 500, and 333 ms (ie, 100, 120, and 180 beats per minute, respectively). In contrary to pacing at low rates, pacing at the highest rate (ie, cycle length of 333 ms) induced low-amplitude, fractionated atrial potentials with prolonged durations. A, atrial complex; P, pacing; PV, pulmonary vein; V, ventricular far-field complex

600 and 500 ms, high-amplitude, single atrial potentials with short durations were observed. In contrary, pacing at a cycle length of 333 ms induced low-amplitude, fractionated atrial potentials with prolonged durations (Figure 3).

3 | DISCUSSION

This case demonstrates direction- and rate-dependency of anisotropic conduction in the intact human heart and is the first to illustrate its morphological manifestations in high-resolution unipolar atrial potentials.

3.1 | Premature impulses can cause unidirectional longitudinal block

In correspondence with the experimental studies of Spach et al,^{3,9} low-amplitude fractionated extracellular potentials with prolonged durations were observed during premature impulses in this patient, indicating slow propagation in association with unidirectional block. While one would expect smooth and biphasic extracellular atrial potentials in uniform anisotropic tissue,³ the observed irregular potentials with low-amplitude deflections and severely prolonged potential duration reveal the nonuniformity of anisotropic tissue in the PV area of this patient.

The coupling interval at which the premature impulse arrives is crucial for the course of propagation. In a canine study, Spach et al showed that at a long coupling interval (290 ms) both longitudinal and transverse propagation succeeded, whereas during stimulation

within the refractory period (130 ms) both failed.¹⁰ At short coupling intervals just above the refractory period (134 and 145 ms) propagation was decremental, showing longitudinal block without transverse conduction. At a coupling interval of 155 ms, decremental conduction and block occurred in the longitudinal direction with preserved transverse propagation, enabling reentry to occur. Spach concluded that only in the latter the premature stimulus was below the safety factor in the longitudinal direction, but above the threshold in the transverse direction, giving rise to longitudinal block with transverse conduction.^{2,8} This example also illustrated that propagation becomes decremental first in the direction having the highest conduction velocity (ie, the longitudinal direction) with a corresponding long refractory period.¹⁰ As illustrated in Figure 2, the SR beat arises from the right-lower part of the mapping area and homogeneously propagates towards the left-upper part, where the earliest activation of the PAC is seen. The relative short coupling interval of the premature impulse (408 ms) causes multiple areas of local conduction block (Δ local activation time ≥ 12 ms), around which the wavefront slowly propagates. This also stresses the importance and impact of wavefront entrance and curvature for initiation of reentry, facilitated by the direction-dependency of nonuniform anisotropic tissue.

3.2 | Increased pacing frequency decreases transverse conduction velocity

Animal studies have shown that the ratio between longitudinal and transverse conduction velocity (ie, anisotropy ratio) is rate-dependent, with higher stimulation rates resulting in an increased

anisotropy ratio due to a relative decrease in transverse conduction velocity.^{2,7} The sudden decay in transverse conduction velocity could not be accounted for by any changes in the action potential and was fully reversible upon decreases of pacing rate,⁷ and therefore must be due to a change in intercellular coupling (ie, gap junctional conductance). Although all gap junctions regardless of directionality will be affected, longitudinal propagation velocity retains due to its relative insensitivity to decreases in coupling.^{7,11} Intercellular coupling is thus susceptible to modulation by rate, even within the course of a few action potentials.^{2,7} In our patient, an increase in pacing frequency induced presence of low-amplitude, multiphasic atrial potentials with long durations, which was likely caused by an increase in intercellular coupling resistance and led to inhomogeneous and slow conduction. Partially similar findings were presented in bipolar recordings,¹² although especially the potential duration delays observed within this case are exceptional.

Importantly, during premature stimulation both longitudinal and transverse conduction velocity decrease proportionally, whereas increasing the pacing frequency primarily induces an exponential decay of transverse conduction velocity.^{2,7} So although closely related, the sudden appearance of fractionated potentials during premature impulses as well as during an increased pacing rate are caused by two distinct phenomena: the direction- and rate-dependency of anisotropic conduction, respectively.

3.3 | Clinical importance

Pacing with different rates and from different sites could aid in identifying nonuniform anisotropic tissue and thus the substrate of AF. Furthermore, substrate-guided AF ablation techniques that are used in clinical practice—such as low-voltage ablation and ablation of complex fractionated atrial electrograms—use thresholds that do not take into account direction- and rate-dependency of (nonuniform) anisotropic tissue.

4 | CONCLUSIONS

Premature impulses and an increased pacing rate induced low-amplitude, fractionated potentials with exceptional prolongation of potential duration. Pacing with different rates and from different sites could aid in identifying nonuniform anisotropic tissue and thus the substrate of AF.

CONFLICT OF INTERESTS

The authors declare that there are no conflict of interests.

ORCID

Roeliene Starreveld  <https://orcid.org/0000-0002-5666-2455>

Natasja M. S. de Groot  <http://orcid.org/0000-0002-0259-6691>

REFERENCES

1. Wit AL, Dillon SM, Coromilas J, Saltman AE, Waldecker B. Anisotropic reentry in the epicardial border zone of myocardial infarcts. *Ann N Y Acad Sci.* 1990;591:86-108.
2. Valderrabano M. Influence of anisotropic conduction properties in the propagation of the cardiac action potential. *Prog Biophys Mol Biol.* 2007;94:144-168.
3. Spach MS. Anisotropy of cardiac tissue: a major determinant of conduction? *J Cardiovasc Electrophysiol.* 1999;10:887-890.
4. Spach MS, Dolber PC. Relating extracellular potentials and their derivatives to anisotropic propagation at a microscopic level in human cardiac muscle. Evidence for electrical uncoupling of side-to-side fiber connections with increasing age. *Circ Res.* 1986;58:356-371.
5. Veeraraghavan R, Lin J, Hoeker GS, Keener JP, Gourdie RG, Poelzing S. Sodium channels in the Cx43 gap junction perinexus may constitute a cardiac ephapse: an experimental and modeling study. *Pflugers Arch.* 2015;467:2093-2105.
6. Veeraraghavan R, Lin J, Keener JP, Gourdie R, Poelzing S. Potassium channels in the Cx43 gap junction perinexus modulate ephaptic coupling: an experimental and modeling study. *Pflugers Arch.* 2016; 468:1651-1661.
7. Spach MS, Kootsey JM, Sloan JD. Active modulation of electrical coupling between cardiac cells of the dog. A mechanism for transient and steady state variations in conduction velocity. *Circ Res.* 1982;51:347-362.
8. Delgado C, Steinhaus B, Delmar M, Chialvo DR, Jalife J. Directional differences in excitability and margin of safety for propagation in sheep ventricular epicardial muscle. *Circ Res.* 1990;67:97-110.
9. Spach MS, Dolber PC, Heidlage JF. Influence of the passive anisotropic properties on directional differences in propagation following modification of the sodium conductance in human atrial muscle. A model of reentry based on anisotropic discontinuous propagation. *Circ Res.* 1988;62:811-832.
10. Spach MS, Miller WT 3rd, Geselowitz DB, Barr RC, Kootsey JM, Johnson EA. The discontinuous nature of propagation in normal canine cardiac muscle. Evidence for recurrent discontinuities of intracellular resistance that affect the membrane currents. *Circ Res.* 1981;48:39-54.
11. Jongsma HJ, Wilders R. Gap junctions in cardiovascular disease. *Circ Res.* 2000;86:1193-1197.
12. Jadidi AS, Duncan E, Miyazaki S, et al. Functional nature of electrogram fractionation demonstrated by left atrial high-density mapping. *Circ Arrhythm Electrophysiol.* 2012;5:32-42.

How to cite this article: Starreveld R, de Groot NMS. Direction- and rate-dependent fractionation during atrial fibrillation persistence: Unmasking cardiac anisotropy? *J Cardiovasc Electrophysiol.* 2020;1-4. <https://doi.org/10.1111/jce.14597>