

Acta Med. Okayama, 2015
Vol. 69, No. 6, pp. 333-338

Copyright©2015 by Okayama University Medical School.

Acta Medica
Okayama

<http://escholarship.lib.okayama-u.ac.jp/amo/>

Original Article

Correlation between ^{18}F -fluorodeoxyglucose Positron Emission Tomography/computed Tomography and Clinicopathological Features in Invasive Ductal Carcinoma of the Breast

Maiko Ito^{a*}, Tadahiko Shien^a, Mitsumasa Kaji^b, Taeko Mizoo^a,
Takayuki Iwamoto^c, Tomohiro Nogami^a, Takayuki Motoki^c, Naruto Taira^a,
Hiroyoshi Doihara^a, and Shinichiro Miyoshi^a

^aDepartment of General Thoracic Surgery and Breast and Endocrine Surgery, Okayama University Graduate School of Medicine, Dentistry and Pharmaceutical Sciences, ^cDepartment of Breast and Endocrine Surgery, Okayama University Hospital, Okayama 700-8558, Japan, and ^bOkayama Diagnostic Imaging Center, Okayama 700-0913, Japan

We evaluated the usefulness of preoperative ^{18}F -fluorodeoxyglucose positron emission tomography/computed tomography (^{18}F -FDG PET/CT) examinations to predict the pathological features in primary breast cancer. In particular, we evaluated the correlation between the maximum standardized uptake values (SUVmax) obtained by ^{18}F -FDG PET/CT and the Ki67 expression in estrogen receptor (ER)-positive invasive ductal carcinoma (IDC). Primary IDC patients operated between March 2009 and July 2013 at Okayama University Hospital were enrolled. We evaluated the correlations between the SUVmax and age, postoperative pT, histological grade, lymph vascular invasion, status of hormone receptor, human epidermal growth factor receptor 2 (HER2), Ki67 expression and node status. The Ki67 expression was classified as high (> 14%) versus low (\leq 14%). We enrolled 138 patients with IDC. Their median SUVmax was 3.85 (range: 0-52.57). In a univariate analysis, the SUVmax was significantly related to age, pT, histological grade, lymphovascular invasion, hormone receptor status, HER2 status, node status and Ki67. In the 113 patients with ER-positive IDC, there was a significant correlation between Ki67 and SUVmax ($p = 0.0030$). The preoperative ^{18}F -FDG PET/CT results of IDC patients had significant relationships with pathological status parameters. The determination of the preoperative SUVmax might help classify Luminal A and Luminal B patients among luminal-type breast cancer patients.

Key words: breast cancer, invasive ductal carcinoma, ^{18}F -fluorodeoxyglucose positron emission tomography/computed tomography, maximum standardized uptake values, clinicopathological features

One of the main characteristics of malignant tumors is the acceleration of glycolysis. ^{18}F -fluorodeoxyglucose positron emission tomography/computed tomography (^{18}F -FDG PET/CT) is an imag-

ing modality that can be used to visualize the local existence of a lesion by reflecting the increased metabolism of cancer cells [1]. PET/CT has been used for the diagnosis, staging, and detection of metastases and recurrence, and it has recently come

Received January 5, 2015; accepted August 18, 2015.

*Corresponding author. Phone: +81-86-235-7265; Fax: +81-86-235-7264
E-mail: snufumin@yahoo.co.jp (M. Ito)

Conflict of Interest Disclosures: No potential conflict of interest relevant to this article was reported.

to be used to estimate the response to chemotherapy early in malignancies, including breast cancer. Several research groups have also suggested that the uptake of FDG to the primary tumor can be used to predict the prognoses of breast cancer patients [2–5].

The breast cancer subtype classified according to positivity for estrogen receptor (ER)/progesterone receptor (PgR) and human epidermal growth factor receptor 2 (HER2) is regarded as a predictive factor for the need for adjuvant therapy. We have also begun using this subtype classification in our decision-making process regarding the need for adjuvant chemotherapy, along with the expression of the cellular marker Ki67 as an indicator of the proliferation of cancer cells. However, the method for measuring the Ki67 index is not currently standardized among institutions, and the cut-off value for Ki67 also varies among institutions [6]. In addition, in breast cancer cases of the luminal type, the level of Ki67 can be used as a parameter to distinguish Luminal B from Luminal A breast cancer. The differentiation of Luminal A and Luminal B is very important to the judgment of the necessity of chemotherapy and the use of neoadjuvant chemotherapy [6]. It is somewhat difficult to measure the exact level of Ki67 before surgery, and it could be very helpful if we could replace the measurement of Ki67 with PET/CT.

Several studies examined the correlation of ^{18}F -FDG uptake and clinicopathological features of breast cancer, and in most of these studies the examination was carried out without making a distinction between invasive ductal carcinoma (IDC) and invasive lobular carcinoma (ILC). However, the morphologic characteristics of ILCs are different from those of IDCs [7], and two-thirds of ILC patients were reported to show false-negative results in a PET/CT examination [8].

The goals of the present study were to determine whether: (1) ^{18}F -FDG uptake is associated with biological parameters including Ki67 expression only for IDC, and (2) the use of maximum standardized uptake (SUVmax) values could help differentiate Luminal A and Luminal B cases among luminal-type breast cancer patients. We assessed the levels of ^{18}F -FDG uptake to primary breast cancers using SUVmax values.

Materials and Methods

Patients. We studied 138 patients with IDC who underwent ^{18}F -FDG PET/CT scans before surgery and had not received neoadjuvant chemotherapy between March 2009 and July 2013 at the Okayama University Hospital. Patients with blood glucose values of > 150 mg/dl during PET/CT image acquisition were excluded.

^{18}F -FDG PET/CT imaging. All patients underwent ^{18}F -FDG PET/CT scans at the Okayama Diagnostic Imaging Center (Okayama, Japan). The patients fasted at least 5–6 h before the ^{18}F -FDG PET examination. Each patient's blood glucose was measured before the tracer injection to ensure a level of 150 mg/dl. Ninety min after an intravenous (IV) administration of 3.7 MBq/kg ^{18}F -FDG, a whole-body scan from the upper end of the orbit to the femoral region was performed with the patient in the supine position with elevation of both upper limbs. Images were obtained using a PET/CT scanner (Biograph LSO/Sensation16, Siemens, Munchen, Germany). A transmission scan using CT for attenuation correction and anatomical imaging was acquired for 90 s. An IV contrast agent was not administered to patients for the CT portion of the ^{18}F -FDG PET/CT.

A region of interest (ROI) was placed in the primary lesion, including the highest uptake area (circular ROI, 3 cm dia.), and the SUVmax in the ROI was calculated. The SUV was calculated using the following formula:

$$\text{SUV} = \frac{\text{activity in the ROI (MBq/ml)}}{\text{injected dose (MBq/kg body weight)}}$$

Histological analysis. Tumor histology and biological parameters were evaluated using the breast cancer tissue obtained by surgery. The histological type was assessed by hematoxylin and eosin staining, and the histological grade was determined using the Scarff-Bloom-Richardson classification. ER and PgR were defined as being positive when at least 10% of the tumor cells showed positive immunohistochemistry (IHC) staining for these molecules. The HER2 status was defined as positive when more than 30% of the cells showed a positive IHC result for this molecule. Ki67 expression was considered high when at least 14% of the cancer cells exhibited positive staining, according to the suggestion of the St. Gallen international expert consensus 2013 [6].

Statistical analysis. A software package (JMP 9.0.2; SAS Institute, Tokyo) was used for all statistical analyses. The correlations between the SUVmax and other parameters evaluated in this study were calculated using the Mann-Whitney *U*-test (when 2 categories were compared) and the Kruskal-Wallis test (when more than 2 categories were compared). A receiver operator characteristic (ROC) curve was used to identify the potential SUVmax cut-off value predictive of different luminal subtypes. An area under the curve (AUC) of 1.0 would indicate a perfect test, whereas 0.5 would represent a non-useful test. All tests were two-sided, and *p*-values < 0.05 were considered significant. All procedures were carried out with the adequate understanding and written consent of each patient.

Results

Patient characteristics. The median age of the 138 patients was 52 years (range 22–86 years). The median pT was 15 mm (range 1–93 mm), and 96 (69%) patients were stage I. ER was positive in 113 (82%) of the patients, and PgR was positive in 95 (69%) patients. Twenty (14%) of the patients were HER2-positive, and 13 (9%) patients had a triple-negative tumor (*i.e.*, their tumor was negative for ER, PgR and HER2). The median SUVmax was 3.85 (range 0–52.57), and FDG uptake to the breast cancer was not seen in 10 patients.

Association between median SUVmax and clinicopathological features. Table 1 shows the associations between SUVmax and the patients' clinicopathological features. There were significant correlations between SUVmax and all of the clinicopathological features examined: age, tumor size,

Table 1 Association between SUVmax in the breast tumor and patient clinicopathological features

Variables	n (%)	median SUVmax (IQR)	<i>p</i> value	
Age	≤49	54 (39)	5.0 (2.9–6.9)	0.026 ^a
	>49	84 (61)	3.1 (2.1–6.4)	
Tumor size (mm)	<10	31 (22)	2.2 (1.2–3.5)	<0.0001 ^b
	10 to 20	65 (47)	3.1 (2.5–5.5)	
	≥20	42 (30)	6.7 (5.2–11.7)	
Lymph node status	positive	46 (33)	5.1 (3.2–7.0)	0.004 ^a
	negative	92 (67)	3.1 (2.1–5.9)	
Histological grade	1	53 (38)	2.8 (2.3–4.6)	<0.0001 ^b
	2	37 (27)	3.2 (2.2–6.6)	
	3	48 (35)	5.7 (3.6–11.4)	
Lymphovascular invasion	0	60 (43)	2.8 (2.0–5.4)	0.014 ^b
	1	46 (33)	4.1 (2.8–6.3)	
	2	17 (12)	6.0 (2.7–6.8)	
	3	15 (11)	5.9 (4.0–9.5)	
ER	positive	113 (82)	3.2 (2.3–5.5)	<0.0001 ^a
	negative	25 (18)	8.7 (4.0–13.2)	
PgR	positive	95 (69)	3.1 (2.3–5.4)	<0.0001 ^a
	negative	43 (31)	6.3 (3.2–10.7)	
HER2	positive	20 (14)	5.5 (3.4–9.3)	0.039 ^a
	negative	116 (84)	3.5 (2.3–6.6)	
	unknown	2		
Ki67	>14	71 (51)	5.5 (2.8–9.3)	<0.0001 ^a
	≤14	67 (49)	2.9 (2.1–4.5)	
subtype	Luminal	113 (82)	3.1 (2.3–5.5)	<0.0001 ^b
	HER2	12 (9)	7.4 (3.8–12.1)	
	Triple negative	13 (9)	8.8 (5.3–13.2)	

IQR, interquartile range; ER, estrogen receptor; PgR, progesterone receptor; HER2, human epidermal growth factor receptor 2.

^aMann-Whitney *U*-test.

^bKruskal-Wallis test.

lymph node status, histological grade, lymphovascular invasion, ER, PgR, HER2, Ki67, and subtype.

There was a significant correlation between pT and SUVmax ($p < 0.0001$). There were significant associations between SUVmax and lymphovascular invasion ($p = 0.012$) and the lymph node status ($p = 0.004$). With regard to lymphovascular invasion, the tumors with lymphovascular invasion had significantly higher ^{18}F -FDG uptake (4.6 vs. 2.8; $p = 0.008$).

ER positivity was associated with significantly lower median SUVmax ($p < 0.0001$), and PgR positivity was similarly associated with significantly lower median SUVmax ($p < 0.0001$). The SUVmax was also significantly influenced by HER2 positivity ($p = 0.039$). Patients who had more than 14% Ki67 expression had significantly higher ^{18}F -FDG uptake ($p < 0.0001$).

With regard to the tumor histological grade, there was a significant correlation between the histological grade and SUVmax ($p < 0.0001$), and the grade 3 tumor group had significantly higher ^{18}F -FDG uptake than the group with grade 1 + 2 (5.7 vs. 2.9; $p < 0.0001$). The tumor subtype had a significant impact on the ^{18}F -FDG uptake to the primary tumor ($p < 0.0001$), and the 13 patients with triple-negative tumors had significantly higher uptake compared to the 125 patients with non-triple negative tumors (8.8 vs. 3.3; $p = 0.0007$).

Among the patients with ER positivity, there was a significant correlation between Ki67 and SUVmax ($p = 0.0030$). To investigate whether SUVmax could be used to help classify Luminal A and Luminal B cases among luminal-type tumors, we used the SUVmax to create an ROC curve for Ki67. The area under the ROC curve was 0.664, and the cut-off SUVmax was 4.34 (Fig. 1).

Discussion

In this study, we assessed the correlations between the tumor uptake of ^{18}F -FDG and clinicopathological features in breast cancer patients who underwent curative surgery. Since there are some biological and morphologic differentiations between IDC and ILC [7, 8], we enrolled only IDC patients in this study. Our analyses revealed significant associations between higher SUVmax values and younger age, larger pT, lymph node metastases, higher histological grade, lymphovascular invasion, negative hormone receptor status, HER2 expression, higher Ki67 index and tri-

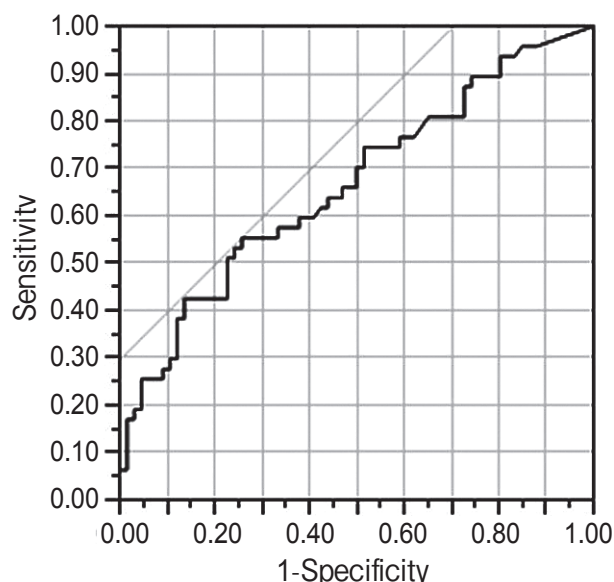


Fig. 1 The receiver operator characteristic (ROC) curve for SUVmax in the different level of Ki67 (high: $> 14\%$, low: $\leq 14\%$) in Luminal type. The curve describes the association between sensitivity and specificity at different thresholds. The area under the curve (AUC) was 0.664 and the optimal cut-off level of SUVmax was 4.34.

ple negativity in comparison with non-triple negativity.

Several reports indicated that high levels of ^{18}F -FDG uptake are correlated with larger tumor size [2-4, 9-11]. In agreement with those reports, the present results showed that pT significantly influences the SUVmax. There was also a significant difference between the SUVmax of the tumors $> 20\text{mm}$ and the 0-20-mm tumors (6.7 vs. 2.9; $p < 0.0001$), indicating that the levels of SUVmax in tumors at more than T2 are significantly higher.

We observed positive correlations between the ^{18}F -FDG uptake and the hormone receptor status, HER2 expression, and tumor grade. This is consistent with previous reports about ER negativity [2-4, 9, 10, 12, 13], PgR negativity [2, 4, 12, 13], HER2 positivity [2-4, 9, 11] and tumor grade [2-4, 9-14].

In agreement with earlier studies [9, 10, 14, 15], we also observed that the Ki67 index was strongly correlated with the SUVmax. This finding might indicate that the acceleration of glucose metabolism supplies enough energy to exaggerate the metabolic activity in aggressive tumors [14]. We also examined the correlation between SUVmax and Ki67

in only the luminal cases. Luminal-type tumors are classified as either Luminal A or Luminal B, and this classification influences the treatment decisions because there are differences in drug sensitivity between Luminal A and B patients [6].

Patients with ER positivity have been reported to show poor responses to chemotherapy [16, 17], but neoadjuvant chemotherapy seems to be effective for Luminal B patients by reducing their tumor volume [17]. Therefore, as adjuvant postoperative therapy for Luminal B patients, chemotherapy is recommended in addition to hormone therapy, and in some cases neoadjuvant chemotherapy is also recommended, whereas the standardized drug therapy for Luminal A is only adjuvant hormone therapy [6]. The Ki67 index can be used to help classify Luminal A and B cases: the cut-off point is 14% [6]. Considering the possibility of an indication for neoadjuvant chemotherapy, it is important to precisely diagnose Luminal A versus B pre-operatively. This classification can also be applied to the recurrence of breast cancer, for which the optimal drug treatment must be chosen.

Niikura *et al.* reported that the Ki67 labeling index varies according to the area of tissue selected in the evaluation [18]. We commonly evaluate preoperative Ki67 by using a core needle biopsy (CNB) specimen, but a CNB provides only a small quantity of specimen. We thus might not be able to evaluate Ki67 precisely using only a CNB specimen. In the present study, we created the ROC curve for Ki67 in ER-positive patients to assess whether the SUVmax can be used to differentiate the groups of high (>14%) and low (\leq 14%) Ki67 patients. The area under the ROC curve was 0.664, which indicates low accuracy, and thus the evaluation of SUVmax cannot supplant the Ki67 index, but the evaluation of SUVmax may support the use of the Ki67 index and help identify the best treatment policy in luminal-type patients. Because the number of luminal-type patients in the present series was only 113, there is room for the further consideration of this issue.

For the reason mentioned above, we examined the correlation between SUVmax and Ki67 only in luminal-type patients. Twenty-four of the 25 cases in the ER-negative group had high Ki67 values, and therefore we judged that there was no need for the examination in the ER-positivity group. The new classification of triple-negative breast cancer (TN) is very

important to the decision-making process regarding the treatment strategy for TN [19]. It may also be useful to determine the SUVmax in ER-negative patients.

This study had some limitations. The limited number of samples may have hampered the detection of slight but crucial significant differences. In addition, this was a retrospective study and it could have been influenced by biases associated with retrospective studies, such as inherent selection bias. The tumor grade, Ki67 index, and subtype of tumor are the major important predictive factors in breast cancer, and our present findings revealed that these factors are associated with ¹⁸F-FDG uptake. An association between SUVmax and the prognosis of breast cancer may exist, as was mentioned in previous reports [2, 4], but we were not able to examine this association because of the short follow-up period in this study.

In conclusion, our results indicate that the SUVmax is associated with almost all of the commonly used clinicopathological characteristics in primary breast cancer. ¹⁸F-FDG PET/CT alone cannot replace the evaluation of Ki67, but it has the potential to be useful by providing additional information about luminal-type cancer in the preoperative assessment of primary IDC. More thorough investigations of larger cohorts with respect to the association between FDG uptake and prognosis might give more precise results.

References

1. Avril N, Rosé CA, Schelling M, Dose J, Kuhn W, Bense S, Weber W, Ziegler S, Graeff H and Schwaiger M: Breast imaging with positron emission tomography and fluorine-18 fluorodeoxyglucose: use and limitations. *J Clin Oncol* (2000) 18: 3495–3502.
2. Kadoya T, Aogi K, Kiyoto S, Masumoto N, Sugawara Y and Okada M: Role of maximum standardized uptake value in fluorodeoxyglucose positron emission tomography/computed tomography predicts malignancy grade and prognosis of operable breast cancer: a multi-institute study. *Breast Cancer Res Treat* (2013) 141: 269–275.
3. Nakajo M, Kajiyama Y, Kaneko T, Kaneko Y, Takasaki T, Tani A, Ueno M, Koriyama C and Nakajo M: FDG PET/CT and diffusion-weighted imaging for breast cancer: prognostic value of maximum standardized uptake values and apparent diffusion coefficient values of the primary lesion. *Eur J Nucl Med Mol Imaging* (2010) 37: 2011–2020.
4. Ueda S, Tsuda H, Asakawa H, Shigekawa T, Fukatsu K, Kondo N, Yamamoto M, Hama Y, Tamura K, Ishida J, Abe Y and Mochizuki H: Clinicopathological and prognostic relevance of uptake level using 18F-fluorodeoxyglucose positron emission tomography/computed tomography fusion imaging (18F-FDG PET/CT) in primary breast cancer. *Jpn J Clin Oncol* (2008) 38: 250–258.

5. Zhang J, Jia Z, Ragaz J, Zhang YJ, Zhou M, Zhang YP, Li G, Wang BY, Wang ZH and Hu XC: The maximum standardized uptake value of 18 F-FDG PET scan to determine prognosis of hormone-receptor positive metastatic breast cancer. *BMC Cancer*. Doi (2013): 10.1186/1471-2407-13-42.
6. Goldhirsch A, Winer EP, Coates AS, Gelber RD, Piccart-Gebhart M, Thürlimann B and Senn HJ: Personalizing the treatment of women with early breast cancer: highlights of the St Gallen International Expert Consensus on the Primary Therapy of Early Breast Cancer 2013. *Ann Oncol* (2013) 24: 2206-2223.
7. Arpino G, Bardou VJ, Clark GM and Elledge RM: Infiltrating lobular carcinoma of the breast: tumor characteristics and clinical outcome. *Breast Cancer Res* (2004) 6: R149-156.
8. Buck AK, Schirrmester H, Mattfeldt T and Reske SN: Biological characterisation of breast cancer by means of PET. *Eur J Nucl Med Mol Imaging* (2004) 31 Suppl 1: S80-87.
9. De Cicco C, Gilardi L, Botteri E, Fracassi Silvia LV, Di Dia GA, Botta F, Prisco G, Lombardo D, Rotmensz N, Veronesi U and Paganelli G: Is [¹⁸F] fluorodeoxyglucose uptake by the primary tumor a prognostic factor in breast cancer? *Breast* (2013) 22: 39-43.
10. Gil-Rendo A, Martinez-Regueira F, Zornoza G, García-Velloso MJ, Beorlegui C and Rodriguez-Spiteri N: Association between [¹⁸F] fluorodeoxyglucose uptake and prognostic parameters in breast cancer. *Br J Surg* (2009) 96: 166-170.
11. Taira N, Ohsumi S, Takabatake D, Hara F, Takashima S, Aogi K, Takashima S, Inoue T, Sugata S and Nishimura R: Determination of indication for sentinel lymph node biopsy in clinical node-negative breast cancer using preoperative 18F-fluorodeoxyglucose positron emission tomography/computed tomography fusion imaging. *Jpn J Clin Oncol* (2009) 39: 16-21.
12. Koolen BB, Vrancken Peeters MJ, Wesseling J, Lips EH, Vogel WV, Aukema TS, van Werkhoven E, Gilhuijs KG, Rutgers EJ and Valdes Olmos RA: Association of primary tumour FDG uptake with clinical, histopathological and molecular characteristics in breast cancer patients scheduled for neoadjuvant chemotherapy. *Eur J Nucl Med Mol Imaging* (2012) 39: 1830-1838.
13. Groheux D, Giacchetti S, Moretti JL, Porcher R, Espie M, Lehmann-Che J, de Roquancourt A, Hamy AS, Cuvier C, Vercellino L and Hindie E: Correlation of high 18F-FDG uptake to clinical, pathological and biological prognostic factors in breast cancer. *Eur J Nucl Med Mol Imaging* (2011) 38: 426-435.
14. Shimoda W, Hayashi M, Murakami K, Oyama T and Sunagawa M: The relationship between FDG uptake in PET scans and biological behavior in breast cancer. *Breast Cancer* (2007) 14: 260-268.
15. Buck A, Schirrmester H, Kuhn T, Shen C, Kalker T, Kotzerke J, Dankerl A, Glatting G, Reske S and Mattfeldt T: FDG uptake in breast cancer: correlation with biological and clinical prognostic parameters. *Eur J Nucl Med Mol Imaging* (2002) 29: 1317-1323.
16. Gianni L, Zambetti M, Clark K, Baker J, Cronin M, Wu J, Mariani G, Rodriguez J, Carcangiu M, Watson D, Valagussa P, Rouzier R, Symmans WF, Ross JS, Hortobagyi GN, Pusztai L and Shak S: Gene expression profiles in paraffin-embedded core biopsy tissue predict response to chemotherapy in women with locally advanced breast cancer. *J Clin Oncol* (2005) 23: 7265-7277.
17. Ades F, Zardavas D, Bozovic-Spasojevic I, Pugliano L, Fumagalli D, Azambuja E, Viale G, Sotiriou C and Piccart M: Luminal B breast cancer: Molecular characterization, clinical management, and future perspectives. *J Clin Oncol* (2014) 32: 2794-2803.
18. Niiikura N, Sakatani T, Arima N, Ohi Y, Honma N, Kanomata N, Yoshida K, Kadoya T, Tamaki K, Kumaki N, Iwamoto T, Sugie T and Moriya T: Assessment of Ki67 labeling index: a Japanese validation ring study. *Breast Cancer* (2014) DOI 10.1007/s12282-014-0536-0.
19. Lehmann BD, Bauer JA, Chen X, Sanders ME, Chakravarthy AB, Shyr Y and Pietenpol JA: Identification of human triple-negative breast cancer subtypes and preclinical models for selection of targeted therapies. *J Clin Invest* (2011) 121: 2750-2767.