

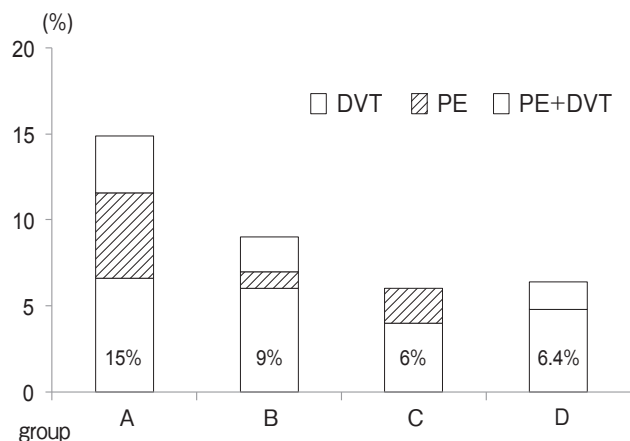
Acta Med. Okayama, 2015

Vol. 69, No. 5, pp. 325

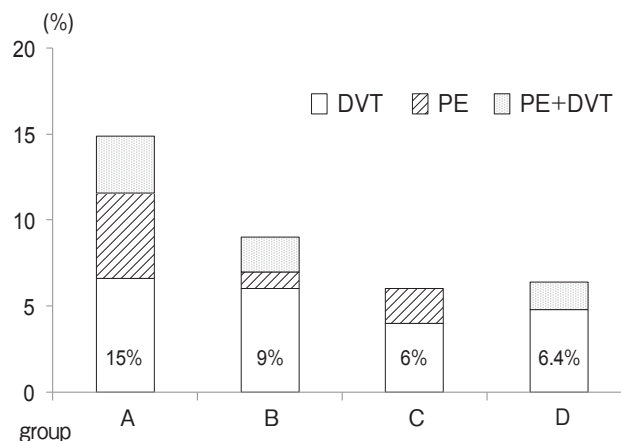
Copyright©2015 by Okayama University Medical School.

Acta Medica  
Okayama<http://escholarship.lib.okayama-u.ac.jp/amo/>*Erratum*

In the article by Okada Y *et al.* entitled “Venous Thromboembolism after Total Hip Arthroplasty Diagnosed by Enhanced Computed Tomography: Comparison of Selective Thromboprophylaxis and No Thromboprophylaxis”, which appeared in the August 2015 issue, Vol. 69, No. 4, pp205–212, Figure 1 should be corrected as below.

**Error:**

**Fig. 1** The bar graph shows the VTE incidence in group A (receiving no anticoagulants), group B (receiving FDX), group C (receiving enoxaparin), and group D (selectively receiving no anticoagulants). The incidences of DVT, PE, and both PE and DVT are indicated by the white bar, striped bar, and dotted bar, respectively.

**Correction:**

**Fig. 1** The bar graph shows the VTE incidence in group A (receiving no anticoagulants), group B (receiving FDX), group C (receiving enoxaparin), and group D (selectively receiving no anticoagulants). The incidences of DVT, PE, and both PE and DVT are indicated by the white bar, striped bar, and dotted bar, respectively.