

Acta Med. Okayama, 2015
Vol. 69, No. 4, pp. 219-226

Copyright©2015 by Okayama University Medical School.

Acta Medica
Okayama

<http://escholarship.lib.okayama-u.ac.jp/amo/>

Original Article

Local Recurrence and Complications after Percutaneous Radiofrequency Ablation of Hepatocellular Carcinoma: A Retrospective Cohort Study Focused on Tumor Location

Junichi Toshimori, Kazuhiro Nouse, Shinichiro Nakamura*, Nozomu Wada, Yuki Morimoto, Yasuto Takeuchi, Tetsuya Yasunaka, Kenji Kuwaki, Hideki Ohnishi, Fusao Ikeda, Hidenori Shiraha, Akinobu Takaki, and Kazuhide Yamamoto

Department of Gastroenterology and Hepatology, Okayama University Graduate School of Medicine, Dentistry and Pharmaceutical Sciences, Okayama 700-8558, Japan

We conducted a retrospective cohort study to investigate the predisposing factors for local recurrence and complications after percutaneous radiofrequency ablation (RFA) of hepatocellular carcinoma (HCC). HCC patients (n = 397) consecutively treated with RFA (256 males, 141 females, median age 69 years) were enrolled. In these patients, 1,455 nodules (median size 17 mm) were ablated. Predisposing factors for overall recurrence and local recurrence in the context of tumor location and complications were examined. Local recurrence was observed for 113 of the 1,455 nodules. The 1-, 3- and 5-year local recurrence rates were 2.2%, 7.4% and 9.5%, respectively. A multivariate Cox proportional hazard analysis revealed that large tumor size (> 2 cm), tumor location (adjacent to the major portal branch or hepatic vein), and small ablated margin (< 3 mm) were independent predisposing factors for local recurrence after RFA (HR = 1.70-2.81). Tumor location (adjacent to the major portal branch, hepatic vein, or diaphragm) was also revealed as a risk factor for liver damage due to RFA. HCC adjacent to the major portal vein or hepatic vein was associated with a higher risk for local recurrence and for complications; therefore, special precautions are necessary when applying RFA to HCC near vessels even when the tumors are located at an easy-to-puncture site.

Key words: hepatocellular carcinoma, radiofrequency ablation, ablated margin, tumor location

Hepatocellular carcinoma (HCC) is the most frequent primary hepatic malignancy and has been recognized as the major cause of death in cirrhotic patients. Epidemiological data indicate that the prevalence of HCC is increasing in the United States and Europe [1-3]. Early detection programs including periodic imaging surveillance with ultrasonography (US) or computed tomography (CT) and periodic

measurements of serum tumor markers such as alpha-fetoprotein (AFP) and des-gamma-carboxy prothrombin (DCP) have increased the number of HCC patients suitable for curative treatment. Surgical resection nevertheless plays a limited role in the treatment of many HCC cases because of liver dysfunction caused by coexisting cirrhosis or the presence of multiple tumors [4, 5]. Moreover, HCC often recurs even after systematic resection of the tumor-bearing liver,

Received October 10, 2014; accepted March 13, 2015.

*Corresponding author. Phone: +81-86-235-7219; Fax: +81-86-225-5991
E-mail: shinnkmr@md.okayama-u.ac.jp (S. Nakamura)

Conflict of Interest Disclosures: No potential conflict of interest relevant to this article was reported.

and liver transplantation can only be offered to a limited number of patients due to the shortage of donors.

Various types of nonsurgical treatments have been developed. Radiofrequency ablation (RFA) can achieve complete tumor necrosis [6–8] and has become a principal treatment in many institutions for patients with small HCCs. The rate of recurrence of HCC after curative treatment including RFA is high: Rossi *et al.* reported a cure rate as high as 70% over a 3-year period [9].

Many studies have been performed to elucidate risk factors for the recurrence of HCC. Large tumor size, high tumor number, high AFP level, and low albumin are frequently noted as risk factors [11–17]; however, most of these risk factors were associated with distant recurrence, and the risk of local recurrence has not been elucidated. We previously reported the risk factors for HCC recurrence after local ablation therapy, and our findings demonstrated that the factors for local and distant recurrence were completely different [10]. At that time, the majority of the patients in the study has been treated with percutaneous ethanol injection therapy. Several studies were later published analyzing the risk factors for local recurrence after RFA, and in those studies, tumor size, tumor location (subcapsular or blood vessel proximity), ablated margins, and HBV viral load were noted as risk factors for local recurrence; however, the factors varied from one report to another [11–17].

In the present study, we analyzed the risk factors for local recurrence in Japanese HCC patients treated with the latest percutaneous RFA technique in conjunction with artificial ascites/pleural effusion, and our analysis included precise information about the location of the tumor(s) and any resulting complications.

Materials and Methods

Patients and tumors. Among the 849 consecutive patients with newly diagnosed HCC between April 2001 and July 2011 at Okayama University Hospital, 397 patients who were treated with RFA as an initial therapy for HCC were enrolled in this study. During this period, we treated 1,455 HCCs within this cohort of 397 patients. Therapies were selected according to the evidence-based clinical practice

guidelines for HCC in Japan [18].

Informed consent to analyze the data was obtained from all patients. The study protocol conformed to the ethical guidelines of the World Medical Association and the Declaration of Helsinki, and was approved by the Hospital's Ethical Committee.

Diagnosis of HCC. HCC diagnosis was confirmed histologically in 103 patients who had undergone ultrasound (US)-guided biopsy. The remaining 294 patients were diagnosed via typical HCC image patterns obtained by angiography, CT, magnetic resonance (MR) imaging, and US. The diagnostic criteria of HCC by imaging modalities were based on previous reports of hyper-attenuation at the hepatic arterial phase, hypo-attenuation at the portal venous phase in triple-phase CT or MR imaging, and tumor stain on angiography, or hyper-enhancement in the arterial phase, hypo-enhancement in the portal venous, and late phases in contrast-enhanced US [19–21].

Tumor vascularity was defined as 'hyper-vascular' when the tumor showed hyper-attenuation at the hepatic arterial phase by CT or MR imaging, or hyper-enhancement in the arterial phase by contrast-enhanced US.

We also checked the location of tumors, and if a tumor was located within 5mm from other organs or vessels, we defined the tumor as 'adjacent.'

Treatment methods. Patients with HCCs that appeared hyper-attenuated at the hepatic arterial phase in dynamic CT or MR imaging underwent super-selective transcatheter arterial chemoembolization (TACE) at least 1wk prior to RFA ($n = 663$, 46%). We skipped TACE in several cases when the tumors were small and we judged that the tumors might become hard to detect by US. Epirubicin hydrochloride (Farmorbicin; Pharmacia, Tokyo, Japan) with iodized oil (Lipiodol Ultrafluid; TERUMO, Tokyo, Japan) followed by embolization with gelatin particles (Gelpart, Nippon Kayaku, Tokyo, Japan) or miriplatin hydrate (Milipra, Dainippon Sumitomo Pharma, Osaka, Japan) was used for chemoembolization [22].

RFA was performed under US guidance as described [10, 22]. A 17-gauge internally cooled-tip electrode (20-cm long with a 2- or 3-cm-long exposed metallic tip) and a 480-kHz monopolar RF generator (Covidien Japan, Tokyo, Japan) were used for ablation. When the diameter of the HCC was < 1.5 cm, a 2-cm-long exposed metallic tip was usually used. A

3-cm-long exposed tip was used in the rest of the cases. After the tumor was penetrated with the electrode, the generator was set to the impedance mode and the output was increased stepwise from 60 W for a 3-cm-exposed tip (40 W for a 2-cm-exposed tip) until it reached maximum power or was impeded out (10–20-W increase per min). After it was impeded out, the power was decreased by 10–20 W, and the ablation was continued for 10–12 min (6–10 min for a 2-cm-exposed tip). We repeated the RFA until the microbubbles covered the area expected to include the entire tumor.

When the targeted nodule was adjacent to the diaphragm or was not clearly seen because of the lung artifact, we used the artificial pleural effusion technique to prevent lung injury (for 368 nodules). If the targeted nodule was close to the gastrointestinal tract, we used the artificial ascites technique (for 142 nodules). To control pain, 15–30 mg of pentazocine and 25 mg of hydroxyzine were administered intravenously to each patient.

The therapeutic effectiveness was assessed with contrast-enhanced CT or MRI performed 3–5 days after the RFA treatment to confirm that the entire tumor was covered within the ablated area. All images were reviewed by 2 radiologists and 2 hepatologists. To determine the “ablative margin,” we measured the minimal distance between the tumor edge and the ablated area that was defined as a nonenhanced area at the portal venous phase of triple-phase CT or MRI.

In cases of residual viable lesion, an additional RFA treatment was performed (122 nodules).

Follow-up. After treatment, the patients were assessed approximately every 2 or 3 months by US, triple-phase CT, or MR imaging. Local recurrences were defined as the appearance of tumors adjacent to (in contact with) the ablated lesion. Patients were followed up until the date of last follow-up or death. The median follow-up period per patient was 55.7 months (interquartile range, 33.0–79.3 months). Complications were reported according to version 4.0 of the U.S. National Cancer Institute’s Common Terminology Criteria for Adverse Events. We considered events equal to or above grade 2 as complications. We did not take pain into account as a complication because most of the patients claimed moderate pain during the procedure and mild pain at the puncture site for 3–4 days.

Complications were divided into 5 categories: liver injury (*i.e.*, ascites, pleural effusion, hepatic infarction, and/or portal vein thrombosis), hemorrhage (*i.e.*, injury of the intracostal artery or hemorrhage to the outside of the liver), biliary damage (*i.e.*, biloma or bile duct stenosis), cardiovascular damage (*i.e.*, vagotonia, paroxysmal atrial tachycardia, or paroxysmal atrial fibrillation), and “other.” Complications that might induce or be induced by the deterioration of liver function were categorized as “liver injury.”

Statistical analysis. Quantitative variables such as clinical background variables are presented as median values and interquartile range, and qualitative variables are presented as absolute and relative frequencies. Survival probabilities were estimated by the Kaplan-Meier method. The parameters for the univariate and multivariate analyses of patient and tumor characteristics included age, gender, Child-Pugh grade, number of tumors, tumor size, vascularity of the tumor, tumor location (adjacent to large vessels such as the hepatic vein, portal vein, or inferior vena cava; adjacent to extrahepatic organs such as the diaphragm, heart, kidney, stomach, colon, pancreas, or gall bladder), tumor markers, and ablated margin. We classified the portal vein into 2 groups: major branch and minor branch. “Major branch” included the main trunk and first- or second-order branches of the portal vein, and “minor branch” were vessels distal to the third-order branch of the portal vein.

Variables associated with recurrence and complications were assessed by the Cox proportional hazard model and logistic regression model, respectively. Variables with a p -value ≤ 0.05 in a univariate comparison were subjected to the multivariate analysis. All significance tests were two-sided, and differences with a p -value < 0.05 were considered significant. All statistical analyses were performed using JMP software, version 11.2 (SAS Institute, Tokyo, Japan).

Results

Patient characteristics. The clinical features of the 397 patients are shown in Table 1. The patient cohort consisted of 256 males and 141 females with a median age of 69 years, including 328 cases of Child-Pugh grade A hepatic impairment. The majority of the patients ($n = 328$, 82.6%) were positive for hepatitis C virus antibody. The median size of the tumor was

17 mm, and 254 patients (64%) had a single tumor.

The 1-, 3- and 5-year survival rates of the patients with primary HCC were 97.4%, 85.3%, and 70.1%, respectively.

Predisposing factors for recurrence.

Recurrence of HCC was observed in 269 patients (67.7%). The 1-, 3- and 5-year recurrence rates were

23.8%, 56.2%, and 68.0%, respectively (Fig. 1). The univariate analysis revealed that low platelet count ($< 1.00 \times 10^5/\mu\text{L}$), high AFP ($\geq 100 \text{ ng/mL}$), high DCP ($\geq 40 \text{ mAU/mL}$), multiple nodules, and large tumor size ($> 2 \text{ cm}$) were predisposing factors for recurrence. Low platelet count, high DCP, and multiple nodules were selected as significant factors for the multivariate analysis (Table 2).

Predisposing factors for local recurrence.

Between April 2001 and July 2011, we used RFA to treat 1,455 HCCs in the 397 patients. We failed to complete ablation for 21 nodules (1.4%). The residual lesions of these tumors were treated with TACE when those tumors enlarged.

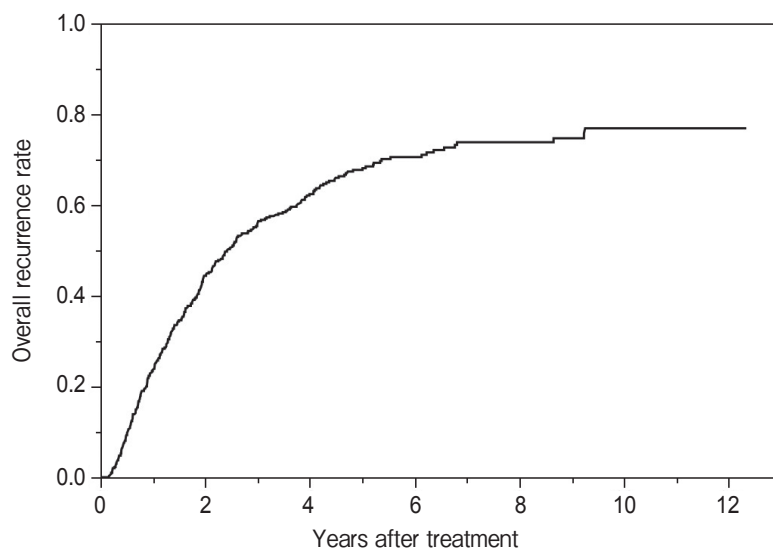
We used the 2-cm-long exposed tip for 1,166 tumors and the 3-cm-long exposed tip for the rest of the tumors. The median (interquartile range) sizes of those tumors were 12 mm (10–15 mm) and 21 mm (17–25 mm), respectively ($p < 0.0001$).

Predisposing factors for local recurrence were examined (Table 3). Two hundred fifty-nine nodules (17.8%) were adjacent to large vessels and 520 nodules (35.7%) were adjacent to extrahepatic organs including the diaphragm, gastrointestinal tract, heart, kidney, pancreas, and gall bladder. Recurrences were observed for 113 nodules, and the 1-, 3- and 5-year

Table 1 Patient data and characteristics

Number of patients	397
Age, years	69 (62–74)
Gender (male/female)	256/141
Etiology (HCV/HBV/HCV and HBV/other)	320/37/8/32
Child-Pugh grade (A/B/C)	328/66/3
Serum bilirubin, mg/dL	0.82 (0.63–1.11)
Serum albumin, g/dL	3.7 (3.3–4.0)
Prothrombin time, %	92 (82–103)
Platelet count $\times 10^5/\mu\text{L}$	1.05 (0.73–1.50)
AFP, ng/mL	13.3 (5.8–43.1)
AFP-L3, %	0.5 (0–1.7)
DCP, mAU/mL	28 (19–62)
Number of nodules (1/2/3/4-)	254/82/37/24
Maximum tumor diameter, mm	17 (13–21)

All variables are reported as the median (interquartile range). HCV, hepatitis C virus; HBV, hepatitis B virus; AFP, alpha-fetoprotein; AFP-L3, lectin-bound alpha-fetoprotein; DCP, des-gamma-carboxy prothrombin.



Patients at risk	397	210	119	62	34	18	3
Patients recurred	0	172	237	260	266	269	269

Fig. 1 Cumulative overall recurrence rates of hepatocellular carcinoma (HCC) after radiofrequency ablation (RFA) therapy. The 1-, 3- and 5-year recurrence rates were 23.8%, 56.2%, and 68.0%, respectively.

Table 2 The predisposing factors for HCC recurrence after RFA

Patient characteristics	Hazard ratio (95% C.I.)			
	Univariate	<i>P</i> value	Multivariate	<i>P</i> value
Age ≥ 70 years	1.08 (0.85–1.37)	0.54		
Gender (male)	1.13 (0.88–1.45)	0.35		
Etiology (HCV)	1.27 (0.93–1.78)	0.13		
Etiology (HBV)	0.82 (0.55–1.18)	0.30		
Child-Pugh grade (B or C)	0.94 (0.67–1.30)	0.72		
Platelet count (< 1.00 × 10 ⁹ /μL)	1.43 (1.12–1.82)	0.0036	1.40 (1.09–1.78)	0.0078
AST > 80 IU/L	0.90 (0.64–1.23)	0.52		
ALT > 80 IU/L	0.96 (0.67–1.32)	0.80		
AFP ≥ 100 ng/mL	1.43 (1.01–1.97)	0.044	1.17 (0.82–1.64)	0.40
AFP-L3 ≥ 10%	1.45 (0.96–2.10)	0.073		
DCP ≥ 40 mAU/mL	1.43 (1.12–1.83)	0.0050	1.34 (1.02–1.74)	0.035
Multiple nodules	1.45 (1.13–1.85)	0.0037	1.40 (1.09–1.80)	0.0096
Tumor diameter > 20 mm	1.44 (1.11–1.87)	0.0070	1.25 (0.94–1.65)	0.13

HCC, hepatocellular carcinoma; RFA, radio-frequency ablation; C.I., confidence interval; HCV, hepatitis C virus; HBV, hepatitis B virus; AFP, alpha-fetoprotein; AFP-L3, lectin-bound alpha-fetoprotein; DCP, des-gamma-carboxy prothrombin.

Table 3 The predisposing factors for local recurrence after RFA

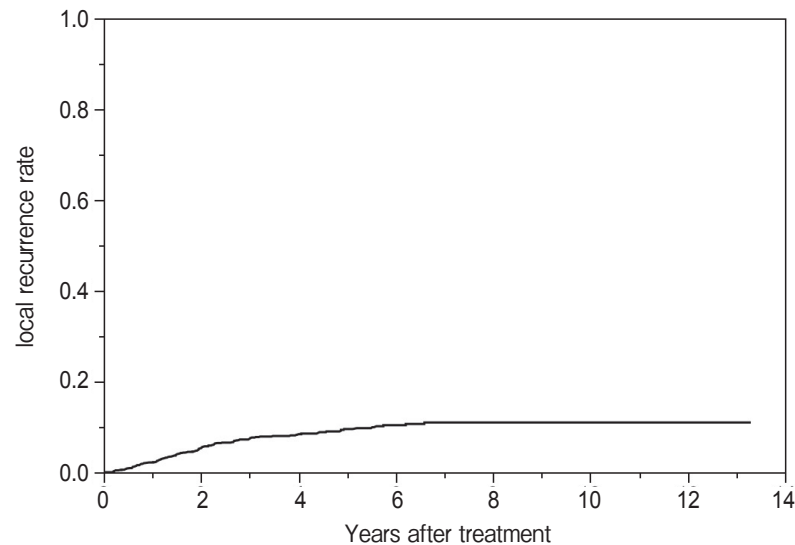
		Risk ratio (95% C.I.)			
		Univariate	<i>P</i> value	Multivariate	<i>P</i> value
Number of tumors	1,455				
Tumor characteristics					
Maximum diameter (> 20 mm)	172 (12)	2.17 (1.37–3.33)	0.0015	1.84 (1.15–2.84)	0.011
Hyper-vascular, n (%)	1,088 (75)	1.56 (1.00–2.55)	0.052		
TACE prior to RFA, n (%)	663 (46)	1.10 (0.76–1.60)	0.61		
Tumor form (simple nodular type/others)	1,424/32	1.27 (0.31–3.38)	0.69		
Tumor location (adjacent to;)					
Liver surface (hump)	221	0.74 (0.41–1.25)	0.28		
Portal vein (major branch)	92	4.67 (2.91–7.21)	<0.001	2.91 (1.77–4.61)	<0.0001
Portal vein (minor branch)	167	1.38 (0.78–2.27)	0.24		
Hepatic duct	14	3.11 (0.76–8.23)	0.10		
Hepatic vein	143	2.66 (1.67–4.09)	<0.001	1.92 (1.19–2.99)	0.0082
IVC	24	1.72 (0.42–4.57)	0.39		
Gall bladder	49	2.10 (0.88–4.18)	0.088		
Colon	42	0.58 (0.10–1.82)	0.40		
Pancreas	12	5.50 × 10 ⁹	0.18		
Heart	77	1.81 (0.92–3.22)	0.084		
Stomach	41	0.27 (0.02–1.21)	0.10		
Diaphragm	326	1.14 (0.75–1.71)	0.53		
Kidney	41	0.31 (0.02–1.40)	0.15		
Ablated margin < 3 mm	579	2.96 (2.02–4.41)	<0.001	2.25 (1.50–3.40)	<0.0001

HCC, hepatocellular carcinoma; RFA, radio-frequency ablation; C.I., confidence interval; TACE, transcatheter arterial chemoembolization; IVC, inferior vena cava; major branch, the main trunk, first or second order branches of the portal vein; minor branch, distal to third order branch of the portal vein.

local recurrence rates were 2.2%, 7.4%, and 9.5%, respectively (Fig. 2).

The univariate analysis revealed that large tumor

size (> 2 cm), tumor location (adjacent to the major portal branch or hepatic vein), and small ablated margin (< 3 mm) were significant predisposing factors



Nodules at risk	1,455	1,070	676	357	160	82	6
Nodules recurred	0	70	100	111	113	113	113

Fig. 2 Local recurrence rates after RFA therapy. The 1-, 3-, and 5-year local recurrence rates were 2.2%, 7.4%, and 9.5%, respectively.

Table 4 Complications due to RFA

	Number of Patients
Liver injury	
Pleural effusion (due to hypoalbuminemia)	11
Hepatic infarction	6
Portal vein thrombosis	6
Ascites	2
Hemorrhage	
Hemorrhage to the abdominal cavity	5
Subcutaneous hemorrhage	4
Hemorrhage to bile duct	1
Hemorrhage to the retroperitoneal space	1
Injury of intracostal artery	1
Biliary damage	
Biloma	5
Bile duct stenosis	4
Cardiovascular damage	
Vagotonia	4
Paroxysmal atrial tachycardia	1
Paroxysmal atrial fibrillation	1
Others	
Liver abscess	1
Pleuritis	1
Pyothorax	1
Skin burn	2
Diaphragmatic hernia	1
Pneumothorax	1

for local recurrence. The multivariate analysis revealed that all of the significant factors in the univariate analysis were independent predisposing factors for local recurrence after RFA (hazard ratio [HR] = 1.84–2.91).

Adverse events. Fifty-nine complications were reported in 53 of the patients (13.2%) (Table 4); some patients experienced multiple complications. No risk factors for hemorrhage, cardiovascular damage, or other complications were reported. However, tumor vascularity (hypervascular) and tumor location (adjacent to the major portal branch, vein, or diaphragm), as well as high DCP and advanced age (≥ 70 year old) were risk factors for liver damage (relative risk [RR] = 2.32–3.70); tumor location (adjacent to the hepatic duct) was the only risk factor for biliary damage (RR = 34.1) (Table 5).

Discussion

We performed a retrospective cohort study to clarify the risk factors for the local recurrence of HCC after RFA using the latest methods including artificial ascites/pleural effusion, and we report the complications in these Japanese HCC patients, who were standard candidates for RFA. Although the rate

Table 5 The risk factors for liver injury and biliary damage after RFA

	Liver injury			Biliary damage	
	Risk ratio (95% C.I.)	<i>P</i> value		Risk ratio (95% C.I.)	<i>P</i> value
Tumor location			Tumor location		
Diaphragm	3.70 (1.71–7.98)	0.0011	Hepatic duct	34.1 (4.77–160.0)	0.0021
Portal vein (major branch)	3.32 (1.03–9.12)	0.045			
Hepatic vein	2.95 (1.11–6.99)	0.032			
Tumor character					
Hyper-vascular	3.04 (1.06–12.8)	0.038			
Patients character					
DCP \geq 40 mAU/mL	2.32 (1.04–5.29)	0.041			
Age \geq 70 years	2.53 (1.10–6.33)	0.028			

Risk ratios (95% C.I.) were calculated with the logistic regression model.

RFA, radio-frequency ablation; C.I., confidence interval; DCP, des-gamma-carboxy prothrombin; major branch, the main trunk, first or second order branches of the portal vein.

of local recurrence was low, it was never zero, even with careful ablation of the tumors. Our analysis revealed that low platelet count, high DCP, and multiple nodules were the predisposing factors for recurrence after RFA overall, and the factors for local recurrence were large tumor size (> 2 cm), small ablated margin (< 3 mm), and tumor location (adjacent to major portal vein or hepatic vein). Liver injury was the major complication of RFA and was closely correlated with the tumor location (adjacent to the diaphragm and hepatic vein as well as a major branch of the portal vein), the vascularity of the tumor, the DCP level, and the age of the patient.

The reported risks for distant recurrence depend mainly on the carcinogenic potential of noncancerous tissues and can change according to the development of antiviral treatments. Here we observed that the risk of local recurrence was closely related to the location of the tumor, especially the proximity to blood vessels. Because the patient's blood flow reduces the elevation of the tumor's temperature during the RFA procedure, the incidence of local recurrence was highest near the blood vessels. Although the use of RFA in high-risk locations has been reported [23], our data clearly demonstrate that the incidence of recurrence was high and the chance of deterioration of liver function was increased in such cases.

Bleeding is the most dangerous complication when it was necessary to puncture an HCC near a large vessel. However, this complication was extremely rare in the present series, indicating that bleeding could be avoided if the puncture is performed properly

under real-time imaging by US and by excluding patients with bleeding tendency as candidates for RFA. In addition, we ablated the puncture tract after tumor ablation to avoid tumor dissemination, and this procedure itself might prevent bleeding.

Although our findings revealed the clinical features of local recurrence after RFA, there were several limitations in this study. One major limitation is that this was a retrospective study conducted at a single center. The inclusion criteria, RFA procedure, and technical skill level could differ depending on the hospital; therefore, there might be small variations in the risk factors of local recurrence and complications of RFA among hospitals. Another limitation lies in the difficulty in performing RFA in balancing the need to prevent recurrence with the necessity to avoid liver injury, which may result from too little or too much ablation. Alternative treatments such as stereotactic radiation therapy (SRT) or percutaneous ethanol injection therapy (PEIT) could thus be another choice in these cases.

In conclusion, our analysis identified predisposing factors for local recurrence and complications following RFA as a treatment for HCC, with a focus on the tumor location. Local recurrence as well as the deterioration of liver function after RFA was high when the HCC was adjacent to the vessels, indicating that special caution must be used for the treatment of HCC near vessels even when the nodule is located at an easy-to-puncture site.

References

1. El-Serag HB, Davila JA, Petersen NJ and McGlynn KA: The continuing increase in the incidence of hepatocellular carcinoma in the United States: an update. *Ann Intern Med* (2003) 139: 817–823.
2. El-Serag HB and Mason AC: Rising incidence of hepatocellular carcinoma in the United States. *N Engl J Med* (1999) 340: 745–750.
3. Taylor-Robinson SD, Foster GR, Arora S, Hargreaves S and Thomas HC: Increase in primary liver cancer in the UK, 1979–94. *Lancet* (1997) 350: 1142–1143.
4. Bruix J and Llovet JM: Prognostic prediction and treatment strategy in hepatocellular carcinoma. *Hepatology* (2002) 35: 519–524.
5. Colombo M and Sangiovanni A: The European approach to hepatocellular carcinoma. *Hepatogastroenterology* (2002) 49: 12–16.
6. Tateishi R, Shiina S, Teratani T, Obi S, Sato S, Koike Y, Fujishima T, Yoshida H, Kawabe T and Omata M: Percutaneous radiofrequency ablation for hepatocellular carcinoma. An analysis of 1000 cases. *Cancer* (2005) 103: 1201–1209.
7. Lencioni RA, Allgaier HP, Cioni D, Olschewski M, Deibert P, Crocetti L, Frings H, Laubenberger J, Zuber I, Blum HE and Bartolozzi C: Small hepatocellular carcinoma in cirrhosis: randomized comparison of radio-frequency thermal ablation versus percutaneous ethanol injection. *Radiology* (2003) 228: 235–240.
8. Livraghi T, Goldberg SN, Lazzaroni S, Meloni F, Solbiati L and Gazelle GS: Small hepatocellular carcinoma: treatment with radiofrequency ablation versus ethanol injection. *Radiology* (1999) 210: 655–661.
9. Rossi S, Ravetta V, Rosa L, Ghittoni G, Viera FT, Garbagnati F, Silini EM, Dionigi P, Calliada F, Quaretti P and Tinelli C: Repeated Radiofrequency Ablation for Management of Patients with Cirrhosis with Small Hepatocellular Carcinomas: A Long-Term Cohort Study. *Hepatology* (2011) 53: 136–147.
10. Nouse K, Matsumoto E, Kobayashi Y, Nakamura S, Tanaka H, Osawa T, Ikeda H, Araki Y, Sakaguchi K and Shiratori Y: Risk factors for local and distant recurrence of hepatocellular carcinomas after local ablation therapies. *J Gastroenterol Hepatol* (2008) 23: 453–458.
11. Kono M, Inoue T, Kudo M, Chishina H, Arizumi T, Takita M, Kitai S, Yada N, Hagiwara S, Minami Y, Ueshima K, Nishida N and Murakami T: Radiofrequency Ablation for Hepatocellular Carcinoma Measuring 2cm or Smaller: Results and Risk Factors for Local Recurrence. *Dig Dis* (2014) 32: 670–677.
12. Kim JS, Kim W, So YH, Yu SJ and Kim BG: Topographical impact of hepatitis B-related hepatocellular carcinoma on local recurrence after radiofrequency ablation. *J Clin Gastroenterol* (2014) 48: 66–72.
13. Xia F, Lai EC, Lau WY, Ma K, Li X, Bie P and Qian C: High serum hyaluronic acid and HBV viral load are main prognostic factors of local recurrence after complete radiofrequency ablation of hepatitis B-related small hepatocellular carcinoma. *Ann Surg Oncol* (2012) 19: 1284–1291.
14. Shiozawa K, Watanabe M, Wakui N, Ikehara T, Iida K and Sumino Y: Risk factors for the local recurrence of hepatocellular carcinoma after single-session percutaneous radiofrequency ablation with a single electrode insertion. *Mol Med Rep* (2009) 2: 89–95.
15. Lam VW, Ng KK, Chok KS, Cheung TT, Yuen J, Tung H, Tso WK, Fan ST and Poon RT: Risk factors and prognostic factors of local recurrence after radiofrequency ablation of hepatocellular carcinoma. *J Am Coll Surg* (2008) 207: 20–29.
16. Berber E and Siperstein A: Local recurrence after laparoscopic radiofrequency ablation of liver tumors: an analysis of 1032 tumors. *Ann Surg Oncol* (2008) 15: 2757–2764.
17. Murakami T, Ishimaru H, Sakamoto I, Uetani M, Matsuoka Y, Daikoku M, Honda S, Koshiishi T and Fujimoto T: Percutaneous radiofrequency ablation and transcatheter arterial chemoembolization for hypervascular hepatocellular carcinoma: rate and risk factors for local recurrence. *Cardiovasc Intervent Radiol* (2007) 30: 696–704.
18. Clinical Practice Guidelines for Hepatocellular Carcinoma - The Japan Society of Hepatology 2009 update. *Hepatol Res* (2010) 40 Suppl 1: 2–144.
19. Claudon M, Dietrich CF, Choi BI, Cosgrove DO, Kudo M, Nolsoe CP, Piscaglia F, Wilson SR, Barr RG, Chammas MC, Chaubal NG, Chen MH, Clevert DA, Correas JM, Ding H, Forsberg F, Fowlkes JB, Gibson RN, Goldberg BB, Lassau N, Leen EL, Mattrey RF, Moriyasu F, Solbiati L, Weskott HP, Xu HX, World Federation for Ultrasound in M and European Federation of Societies for U: Guidelines and good clinical practice recommendations for Contrast Enhanced Ultrasound (CEUS) in the liver - update 2012: A WFUMB-EFSUMB initiative in cooperation with representatives of AFSUMB, AIUM, ASUM, FLAUS and ICUS. *Ultrasound Med Biol* (2013) 39: 187–210.
20. Bruix J, Sherman M and American Association for the Study of Liver D: Management of hepatocellular carcinoma: an update. *Hepatology* (2011) 53: 1020–1022.
21. Bruix J, Sherman M, Llovet JM, Beaugrand M, Lencioni R, Burroughs AK, Christensen E, Pagliaro L, Colombo M and Rodes J: Clinical management of hepatocellular carcinoma. Conclusions of the Barcelona-2000 EASL conference. European Association for the Study of the Liver. *J Hepatol* (2001) 35: 421–430.
22. Nouse K, Shiraga K, Uematsu S, Okamoto R, Harada R, Takayama S, Kawai W, Kimura S, Ueki T, Okano N, Nakagawa M, Mizuno M, Araki Y and Shiratori Y: Prediction of the ablated area by the spread of microbubbles during radiofrequency ablation of hepatocellular carcinoma. *Liver Int* (2005) 25: 967–972.
23. Teratani T, Yoshida H, Shiina S, Obi S, Sato S, Tateishi R, Mine N, Kondo Y, Kawabe T and Omata M: Radiofrequency ablation for hepatocellular carcinoma in so-called high-risk locations. *Hepatology* (2006) 43: 1101–1108.