

Acta Med. Okayama, 2015  
Vol. 69, No. 2, pp. 119–122

Copyright©2015 by Okayama University Medical School.

Acta Medica  
Okayama

<http://escholarship.lib.okayama-u.ac.jp/amo/>

Case Report

## A Paraganglioma in a Hypertensive Patient with Unilateral Renal Hypoplasia

Tomohiro Terasaka<sup>a,b\*</sup>, Hideharu Hagiya<sup>a</sup>, Kosuke Kimura<sup>a</sup>, Takahiro Nada<sup>a</sup>,  
Eri Nakamura<sup>a</sup>, Yoshihisa Hanayama<sup>a</sup>, Hitoshi Sugiyama<sup>b</sup>, Yasuyuki Kobayashi<sup>c</sup>,  
Hiroyuki Yanai<sup>d</sup>, and Fumio Otsuka<sup>a</sup>

Departments of <sup>a</sup>General Medicine, <sup>b</sup>Medicine and Clinical Science, <sup>c</sup>Urology and <sup>d</sup>Pathology,  
Okayama University Graduate School of Medicine, Dentistry and Pharmaceutical Sciences, Okayama 700–8558

We report the case of a 46-year-old hypertensive Japanese female with renal insufficiency related to unilateral renal hypoplasia. The patient was found to have developed paraganglioma in the retroperitoneal space over a 5-year period. Catecholamine-producing tumors are not usually recognized as conditions associated with renal hypoplasia. Our long-term observation of the patient eventually led us to the diagnosis of paraganglioma. In hypertensive patients with chronic kidney disease, not only the renin-angiotensin-aldosterone system but also catecholamine activity may be involved, particularly in the patients whose cases are complicated with unilateral renal hypoplasia.

**Key words:** catecholamine, paraganglioma, renal hypoplasia, renovascular hypertension, secondary hypertension

We report the case of a hypertensive patient who developed paraganglioma in the retroperitoneal space of unilateral renal hypoplasia. The co-existence of a catecholamine-producing tumor and unilateral renal hypoplasia is a very rare condition in the clinical setting for hypertension.

### Case Presentation

A 46-year-old Japanese female was referred to our hospital for the evaluation of hypertension with chronic kidney disease (CKD stage G3a1; serum creatinine: 0.84–0.90 mg/dL, eGFR: 54–60 mL/min and no proteinuria). Her hypertension and tachycardia had been identified a few years earlier, and she had been

treated with a small dose of a  $\beta$ -blocker, bisoprolol (2.5 mg/day). Her blood pressure on the first visit was almost normal (109/80 mmHg). She had no abnormal findings regarding her neonatal period and no family history related to multiple endocrine neoplasia type 2 (MEN2) including medullary thyroid carcinoma, pheochromocytoma or parathyroid hyperplasia, though she had a surgical history for parotid cancer.

Abdominal computed tomography (CT) revealed that the right kidney was markedly smaller than the left kidney, but no tumor lesion was detected in the retroperitoneal space (Fig. 1A). The right kidney was morphologically small, but the thickness of the renal cortex to the medullar area was proportional, while the left kidney was marginally enlarged.

The initial endocrine examination showed normal

Received September 10, 2014; accepted October 9, 2014.

\*Corresponding author. Phone: +81-86-235-7342; Fax: +81-86-235-7345  
E-mail: [teras-t@md.okayama-u.ac.jp](mailto:teras-t@md.okayama-u.ac.jp) (T. Terasaka)

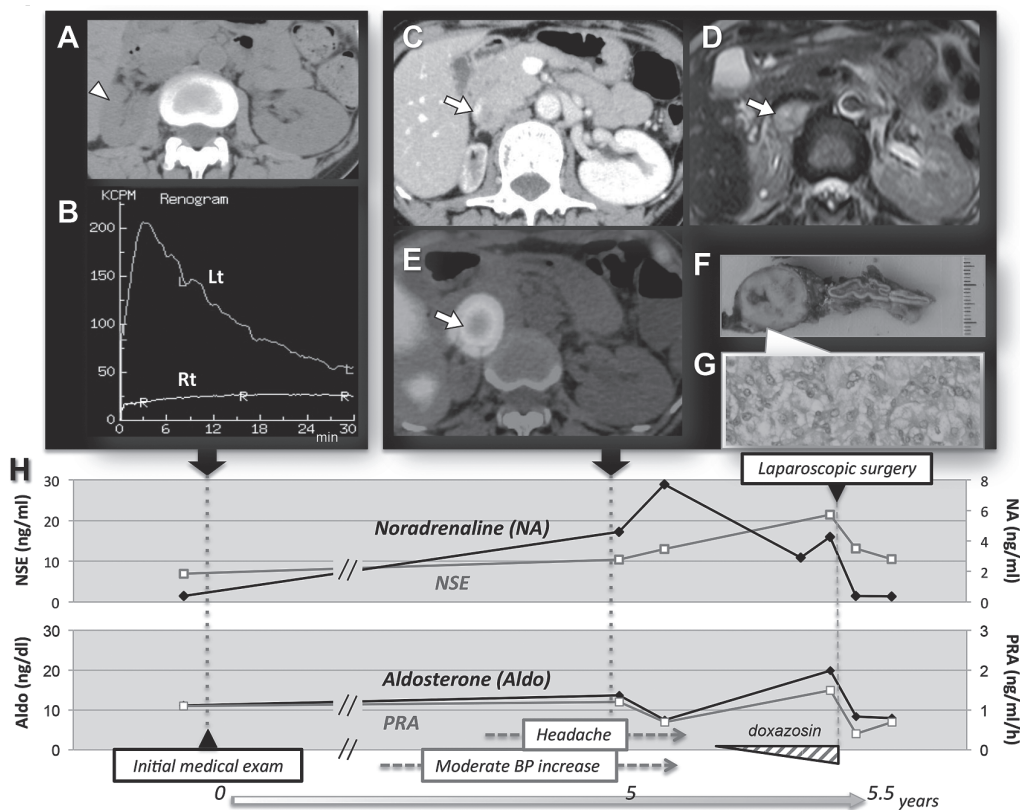
Conflict of Interest Disclosures: No potential conflict of interest relevant to this article was reported.

levels of serum aldosterone (11.2 ng/dL; normal, 3.6–24) and plasma renin activity (PRA; 1.1 ng/mL/h; normal, 0.2–2.7). At that time, the patient's plasma levels of catecholamines were also within normal ranges (adrenaline: 0.03 ng/mL, normal, <0.1; noradrenaline: 0.39 ng/mL, normal, 0.1–0.5; and dopamine: 0.02 ng/dL, normal, <0.03).

To examine the differential function of bilateral kidneys, we performed  $^{99m}\text{Tc}$ -mercaptoacetyltriglycine renography, and it showed functional loss of the right hypoplastic kidney with defects in the vascular phase in contrast to the preserved left side (Fig. 1B). Based on the diagnosis of hypertension possibly related to her right renal ischemia regardless of normal levels of PRA, the patient's renal function and blood pressure were occasionally re-examined. Although a RAS inhibitor as a chronic kidney disease (CKD) treatment was administered once, we discontinued it due to

adverse effects including tachycardia and general fatigue. Her systolic blood pressure, examined in our outpatient clinic over a period of a few years, increased slightly to 120–130 mmHg, though her renal function was not significantly altered.

Five years after her referral to us, she was admitted to a neighboring hospital because of headache and moderate increase of blood pressure (130/84 mmHg) under bisoprolol (3.75 mg/day) treatment. At that time, a screening abdominal CT incidentally uncovered a 2.5-cm mass with early enhancement in the right retroperitoneal region (Fig. 1C). Abdominal magnetic resonance imaging (MRI) exhibited a high-intensified tumor by T2-weighted images (Fig. 1D). Fat-suppression and spectral attenuated inversion recovery (SPAIR) MRI further showed the least inclusion of adipose tissue in the tumor, indicating that the tumor was likely to be a pheochromocytoma or para-



**Fig. 1** A, Right renal hypoplasia (arrowhead) shown by plain abdominal CT; B, Functional defect of the right kidney shown by a renogram; C, An enhanced retroperitoneal tumor (arrow) in the adrenal region shown by contrast-enhanced CT; D, A high-intensified lesion (arrow) shown by T2-weighted MRI; E, Accumulation of  $^{123}\text{I}$ -MIBG tracer (arrow) in the right adrenal region shown by SPECT; F, Gross feature of the resected tumor with adjacent normal adrenal; G, Histological findings of the resected paraganglioma; H, Hormonal changes in the clinical course. Aldo, aldosterone; NA, noradrenaline; NSE, neuron-specific enolase; PRA, plasma renin activity.

ganglioma.

An endocrine examination confirmed that the patient's plasma levels of catecholamines were increased compared to the levels 5 years earlier, as follows: adrenaline, 0.02–0.05 ng/mL, noradrenaline, 4.25–7.71 ng/mL, and dopamine, 0.02–0.07 ng/mL (Fig. 1H). Urinary excretions of noradrenaline and its metabolites were also increased on admission as follows: adrenaline (7.9 µg/day, normal 3–41), noradrenaline (900.9 µg/day, normal 31–160), metanephrine (0.07 mg/day, normal 0.04–0.18), normetanephrine (0.94 mg/day, normal 0.1–0.28), and vanillyl mandelic acid (VMA; 10.1 mg/day, normal 1.5–4.3).

Laboratory data also showed that the patient's renal function (serum creatinine: 0.78–0.86 mg/dL, eGFR 54.7–63.5 mL/min, and proteinuria: 60–100 mg/day) was not significantly changed compared with that 5 years before. Of note, her serum level of neuron-specific enolase (NSE), which was initially 6.95 ng/mL, had increased to 21.5 ng/mL (normal: < 16.3) in 5 years (Fig. 1H). In addition, the levels of plasma adrenocorticotropin (ACTH; 18.3 pg/mL, normal 7.2–63.3), cortisol (14.6 µg/dL, normal 8–25), aldosterone (19.9 ng/dL) and PRA (1.5 ng/mL/h) were within normal ranges.

Single photon emission CT (SPECT) using <sup>123</sup>I-metaiodobenzylguanidine (MIBG) exhibited a specific spot in the right peritoneal lesion (Fig. 1E), leading to the diagnosis of a catecholamine-producing tumor in the right adrenal region. Laparoscopic resection of the tumor was performed after careful preconditioning with oral doxazosin (6 mg/day) and daily transfusion (Fig. 1H). The adjunct right hypoplastic kidney and adrenal gland were also removed en bloc due to tissue adhesion.

The resected tumor was proven to be paraganglioma pathologically separated from the normal adrenal and partly adhered to the right renal capsule (Fig. 1F). The pathological workup showed that the paraganglioma was benign, with 2 points on the PASS (Pheochromocytoma of the Adrenal Gland Scaled Score) consisting of capsular invasion and profound nuclear pleomorphism [1] (Fig. 1G). Renal pathology also revealed that the resected kidney had a hypoplastic feature but no atrophic change, based on the reduced number of normal glomeruli in the resected renal specimens. After the surgery, no antihypertensive drug was needed and the patient's

renal function was nearly preserved (eGFR of 50–60 mL/min).

## Discussion

Catecholamine-producing tumors such as pheochromocytomas and paragangliomas are not clinically recognized as conditions associated with renal hypoplasia. However, the occurrence of a pheochromocytoma in patients complicated with renal agenesis or hypoplasia has occasionally been reported [2, 3]. The genes *RET*, *VHL*, *NF1* and *SDH* are known to be related to the development of pheochromocytomas and paragangliomas [4–6]. Renal malformation and/or agenesis is likely to be linked to the *RET* mutation that is associated with MEN2 including pheochromocytomas. The *RET* gene seems to be functionally involved in the embryonic process of renal formation and renal development in mammals [7, 8].

Although the *RET* oncogene mutation was not examined in our patient because of the lack of a significant family history, we cannot completely exclude the possibility of occult *RET* mutation in our patient in light of her history of parotid cancer and the 5% rate of sporadic MEN2 patients [8]. In another case, renal arterial stenosis secondarily caused by a catecholamine-producing tumor was reported [9]. In that patient, the ipsilateral renal feeding artery was compressed by the adjacent enlarged tumor [9], unlike our patient's hypoplastic kidney.

In the present case, the first hospital visit was due to mild hypertension and CKD complicated with unilateral renal hypoplasia. However, long-term observation eventually led us to the diagnosis of a catecholamine-producing tumor (Fig. 1H). In our patient, a *RET* gene analysis was not performed because we could not obtain the patient's permission. In any case, careful follow-up is needed in the future due to the risk of recurrence and/or occurrence of MEN2-related lesions. Physicians sometimes come across hypertensive patients with an atrophic unilateral kidney. In such cases, the patient's renin-angiotensin-aldosterone system (RAS) should be evaluated first in order to exclude the possibility of renovascular hypertension. The pathophysiologic relationship between renal hypoplasia and paraganglioma remains unclear. However, it would be clinically important to check catecholamine levels as well in hypertensive patients

to rule out the existence of catecholamine-producing tumors, particularly in patients complicated with unilateral renal hypoplasia.

### References

1. de Wailly P, Oragano L, Rade F, Beaulieu A, Arnault V, Levillain P and Kraimps JL: Malignant pheochromocytoma: New malignancy criteria. *Langenbecks Arch Surg* (2012) 397: 239–246.
2. Hibi Y, Ohye T, Ogawa K, Shimizu Y, Shibata M, Kagawa C, Mizuno Y, Kurahashi H and Iwase K: A men2a family with two asymptomatic carriers affected by unilateral renal agenesis. *Endocr J* (2014) 61: 19–23.
3. Wang HD, Li GZ, Wang JW, Liu N, He F and Man LB: Laparoscopic adrenalectomy of a large pheochromocytoma in a multiple endocrine neoplasia-2a patient with renal agenesis. *Chin Med J (Engl)* (2013) 126: 2996.
4. Dahia PL: Pheochromocytoma and paraganglioma pathogenesis: Learning from genetic heterogeneity. *Nat Rev Cancer* (2014) 14: 108–119.
5. Galan SR and Kann PH: Genetics and molecular pathogenesis of pheochromocytoma and paraganglioma. *Clin Endocrinol (Oxf)* (2013) 78: 165–175.
6. Andreasson A, Kiss NB, Caramuta S, Sulaiman L, Svahn F, Backdahl M, Hoog A, Juhlin CC and Larsson C: The vhl gene is epigenetically inactivated in pheochromocytomas and abdominal paragangliomas. *Epigenetics* (2013) 8: 1347–1354.
7. Mologni L: Development of ret kinase inhibitors for targeted cancer therapy. *Curr Med Chem* (2011) 18: 162–175.
8. Gestblom C, Sweetser DA, Doggett B and Kapur RP: Sympathoadrenal hyperplasia causes renal malformations in ret(men2b)-transgenic mice. *Am J Pathol* (1999) 155: 2167–2179.
9. Camberos A, Bautista N, Rubenzik M and Applebaum H: Renal artery stenosis and pheochromocytoma: Coexistence and treatment. *J Pediatr Surg* (2000) 35: 714–716.