

Increase of DC-LAMP+ mature dendritic cell subsets in dermatopathic lymphadenitis of mycosis fungoides

Kotaro TADA^{1,2}, Toshihisa HAMADA¹, Kenji ASAGOE³, Hiroshi UMEMURA¹, Kazuko MIZUNO-IKEDA¹, Yumi AOYAMA¹, Masaki OHTSUKA¹, Osamu YAMASAKI¹, Keiji IWATSUKI¹

1. Department of Dermatology, Okayama University Graduate School of Medicine, Dentistry, and Pharmaceutical Sciences, 2-5-1 Shikata-cho, Kita-ku, Okayama 700-8558, Japan. Tel: +81-86-235-7282; Fax: +81-86-235-7283.

2. Department of Dermatology, Kurashiki Daiichi Hospital, 5-3-10 Oimatu-cho, Kurashiki 710-0826, Japan. Tel: +81-86-424-1000; Fax: +81-86-421-4254.

3. Department of Dermatology, Okayama Medical Center, Japan. 1711-1 Tamasu, Kita-ku, Okayama 701-1192, Japan. Tel: +81-86-294-9911; Fax: +81-86-294-9255.

Reprints: K Iwatsuki, (e-mail: kejijiwa@cc.okayama-u.ac.jp)

Tel: +81-86-235-7282; Fax: +81-86-235-7283

Author Contributions: Dr. K. Tada has full access to all of the data in the study and takes responsibility for the integrity of the data and the accuracy of the data analysis. *Study concept and design:* Hamada, Asagoe and Iwatsuki. *Acquisition of data:* Tada, Hamada, Asagoe, Umemura, Ikeda, Ohtsuka and Yamasaki.

Analysis and interpretation of data: Tada, Hamada, Asagoe and Aoyama.

Drafting of the manuscript: Tada, Hamada and Iwatsuki. *Administrative, technical, or material support:* Hamada and Umemura. *Study supervision:* Aoyama and Iwatsuki

Funding/Support: A grant from the Ministry of Health, Labour and Welfare (Research for Promotion of Cancer Control Programmes: Principal Investigators; Drs. Uchimaru, and Hirata).

Role of the Sponsors: No sponsors for this study.

Financial Disclosure: None of the authors have relevant financial interest in this article.

Acknowledgment: This work was partly supported by a grant from the Ministry of Health, Labour and Welfare (Research for Promotion of Cancer Control Programmes).

Running Title: Dendritic cell subsets in dermatopathic lymphadenitis.

Word count: Abstract, 192 words; Text, 1900 words.

Corresponding Author: K Iwatsuki, Department of Dermatology, Okayama University Graduate School of Medicine, Dentistry, and Pharmaceutical Sciences, 2-5-1 Shikata-cho, Okayama 700-8558, Japan.

Tel: +81-86-235-7282; Fax: +81-86-235-7283

(e-mail: keijiwa@cc.okayama-u.ac.jp)

Background: Little has been known about the immunological milieu of the skin-draining lymph nodes (LNs) in mycosis fungoides (MF). *Objectives:* We studied dendritic cell (DC) subsets in the dermatopathic lymphadenitis of MF patients. *Methods:* We immunohistochemically examined DC subsets and their distribution in 16 LN samples from 14 patients with MF (N1 LN, eight patients; N2, four; and N3, four), and we compared them with non-metastatic sentinel LNs from eight patients with melanoma. *Results:* The number of S-100 protein+ DCs was markedly increased in the LNs from the MF patients, and the major component was DC-LAMP+ mature DCs in the outer and paracortex areas, where DC-SIGN+ immature DCs were relatively decreased in proportion. In contrast, DC-SIGN+ cells were relatively increased in proportion compared to DC-LAMP+ cells in the medulla. Although no significant difference was observed in the proportions of CD1a+ or Langerin+ DCs among the N1, N2, and N3 nodes, CD163+ M2-type macrophages were increased in number in the N2 and N3 nodes. *Conclusions:* Our observations indicate that mature DCs were accumulated in the outer and paracortex areas in dermatopathic lymphadenitis, and M2-type macrophages might increase in number during disease progression.

Key words: Mycosis fungoides, dendritic cell, dermatopathic lymphadenitis, DC-LAMP, DC-SIGN, M2-type macrophage.

Mycosis fungoides (MF) is the most common type of cutaneous T-cell lymphoma (CTCL), characterized by the epidermotropic infiltration of clonal CD4-positive T-lymphocytes. Typically, the clinical course of MF is indolent with a slow progression from patches to plaques, and occasionally to tumors. MF lesions start and progress predominantly in the skin and eventually to lymph nodes (LNs) and/or peripheral blood [1, 2]. In 2007, a revised version of the MF/Sézary syndrome (SS) staging system was proposed through several consensus meetings, based on the histopathological, phenotypic and molecular characteristics of MF/SS [3], and the system was further revised in 2011 [4]. The LN involvement in MF/SS has been classified into four categories: N0, N1, N2 and N3. The N1 and N2 categories correspond to the previous designation “dermatopathic lymphadenitis” with the minimal involvement of neoplastic T cells. Partially or completely effaced LNs in MF/SS, designated N3, uniformly show a clonal rearrangement of T-cell receptor (TCR). A key aspect of the N classification depends on the histopathological findings, including the degree of infiltrating malignant cells into LNs and the nodal architecture. The recent elucidation of the immunological background of MF/SS has provided a more comprehensive view of the immunological milieu, especially in the skin and peripheral blood. Although the role of dendritic cells (DCs) in CTCL has been gradually clarified [2, 5, 6], little has been known about DC subsets and their properties in the node involvement. In the present study, to clarify the immunological milieu of the skin-draining LNs in CTCL, we examined DC phenotypes and their distribution in LNs from patients with MF (16 samples from 14 patients), and compared them with those of non-metastatic sentinel LNs from eight patients with melanoma (pT1–pT4b).

Materials and methods

Patients and materials

Sixteen inguinal LN samples from 14 patients with MF were used for the present study (*table 1*). All patients were fully assessed by clinicopathological findings,

radiological examination and laboratory data according to the TNM classification for MF/SS [3, 4]. The diagnoses were stage IIA in six patients, IIB in two, IIIA in two, and IVA2 in four. Eight of the 16 LNs were an N1 node, four were an N2 node, and four were an N3 node.

Eight non-metastatic sentinel LNs from eight patients with melanoma (tumor stage pT1a, two patients; pT2b, two; pT3b, one; pT4a, two; pT4b, one), were used as a control group. Five LNs were obtained from the inguinal area, two LNs were from cervical area and one was from axillae. Although these LNs did not show any histopathologic changes suggestive of dermatopathic lymphadenitis, we could not exclude the possibility of some alterations in the cellular components because of the draining LNs of the melanoma patients.

The present study was approved by the Institutional Review Board of Okayama University Hospital (No. 952), and all patients provided written informed consent to have their skin biopsy or LN resection used, in accord with the 1975 Declaration of Helsinki.

Immunohistochemistry

All biopsy specimens from the resected LNs were fixed in 10% formalin and embedded in paraffin in a routine manner. Tissue sections were cut and then stained with hematoxylin and eosin. Immunohistochemical staining was performed with antibodies to CD3, CD4, CD8, CD20, CD79a, S-100 protein, CD1a, CD14, CD68, DC-LAMP (CD208), DC-SIGN (CD209), Langerin (CD207), and CD163. Antibodies were purchased from Nichireibio (CD3, CD20, CD79a), Becton Dickinson (CD4, CD8), Dako (S-100 protein, CD68), Immunotech (CD1a, DC-LAMP), Novocastra (Langerin, CD14), Abcam (DC-SIGN), and Biorbyt (CD163).

The absence of metastasis in the sentinel LN samples from the melanoma patients was confirmed by two methods: immunohistochemistry with antibodies to S-100 protein (Dako), HMB-45 (Signet), Tyrosinase (Novocastra) and MART-1 (Dako) and reverse transcriptase-polymerase chain reaction (RT-PCR) using primer sets specific for gp100, melan A, and tyrosinase.

Formalin-fixed, paraffin-embedded specimens were deparaffinized with xylol, and antigen retrieval was performed with S1699 solution (Dako) in a water bath at 96°C for 40 min. The sections were incubated with first antibodies at room temperature for 60 min, and further reacted by the avidin-biotin complex/alkaline phosphatase method (E0678: Dako Cytomation, Glostrup, Denmark).

Double immunofluorescence staining

Tissue sections were first incubated with rabbit anti-human S-100 protein antibody, then incubated with mouse monoclonal anti-human CD1a, CD207/Langerin, CD208/DC-LAMP, CD209/DC-SIGN, CD68, or CD14 at room temperature for 60 min. The sections were further reacted with fluorescence isothiocyanate (FITC)-conjugated donkey anti-rabbit IgG (Green) and Cy3-conjugated donkey anti-mouse IgG (Red) at 4°C overnight.

Digital images

Digital images were obtained using a photo-imaging system (V-100, Olympus, Tokyo). The numbers of the antibody-positive cells were enumerated in three randomly selected fields (original magnification; $\times 400$) per section, and the results are expressed as the mean \pm standard deviation (SD)/mm². The proportion of antibody-positive cells is expressed as the percentage of the antibody-positive cell number compared to the S-100 protein-positive cell number.

Statistical analysis

The comparisons between the MF and control groups were performed using Mann-Whitney's U-test, with a significance level of $p < 0.01$ and $p < 0.05$.

Results

DC subsets in dermatopathic lymphadenitis

Compared with the non-metastatic sentinel LNs from melanoma patients, dermatopathic lymphadenitis, including the N1 and N2 of MF patients, revealed the accumulation of S-100 protein+ T-zone histiocytes in the outer and paracortex areas (642.5 ± 133.4 vs. 201.3 ± 94.5 , $p=0.0002$) (*figure 1*). The N2 LNs showed maximal S-100 protein+ cell infiltration, whereas the N3 nodes contained a decreased number of S-100 protein+ cells because of the massive infiltration of neoplastic cells (N1 vs. N2: 580.0 ± 85.2 vs. 767.5 ± 130.5 , $p=0.027$; N2 vs. N3: 767.5 ± 130.5 vs. 253.3 ± 118.4 , $p=0.0095$). The numbers of other DC subsets in the N1 and N2 LNs were as follows: mean number of DC-LAMP+ cells, 508.3 ± 121.0 ; CD1a+ cells, 211.7 ± 104.2 ; DC-SIGN+ cells, 95.8 ± 76.6 ; Langerin+ cells, 85.0 ± 33.7 .

In the N1 and N2 LNs, various types of DC subsets and other non-lymphoid cell types were detected by the double immunofluorescence study. The vast majority of S-100 protein+ cells co-expressed DC-specific antigens including CD1a, Langerin (CD207), DC-SIGN (CD209) and DC-LAMP (CD208) (*figure 2*). Most of the S-100 protein+ cells were negative for CD68 and CD14, although the exact discrimination of the co-expression was limited in the tissue sections.

Localization of DC subsets in the LNs

S-100 protein+ cells were distributed, at various densities, throughout the entire cortex, lymph follicles, and medulla in the LNs obtained from the patients with MF or melanoma. We focused on the DC subsets infiltrating in the outer cortex, paracortex and medulla, excluding S-100 protein+ follicular dendritic cells. Compared to the non-metastatic LNs from melanoma patients, DC-LAMP (CD208)+ cells were significantly increased in density in the outer and paracortex areas (T-cell zone) of the N1 and N2 LNs from MF patients, where a small number of DC-SIGN (CD209)+ cells were present (*figure 3*). No difference was observed in the localization of Langerin (CD207)+ or CD1a+ cells; these cell

types were present in the outer and paracortex areas and the medulla. These observations indicated that mature DC-LAMP (CD208)+ cells were a major component of S-100 protein+ DCs in the outer and paracortex areas.

Proportion of DC subsets to S-100 protein+ cells in the N1, N2 and N3 nodes

Many S-100 protein+ cells, designated as “T-zone histiocytes” were found in the outer and paracortex areas of the N1 and N2 LNs. The proportion of DC-LAMP(CD208)+ cells to all S-100 protein+ cells was significantly increased in the outer and paracortex areas of MF compared to those in the non-metastatic LNs of melanoma (median proportion: N1 LNs, 77.0% vs. 39.5%, $p=0.0009$; N2 LNs, 85.5% vs. 39.5%, $p=0.0084$, respectively) (*figure 4*). No difference was observed in the density of DC-LAMP (CD208)+ cells between the N1 and N2 LNs (median 80.5% vs. 87.0%, $p=0.5515$, respectively).

The proportion of DC-SIGN+ cells was significantly decreased in the dermatopathic lymphadenitis of MF (N1+N2) compared to that of the control group (14.5% vs. 36.6%, $p=0.0481$, respectively), although there was no significant difference between the N1 and N2 LNs. No significant difference was observed in the proportion in the N1 (14.5%, $p=0.1008$) or N2 LNs (11.0%, $p=0.1054$), as compared with those in control (median proportion: 36.5%). No significant difference was observed in the proportion of CD1a+ or Langerin (CD207)+ cells to S-100 protein+ cells between the N1 and N2 LNs (CD1a+: 34.0% vs. 42.0%, $p=0.5697$; Langerin+: 13.5% vs. 16.0%, $p=0.6085$, respectively), or between the MF (N1+N2) and melanoma groups (CD1a+: 34.5% vs. 40%, $p=0.938$; Langerin (CD207)+: 13.5% and 13.5%, $p=0.969$, respectively) (*figure 5*).

Increase of CD163+ M2-type macrophages in the N2 nodes

CD163+ M2-type macrophages were absent or at the background level in the early stage of dermatopathic lymphadenitis in the N1 LNs, but the number of CD163+ cells was increased in the N2 and N3 nodes (*figure 6*). The mean

numbers of CD163+ cells in the N2 and N3 nodes were 4.8 ± 2.6 cells/high-power field (HPF) and 2.0 ± 0.8 cells/HPF, respectively.

Discussion

Dermatopathic lymphadenitis is a reactive lymphoid hyperplasia that commonly involves regional LNs in patients with MF [7, 8]. The histopathologic hallmark is a marked expansion of the paracortex areas because of the infiltration of pale-staining cells, designated as T-zone histiocytes, representing both interdigitating reticulum cells and Langerhans cells [9, 10]. S-100 protein is a characteristic marker for DCs in LNs, but we could not exclude a small number of non-DCs positive for S-100 protein such as benign nevocytes, sinus histiocytes, and Schwann cells. Our present findings demonstrated that a variety of DC subsets were accumulated in the outer cortex, paracortex, and medulla in the N1 and N2 LNs, where DC-LAMP+ DCs were a major subset, followed by CD1a+, DC-SIGN+, and Langerin (CD207)+ DCs.

DC-LAMP (CD208) is a molecule specifically expressed by mature DCs, and DC-SIGN (CD209) is known to be expressed by immature DCs, which are capable of inducing immunological tolerance [5]. Although we observed S-100 protein+ cells throughout the LNs in the present study, the localization of DC subsets was characteristic: mature DC-LAMP (CD208)+ cells were observed mainly in the outer and paracortex areas and conversely decreased in number in the medulla. In contrast, immature DC-SIGN (CD209)+ cells were observed predominantly in the medulla.

It was reported that the presence of mature DC-LAMP (CD208)+ cells and activated T-cells was associated with the longer survival of patients with melanoma and that these cells could be a marker of a functional immune response against melanoma progression, then the high density of DC-LAMP (CD208)+ cells in melanoma draining sentinel LNs is associated with significant and prolonged overall survival benefit, reinforcing the notion that the immune system plays an active role in limiting the spread of melanoma [11, 12]. In

addition, a dynamic change of DC subsets was reported, in which mature DC subsets such as CD83+ and DC-LAMP (CD208)+ cells were decreased in number prior to the metastatic invasion of breast carcinoma cells to the LNs; once the metastasis was established however, mature DCs were increased in number, associated with the Th1-skewed immune responses [13]. As discussed in melanoma, we speculate that the increase of mature DC-LAMP (CD208)+ DCs with a concomitant decrease of DC-SIGN (CD209)+ DCs might be induced by the invasion of neoplastic MF cells to the LNs, and may contribute to the protection of tumor growth.

Although we observed no clear difference in the DC subset proportion between the N1 and N2 LNs, the numbers of CD163+ M2-type macrophages were different: they were absent or at a background level in the N1 LNs and increased in the N2 and N3 LNs. CD163+ M2-type macrophages produce interleukin (IL)-10, IL-1 β , and vascular endothelial growth factor (VEGF), which contribute to tumor growth. In the present study, one patient with N2 LNs (stage IIB) progressed to the N3 stage associated with erythroderma within 55 months, and died of tumor progression and bacterial infection. Another patient (stage IIIA) had no progression of the illness in a 46-month follow-up period.

The presence of many DC-LAMP (CD208)+ DCs with a concomitant decrease of DC-SIGN (CD209)+ and scant infiltration of CD163+ M2-type macrophages in the outer and paracortex in N1 LNs might be protective for tumor growth. In contrast, the increased number of CD163+ M2-type macrophages might be responsible for the progression from N1 to N2 LNs.

Disclosure

Financial support: This work was partly supported by a grant from the Ministry of Health, Labour and Welfare (Research for Promotion of Cancer Control Programmes). Conflict of interest: NONE.

References

1. Hwang ST, Janik JE, Jaffe ES, Wilson WH. Mycosis fungoides and Sézary syndrome. *Lancet* 2008; 371: 945-57.
2. Kim EJ, Hess S, Richardson SK, et al. Immunopathogenesis and therapy of cutaneous T cell lymphoma. *J Clin Invest* 2005; 115: 798-812.
3. Olsen E, Vonderheid E, Pimpinelli N, et al. Revisions to the staging and classification of mycosis fungoides and Sezary syndrome: a proposal of the International Society for Cutaneous Lymphomas (ISCL) and the cutaneous lymphoma task force of the European Organization of Research and Treatment of Cancer (EORTC). *Blood* 2007; 111: 1713-22.
4. Olsen EA, Whittaker S, Kim YH, et al. Clinical End Points and Response Criteria in Mycosis Fungoides and Sezary Syndrome: A Consensus Statement of the International Society for Cutaneous Lymphomas, the United States Cutaneous Lymphoma Consortium, and the Cutaneous Lymphoma Task Force of the European Organisation for Research and Treatment of Cancer. *J Clin Oncol* 2011; 29: 2598-607.
5. Schlapbach C, Ochsenbein A, Kaelin U, Hassan AS, Hunger RE, Yawalkar N. High numbers of DC-SIGN⁺ dendritic cells in lesional skin of cutaneous T-cell lymphoma. *J Am Acad Dermatol*. 2010; 62: 995-1004.
6. Der-Petrossian M, Valencak J, Jonak C, et al. Dermal infiltrates of cutaneous T-cell lymphomas with epidermotropism but not other cutaneous lymphomas are abundant with langerin⁺ dendritic cells. *J Eur Acad Dermatol Venereol*. 2011; 25: 922-7.
7. Burke JS, Colby TV. Dermatopathic lymphadenopathy. Comparison of cases associated and unassociated with mycosis fungoides. *Am J Surg Pathol*. 1981 ; 5: 343-52.
8. Colby TV, Burke JS, Hoppe RT. Lymph node biopsy in mycosis fungoides. *Cancer*. 1981; 47: 351-9.
9. Rausch E, Kaiserling E, Goos M. Langerhans cells and interdigitating reticulum cells in the thymus-dependent region in human dermatopathic lymphadenitis. *Virchows Arch B Cell Pathol*. 1977; 25: 327-43.
10. Lampert IA, Pizzolo G, Thomas A, Janossy G. Immuno-histochemical

characterisation of cells involved in dermatopathic lymphadenopathy. *J Pathol.* 1980; 131: 145-56.

11. Ladányi A, Kiss J, Somlai B, et al. Density of DC-LAMP(+) mature dendritic cells in combination with activated T lymphocytes infiltrating primary cutaneous melanoma is a strong independent prognostic factor. *Cancer Immunol Immunother.* 2007; 56: 1459-69.

12. Elliott B, Scolyer RA, Suci S, et al. Long-term protective effect of mature DC-LAMP+ dendritic cell accumulation in sentinel lymph nodes containing micrometastatic melanoma. *Clin Cancer Res.* 2007; 13: 3825-30.

13. Matsuura K, Yamaguchi Y, Ueno H, Osaki A, Arihiro K, Toge T. Maturation of dendritic cells and T-cell responses in sentinel lymph nodes from patients with breast carcinoma. *Cancer.* 2006; 106: 1227-36.

Legends

Figure 1. Histopathological features of examined LNs. MF patients: (A-F). Control (melanoma) patients: (G, H). Hematoxylin-Eosin stainings (N1: A; N2: C; N3: E; Control: G). Immunohistochemical stainings: S-100 protein (N1: B; N2: D; N3: F; Control: H). N1 and N2 revealed the accumulation of S-100 protein+ cells in the outer and paracortex areas. Bar indicate 500 µm in length.

Figure 2. Immunofluorescence study of the N1 LNs. (S-100 protein: (A-F); CD1a: G; Langerin: H; DC-LAMP: I; DC-SIGN: J; CD68: K; CD14: L). (Overlay S-100 protein/CD1a: M; S-100 protein/Langerin: N; S-100 protein/DC-LAMP: O; S-100 protein/DC-SIGN: P; S-100 protein/CD68: Q; S-100 protein/CD14: R). CD68+ cells are distinct from S-100 protein+ cells. Most CD14+ cells are distinct from S-100 protein+ cells. Langerin+, CD1a+, DC-SIGN+ and DC-LAMP+ cells co-expressed S-100 protein.

Figure 3. Localization of DC subsets in the LNs. MF: (A, C, E, G); Control: (B, D, F, H); DC-LAMP: (A, B); DC-SIGN: (C, D); CD1a: (E, F); Langerin: (G, H). Compared with the control, DC-LAMP (CD208)+ cells are significantly increased in density in the outer and paracortex areas (T-cell zone) of the N1 and N2, where a small number of DC-SIGN (CD209)+ cells are present. Bar indicate 200 µm in length.

Figure 4. The proportion of DC-LAMP+ cells in the N1 and N2 LNs are significantly increased in outer and paracortex areas of MF, as compared with those in control. The median proportion: N1: 77.0% vs. 39.5%, ** $p=0.0009$, and N2: 85.5% vs. 39.5%, ** $p=0.0084$, respectively.

The Mann-Whitney U test, with a significance level of ** $p<0.01$ and * $p<0.05$.

Figure 5. The proportion of DC-SIGN+ cells is significantly decreased in the MF compared to that of the control group (14.5% vs. 36.6%, $p=0.0481$, respectively). No significant difference is observed in the proportion of CD1a+ or Langerin

(CD207)+ cells between the MF and control groups (CD1a+: 34.5% vs. 40%, $p=0.938$; Langerin (CD207)+: 13.5% and 13.5%, $p=0.969$, respectively).

The Mann-Whitney U test, with a significance level of ** $p<0.01$ and * $p<0.05$

Figure 6. CD163+ cells in the LNs of MF. N1: **A**; N2: **B**; N3: **C**; magnifying image of A: **D**; magnifying image of B: **E**; magnifying image of C: **F**. The number of CD163+ cells is increased in the N2 and N3. (4.8 ± 2.6 /HPF and 2.0 ± 0.8 /HPF, respectively). Bar indicate 200 μm in length.

HPF: high power field

Table 1.

Table 1. Clinical stages of patients studied.

No. Age/Sex	Clinical stage	Anatomical site of LN	TCR rearrangement
1. 60 M	T3 N2 M0 B0 stage II B	Inguinal	N.D
2. 61 M	T2 N1 M0 B0 stage II B	Inguinal	(-)
3. 59 F	T2b N1 M0 B0 stage II A	Inguinal	(-)
4. 73 F	T2b N2 M0 B0 stage II A	Inguinal	(-)
5. 57 F	T4 N1 M0 B0 stage III A	Inguinal	(-)
	The same as NO.5	Inguinal	(-)
6. 70 F	T4 N2 M0 B0 stage III A	Inguinal	(-)
	The same as NO.6	Inguinal	(-)
7. 48 F	T2 N1 M0 B0 stage II A	Inguinal	N.D
8. 46 M	T2b N1 M0 B0 stage II A	Inguinal	N.D
9. 63 F	T2a N1 M0 B0 stage II A	Inguinal	(+)
10. 37 F	T2 N1 M0 B0 stage II A	Inguinal	(-)
11. 53 M	T3 N3 M0 B0 stage IV A2	Inguinal	(+)
12. 34 M	T3 N3 M0 B0 stage IV A2	Inguinal	(+)
13. 35 F	T3 N3 M0 B0 stage IV A2	Inguinal	N.D
14. 56 M	T3 N3 M0 B0 stage IV A2	Inguinal	(+)

TCR: T cell receptor; LN: Lymph node

Figure 1.

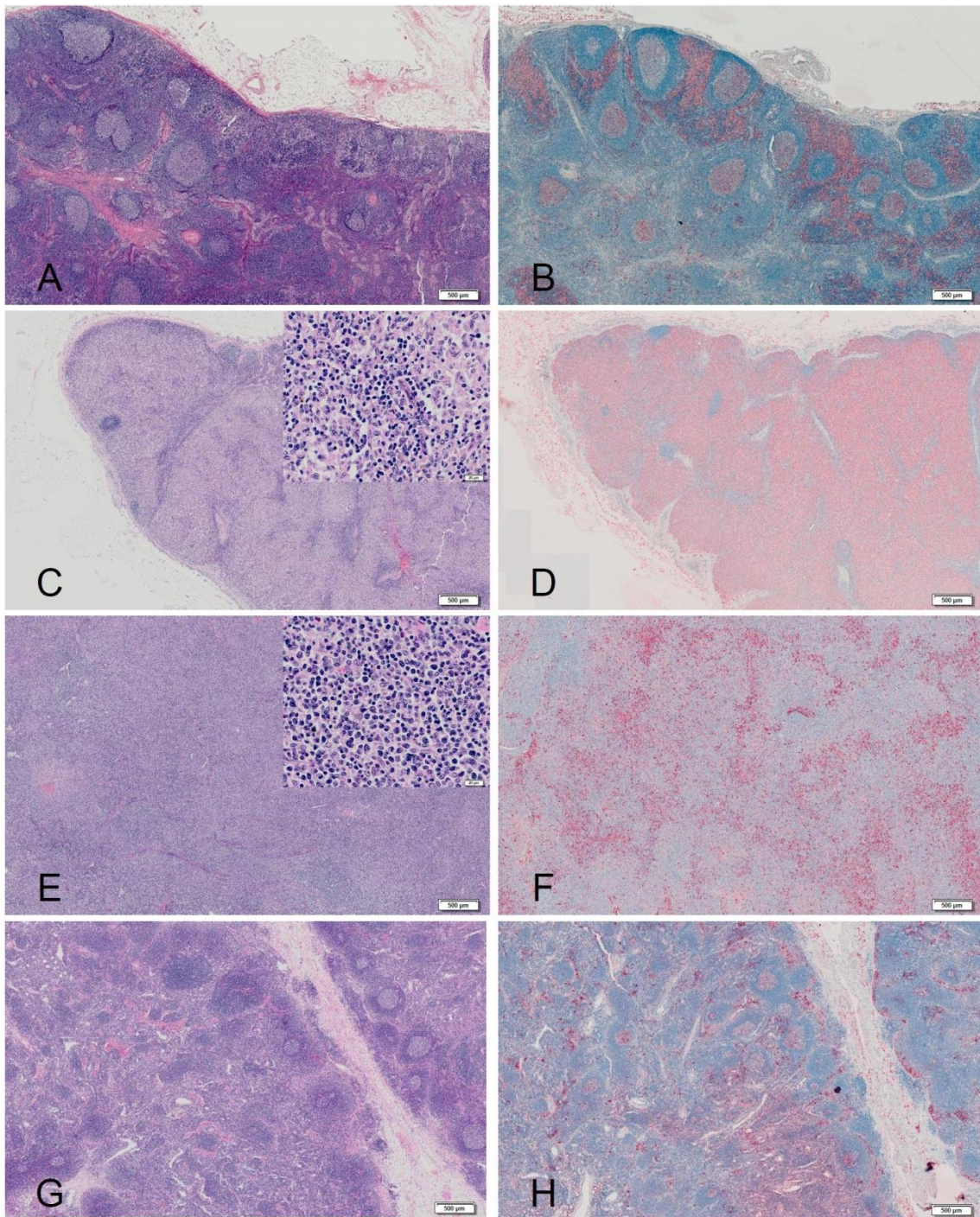


Figure 2.

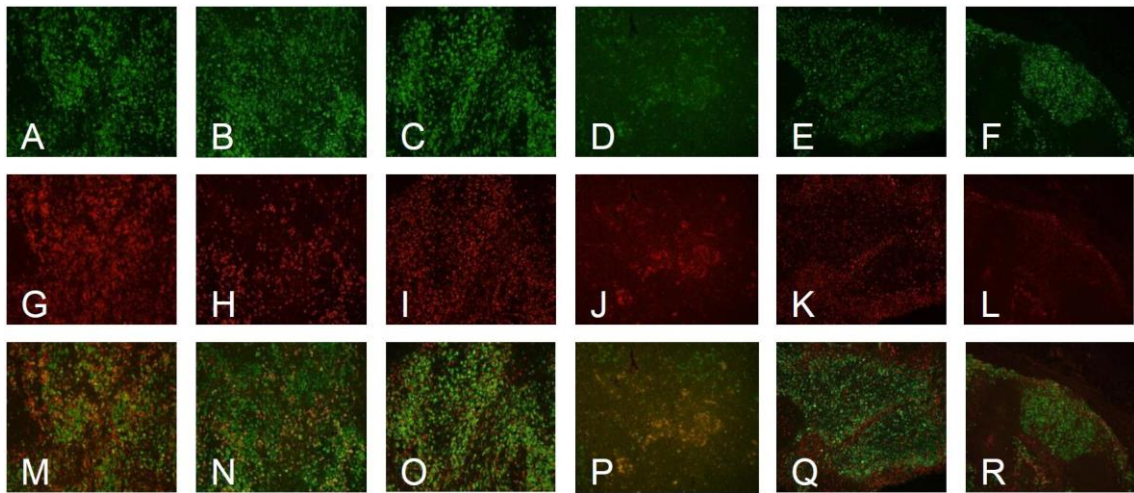


Figure 3.

MF

Control

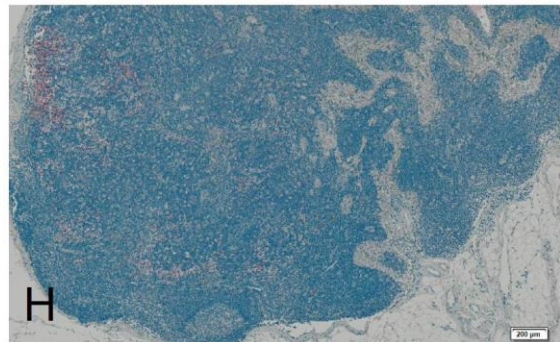
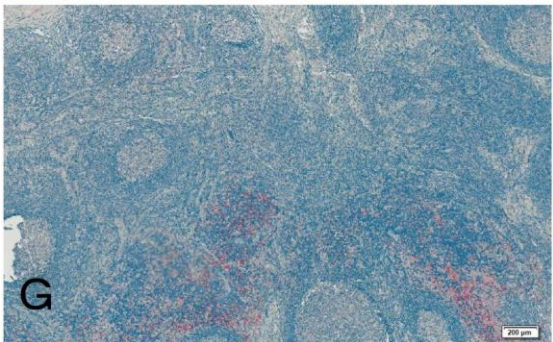
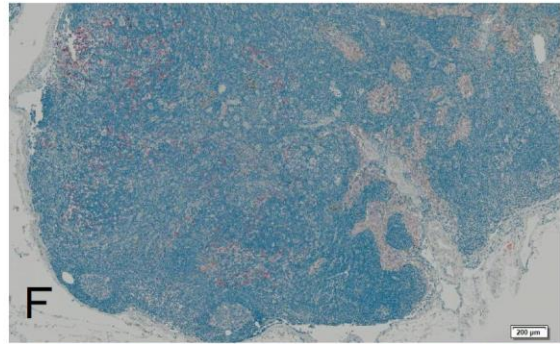
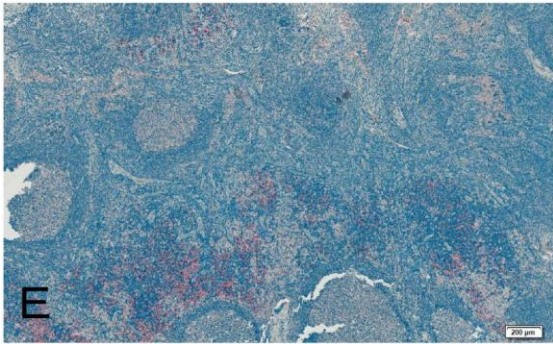
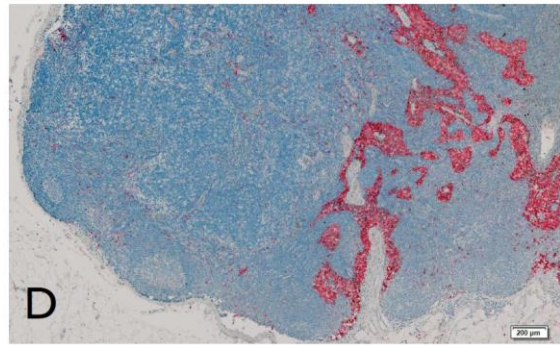
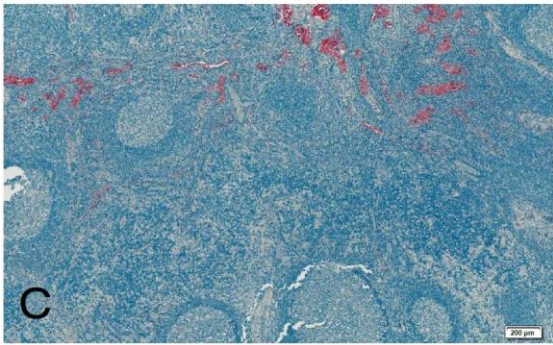
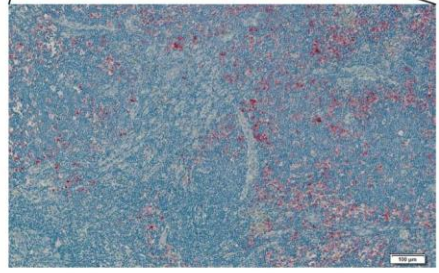
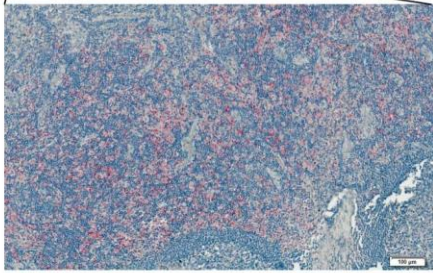
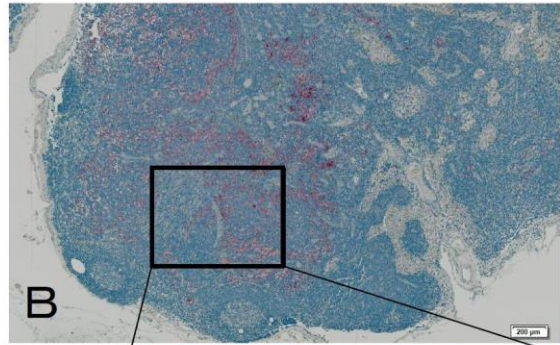
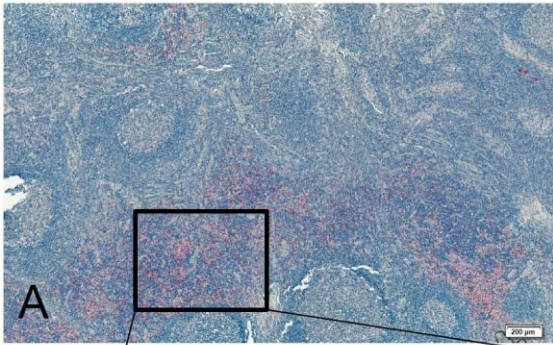


Figure 4.

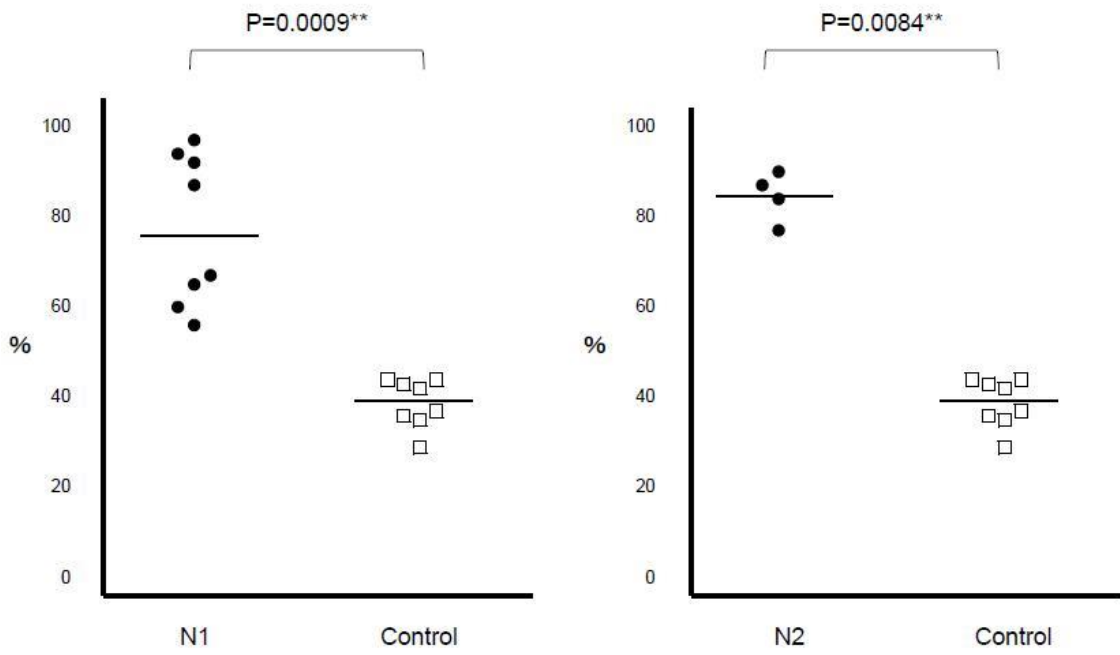


Figure 5.

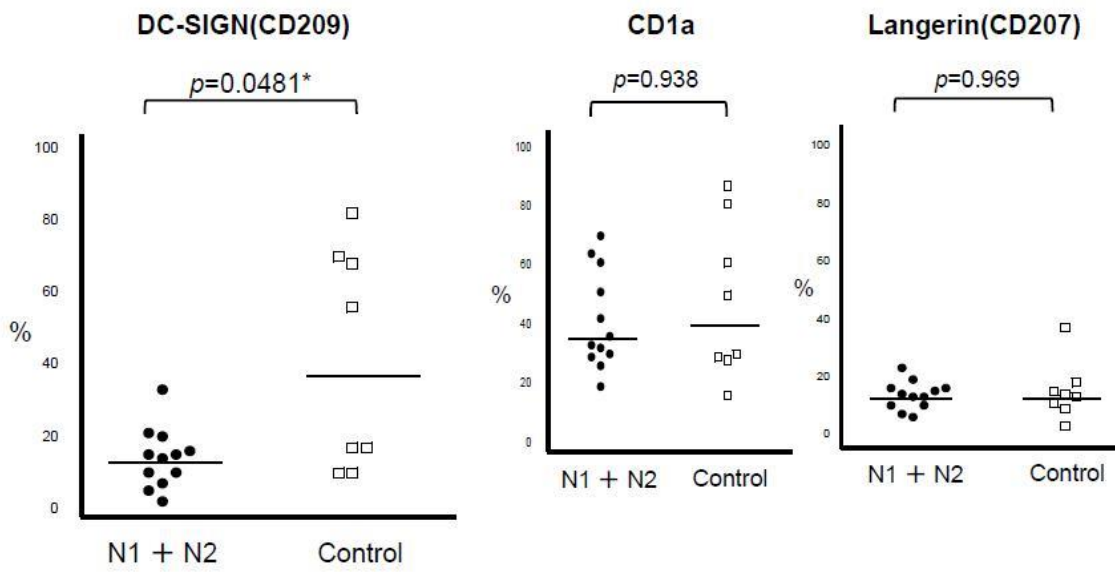


Figure 6.

