

MRI of Rheumatoid Arthritis: Comparing the Outcome Measures in Rheumatology Clinical Trials (OMERACT) Scoring and Volume of Synovitis for the Assessment of Biologic Therapy

Ryuichi Nakahara^{a*}, Keiichiro Nishida^b, Kenzo Hashizume^a, Ryouzou Harada^a,
Takahiro Machida^a, Masahiro Horita^a, Aiji Ohtsuka^b, and Toshifumi Ozaki^a

Departments of ^aOrthopaedic Surgery, and ^bHuman Morphology, Okayama University Graduate School of Medicine,
Dentistry and Pharmaceutical Sciences, Okayama 700-8558, Japan

The outcome measures in rheumatology clinical trials (OMERACT) scores are the most mature quantitation system for rheumatoid arthritis (RA) on magnetic resonance imaging (MRI). Direct measuring techniques of synovial volume have been reported with good reproducibility, although few reports have demonstrated the changes of these measures in response to treatment. To assess these clinical responses, we evaluated the correlation of the changes of clinical activity score 28-joints disease activity score (DAS28-CRP) with the changes of OMERACT scores and with synovial volume measurements. Eight RA patients who were treated by biologic agents were examined with MRI of the dominant affected wrist and finger joints before and one year after the treatment. The total OMERACT score was reduced from 48.0 to 41.3, and synovial volume was reduced from 15.4 to 8.8 milliliters. Positive correlations were seen between the changes of DAS28-CRP and the changes of OMERACT synovitis score ($r = 0.27$), OMERACT total score ($r = 0.43$) and synovial volume ($r = 0.30$). Limited to synovium assessment, synovial volume showed a better correlation with DAS28-CRP than the OMERACT synovitis score. On the other hand, the OMERACT total score showed a higher correlation with DAS28-CRP than synovial volume, probably because the OMERACT total score includes scores for bone erosion and bone edema as well.

Key words: magnetic resonance imaging, rheumatoid arthritis, outcome measures in rheumatology clinical trials scoring system, direct volume measuring, medical work station

Treatments for rheumatoid arthritis (RA) have changed remarkably since the advent of biologic agents, and the treatment goals have greatly shifted to the achievement of remission and prevention of joint destruction. To evaluate treatment responses, imaging studies are important in addition to clinical evaluations such as the 28-joints disease activity score

(DAS28). Magnetic resonance imaging (MRI) allows the assessment of not only bone erosions but also bone marrow edema and synovitis, which are difficult to detect on plain radiographic images.

The outcome measures in rheumatology clinical trials (OMERACT) RA MRI scoring (RAMRIS) scoring system was devised for use in multi-center studies as a method of MRI assessment of the wrist and meta-

carpophalangeal (MCP) joints [1]. It is utilized in various clinical studies worldwide as a standard assessment method for MRI. It characteristically allows separate scoring of synovitis, bone erosions, and bone marrow edema. However, as a total of 53 sites—7 for synovitis and 23 each for bone erosion and bone marrow edema—are evaluated, its application is time-consuming. In addition, low reproducibility has been recognized as a limitation [2]. Atlases have been published to improve the reproducibility of results obtained with this method, [3, 4]. Nevertheless, even a trained rater needs about 30 min to complete the evaluation, making it difficult to utilize in clinical practice.

Many studies have demonstrated the use of direct measurement of synovial volume and shown its reproducibility. First, a manual outlining technique was developed, but outlining the synovitis manually can take 1–2 h per scan [5, 6]. To reduce analysis times, a semi-automated volume measuring system was developed. Thresholding in combination with rough manual outlining in each plane can substantially reduce analysis times.

These studies have reported good reproducibility, but did not elucidate patients' responses to treatments. In the current study, we developed thresholding in combination with manual outlining in 3D space using a medical workstation, and used it to calculate the synovial volume. To assess the effects of biologic treatments, we evaluated the correlation of the changes of clinical activity score (DAS28-CRP) with the changes of OMERACT scores and synovial volume.

Patients and Methods

Patients and clinical assessments. This research was a retrospective single center study conducted between the dates of January 2008 and December 2013. Inclusion criteria included patients with rheumatoid arthritis, biological therapy, and high-field (1.5-T) MR imaging examinations at baseline and 12 months following the biological therapy. Of the 24 patients undergoing MR imaging before biologic therapy, 16 patients either dropped out of therapy or did not undergo MR imaging at the one-year point. Thus, 8 patients (7 women and 1 man) were included in this study. Clinical assessment was also performed before and 1 year after the initiation

of treatment with biological agents. For clinical assessment, the results of the visual analogue scale (VAS) for general health, counts of swollen and tender joints, and levels of C-reactive protein (CRP) and matrix metalloproteinase 3 (MMP-3) were determined. DAS28-CRP was calculated from the results obtained. The study protocol was approved by the Human Ethics Review Committee of Okayama University Hospital.

MRI examination and its protocol. MRI examinations of the more severely-affected-side wrist, MCP and PIP joints were performed at baseline and at 1 year. MRI examinations were performed on a 1.5-T imaging unit (MAGNETOM Avanto, ©Siemens, Erlangen, Germany), utilizing a small flex coil positioned on the dorsum of the wrist. Patients were examined in the prone position with the arm extended and wrist placed in an 8-channel surface-array-coil. The imaging sequence was selected based on the OMERACT core set recommendation [7]. MR images with and without contrast material were acquired; T1-weighted spin-echo (TR 641 ms, TE 11 ms) images, short-time inversion recovery (STIR; TR 3070 ms, TE 91 ms, T1 160 ms) images and contrast-enhanced (3D gradient recalled echo) images were obtained. A bolus of gadolinium (Gd) contrast agent at 0.1 mmol/kg body weight was intravenously injected and images were obtained within 10 min after injection.

Evaluation of MRI findings. Semiquantitative scoring of synovitis, bone marrow edema, and bone erosion, as visualized by MRI, was performed using the European League Against Rheumatism (EULAR)-OMERACT RAMRIS scoring system [8].

Synovial volumes were measured at the wrist and from the 2nd to 5th MCP joints (a total of 5 sites per patient) on Gd-3D images. The volumes were determined according to the method of Tam *et al.* [9], and the enhancement threshold level was set at +2.5 standard deviations (SDs) of the mean intensity of the thenar muscle on enhanced images (Fig. 1). Based on the threshold level, an enhanced area was automatically extracted and a 3D image was constructed. Next, the vascular area was erased manually from the 3D image to obtain a semi-automatically measured synovial volume with high accuracy. Volume measurements were made using the 3D volumetry function of the AZE Virtual Place (AZE Co., Tokyo, Japan) software application (Fig. 2).

One investigator, blinded to the patients' profiles

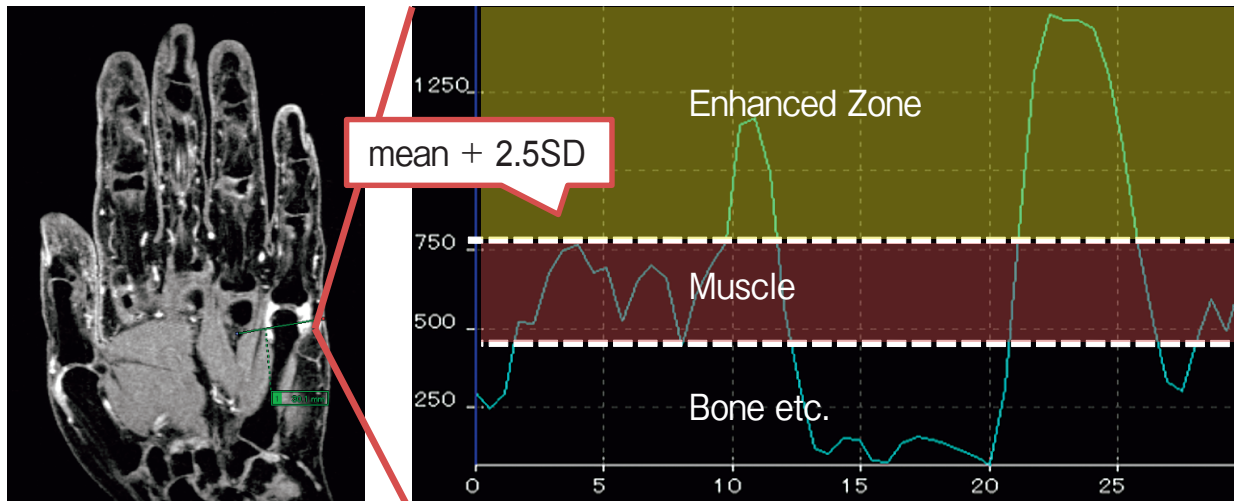


Fig. 1 Enhancement threshold. The enhancement threshold level was set at +2.5 standard deviations (SDs) of the mean intensity of the thenar muscle on enhanced images.

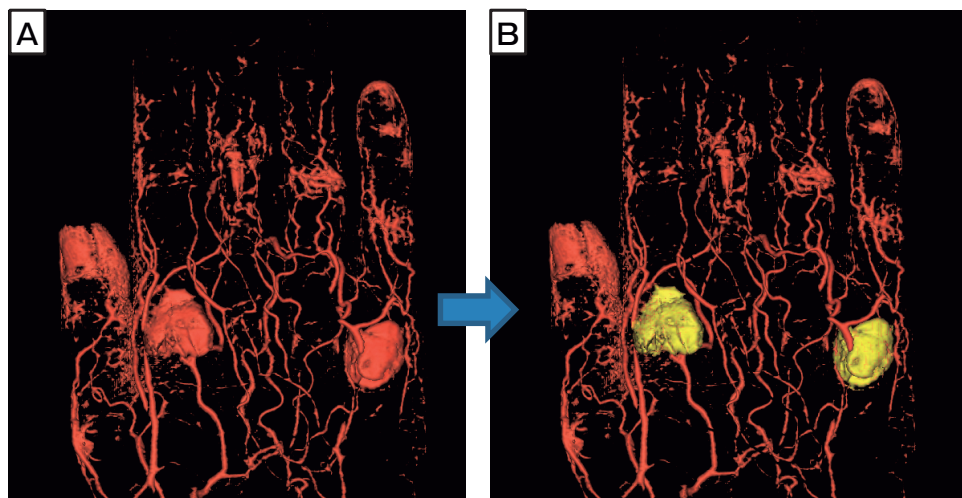


Fig. 2 Semi-automatically measurement on a medical workstation. (A) After thresholding, the synovial area and vascular area were visualized automatically in 3D space. (B) In 3D space, the vascular area was manually erased, and the synovial volume was calculated.

and the chronological order in which the images had been obtained, assessed all images.

To compare the predictability of various MR images for clinical scores, correlations of the DAS28-CRP results with total and synovitis scores of the OMERACT RAMRIS and synovial volumes were evaluated.

The correlation between the synovitis score of the OMERACT RAMRIS and the synovial volume was also analyzed in the wrists and the 2nd to 5th MCP

joints.

Statistical analysis. Variables are presented as means \pm SDs. The Paired *t* test was used to compare results at baseline and 1 year. The Pearson product-moment correlation coefficient was used. *P* values < 0.05 were considered to indicate statistically significant differences.

Results

Patient demographics. The mean age was 58.6 ± 6.4 years and the mean disease duration was 10 ± 8.1 years. The biological agents used were infliximab ($n = 3$), etanercept ($n = 3$), and adalimumab ($n = 2$). The disease modified anti-rheumatic-drugs (DMARDs) used were salazosulfapyridine (SASP; $n = 3$), bucillamine (BUC; $n = 2$), and tacrolimus (TAC; $n = 1$). The mean weekly dose of methotrexate was 6.5mg. The mean weekly dose of prednisolone was 3.1mg (Table 1).

Clinical assessment. Clinical parameters pre- and post-treatment are shown in Table 1. Symptom improvements were seen in all 8 patients. The following reductions in clinical parameters were obtained: the swollen joint count, from 4.75 to 1.75; the tender joint count, from 4.50 to 1.13; the VAS score, from 41.8 to 16.3; the CRP level (mg/l), from 2.51 to 0.22; DAS28-CRP, from 3.75 to 1.92.

MR imaging assessment. The OMERACT RAMRIS synovitis, bone marrow edema, and bone erosion scores changed from 12.1 to 6.6, from 6.8 to 4.4, and from 29.0 to 30.2, respectively. The synovial volume was reduced from 15.4 ± 7.4 ml to 8.8 ± 6.3 ml

Table 1 Patients' background

Characteristics	Baseline
Age (years)	58.6 ± 6.4
Gender	F7, M1
Disease duration (years)	10 ± 8.1
Biologic agents	INF 3, ETN 3, ADA 2
DMARDs	SASP 3, BUC 2, TAC 1
Methotrexate (mg/week)	6.5 ± 2.0
Prednisolone (mg/day)	3.1 ± 1.7

ENT, etanercept; IFX, infliximab; ADA, adalimumab; SASP, sulfasalazine; BUC, bucillamine; TAC, tacrolimus.

Table 2 Changes of clinical parameters

	Baseline	1 year
DAS28-CRP	3.7 ± 0.8	$1.9 \pm 0.5^*$
Synovial volume (ml)	15.4 ± 7.4	$8.8 \pm 6.3^*$
OMERACT RAMRIS	48.0 ± 33.8	$41.3 \pm 36.3^*$
synovitis score	12.1 ± 5.3	$6.6 \pm 5.3^*$
edema score	6.9 ± 6.9	4.4 ± 6.1
erosion score	29.0 ± 27.7	30.3 ± 27.8

DAS, disease activity score; paired *t* test < 0.05.

(Table 2). It took 30 to 40 min per patient to complete scoring by the OMERACT system while approximately 20 min were required to measure the synovial volume.

Correlation. Changes in synovial volume and DAS28-CRP are shown in Fig. 3. Changes in the OMERACT RAMRIS score and DAS28-CRP are shown in Fig. 4. Positive correlations were seen between the DAS28-CRP and the OMERACT synovitis score ($r = 0.67$), OMERACT total score ($r = 0.37$) and synovial volume ($r = 0.66$). The changes in the OMERACT RAMRIS total score ($r = 0.43$), OMERACT RAMRIS synovitis score ($r = 0.27$), and synovial volume ($r = 0.30$) showed positive correla-

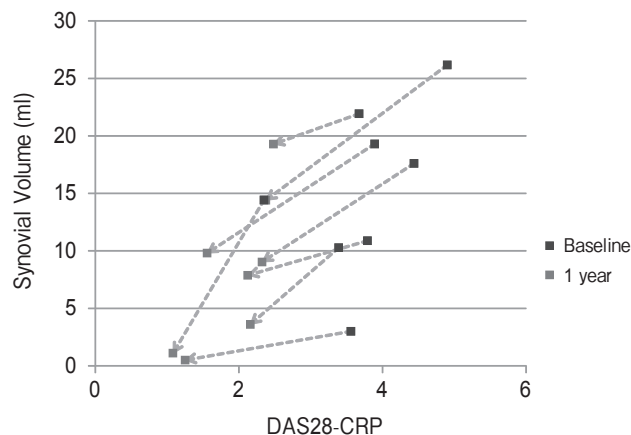


Fig. 3 Changes in volume and DAS28-CRP. Plot of changes in synovial volume and DAS28-CRP.

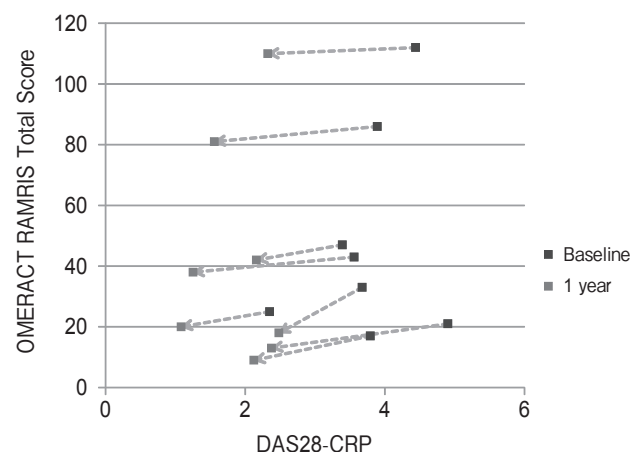


Fig. 4 Changes in OMERACT RAMRIS score and DAS28-CRP. Plot of changes in OMERACT RAMRIS score and DAS28-CRP.

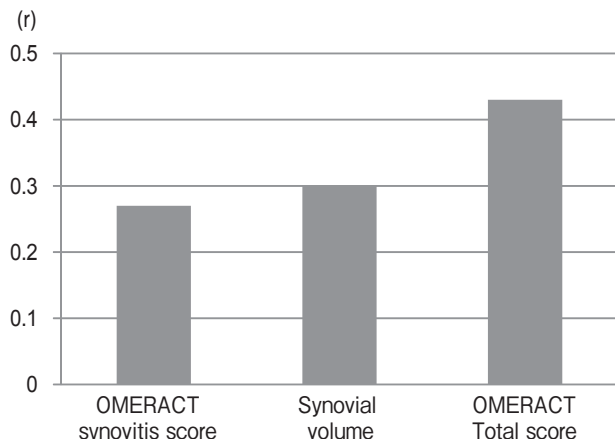


Fig. 5 Correlation with change of DAS28-CRP. The changes in the OMERACT RAMRIS total score ($r = 0.43$), OMERACT RAMRIS synovitis score ($r = 0.27$), and synovial volume ($r = 0.30$) showed positive correlations with DAS28-CRP changes.

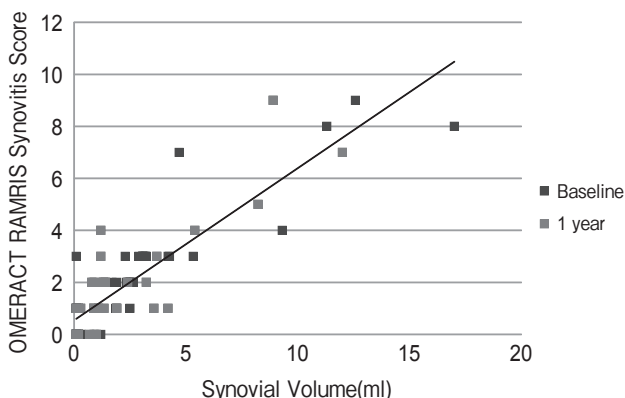


Fig. 6 Volume of each joint and OMERACT RAMRIS synovitis score. The synovial volume of each joint and the OMERACT RAMRIS synovitis score showed a good correlation ($r = 0.88$).

tions with DAS28-CRP changes (Fig. 5).

Correlations between the synovial volume of each joint and the OMERACT RAMRIS synovitis score are presented in Fig. 6. In each joint, synovial volume showed a good correlation ($r = 0.876$) with the OMERACT RAMRIS synovitis score.

Discussion

The OMERACT RAMRIS system has been used in many clinical studies because the results correlate with clinical scores of disease activity such as DAS28 and it is useful for evaluating drug efficacy. Although

the OMERACT RAMRIS total score is usually used, the synovitis score, bone marrow edema score, or bone erosion score alone reportedly correlates with clinical assessment parameters. The synovitis and bone marrow edema score reportedly correlate with the degree of inflammation on scintigraphic images as well as with levels of CRP and the erythrocyte sedimentation rate (ESR) [10]. Several studies have demonstrated that bone erosion, bone marrow edema, or the synovitis score alone predicts the progression of bone erosion [11, 12].

As the OMERACT RAMRIS system has limitations associated with low reproducibility and its time-consuming nature, synovial volumes were measured in the present study to determine whether this method provides better reproducibility as well as reduced reading time. Measurement of synovial volumes has advantages over the RAMRIS score not only in reducing reading time and enhancing reproducibility but also in improving the ability to assess clinical disease activity. Synovial volumes are reportedly useful for evaluating treatment efficacy because they correlate not only with clinical scores [9, 13] but also with changes in clinical scores from pretreatment values [14]. They have also been reported to correlate with histological inflammation [15] and bone erosion progression [16].

Unlike computed tomography (CT) images, MRI is frequently affected by inherent imaging distortions and unevenness. Therefore, manual outlining is regarded as the area selection method yielding the highest reproducibility. However, a higher-field MR scanner has become available and extremity coils have been developed, the resolution has improved and distortion has decreased. In recent years, it has been possible to set an enhancement threshold level in order to extract an enhanced area, thereby allowing differentiation of the synovial area from the vascular area. This semi-automated measurement method has been widely used. Because MRI can be obtained with thin slices, and as many as 90 images are obtained during one 3D imaging session, manual outlining has become time-consuming and cumbersome to perform.

It is challenging to set an enhancement threshold level for extracting an enhanced area. Several studies have proposed determining this threshold relative to muscle tissue [9, 17] or employing dynamic contrast-enhanced intensities [9]. In the present study, dynamic

MRI was not performed in all 8 patients and the threshold level for extracting an enhanced area was set relative to the enhancement of muscle tissue (+2.5 SDs of the mean thenar muscle enhancement). In addition to the intra-articular synovium, an enhanced area contains blood vessels, tenosynovitis, and bone marrow edema, all of which must be erased. This procedure is performed only manually, and is therefore referred to as a semi-automated measurement. Although the blood vessels, edema, and tenosynovitis have thus far been erased manually on a one-by-one basis, at present a medical workstation for 3D analysis of CT images would allow 3D reconstruction of the extracted images and detection of the synovium in the 3D space, resulting in improved accuracy of extraction and a reduction in reading time. With these measures, nearly 15 min were required to measure synovial volumes in each of the patients in this study.

Since distinguishing synovial fluid from synovial tissue is difficult with non-contrast MR imaging, administration of contrast medium is necessary for measurement of synovial volumes. Synovial volumes measured using unenhanced images are reportedly larger than those measured from enhanced images [18]. Thus, administration of contrast material is considered to be useful for accurate volume measurement. The timing of administration of the medium is also important. In one study, MR images of the knee were acquired every 1.75 min after administration of contrast material. After 11 min, the boundary between the synovial tissue and fluid reportedly became obscure [19]. Thus, the present study protocol specified that 3D images were to be taken within 10 min after injection of contrast medium.

Since the OMERACT RAMRIS synovitis score in each joint correlated strongly with synovial volume, measurement of synovial volumes is considered to be useful for clinically assessing the disease state. The change in synovial volume from pretreatment levels correlated with the change in DAS28-CRP, and the correlation coefficient was higher than that of the change in the OMERACT RAMRIS synovitis score but lower than that of the change in the OMERACT RAMRIS total score. Even though we assessed only 8 subjects in this study, the present results might suggest that synovial volume was more useful for the evaluation of treatment response than the OMERACT RAMRIS synovitis score alone; however, it was

inferior to the OMERACT RAMRIS total score, which includes scores for bone erosion and bone marrow edema.

There were several limitations in this study: (i) the sample size was small, which may have limited the statistical power; (ii) all patients had high disease activity at baseline and all patients clinically responded to therapy, so low-disease-activity patients and poor responders to therapy were not evaluated.

In conclusion, measurement of synovial volumes showed higher reproducibility, reduced reading time and a better correlation with DAS28-CRP than the OMERACT RAMRIS synovitis score. However, this method can be said to be less accurate than the OMERACT RAMRIS total score at evaluating clinical disease activity because the correlations with clinical parameters were poorer than those with the OMERACT RAMRIS total score.

References

1. McQueen F, Lassere M, Edmonds J, Conaghan P, Peterfy C, Bird P, O'Connor P, Ejbjerg B, Klarlund M, Stewart N, Emery P, Shnier R, Genant H and Ostergaard M: OMERACT Rheumatoid Arthritis Magnetic Resonance Imaging Studies. Summary of OMERACT 6 MR Imaging Module. *J Rheumatol* (2003) 30: 1387-1392.
2. Conaghan P, Lassere M, Ostergaard M, Peterfy C, McQueen F, O'Connor P, Bird P, Ejbjerg B, Klarlund M, Shnier R, Genant H, Emery P and Edmonds J: OMERACT Rheumatoid Arthritis Magnetic Resonance Imaging Studies. Exercise 4: an international multi-center longitudinal study using the RA-MRI Score. *J Rheumatol* (2003) 30: 1376-1379.
3. Conaghan P, Bird P, Ejbjerg B, O'Connor P, Peterfy C, McQueen F, Lassere M, Emery P, Shnier R, Edmonds J and Ostergaard M: The EULAR-OMERACT rheumatoid arthritis MRI reference image atlas: the metacarpophalangeal joints. *Ann Rheum Dis* (2005) 64 Suppl 1: i11-21.
4. Ejbjerg B, McQueen F, Lassere M, Haavardsholm E, Conaghan P, O'Connor P, Bird P, Peterfy C, Edmonds J, Szkudlarek M, Genant H, Emery P and Ostergaard M: The EULAR-OMERACT rheumatoid arthritis MRI reference image atlas: the wrist joint. *Ann Rheum Dis* (2005) 64 Suppl 1: i23-47.
5. Savnik A, Bliddal H, Nyengaard JR and Thomsen HS: MRI of the arthritic finger joints: synovial membrane volume determination, a manual vs a stereologic method. *Eur Radiol* (2002) 12: 94-98.
6. Ostergaard M: Different approaches to synovial membrane volume determination by magnetic resonance imaging: manual versus automated segmentation. *Br J Rheumatol* (1997) 36: 1166-1177.
7. Ostergaard M, Peterfy C, Conaghan P, McQueen F, Bird P, Ejbjerg B, Shnier R, O'Connor P, Klarlund M, Emery P, Genant H, Lassere M and Edmonds J: OMERACT Rheumatoid Arthritis Magnetic Resonance Imaging Studies. Core set of MRI acquisitions, joint pathology definitions, and the OMERACT RA-MRI scoring system. *J Rheumatol* (2003) 30: 1385-1386.

8. Lassere M, McQueen F, Ostergaard M, Conaghan P, Shnier R, Peterfy C, Klarlund M, Bird P, O'Connor P, Stewart N, Emery P, Genant H and Edmonds J: OMERACT Rheumatoid Arthritis Magnetic Resonance Imaging Studies. Exercise 3: an international multicenter reliability study using the RA-MRI Score. *J Rheumatol* (2003) 30: 1366–1375.
9. Tam LS, Griffith JF, Yu AB, Li TK and Li EK: Rapid improvement in rheumatoid arthritis patients on combination of methotrexate and infliximab: clinical and magnetic resonance imaging evaluation. *Clin Rheumatol* (2007) 26: 941–946.
10. Palosaari K, Vuotila J, Takalo R, Jartti A, Niemela R, Haapea M, Soini I, Tervonen O and Hakala M: Contrast-enhanced dynamic and static MRI correlates with quantitative ⁹⁹Tcm-labelled nanocolloid scintigraphy. Study of early rheumatoid arthritis patients. *Rheumatology (Oxford)* (2004) 43: 1364–1373.
11. Palosaari K, Vuotila J, Takalo R, Jartti A, Niemela RK, Karjalainen A, Haapea M, Soini I, Tervonen O and Hakala M: Bone oedema predicts erosive progression on wrist MRI in early RA—a 2-yr observational MRI and NC scintigraphy study. *Rheumatology (Oxford)* (2006) 45: 1542–1548.
12. Ostergaard M, Duer A, Nielsen H, Johansen JS, Narvestad E, Ejbjerg BJ, Baslund B, Moller JM, Thomsen HS and Petersen J: Magnetic resonance imaging for accelerated assessment of drug effect and prediction of subsequent radiographic progression in rheumatoid arthritis: a study of patients receiving combined anakinra and methotrexate treatment. *Ann Rheum Dis* (2005) 64: 1503–1506.
13. Palmer WE, Rosenthal DI, Schoenberg OI, Fischman AJ, Simon LS, Rubin RH and Polisson RP: Quantification of inflammation in the wrist with gadolinium-enhanced MR imaging and PET with 2-[F-18]-fluoro-2-deoxy-D-glucose. *Radiology* (1995) 196: 647–655.
14. Argyropoulou MI, Glatzouni A, Voulgari PV, Xydis VG, Nikas SN, Efremidis SC and Drosos AA: Magnetic resonance imaging quantification of hand synovitis in patients with rheumatoid arthritis treated with infliximab. *Joint Bone Spine* (2005) 72: 557–561.
15. Ostergaard M, Stoltenberg M, Lovgreen-Nielsen P, Volck B, Jensen CH and Lorenzen I: Magnetic resonance imaging-determined synovial membrane and joint effusion volumes in rheumatoid arthritis and osteoarthritis: comparison with the macroscopic and microscopic appearance of the synovium. *Arthritis Rheum* (1997) 40: 1856–1867.
16. Savnik A, Malmskov H, Thomsen HS, Graff LB, Nielsen H, Danneskiold-Samsøe B, Boesen J and Bliddal H: MRI of the wrist and finger joints in inflammatory joint diseases at 1-year interval: MRI features to predict bone erosions. *Eur Radiol* (2002) 12: 1203–1210.
17. Lee SH, Suh JS, Kim HS, Lee JD, Song J and Lee SK: MR evaluation of radiation synovectomy of the knee by means of intra-articular injection of holmium-166-chitosan complex in patients with rheumatoid arthritis: results at 4-month follow-up. *Korean J Radiol* (2003) 4: 170–178.
18. Savnik A, Malmskov H, Thomsen HS, Bretlau T, Graff LB, Nielsen H, Danneskiold-Samsøe B, Boesen J and Bliddal H: MRI of the arthritic small joints: comparison of extremity MRI (0.2T) vs high-field MRI (1.5T). *Eur Radiol* (2001) 11: 1030–1038.
19. Ostergaard M and Klarlund M: Importance of timing of post-contrast MRI in rheumatoid arthritis: what happens during the first 60 minutes after IV gadolinium-DTPA? *Ann Rheum Dis* (2001) 60: 1050–1054.