

Acta Med. Okayama, 2014
Vol. 68, No. 4, pp. 201-206

Copyright©2014 by Okayama University Medical School.

Acta Medica
Okayama

<http://escholarship.lib.okayama-u.ac.jp/amo/>

Original Article

Two-Directional Arthrographic Assessment for Treating Bilateral Development Dislocation of the Hips in Children after Walking Age

Hirosuke Endo^{a*}, Hirofumi Akazawa^b, Shigeru Mitani^c, Yoshiki Okada^d,
Kentaro Yamane^d, and Toshifumi Ozaki^d

^aDepartment of Medical Materials for Musculoskeletal Reconstruction, Okayama University Graduate School of Medicine, Dentistry and Pharmaceutical Sciences, and ^dDepartment of Orthopaedic Surgery, Okayama University Hospital, Okayama 700-8558, Japan, ^bDepartment of Orthopaedic Surgery, Asahigawaryoikuen, Okayama 703-8555, Japan, and ^cDepartment of Orthopaedic Surgery, Kawasaki Medical School, Kurashiki, Okayama 701-0192, Japan

We reviewed the treatment outcome in 14 hips of 7 patients who were diagnosed as having bilateral developmental dislocation of the hip (DDH) after walking age and could be followed up until they were at least 14 years of age. Based on the results of two-directional arthrography of the hip, closed reduction was performed in 2 hips, and open reduction was performed without osteotomy in 12 hips. The final radiographic evaluations were made according to the Kalamchi and MacEwen classification and Severin classification. The mean age at the initial visit was 1 year and 9 months (range, 1 year and 5 months to 3 years). The outcome was satisfactory for one hip in Group I and 2 hips in Group II according to the Kalamchi and MacEwen classification, and in 83% of the Severin Class I and II hips. Arthrography was useful for identifying asymmetry, demonstrating the usefulness of a treatment strategy based on arthrography of the hip.

Key words: developmental dislocation of the hip, bilateral case, arthrogram, open reduction, after walking age

The prevalence of bilateral developmental dislocation of the hip (DDH) is low. Since there are fewer bilateral differences in the physical findings of bilateral DDH (such as lower limb length and limitation of abduction in flexion), the diagnosis of bilateral DDH tends to be delayed compared to that of unilateral DDH. As a result, conservative treatment is not applicable and surgical treatment is required after a delayed diagnosis. Of 895 DDH patients treated in our hospital from 1975 to 2012, 117 patients (13%) had bilateral disease. Of the 60 patients diagnosed as

having DDH after walking age, 10 patients had bilateral DDH, accounting for approx 1%. The present study was conducted to investigate bilateral DDH diagnosed after walking age. The decision to perform a closed reduction or open reduction was based on a 2 directional arthrogram before the operation. The results of our strategy based on the arthrogram were satisfactory at the patient's mature ages.

Patients and Methods

Of the 20 hips of the 10 patients with bilateral DDH diagnosed after walking age and treated in our hospital after 1974, a total of 14 hips of 7 patients (6 girls, 1 boy; mean age at the initial visit, 1 year and

Received October 22, 2013; accepted February 14, 2014.

*Corresponding author. Phone: +81-86-235-7273; Fax: +81-86-223-9727
E-mail: hirosuke@md.okayama-u.ac.jp (H. Endo)

7 months [range 1 year and 5 months to 2 years]) could be followed up until the patients were at least 14 years old (mean age at the final examination, 18 years [range 14–26 years]). These 20 hips were examined in the present study. Cases of teratologic dislocation and paralytic dislocation were excluded. Bilateral open reduction (hereinafter abbreviated as OR) was performed in 5 patients (10 hips), and unilateral OR and unilateral closed reduction (here in after abbreviated as CR) were performed in 2 patients (4 hips) (Table 1).

We assessed the plain radiographs obtained at the patient's initial visits and their preoperative arthrographic findings. The radiographs at the initial visit were used to measure the α -angle and Yamamuro's distance a and b [6]. In the arthrographic evaluation, we assessed the frontal view with the patient in the frog position and the lateral view, and classified the reduction type according to the Miyake classification [1] and Mitani classification [2], respectively. We also investigated the relation between the radiographic measurements and arthrographic findings.

We used the bilateral frontal radiograph at the final examination to measure the center-edge (CE) angle and the Sharp angle for evaluation according to the Severin classification [3]. We also determined the presence or absence of femur head necrosis according

to the Kalamchi and MacEwen classification [4] (hereinafter abbreviated as the K & M classification). The range of motion of the hip joint, leg length discrepancy, and the Japanese Orthopedic Association (JOA) score were assessed as clinical outcome parameters.

In our hospital, treatment of bilateral DDH after walking age generally starts with preoperative two-directional arthrography of the hip. CR is performed for Type A with no involvement of the anterior or posterior acetabular labrum, and OR is performed for Types B and C with inverted limbus. If a bilateral OR is indicated, a unilateral OR is followed by a contralateral OR several months later. If a unilateral CR is indicated, a contralateral OR is performed in parallel with the CR. In our hospital, OR, which is soft tissue surgery, has been performed according to Tanabe's method [5] since 1974.

Results

Radiography at the initial visit revealed a mean α -angle of 38° (range 29° – 45°), mean Yamamuro's distance a ([6]) of -4 mm (range -15 mm to 2 mm), and mean Yamamuro's distance b of 21 mm (range 18 – 23 mm). Few bilateral differences were observed in Yamamuro's distance A and B in any patient (Fig. 1).

Preoperative arthrography revealed symmetry in 4 patients in the frontal and lateral views, and two-directional symmetry in 3 patients (Table 2). In 2 hips

Table 1 Distribution of patients according to sex, age at operation, and age at the final follow-up

Patient no./gender	Age(months) at op		Final follow-up (years)
	Rt	Lt	Age
1/F	24	30	26
2/F	19 (CR)	19	20
3/F	25	19	20
4/F	30	24	18
5/F	23	30	14
6/M	19 (CR)	19	14
7/F	17	24	18

The square of dotted line indicate that one hip was treated by operation, and the other side was treated closed reduction spontaneously.

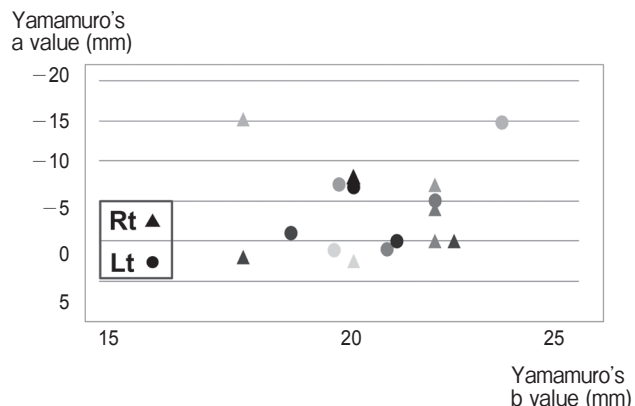


Fig. 1 Pre-operative radiographic findings. Vertical line shows Yamamuro's a value, and horizontal line shows b value. Plot point means the a and b values in each hip. The triangle plot shows right hip, the circle plot shows left hip, the plots of same coloration means same case.

Table 2 Pre-operation arthrogram findings

Patient no.	Rt		Lt	
	A-p	Lateral	A-p	Lateral
1	intermediate	Type B	impossible	Type C
2	evert	Type C	evert	Type A
3	impossible	Type C	impossible	Type C
4	impossible	Type C	blockaded	Type C
5	blockaded	Type C	blockaded	Type C
6	evert	Type A	evert	Type B
7	blockaded	Type C	blockaded	Type C

The square of dotted line indicate that the hip was treated by closed reduction. The circle of solid line indicate that completely irreducible hip under general anesthesia.

classified as Type A, a CR using Lorenz casting was performed in parallel with a contralateral OR. No relation was observed between the radiographic measurements (Yamamuro's distance a and b) and arthrographic findings (Type A treated with reposition, reducible Type B, and irreducible Type C) at the initial visit (Fig. 2).

The mean age at the initial surgery was 1 year and 9 months (range, 1 year and 7 months to 2 years and 1 month). As for additional surgery, femoral varus derotational osteotomy was performed in 1 of the 14 hips (7%) at 8 years after the initial surgery. No recurrence of dislocation or complication such as infection was reported in any patient.

As for radiographic measurements at the final examination, the mean CE angle was 27° (range, 13°–40°) and the mean Sharp angle was 47° (range, 37°–59°). Based on the radiographic evaluation at the final examination, a total of 2 hips (14.3%) were classified into Group I (one hip) or II (one hip) according to the K & M classification, and 10 (71.4%), 2 (14.3%), and 2 (14.3%) hips were classified into Classes I, II, and III, respectively, according to the Severin classification.

With regard to the range of motion at the final examination, the hip with CR using a cast had a better flexion angle than the opposite hip with OR, but no bilateral differences were observed in the range of flexion in any patient with bilateral OR (Fig. 3). At

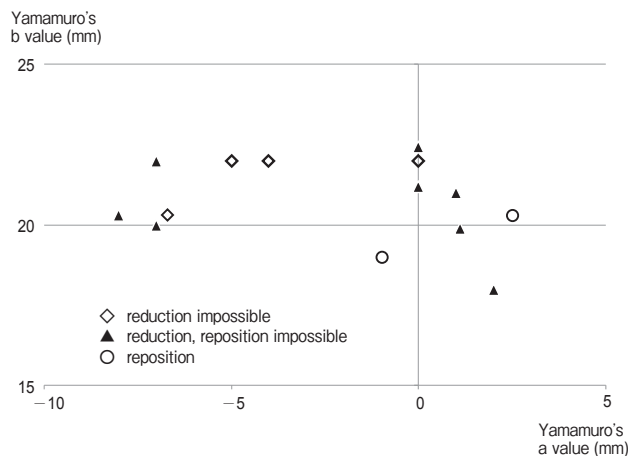


Fig. 2 Relation of X-ray and arthrogram. Vertical line shows Yamamuro's b value, and horizontal line shows a value. Plot point means the a and b values in each hip. The rhombus plot shows the hip reduction was unable, triangle plot shows the hip reduced but reposition was unable, the circle plot shows the hip reposition was gained in lateral view of arthrogram.

the final examination, the leg length discrepancy was not greater than 1 cm in any patient. The mean JOA score was 94 points (87–100 points) (Fig. 4).

Case. This girl was brought to our hospital because of abnormal gait at 1 year and 5 months of age. At the initial visit, no bilateral differences were observed in radiographic measurements, with α -angle of 40° and 38°, Yamamuro's distance a of 1 mm, and Yamamuro's distance b of 19 mm (Fig. 5A). At arthrography, the frontal view showed bilateral coxa valga (Fig. 5B). The lateral view showed that the right hip was Type A with no involvement of the acetabular labrum, and the left hip was irreducible Type C (Fig. 5C, D). After a right CR was performed in parallel with a left OR at 1 year and 7 months of age, she was followed up without additional surgery (Fig. 6A–C). At the final examination at 20 years of age, the right hip was Severin I, and the left hip was Severin II. The left hip was K & A Group II with mild coxa magna (Fig. 7). The JOA scores of the right and left hips were 86 and 87 points, respectively, with a complaint of mild bilateral hip pain.

Discussion

The prevalence of bilateral DDH was reported to be from 12% to 29% in several European and Asian

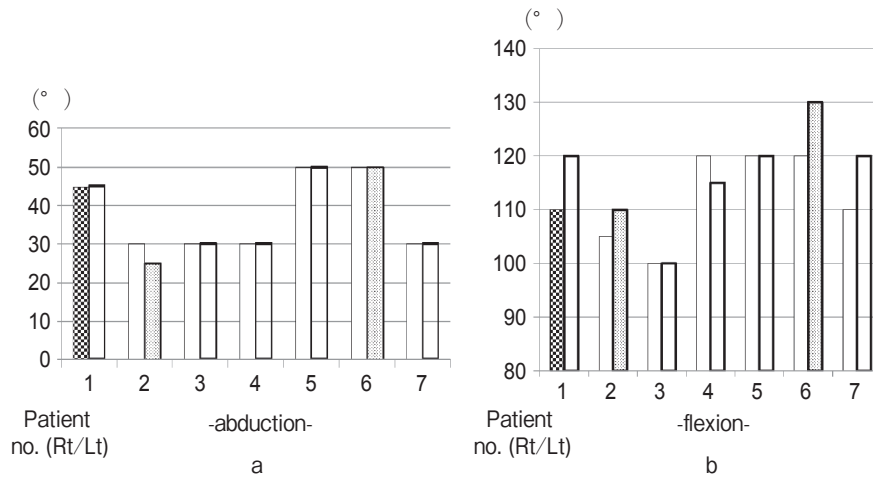


Fig. 3 Range of motion at final examination. Check bar means the hip additional operation was performed. Spot bar means the hip closed reduction was performed.

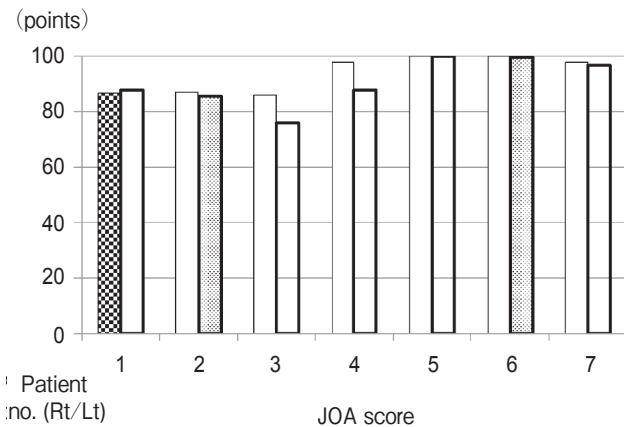


Fig. 4 Final examination of JOA score.

country [7-11]. In Japan, the reported prevalence from 2.9% to 13% [12-14], and fewer cases of bilateral DDH were detected after walking age compared to the unilateral cases. In our hospital, bilateral DDH has accounted for 13% of complete dislocations, and delayed diagnoses of bilateral DDH after walking age have accounted for 1%. Due to the symmetry of physical findings, bilateral DDH is more difficult to diagnose than unilateral DDH and sometimes remains unnoticed even after walking age.

Greene and Drennan reported a tendency for bilateral DDH diagnoses to be delayed compared with unilateral DDH diagnoses, as shown by their finding that 20% of the bilateral DDH cases were detected

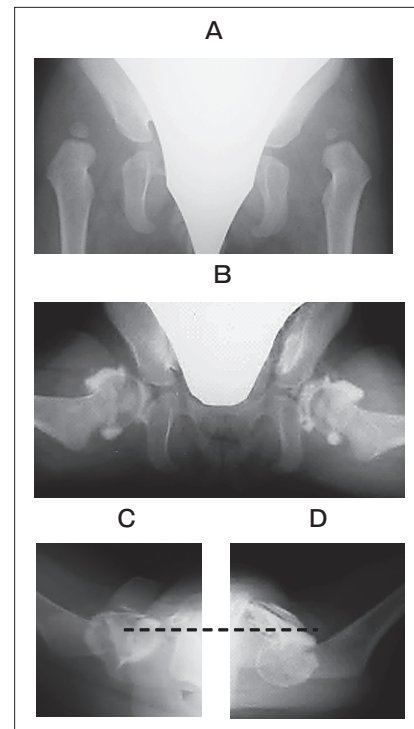


Fig. 5 Frontal view of the right and left hip joints at the initial visit of a 1 year and 5 months girl with severe bilateral complete dislocation of the hip. (A) Arthrogram of the hip in the frog position. The limbus of both hips showed everted type according to the Miyake classification. (B) Arthrogram of the hip in lateral view. According to the Mitani classification, the right hip was Type A with no involvement of the acetabulum between femoral head, and the left hip was irreducible Type C (C).

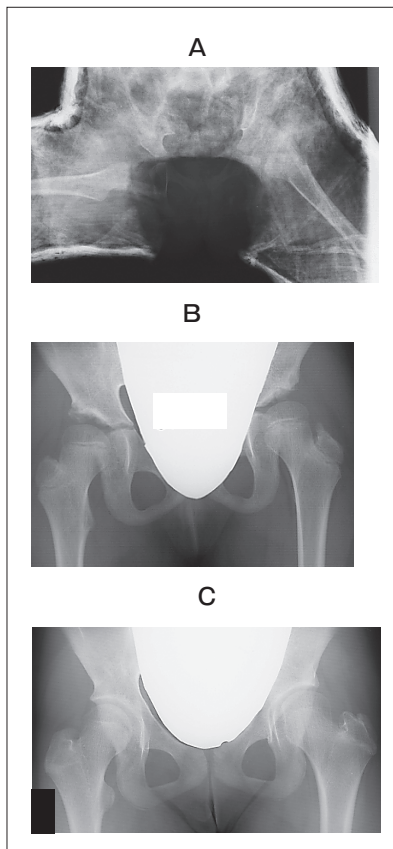


Fig. 6 Surgery was performed at 1 year and 7 months right closed reduction in parallel with left open reduction. AP view of hip joints with casting. (A) AP view of hip joints at 7 years of age. (B) AP view of hip joints at 14 years of age (C).

after walking age (between 12 and 18 months of age) [15]. Those authors also mentioned that the necessity for treatment differs between right and left hips in bilateral DDH despite their symmetric appearance [15]. In the present study as well, no marked bilateral differences were observed in preoperative radiographic measurements, but arthrography under anesthesia showed that the severity was not symmetric in one-half of the patients.

Unlike plain radiography, arthrography can detect asymmetry in bilateral DDH and can even identify hip joints suitable for conservative treatment with no involvement of the acetabular labrum during reduction. As a result, the range of motion and clinical outcome were good in the conservatively treated hip joints in the present study.

However, conservative treatment has limitations

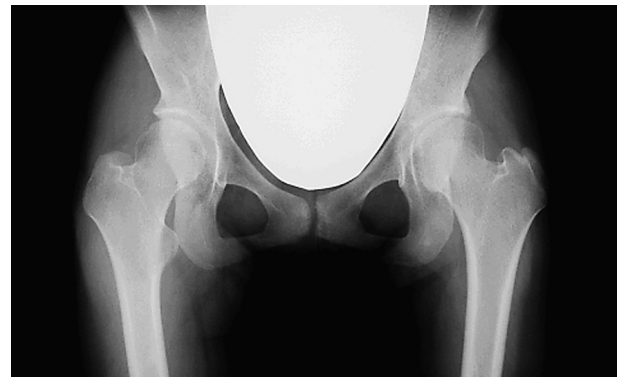

Fig. 7 AP view of hip joints at the final follow-up at 20 years of age.

for DDH after walking age [16–18]. Wilkinson and Carter reported that CR was unsuccessful in 48 of 84 hips of 42 patients with bilateral DDH [7]. In a review of bilateral DDH in 16 patients (32 hips) who were followed up until they were at least 9 years of age, Nakatoh reported that the outcomes of conservative treatment or Colonna arthroplasty were not consistent, and that the outcomes of bilateral open reduction according to Tanabe's method were better in 11 hips of 6 patients [19]. One-stage open reduction performed simultaneously with femoral shortening osteotomy with or without acetabuloplasty has been reported as a surgical treatment of bilateral DDH after walking age [10, 20, 21]. Moussa and Al-Othman reported the outcome of surgery combined with osteotomy in 30 hips of 15 patients given a diagnosis of bilateral DDH at 2 years of age or older (2–8 years) [20]. With a mean follow-up duration of 3 years and 2 months, the final Severin class was I in 10 hips, II in 16 hips, III in 1 hip, IV in 2 hips, and V in 1 hip. In a review of the outcome of 11 patients (22 hips) given a diagnosis of bilateral DDH at 3 years of age or older (3–9.5 years) and who underwent a one-stage operation in the acetabular roof and femur together, Subasi *et al.* reported observing femur head necrosis in 12 hips, and poorer final clinical outcomes in patients diagnosed at 5 years of age or older compared to those diagnosed before 5 years of age [10].

In the present study of patients who were followed up until they were at least 14 years of age, the outcome of bilateral DDH treatment was good, with femur head necrosis in 2 hips (14.3%) and Severin Classes I, II, and III in 10 (71.4%), 2 (14.3%),

and 2 (14.3%) hips, respectively. Open reduction according to Tanabe's method [5], which we use, is designed to achieve the optimal joint position by removing all intra- and extracapsular factors that make dislocation irreducible. The good outcome in the present study may be partly explained by the fact that all patients were treated bilaterally before 3 years of age. If treated after that age, the outcome may have been poorer as previously reported. Gholve *et al.* reported the outcome in 49 hips of 42 DDH patients who were followed up for at least 5 years (mean: 9.7 years) after treatment at a mean age of 2 years and 7 months (OR alone in 12 hips; acetabular osteotomy in 15 hips; femoral osteotomy in 4 hips, and femoral and acetabular osteotomy in 18 hips) [21]. Additional surgery was required by 24 patients after a mean duration of 3 years, and OR alone often resulted in the second of a two-stage operation. It was indicated that acetabular remodeling may be maintained for only up to 4 years after reduction. In patients under 3 years of age, in contrast, conservative treatment or OR alone without osteotomy, which is selected based on the results of two-directional arthrography, may have a good outcome. In the future, it may be helpful to study the one-stage operation although it is associated with problems such as blood loss and a long surgery duration.

References

- Miyake Y: Evaluation of arthrogram of congenital dislocation of the hip especially for the strangulation of ligamentum transversum acetabuli. *Cent Jpn J Orthop Traumat* (1967) 10: 467-483 (in Japanese).
- Mitani S, Nakatsuka Y, Akazawa H, Aoki K and Inoue H: Treatment of developmental dislocation of the hip in children after walking age. Indications from two-directional arthrography. *J Bone Joint Surg Br* (1997) 79: 710-718.
- Severin E: Contribution to knowledge of congenital dislocation of the hip: late results of closed reduction and arthrographic studies of recent cases. *Acta Chir Scand* (1941) 84: 1-142.
- Kalamchi A and MacEwen GD: Avascular necrosis following treatment of congenital dislocation of the hip. *J Bone Joint Surg Am* (1980) 62: 876-888.
- Akazawa H, Tanabe G and Miyake Y: A new open reduction treatment for congenital hip dislocation: long-term follow-up of the extensive anterolateral approach. *Acta Med Okayama* (1990) 44: 223-231.
- Yamamoto T and Chene SH: A radiological study on the development of the hip joint in normal infants. *J Jpn Orthop Assoc* (1975) 49: 421-439.
- Wilkinson J and Carter C: Congenital dislocation of the hip: The results of conservative treatment. *J Bone Joint Surg Br* (1960) 42: 669-688.
- Blockley NJ: Derotation osteotomy in the management of congenital dislocation of the hip. *J Bone Joint Surg Br* (1984) 66: 485-490.
- Guille JT, Pizzutillo PD and MacEwen GD: Development dysplasia of the hip from birth to six months. *J Am Acad Orthop Surg* (2000) 8: 232-242.
- Subasi M, Arslan H, Cebesoy O, Buyukbecici O and Kapukaya A: Outcome in unilateral or bilateral DDH treated with one-stage combined procedure. *Clin Orthop Relat Res* (2008) 466: 830-836.
- El-Sayed MM: Single-stage open reduction, Salter innominate osteotomy, and proximal femoral osteotomy for the management of developmental dysplasia of the hip in children between the ages of 2 and 4 years. *J Pediatr Orthop B* (2009) 18: 188-196.
- Yamada N, Maeda S, Fujii G, Kita A, Funayama K and Kokubun S: Closed reduction of developmental dislocation of the hip by prolonged traction. *J Bone Joint Surg Br* (2003) 85: 1173-1177.
- Satsuma S, Kobayashi D, Hamamura K: Developmental dysplasia of the hip in Kobe Children's Hospital: Survey results. *J Jpn Ped Orthop Assoc* (2008) 17: 298-302 (in Japanese).
- Kataoka H, Futami T, Ohta E, Tomoda Y, Ogi Y: Developmental dysplasia of the hip: Annual incidence in Shiga Prefecture. *J Jpn Ped Orthop Assoc* (2008) 17: 303-306 (in Japanese).
- Greene WB, Drennan JC: A comparative study of bilateral versus unilateral congenital dislocation of the hip. *Clin Orthop Relat Res* (1982) 162: 78-86.
- Mardam-Bey G and MacEwen D: Congenital hip dislocation after walking age. *J Pediatr Orthop* (1982) 2: 478-486.
- Huang SC and Wang JH: A comparative study of nonoperative versus operative treatment of developmental dysplasia of the hip in patients of walking age. *J Pediatr Orthop* (1997) 17: 181-188.
- Aiga A, Kadota H, Kikuchi T, Inoue H, Mitani S and Asami K: Treatment for developmental dislocation in the Hip by closed reduction in walking age. *J Jpn Ped Orthop Assoc* (2005) 14: 17-21 (in Japanese).
- Nakatoh S: Treatment of congenital dislocation of the hip: Follow-up study of cases of bilateral dislocation of the hip. *Nihon Seikeigeka Gakkai Zasshi* (1987) 61: 129-142 (in Japanese).
- Moussa M and Al-Othman A: Bilateral developmental dysplasia of the hip: asymmetric outcome in the older child. *Clin Orthop Relat Res* (2001) 392: 358-365.
- Gholve PA, Flynn JM, Garner MR, Millis MB and Kim YJ: Predictors for secondary procedures in walking DDH. *J Pediatr Orthop* (2012) 32: 282-289.