

Utah State University

DigitalCommons@USU

---

All Graduate Theses and Dissertations

Graduate Studies

---

5-2014

## Antiviral Activity of Favipiravir (T-705) Against Lethal Rift Valley Fever Virus Infection in Hamsters

Dionna Scharton  
*Utah State University*

Follow this and additional works at: <https://digitalcommons.usu.edu/etd>



Part of the [Veterinary Medicine Commons](#)

---

### Recommended Citation

Scharton, Dionna, "Antiviral Activity of Favipiravir (T-705) Against Lethal Rift Valley Fever Virus Infection in Hamsters" (2014). *All Graduate Theses and Dissertations*. 2323.

<https://digitalcommons.usu.edu/etd/2323>

This Thesis is brought to you for free and open access by the Graduate Studies at DigitalCommons@USU. It has been accepted for inclusion in All Graduate Theses and Dissertations by an authorized administrator of DigitalCommons@USU. For more information, please contact [digitalcommons@usu.edu](mailto:digitalcommons@usu.edu).



ANTIVIRAL ACTIVITY OF FAVIPIRAVIR (T-705) AGAINST LETHAL RIFT VALLEY FEVER VIRUS

INFECTION IN HAMSTERS

by

Dionna Scharton

A thesis submitted in partial fulfillment  
of the requirements for the degree

of

MASTER OF SCIENCE

in

Animal, Dairy, and Veterinary Science  
(Animal Health and Disease)

Approved:

---

Brian B. Gowen  
Major Professor

---

Justin G. Julander  
Committee Member

---

Kerry A. Rood  
Committee Member

---

Dirk K. Vanderwall  
Interim Department Head

---

Mark R. McLellan  
Vice President for Research and  
Dean of the School of Graduate Studies

UTAH STATE UNIVERSITY  
Logan, Utah

2014

Copyright © Dionna Scharton 2014  
All Rights Reserved

## ABSTRACT

Antiviral Activity of Favipiravir (T-705) Against Lethal Rift Valley Fever Virus Infection in  
Hamsters

by

Dionna Scharton, Master of Science

Utah State University, 2014

Major Professor: Brian B. Gowen  
Department: Animal, Dairy and Veterinary Science

Rift Valley Fever is a zoonotic, arthropod-borne disease that adversely affects ungulates and people. The etiologic agent, Rift Valley fever virus (RVFV; *Bunyaviridae*, *Phlebovirus*), is primarily transmitted through mosquito bites, yet can be transmitted by exposure to infectious aerosols. Presently, there are no licensed vaccines or therapeutics to prevent or treat severe RVFV infection in humans. We have previously reported on the activity of favipiravir (T-705) against the MP-12 vaccine strain of RVFV and other bunyaviruses in cell culture. Additionally, efficacy has been documented in mouse and hamster models of infection with the related Punta Toro virus. Here, we characterize a hamster RVFV challenge model and use it to evaluate the activity of favipiravir against the highly pathogenic ZH501 strain of the virus. Subcutaneous RVFV challenge resulted in substantial serum and tissue viral loads and caused severe disease and mortality within 2-3 days after infection. Oral favipiravir (200 mg/kg/day) prevented mortality in 60% or greater in hamsters challenged with RVFV when administered within 6 h post-exposure and reduced RVFV titers in serum and tissues relative to the time of treatment initiation. In contrast, although ribavirin (75 mg/kg/day) was effective at protecting animals

from the peracute RVFV disease, most ultimately succumbed from a delayed-onset neurologic disease associated with high RVFV burden in the brain observed in moribund animals. When combined, T-705 and ribavirin treatment started 24 h post-infection significantly improved survival outcome and reduced serum and tissue virus titers compared to monotherapy. Our findings demonstrate significant post-RVFV exposure efficacy with favipiravir against both peracute disease and delayed-onset neuroinvasion, and suggest added benefit when combined with ribavirin.

(74 pages)

## PUBLIC ABSTRACT

## Efficacy of Favipiravir (T-705) Against Lethal Rift Valley Fever Virus Infection in Hamsters

Dionna Scharton

Rift Valley fever (RVF) is a severe disease affecting both humans and a number of agriculturally important livestock species. The causative agent, RVF virus (RVFV), is primarily transmitted through mosquito bites, with transmission also occurring by exposure to infectious aerosols and direct contact with infected body fluids such as blood. Presently, there are no licensed vaccines or medicines to prevent or treat severe RVFV infection in humans. Favipiravir (T-705) is a novel compound licensed for the treatment of influenza in Japan and presently in Phase III clinical trials in the US, which has demonstrated favorable activity against an attenuated strain of RVFV, as well as other related viruses in cell culture. Additionally, it has also demonstrated favorable activity in mouse and hamster models based on infection with the closely related, less biohazardous Punta Toro virus. Although mouse models have been used extensively in RVFV research and are fairly well characterized, details regarding RVFV infection in hamsters are lacking. The present studies were aimed at characterizing RVFV infection in hamsters to gain a better understanding of the disease model compared to human disease, and employing the hamster infection model to evaluate T-705 as a promising broadly active antiviral with potential for off-label use to treat severe RVF disease. Herein, we describe the natural history of disease in hamsters challenged with low infectious doses of RVFV and demonstrate the efficacy of T-705 in preventing mortality and reducing viral loads in infected hamsters. Our results support the future use of the RVFV hamster infection model for early stage antiviral drug and vaccine development studies, as well as further development of T-705 using more advanced nonhuman primate models of disease.

DEDICATION

This is for my family, especially Erin.

## ACKNOWLEDGMENTS

I wish to thank the Institute for Antiviral Research (IAR) and the National Institute for Health for the support and funding of this project. I am grateful to my graduate committee, Drs. Justin Julander and Kerry Rood, for the continual support they afforded to me over the course of my education. I am particularly grateful to the technicians and staff of the IAR Select Agent Laboratory and the USU Veterinary Diagnostic Laboratory, for their tireless efforts under extreme conditions as well as their patience with processing the numerous samples involved. I would like to personally thank Dr. Arnaud Van Wetter for his advice, time and efforts towards providing histologic analysis of a considerable amount of tissues. I am especially thankful to Dr. Venkatraman Siddharthan and Ivy Binks for technical advice and training in IHC procedures, Jonna Westover for her patience, ceaseless editing, continual advisement and encouragement, and Luci Wandersee for her assistance throughout various laboratory projects and life in general. Special thanks to Dr. Yousuke Furuta from the Toyama Chemical Co. for generously providing the favipiravir compound. Finally, I wish to express my sincere gratitude to Dr. Brian B. Gowen, whose constant guidance, encouragement and occasional swift-kick enabled me to complete this project in a “timely” fashion.

Dionna Scharton



## CONTENTS

	Page
ABSTRACT.....	iii
PUBLIC ABSTRACT .....	v
ACKNOWLEDGMENTS.....	vii
LIST OF TABLES.....	ix
LIST OF FIGURES.....	x
CHAPTER	
1. INTRODUCTION - LITERATURE REVIEW .....	1
Introduction .....	1
Molecular Biology of RVFV.....	1
RVFV Transmission.....	3
RVFV's Increasing Geographic Distribution .....	3
Clinical Pathology of RVF .....	4
RVFV Infection Animal Models .....	5
Vaccine and Therapeutic Development.....	8
Bioterrorism .....	10
2. MODEL DEVELOPMENT .....	12
Introduction .....	12
Materials and Methods.....	14
Results.....	17
Discussion .....	23
3. FAVIPRAVIR (T-705) EVALUATION STUDIES.....	31
Introduction .....	31
Materials and Methods.....	32
Results.....	36
Discussion .....	49
4. CONCLUSIONS AND FUTURE DIRECTIONS .....	54
REFERENCES.....	57

## LIST OF TABLES

Table	Page
1. Comparison of RVFV animal models to the Syrian hamster model.....	26
2. Post-exposure T-705 plus ribavirin combination treatment regimens.....	47

## LIST OF FIGURES

Figure	Page
1. RVFV challenge of golden Syrian hamsters is rapidly lethal .....	18
2. Temporal analysis of ALT levels and virus titers in hamsters challenged s.c. with 10 PFU of RVFV .....	20
3. Temporal analysis of ALT levels and virus titers in hamsters challenged s.c. with 1 PFU of RVFV .....	21
4. Histological findings in livers and spleens from RVFV-infected hamsters .....	24
5. Immunohistochemistry analysis of liver tissues from RVFV-infected hamsters demonstrates presence of viral antigen.....	25
6. In vitro activity of T-705 against the ZH501 strain of RVFV .....	37
7. T-705 post-RVFV exposure treatment protects hamsters from lethal disease .....	39
8. Sub-acute central nervous system RVFV infection in ribavirin-treated animals that survive the acute disease.....	42
9. T-705 intervention is effective out to 6 h post-RVFV exposure.....	43
10. Analysis of brain viral titers in moribund RVFV-infected hamsters treated with T-705 or ribavirin .....	45
11. Combined T-705 and ribavirin therapies significantly improve survival outcome and reduce viral burden when starting treatment 24 h post-RVFV challenge .....	48
12. Immunohistochemistry analysis of brain tissues from RVFV-infected hamsters demonstrates presence of viral antigen .....	51

## CHAPTER 1

### INTRODUCTION - LITERATURE REVIEW

#### RIFT VALLEY FEVER VIRUS AND FAVIPRAVIR

##### **Introduction**

Rift Valley fever (RVF) is a zoonotic infectious disease responsible for multiple epidemics and epizootics throughout Africa and the Arabian Peninsula. The etiologic agent, RVF virus (RVFV; *Bunyaviridae*, *Phlebovirus*) is principally transmitted by mosquitoes and typically manifests as an acute, self-limiting febrile illness; however, infection can lead to severe disease characterized by hemorrhagic fever, hepatitis, retinitis, and occasionally late-onset encephalitis [1-3]. Case-fatality rates in hospitalized patients are estimated to be 20%. Many ungulates are highly susceptible to RVFV infection. Mortality among young animals is especially high and gestating animals often experience spontaneous abortions. Outbreaks have had devastating effects on public and veterinary health, animal agriculture and both regional and national economies. Recent RVF outbreaks affecting both humans and ruminants have occurred in Mauritania (2012), South Africa (2010), Madagascar (2008), Sudan (2007-2008), Kenya (2006-2007), Somalia (2007), Tanzania (2007), Yemen (2000), and Saudi Arabia (2000) underscore the importance of this neglected tropical disease [4].

##### **Molecular Biology of RVFV**

RVFV is a spherical, enveloped virus containing a negative-sense RNA genome that is divided into three segments: small (S), medium (M) and large (L). The S segment encodes in an ambisense manner the nucleocapsid protein (N), which encapsidates the viral genome and a nonstructural protein, NSs, which is involved in the inhibition of the host innate-immune response [2,5,6]. The M segment encodes two envelope glycoproteins, Gn and Gc, and a

nonstructural protein, NSm; the L segment encodes an RNA-dependent RNA-polymerase (RdRp). Virions enter a host organism via direct contact with infected fluids/tissues or inhalation of aerosolized infectious particulate. RVFV is thought to gain entry into host cells by endocytosis and fusion with the plasma membrane is induced by a low pH [7,8]. Transcription and replication occur in the cytoplasm of host cells and require both RdRp and N, while Gn and Gc enter the secretory system [6,9]. The envelope glycoproteins form a complex which localizes in steady-state to the Golgi apparatus for virion maturation [10,11]. The assembled virus subsequently buds into the lumen of the Golgi apparatus, gets transported to, and then fuses with the plasma membrane, allowing virions to be released from the cell into the extracellular matrix [9-11] where they can gain access to neighboring uninfected cells and begin the replication process once again.

Light microscopy, electron microscopy, quantitative real-time PCR, *in vivo* and *ex vivo* imaging studies of RVFV infection and replication demonstrate a large tropism for a variety of tissues and cell types. Upon infection, it is presumed the virus replicates at the exposure site and the draining lymphatics; subsequent viremia seeds the target organs. During this stage of the infection, viral replication mainly targets the liver (particularly hepatocytes), spleen, thymus, brain and pancreas [12-14]. Utilization of a fluorescence-activated cell sorting analysis in recombinant GFP-expressing RVFV-infected mice demonstrated macrophages, dendritic cells and granulocytes to be the main target cells for RVFV replication [12]. Viral antigens have been detected in lymph node macrophages, and mononuclear phagocytic cells and dendritic cells in the spleen, thymus and lymph nodes of rats and mice [12-14].

### **RVFV Transmission**

RVF outbreaks generally follow periods of heavy rainfall and flooding, which create an ideal breeding environment for mosquito vectors [15-18]. The virus is typically spread by a variety of mosquito species, mainly those in the *Aedes* and *Culex* genera, although sandflies and certain midge and tick species have also been identified as vectors [16]. Various *Aedes* subspecies have been identified as the primary vector for RVFV. Of particular note, *Aedes mcintoshi* also has the ability to transmit the virus transovarially; RVFV persists in the infected mosquito eggs between epizootic periods, possibly representing the viral reservoir [19]. The cycle continues when the infected larvae hatch during periods of heavy rainfall emerging and feeding on nearby animals [20]. Amplification occurs mainly with *Culex* and other subspecies of mosquitos, which feed on the newly-infected animals and propagating the infection cycle through feeding on naïve animals. Other studies have demonstrated the capability of RVFV to be preserved in an enzootic cycle involving both *Aedes* and *Culex* mosquitos [16,18,21,22].

Transmission of the virus also occurs through direct contact with infected body fluids and tissues, and by aerosol transmission [23-26]. Past reports have documented the transmission of RVFV to slaughterhouse workers, animal handlers (including veterinary students) and laboratory staff which have come into contact with infected specimens/samples [15,26].

### **RVFV's Increasing Geographic Distribution**

In July 1930, farmers from the Great Rift Valley in Kenya reported gestating ewes spontaneously aborting and high mortality in newly-born lambs which prompted investigation and the subsequent identification of RVFV [26]. Since its discovery, the geographic distribution of RVFV has spread from this endemic region to neighboring countries, including Egypt, Madagascar, and regions in western Africa. The identification of RVFV in the Arabian Peninsula

in 2000 was the first RVFV epidemic recognized outside the continent of Africa [24,27-29].

These severe outbreaks have involved hundreds of thousands of people and animals and have caused substantial economic losses, particularly within livestock production [24,27,29].

A recent study published the genome sequence of 33 different strains of RVFV from past outbreaks throughout Africa and Saudi Arabia [17]. Phylogenetic analysis of these samples suggests the emergence of the originating strain of today's RVFV occurred in the late 1800's. Coincidentally, this was also when an agricultural shift was occurring, where indigenous livestock populations were becoming replaced by imported European breeds. It is speculated that the imported cattle and sheep, being highly susceptible to RVFV, were instrumental in endemic RVFV establishment; subsequent movement of these infected animals/herds and mosquitoes would conceivably propagate the dissemination of the virus throughout naïve regions [17]. Accordingly, should the virus be introduced, widespread transmission could readily occur in the United States and other Western countries where the vector species are endemic and susceptible hosts are present [6,30,31].

### **Clinical Pathology of RVF**

RVF epizootics are usually marked by an unexplained sudden onset of abortions in pregnant animals and high mortality rates in neonates following seasonal heavy rains; human RVF epidemics generally arise during these epizootic episodes [32-34]. Susceptibility of ruminant animals to RVFV infection varies greatly depending on a host of factors such as the viral strain and the species and age of the infected animal [2,5]. Typically, RVF manifests with the sudden onset of abortions ("abortion storms") in the majority of pregnant animals within a herd, coupled with a high incidence of mortality in the young. Young sheep, particularly lambs ( $\leq 1$  week old), appear to be the most susceptible to RVFV infection, with incidents of mortality reaching 90 – 100%; mortality of adult sheep in experimental RVFV infection is approximately

20% [35]. Goats display similar degrees of illness and mortality to that of sheep, whereas cattle experience comparable clinical symptoms, but mortality rates in adult animals are much lower (<10%) [35]. Infected animals clinically demonstrate a biphasic febrile reaction with severe prostration and collapse in young animals, agalactia in milk-producing females, nasal and (in cattle) lachrymal discharge, lymphadenitis, hemorrhagic diarrhea, debility with jaundice and death in older animals [1,26,36].

The clinical pathology of RVF is usually marked by leukopenia, high levels of enzymes associated with liver damage (i.e. alanine aminotransferase [ALT], glutamate dehydrogenase [GLDH]) and thrombocytopenia [26,36]. Postmortem investigation of RVFV-infected animals find that the liver is the primary site of pathological change where hepatic lesions progress to a massive necrotic hepatitis [26,36]. Extensive hemorrhaging (petechial and ecchymotic hemorrhages and hemorrhagic gastroenteritis), generalized lymphadenopathy and pulmonary edema and emphysema have been identified as postmortem indications [36].

In people, the virus has an incubation period of 2-6 days, after which flu-like symptoms appear and typically last 2-7 days after onset of illness. Symptoms are generally described as an abrupt onset of fever, chills, and lethargy with 1-3% of cases progressing to more serious forms of the disease including hemorrhagic syndrome, acute-onset hepatitis, delayed-onset encephalitis with long-term neurologic deficits, and retinal vasculitis and macular lesions that can result in varying degrees of blindness [32,33]. In severe cases of RVF, the fatality rate is 10-20%, but in recent outbreaks it has climbed as high as 40% [29].

### **RVFV Infection Animal Models**

Mouse models of RVFV infection are the most widely used for antiviral research and pathogenesis studies due to their susceptibility, similar disease pathology to newborn lambs and humans, and relatively low cost [2,37,38]. Typically, mice infected with the ZH501 strain die



within 3 to 7 days [13,39-41]. Clinical signs become apparent within 2 to 3 days post-infection (p.i.) indicated by ruffled fur, hunched posture and lethargy. Mice generally succumb from acute hepatitis or delayed meningoencephalitis. Although RVFV demonstrates diverse tissue tropism, as evidenced by high viral loads in a variety of tissues, histologic and immunohistochemical (IHC) examination of these tissues reveal the liver is the principle target organ. An overwhelming infection of hepatocytes results in cell damage, thereby elevating serum ALT and bilirubin levels, and frequently resulting in death by day 3 p.i. [2,38]. Interestingly, mice which survive the acute hepatic phase generally succumb to a late developing encephalitis, similar to that seen in human RVFV infection [13]. Additional histologic findings include congestion and hemorrhage of the liver, brain, spleen, lymph nodes, large intestine and the kidneys [2].

RVFV infection by both sub-cutaneous (s.c.) and aerosol routes in different strains of inbred rats reveals marked differences in susceptibility, disease progression and lethality. Following parenteral infection, Fisher 344, Buffalo, DA and Lewis strains of rats are essentially resistant to RVFV infection, ACI and Maax strains are moderately susceptible and Wistar-Furth and Brown Norway strains are highly susceptible [2,42,43]. When challenged by s.c. route, the Wistar-Furth and Brown Norway animals succumb to a fulminant hepatitis characterized by severe hepatocellular necrosis. To a lesser extent, necrotic lesions were also detected in the spleen, particularly the red pulp. Additionally, viremia and high viral loads in a variety of tissues, including the liver, spleen, lungs and kidneys have been reported; these pathogenic characteristics are similar to those reported in RVFV infected mice. In contrast, virus was not detected in the liver or blood of ACI and Maax strains; these animals succumbed to encephalitis. Aerosol challenge demonstrated that Wistar-Furth rats were the only strain to develop and

succumb to acute hepatic disease, whereas the ACI and Lewis rat strains both developed fatal encephalitis.

With death occurring 2 – 3 days post-RVSV infection, golden Syrian hamsters are one of the most susceptible rodent species [44-46]. Despite being one of the first laboratory animals to be challenged with the virus [26], very little work has been done characterizing the pathogenesis of RVSV infection in hamsters. Similar to mice, pathological changes to the liver involve an overwhelming infection of hepatocytes [37]. In a subsequent study, the hamster model was used to determine a minimum protective titer after passive and active immunization [44]. Immunized animals had a high variation in antibody response, more than any other tested rodents. Additionally, it was discovered that the passive administration of low titers of neutralizing antibodies protected animals from fulminant hepatitis, yet animals ultimately succumbed from delayed-onset encephalitis. As this study was aimed towards comparison of active and passive immunization, further investigations towards understanding the pathogenesis of encephalitis was not conducted [44].

The gerbil represents a distinctive RVSV infection model, typically succumbing to fatal encephalitis in the absence of extraneural lesions and with minimal liver involvement, in contrast to other rodent systems [47]. Moderately susceptible to RVSV infection, animals typically die within 1 to 3 weeks in an infectious dose-dependent manner. Remarkably, animals also exhibited age-dependent resistance to RVSV infection, where viral replication in the brain occurred in 4-week-old gerbils, but not in 10-week-old gerbils. Histologic examination of the brain revealed a focal necrotizing encephalitis with neuronal necrosis [47].

Recently, two distinct novel non-human primate (NHP) RVSV infection models utilizing marmosets and African Green monkeys (AGMs) were published. As RVSV infection in the rhesus macaque NHP model is not uniformly lethal and variations in susceptibility when using different

strains of RVFV have been reported [38,48], the marmoset and AGM were evaluated as possible alternatives [49,50]. Regardless of the exposure route (s.c., i.v. and i.n.), marmosets were found to be more susceptible to infection than the rhesus macaque, as these animals quickly succumbed to a lethal hepatitis, characterized by robust infection of hepatocytes. Additionally, signs of viral hemorrhagic fever (VHF), neurologic impairment and possible retinitis were observed [49]. When both marmosets and AGMs were infected via aerosol challenge, marmosets were found to be more susceptible to lower doses of RVFV than AGM ( $3.5 \times 10^3$  PFU vs.  $1.17 \times 10^5$  PFU, respectively). Despite this, clinical signs of encephalitis and mortality rates between the two species were comparable to each other and the data suggests that both AGMs and marmosets would be suitable disease models for human RVFV aerosol exposure [43]. Furthermore, the ability of marmosets to reproduce lethal hepatitis and encephalitis can serve as a useful model towards evaluating promising antiviral compounds and vaccines.

### **Vaccine and Therapeutic Development**

Currently, two vaccines are approved for the prophylactic immunization of livestock. The Smithburn vaccine is a live attenuated vaccine, and although useful in rapidly providing long-term immunity after a single dose, its use has led to high abortion rates and/or teratology in a significant number of gestating animals [51-53]. The second vaccine is a formalin inactivated aluminum hydroxide-adjuvant vaccine based on a low passage wild-type RVFV strain. This type of vaccine is costly to produce and requires multiple inoculations with regular boosters, but is useful during outbreaks, particularly in non-endemic areas [54,55].

The only RVFV vaccine currently available for human use is TSI-GSD-200. Derived from the RVFV vaccine NDBR-103 to reduce inter-lot variation, TSI-GSD-200 is a formalin-inactivated vaccine that is available to personnel working in high infectious risk and/or endemic areas. Unfortunately, the vaccine is costly and difficult to produce, requires a large dose volume

(relative to an attenuated vaccine), three initial inoculations, a 6-month booster and continual annual boosters [55-57]. A promising live-attenuated vaccine, MP-12, was generated via mutagenesis of an RVFV strain (ZH548) isolated from the 1977 outbreak in Egypt and grown in MRC-5 human diploid fibroblast cells [58,59]. The MP-12 vaccine has demonstrated efficacy in multiple livestock studies [60-62] and, more recently, it was evaluated in Phase II clinical trials with favorable results with confirmatory reports still pending [55,63].

While vaccines are the primary defense against viral diseases [64] the need for the development of effective antiviral therapeutics is another essential component towards fighting severe viral infections [65]. The antiviral compound ribavirin is the only licensed drug that can be used for emergency treatment of RVFV infection. Acting as a purine nucleoside analog, ribavirin is a broad spectrum antiviral for which the principle mechanism of action *in vivo* remains undetermined. Evidence reported in previous studies indicate direct (polymerase inhibition, RNA capping interference and lethal mutagenesis) and indirect (inosine monophosphate dehydrogenase inhibition and immunomodulatory effects) mechanisms may both play important roles in ribavirin's antiviral activity [66,67]. Unfortunately, due to adverse side effects such as dose-related hemolytic anemia and teratogenic effects, ribavirin is only approved for compassionate use under investigational new drug protocols for the treatment of RVF, several other bunyaviral hemorrhagic fevers, and hemorrhagic fever of arenaviral origin [68,69]. Additionally, the use of emergency ribavirin therapy as the post-exposure treatment of RVFV exposure has been reported to have unforeseen negative consequences. During the Saudi Arabia outbreak, ribavirin was used to treat patients suffering from hemorrhagic manifestation associated with RVFV infection. Despite apparent success in resolving the hemorrhagic symptoms, patients later succumbed to a severe late-onset of meningoencephalitic complications [55]. The ribavirin molecule is too large to effectively bypass the blood-brain

barrier (BBB), therefore the development of safer and more effective antivirals that can gain access to the central nervous system are needed [55].

Another promising antiviral compound is favipiravir (6-fluoro-3-hydroxy-2-pyrazinecarboxamine), also called T-705, which is a pyrazine derivative that is an RdRp inhibitor of the influenza virus and has demonstrated potent antiviral activity against multiple RNA viruses [70]. Evidence suggests host cell enzymes convert T-705 into T-705-4-ribofuranosyl-5-triphosphate (T-705RTP), the active form of the drug that selectively inhibits the viral polymerase without affecting host cellular DNA or RNA synthesis [71]; this specificity is what likely contributes to its low toxicity.

T-705 has demonstrated robust activity against the MP-12 vaccine strain of RVFV in cell culture along with several other related bunyaviruses, including: several hantaviruses, La Crosse virus, and Punta Toro and sandfly fever phleboviruses [40,72-74]. Punta Toro virus (PTV), a more accessible and less biohazardous agent (biosafety level 2; BSL-2) belonging to the same genus as RVFV, has been used to model severe RVFV infection in mice and hamsters [75-77]. Initial studies evaluating the efficacy of T-705 in the PTV infection models have yielded favorable results, demonstrating a drastic reduction in mortality, viral loads in the tissues and sera and liver disease [40,74].

### **Bioterrorism**

RVFV is categorized as a potential biological weapon due to its transmissibility by aerosol, ease of propagation in cell culture systems to very high titers, and its potential to be modified by reverse genetics technologies into a more virulent agent which could escape detection and/or prevention and control measures currently in development [32,78]. In addition to the above, the threat RVFV poses to public health and animal agriculture and the current lack of prophylactic countermeasures has resulted in the virus being classified as a

priority Category A pathogen by the National Institute of Allergy and Infectious Diseases (NIAID) and an overlap "Select Agent" by the Center for Disease Control (CDC) and the United States Department of Agriculture (USDA) [78-81]. Because RVFV can quickly gain footholds in naïve populations where competent vectors are abundant, the potential for expansion into other continents such as North America and Europe is feasible [82,83]. The vulnerability of these regions could result in worldwide spread and significant outbreaks of disease, further emphasizing the need to develop safe and efficacious vaccine or post-exposure therapeutic.

## CHAPTER 2

### MODEL DEVELOPMENT

#### **Introduction**

Rift Valley fever (RVF) is a zoonotic, arthropod-borne illness that typically manifests as an acute febrile and hepatic disease in ungulates and humans. RVF is of notable public health importance due to its severity, recurrent outbreaks and progressive geographic distribution [6,10,17]. The etiological agent, Rift Valley fever virus (RVFV), is a member of the *Bunyaviridae* family and the genus *Phlebovirus*. The virus has a tripartite single-stranded RNA genome which encodes 7 proteins using an ambisense coding strategy [6,32]. It can be transmitted by a variety of mosquito species, but is also spread via contact with infected fluids and tissues [26].

Susceptibility of livestock to RVFV infection varies greatly depending on the viral strain, and the species and age of the infected animal [5]. Hepatic necrosis, an increase in liver enzymes, and high viremia are characteristic of severe acute lethal infection in ruminants. In humans, the virus has an incubation period of 2-6 days, after which flu-like clinical signs appear and typically last 2-7 days after onset of illness [26,32,33]. Symptoms are generally described as an abrupt onset of fever, chills, and lethargy with 1-3% of cases progressing to more serious forms of disease including hemorrhagic syndrome, acute-onset hepatitis, delayed-onset encephalitis with long-term neurologic deficits, and retinal vasculitis and macular lesions which can result in varying degrees of blindness [2]. In severe cases of RVF, the fatality rate is 10-20%, but in recent outbreaks it has climbed as high as 40% [29]. Currently, no FDA approved vaccines or antiviral therapies for the prevention or treatment of RVF exist. Consequently, the development of animal models to better understand the disease is of increasing importance when considering the threat RVFV presents to public and animal health and the potential for

importation into the US or other naïve regions of the world that harbor competent mosquito vector populations [21,30,31].

The key pathological features of RVFV infection vary widely among animal species and humans. Typically, RVFV infection that results in severe disease is characterized by hepatocellular necrosis [26,84]. Because of the greater biohazard risk and “Select Agent” status of RVFV, a surrogate hamster model for RVF is based on challenge with the related Punta Toro virus (PTV), a BSL-2 agent, has been used for pathogenesis and antiviral studies [3]. Although the hamster PTV infection model has proved useful for reproducing certain features of severe human and animal RVFV infections where hepatic disease is a prominent pathological feature, the animals fail to develop encephalitis [75,76]. Recently, a detailed characterization describing the pathogenesis of RVFV infection in BALB/c mice reported hepatitis and encephalitis consistent with severe human RVFV infection [13]. Additionally, a study using three different inbred strains of rats infected with RVFV by both aerosol and sub-cutaneous (s.c.) routes demonstrated remarkable differences in disease progression and lethality [42]. Wistar-Furth rats were the only strain to develop and succumb to acute hepatic disease following aerosol exposure. ACI and Lewis rat strains both developed fatal encephalitis after aerosol challenge, but with varying degrees of susceptibility to RVFV; remarkably, Lewis rats are refractory to s.c. challenge [42]. These differences are consistent with the varying clinical disease presentations observed in humans. Although these murine and rat RVFV models are useful systems to evaluate most vaccine and antiviral drug candidates, certain therapeutic platforms, particularly those directed at host targets, may have little to no activity in mice or rats. For example, consensus IFN, an FDA-licensed recombinant protein therapeutic, was evaluated in the hamster PTV model because it does not cross-react with the mouse system [85,86].



Hamsters models are becoming more widely used in infectious disease research with greatest increase in use in the field of virology [87]. We recently evaluated a promising broad-spectrum antiviral drug candidate and adenovirus vectored human consensus IFN in a model of RVFV infection in hamsters [84,88]. Limited details describing RVFV infection and disease in hamsters have previously been reported [37,44,45,89-91]. Here, we present linked virologic, liver enzyme, and pathology findings during the course of RVFV infection in golden Syrian hamsters challenged s.c. with the pathogenic ZH501 strain of RVFV to gain insights into the natural history of disease in this small animal model of RVFV.

## **Materials and Methods**

### ***Virus and cells***

The molecular clone of RVFV, strain ZH501, was obtained from Dr. Stuart Nichol (CDC, Atlanta, GA). The virus stock ( $1.1 \times 10^8$  plaque-forming units (PFU/ml); 1 passage in BSRT7 cells, 3 passages in Vero E6 cells) used was from a clarified cell culture lysate preparation and was inoculated by subcutaneous (s.c.) injection (ventral, right side of abdomen). The African green monkey kidney cell line, Vero 76, was purchased from the American Type Culture Collection (ATCC) (Manassas, VA) and maintained in minimal essential medium (MEM) supplemented with 10% heat-inactivated fetal bovine serum (FBS) (GE Healthcare HyClone Laboratories, Logan, UT).

### ***Animals and ethics regulation***

Female 90-115 g golden Syrian hamsters (The Charles River Laboratory, Willimantic, CT) were quarantined for 7 days prior to challenge and fed standard Harlan lab block and tap water *ad libitum*. All animal procedures complied with USDA guidelines and were conducted at the AAALAC-accredited Laboratory Animal Research Center at Utah State University under protocol 2011, approved by the Utah State University Animal Care and Use Committee.

### ***Titration of RVFV in hamsters***

To determine the most appropriate RVFV challenge dose for the natural history study, hamsters (n=5-6/group) were challenged by s.c. injection with a 0.2 ml inoculum containing varying log<sub>10</sub> dilutions of RVFV spanning 6 orders of magnitude. The s.c. challenge was intended to simulate natural mosquito-borne transmission. The animals were observed 15 days for morbidity and mortality, and weighed every 3 days starting on the day of challenge.

### ***Natural history of RVFV infection in hamsters***

Based on the titration study, challenge doses of 10 PFU or 1 PFU were selected to evaluate the progression and tissue tropism of RVFV infection. Hamsters (n=4-6/group) were selected for sacrifice on days 1 through 4 post s.c. challenge with RVFV. Various tissue samples were collected (pancreas, spleen, liver, lung, brain, large intestine, kidney, adrenal gland, and eye) for virus titer determination, histopathology and immunohistochemistry (IHC) analysis, as described below. Whole blood was collected for clinical chemistry analysis, and serum was assayed for viral load and kinetic alanine aminotransferase (ALT) levels.

### ***Virus titer determination***

Virus titers were assayed using an infectious cell culture assay. Tissue samples were homogenized in a fixed volume of MEM and the homogenate and serum were serially diluted and added to quadruplicate wells of Vero cell monolayers in 96-well microplates. The viral cytopathic effect (CPE) was determined 3-4 days post-plating, and the 50% endpoints were calculated as described [92]. The lower limit of detection for serum samples was 1.75 log<sub>10</sub> CCID<sub>50</sub>/ml and the lower limit of detection for tissues was generally in the range of 2-3 log<sub>10</sub> CCID<sub>50</sub>/g.

***Kinetic serum alanine aminotransferase (ALT) determinations***

Detection of ALT in serum is an indirect method for evaluating liver dysfunction. Serum ALT concentrations were measured using the ALT (SGPT) Reagent Set purchased from Pointe Scientific, Inc. (Lincoln Park, MI) per the manufacturer's recommendations. The reagent volumes were adjusted for analysis on 96-well microplates.

***Histopathology***

Tissue samples of the pancreas, spleen, liver, lung, kidney, adrenal gland, large intestine, brain and eye were obtained at prescribed necropsy times and preserved for 3 weeks in 10% neutral buffered formalin. The samples were subsequently sent to the Utah Veterinary Diagnostic Laboratory (Logan, UT) for blinded histopathology examination and analysis by a board certified veterinary pathologist.

***Immunohistochemical staining***

Based on viral burden in the tissues and histopathology review, replicate tissue sections from a representative animal per sacrifice group were selected for immunohistochemical (IHC) staining. The sections were deparaffinized and rehydrated by standard histological procedures with xylene-ethanol, descending grades of alcohol, and distilled water. Briefly, sections were immersed in DakoCytomation Target Retrieval Solution (Dako Corp., Carpinteria, CA), boiled at 125°C for 4 minutes in a decloaking chamber (Biocare Medical, Concord, CA), permeabilized with 0.5% X-100 in PBS, and exposed to a peroxide block using 3% hydrogen peroxide. Slides were then incubated in 10% normal goat serum (NGS) and 0.2% Triton X-100 in PBS for 1 hour, and subsequently incubated with a mouse anti-RVfV Ab (1:1000; RVf MP-12 mouse hyperimmune ascites fluid provided by Dr. Robert Tesh, World Reference Center for Emerging Viruses and Arboviruses, University of Texas Medical Branch, Galveston, TX) for 24 hours at room

temperature. Secondary antibody using goat anti-mouse horseradish peroxidase (1:200; Sigma-Aldrich, St. Louis, MO) was applied to the slides for 1 hour, then incubated for 15 minutes using Impact™ NovaRed substrate (Vector Laboratories, Burlingame, CA), and counterstained with hematoxylin QS nuclear counterstain (Vector Laboratories). Lastly, sections were dehydrated in ascending grades of alcohol, passed in xylene and permanently mounted with non-aqueous mounting medium VectaMount (Vector Laboratories). The stained slides were sent to the Utah Veterinary Diagnostic Laboratory for IHC/histopathology examination and analysis by a board certified veterinary pathologist.

## **Results**

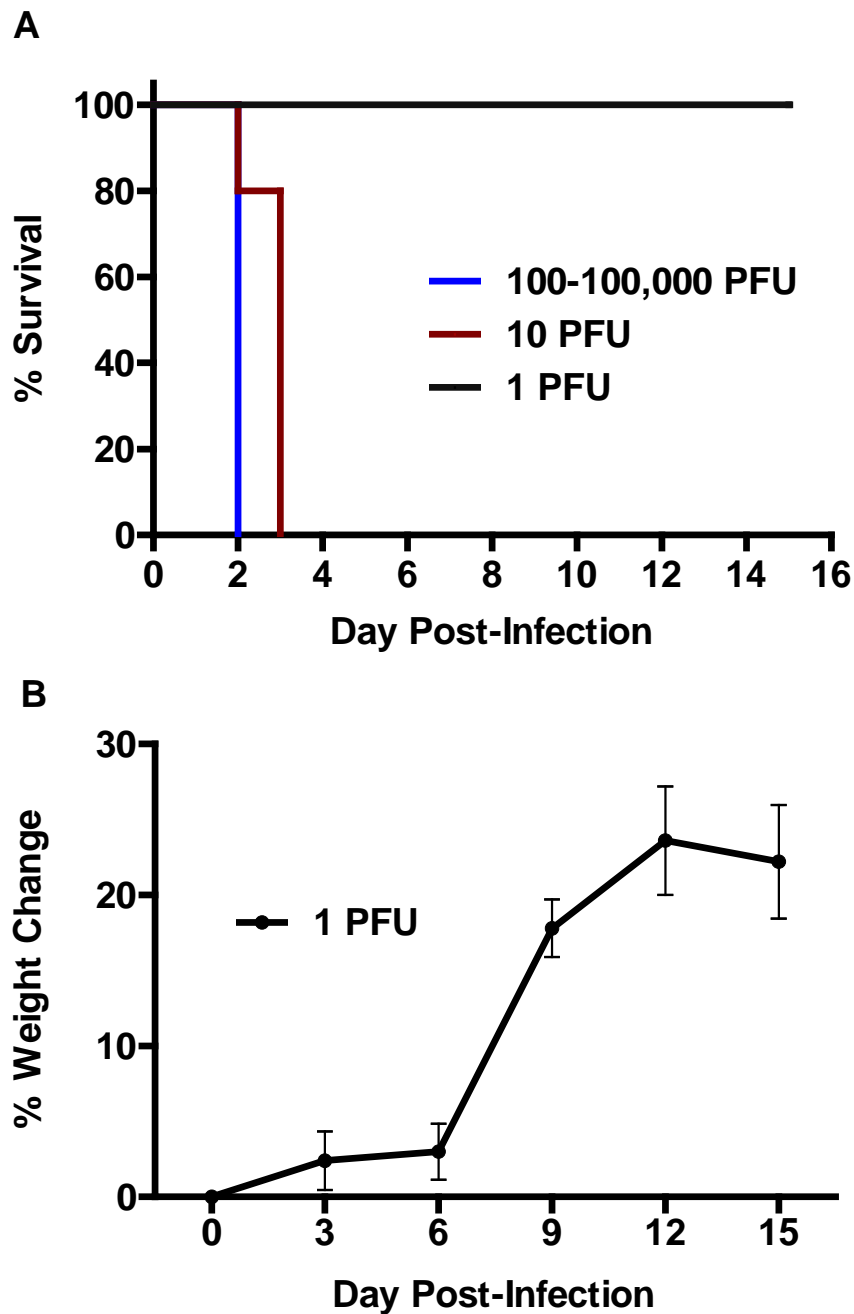
### ***Susceptibility of hamsters to RVFV***

The initial titration of the ZH501 strain of RVFV in golden Syrian hamsters revealed a rapid disease progression which was predominately lethal. Clinical signs of illness including lethargy, ruffled fur, and hunched posture were observed in many of the animals by day 2 post-infection (p.i.). The virus was uniformly lethal within 2-3 days following s.c. route inoculation at doses of 10 PFU or greater (Figure 1A). Only animals that received the lowest infectious dose of approximately 1 PFU (based on plaque titration in Vero 76 cells) survived the challenge.

Although none of these animals succumbed to infection, the slow weight gain at the onset of the experiment, followed by the marked increase in weight beginning day 6 p.i. suggests that the animals were likely exhibiting some degree of illness (Figure 1B).

### ***Characterization of RVFV disease progression***

Based on the titration experiment demonstrating high susceptibility of hamsters to s.c. RVFV infection, we next challenged animals with either 10 or 1 PFU of RVFV to assess the natural

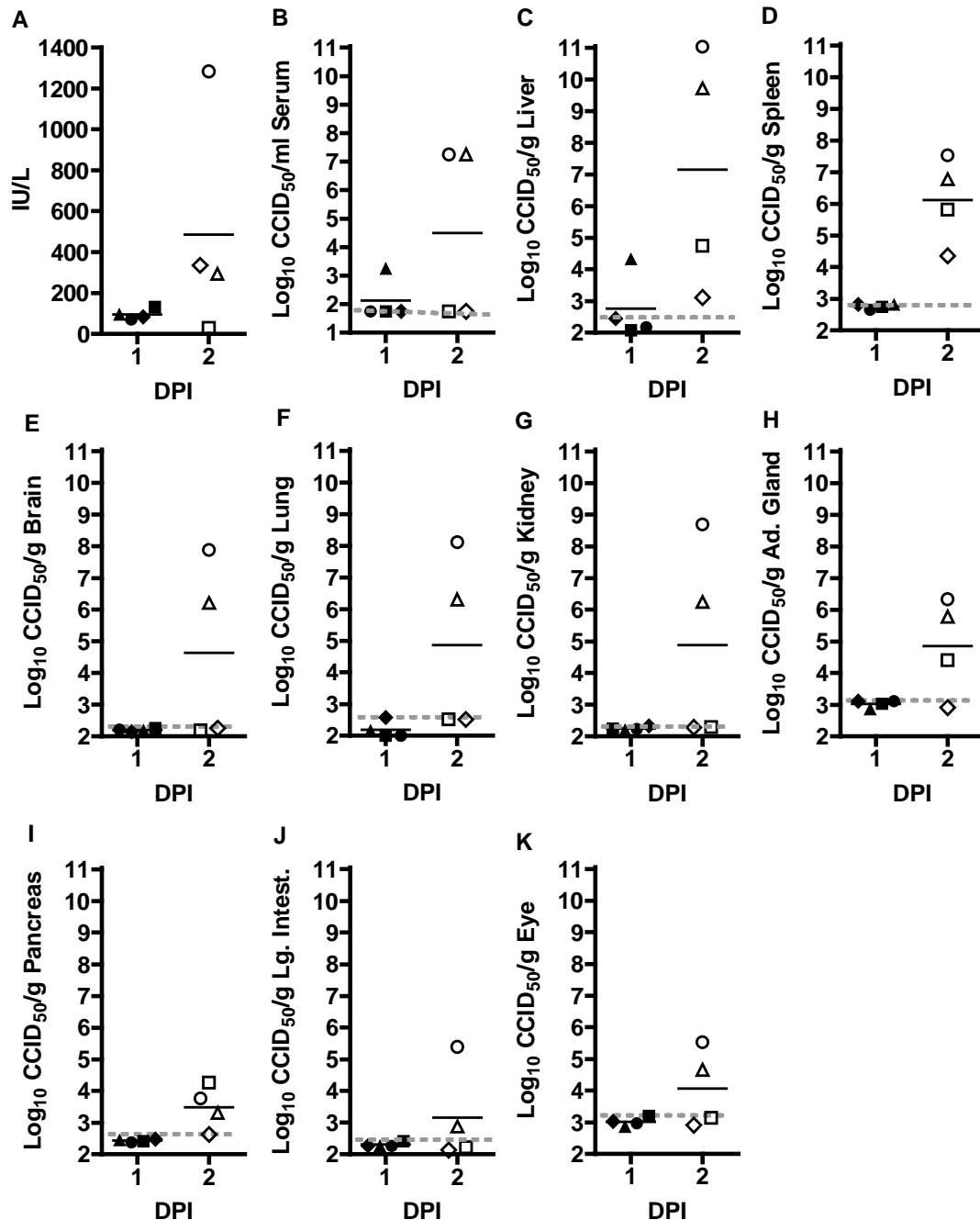


**Figure 1. RVFV challenge of golden Syrian hamsters is rapidly lethal.** Groups of 5-6 hamsters were infected s.c. with 0.2 ml of viral inoculum containing the indicated PFU of RVFV. Mortality was monitored over a 15-day period. A) Percent survival and B) mean % change in weight of surviving animals relative to respective day 0 weights measured every 3<sup>rd</sup> day are shown.

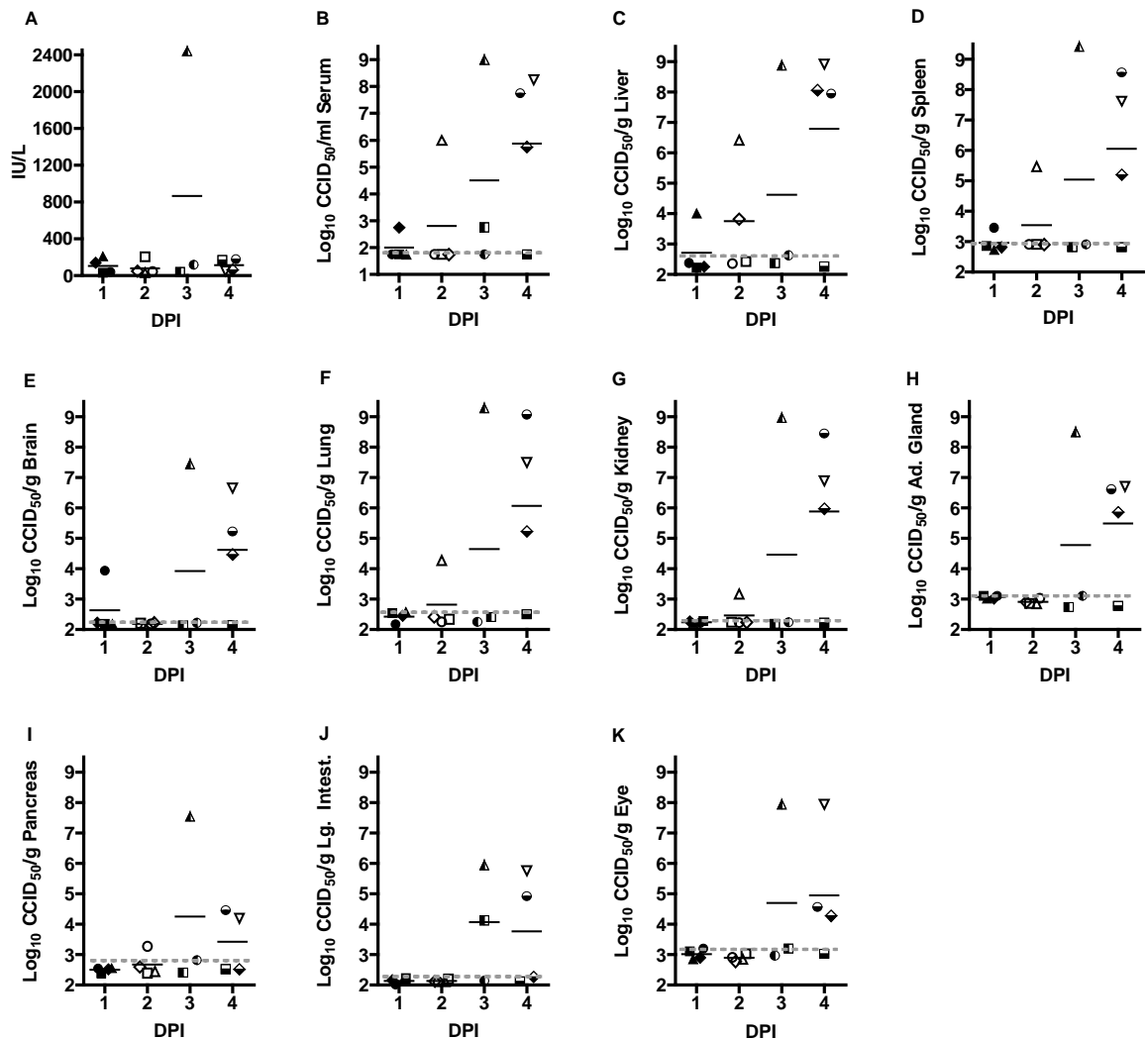
history of disease. Subsets of animals were sacrificed on day's 1 - 4 p.i., to examine the development of viremia, tissue titers, ALT, and histopathology in a temporal fashion. Because all animals receiving 10 PFU in the titration study succumbed by day 3 p.i., this portion of the study was designed to have only a day 1 and 2 sacrifice. For the animals challenged with 1 PFU, several animals scheduled for sacrifice on day 3 (3 of 6 hamsters) and 4 (2 of 6 hamsters) succumbed prior to the time of sacrifice. The threshold for lethality appears to be very close to 1 PFU, and thus the lack of mortality with the 1 PFU challenge in the titration study is likely due to experimental variability in the preparation of the challenge stock.

In the 10 PFU challenge group, serum ALT was not elevated until day 2 p.i., demonstrated by a high level in one hamster, and slightly elevated concentrations in two others (Figure 2A). In one animal, low level viremia and liver virus was detected as early as day 1 p.i. (Figure 2B, C). In the day 2 p.i. cohort of animals two hamsters had virus in all tissues examined, with low-level or undetectable virus burden in the other two animals (Figure 2B-K).

When the RVFV challenge dose was reduced to 1 PFU, ALT concentration was dramatically elevated on day 3 (>2300 IU/L) in the only surviving hamster which also had significant liver virus titers (Figure 3A and C, half-filled triangle). Despite substantial viral loads in the livers of 3 of the 4 animals in the day 4 group, ALT levels were not significantly elevated. Little to no virus was detected in the serum 24 h after challenge and only one of four hamsters had viremia in the 48 h cohort (Figure 3B). By day 3 p.i., 2 of 3 surviving animals had measurable virus, and on day 4 p.i., 3 of 4 hamsters had remarkable viremia. In general, the day 3 and day 4 animals with high viremias had substantial viral loads in all tissues examined; the highest levels of virus were found in the liver, spleen, lung, kidney and adrenal gland (between 8.5-9.4 log<sub>10</sub> CCID<sub>50</sub>/g), and significant amounts were detected in the brain, pancreas, large intestine and the



**Figure 2. Temporal analysis of ALT levels and virus titers in hamsters challenged s.c. with 10 PFU of RVFV.** Groups of 4 animals were sacrificed on the specified days post-infection for analysis of A) serum ALT concentration, and B) serum, C) liver, D) spleen, E) brain, F) lung, G) kidney, H) adrenal gland, I) pancreas, J) large intestine, and K) eye virus titers. Unique symbols represent values for the same animal across all parameters assessed and the gray dotted lines represents the limits of detection for each tissue or serum. DPI, day post-infection.



**Figure 3. Temporal analysis of ALT levels and virus titers in hamsters challenged with 1 PFU of RVFV.** Groups of 3-4 animals were sacrificed on the specified days post-infection for analysis of A) serum ALT concentration, and B) serum, C) liver, D) spleen, E) brain, F) lung, G) kidney, H) adrenal gland, I) pancreas, J) large intestine, and K) eye virus titers. Several hamsters succumbed prior to their designated time of sacrifice (3 in the day 3 sacrifice group and 2 in the day 4 group) and thus were not included in the analysis. The limits of detection are indicated by the grey dotted lines. Unique symbols represent values for the same animal across all parameters assessed. DPI, day post-infection



eye (between 5.9-7.9  $\log_{10}$  CCID<sub>50</sub>/g) (Figure 3C-K). Due to the expiration of several hamsters prior to their designated time of sacrifice, it is important to note that data from these animals with the most severe disease are not represented in the day 3 and 4 data.

### ***Histopathology and IHC analysis***

Histopathology and subsequent IHC analysis was performed on all collected tissues, as described above. Histologic examination of tissues from animals challenged with 10 or 1 PFU identified the liver as the primary target organ of infection. Overall, the main histologic lesion of the liver was randomly distributed multifocal acute hepatocellular necrosis with frequent eosinophilic intranuclear inclusions (Cowdry type A) bodies in hepatocytes surrounding the areas of necrosis during the acute infection (Figure 4D), which become apparent by day 2 and 3 p.i. for the 10 and 1 PFU challenged animals, respectively.

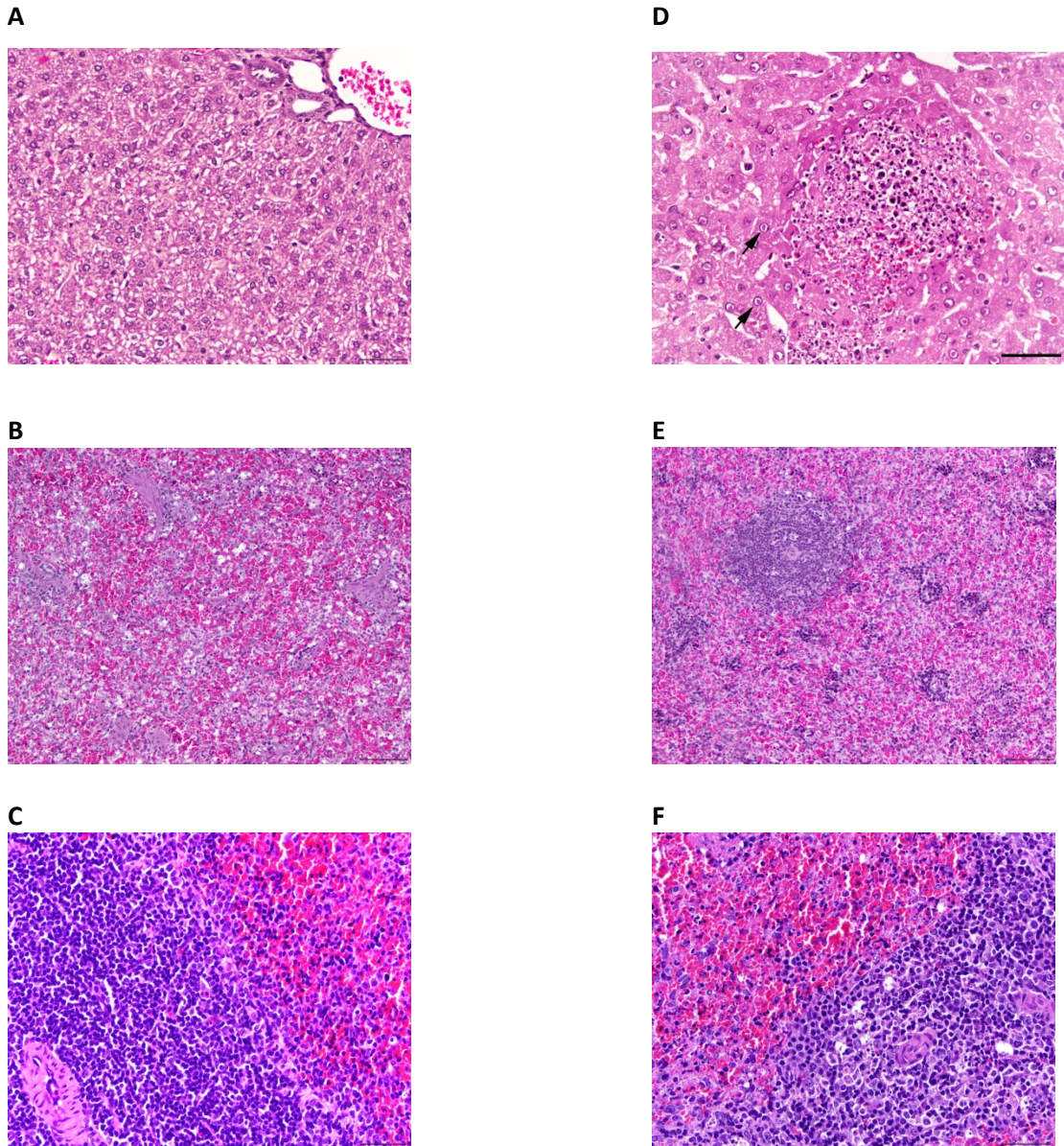
In general, the spleens of hamsters from both 1 and 10 PFU challenge groups exhibited a mild increase in lymphocyte area, and cellularity of the periarteriolar lymphoid sheath and lymphoid follicle. Erythrocyte depletion of the splenic red pulp, possibly due to splenic contraction, was detected in 2 of 4 animals in the 10 PFU group at day 1 p.i, with one animal also having white pulp (lymphoid) depletion (Figure 4E). In the day 2 p.i. 10 PFU sacrifice group, 3 of 4 animals began to exhibit multifocal hepatocellular necrosis; one animal also had discernable erythroid and lymphoid depletion (Figure 4F). Comparatively, erythroid or lymphoid depletion was not observed in the 1 PFU challenge group until day 3 p.i. in 1 of the 3 surviving animals (Figure 4F). Additionally, a significant amount of cell debris in the red pulp was observed, suggesting necrosis or apoptosis of lymphocytes and/or other circulating cells migrating through the splenic parenchyma. Of the hamsters sacrificed on day 4 p.i. only one animal had detectable white pulp depletion (data not shown). Little to no significant

microscopic lesions was observed in pancreas, lung, brain, large intestine, kidney, adrenal gland, or eye tissues.

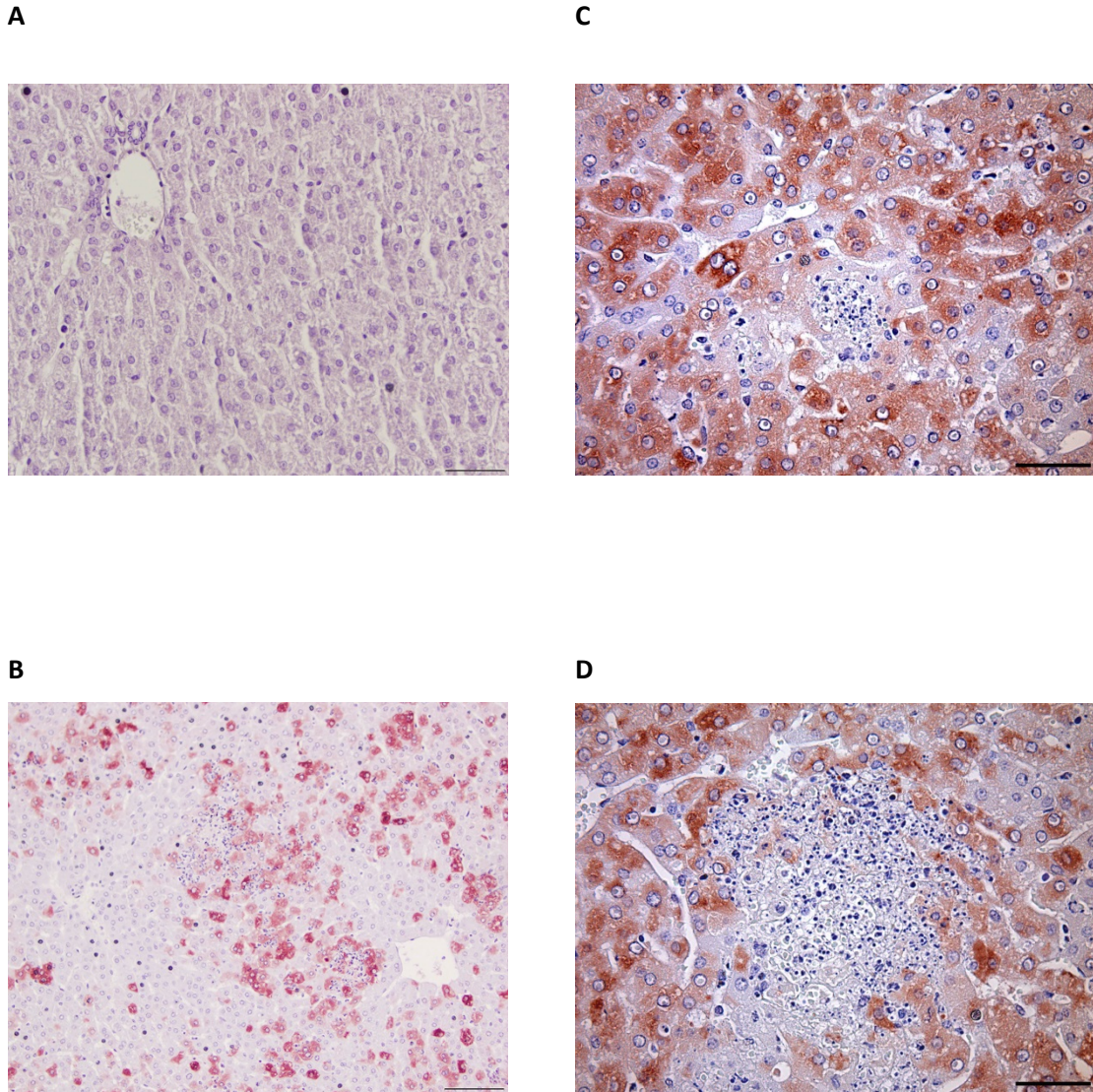
Successive IHC staining and analysis of the collected tissues generally demonstrated increased immunoreactivity in the livers with the most severe lesions. No immunoreactivity was observed in any of the animals challenged with 10 PFU at day 1 p.i., but by day 2 p.i. approximately 30-40% of hepatocytes examined showed diffuse to multifocal and mild to strong cytoplasmic staining for RVFV antigen (Figure 5B); positive hepatocytes are in small groups or randomly distributed individual hepatocytes. The 1 PFU challenge group did not display any immunoreactivity until day 3 p.i., when IHC staining revealed most hepatocytes (approximately 90%) in the liver sections having strong, diffuse, cytoplasmic immunoreactivity for RVFV antigen (Figure 5C). Occasional multifocal RVFV positive cells were present in the sinusoids and were interpreted as likely infected Kupffer cells (data not shown). On day 4 p.i. approximately 40-50% of hepatocytes exhibited a multifocal to diffuse, and mild to strong, cytoplasmic immunoreactivity for RVFV antigen (Figure 5D); positive hepatocytes are in larger areas/groups of hepatocytes. The hepatocytes surrounding the areas of hepatocellular necrosis were positive for RVFV, but only rare cell debris was positive for viral antigen in the areas of necrosis (Figure 5D). Inclusion bodies in the nuclei of hepatocytes, endothelial cell lining blood vessels and sinusoids, and biliary cells were not immunoreactive. As observed with the 10 PFU animals, no staining for RVFV antigen was observed in the spleen, brain, kidneys, lung, pancreas, adrenal gland, intestine, blood vessels, or eye in the hamsters challenged with 1 PFU.

## **Discussion**

Although previous studies have examined the susceptibility of hamsters to lethal RVFV infection [37,44,45,89-91], a more detailed description of the natural history is lacking. Here,



**Figure 4. Histological findings in livers and spleens from RVFV-infected hamsters.** A) Hamster liver section from sham-infected control animal showing normal liver histology, 400X, bar = 50  $\mu$ m. B) Hamster spleen from sham-infected control showing normal red pulp, 200X, bar = 100  $\mu$ m and C) white pulp, 400X, bar = 50  $\mu$ m. D) 1 PFU, day 3 p.i. hamster liver (Figure 3, half-filled triangle) showing acute hepatocellular necrosis and eosinophilic nuclear inclusions (arrows) in hepatocytes surrounding the area of necrosis, 600X, bar = 30  $\mu$ m. E) 10 PFU, day 2 p.i. hamster spleen (Figure 2, open triangle) displaying diffuse erythroid depletion of the red pulp and lymphoid depletion of the white pulp, 200X, bar = 100  $\mu$ m. F) 1 PFU, day 3 p.i. hamster spleen (Figure 3, half-filled triangle) displaying diffuse lymphoid depletion of the white pulp. Heterochromatic cell fragments, indicative of apoptotic bodies and tingible body macrophages with cytoplasmic phagocytized apoptotic debris are scattered in the periarteriolar lymphoid sheath. 400X, bar = 50  $\mu$ m. Hematoxylin and Eosin stain.



**Figure 5. Immunohistochemistry analysis of liver tissues from RVFV-infected hamsters demonstrates presence of viral antigen.** A) Hamster liver section from sham-infected control animal, 400X, bar = 50  $\mu$ m. B) 10 PFU, day 2 p.i. hamster liver (Figure 2, open circle) with 30-40% of hepatocytes exhibiting immunoreactivity for RVFV antigen, 20X, bar = 100  $\mu$ m. C) 1 PFU, day 3 p.i. hamster liver (Figure 3, half-filled triangle) with hepatocytes showing strong diffuse cytoplasmic immunoreactivity for RVFV antigen, 400X, bar= 50 $\mu$ m. D) 1 PFU, day 4 p.i. hamster liver (Figure 3, open upside-down triangle) with hepatocytes positive for RVFV antigen, 400X, bar = 50  $\mu$ m. NovaRed stain with hematoxylin QS counterstain.

Table 1. Comparison of RVFV animal models to the Syrian hamster model.

General Considerations	MODELS					
	Mouse	Rat <sup>a</sup>	Hamster	Marmoset	AGM <sup>d</sup>	Macaque
Lethality	High	Low-High	High	Moderate	Moderate	Low
Aerosol	Yes	Yes	ND	Yes	Yes	Yes
Cost	Low	Low	Low	Moderate	Moderate	High
Availability/Accessibility	High	High	High	Low	Low	Low
Mortality from Acute Disease (days)	3-5	3-5	2-3	9-11	9-11	5-15
<b>Components of Human Disease</b>						
Biphasic Fever	No	No <sup>b</sup>	ND	Yes	Single-phase	Yes
Hemorrhage	Yes	No	No	Yes	No	Yes
Petechia	No	No	No	No	No	Yes
Thrombocytopenia	Yes	ND	ND	NEI	NEI	Yes
Leukopenia	Yes	ND	ND	No	No	Yes
Lymphoid depletion	Yes	ND	Yes	ND	ND	ND <sup>b</sup>
Lymphocyte apoptosis	Yes	ND	NEI	ND	ND	ND <sup>b</sup>
Infection of macrophages	Yes	ND	NEI	ND	ND	ND <sup>b</sup>
Coagulopathy (DIC)	No	ND	ND	NEI	NEI	Yes
Hepatitis/Hepatocellular Necrosis	Yes	Yes	Yes	Yes	No	Yes
Retinitis	No	No	No	NEI	No	No
Delayed-Onset Encephalitis	Yes	Yes	Yes <sup>c</sup>	Yes	Yes	No

<sup>a</sup> Strain dependent

<sup>b</sup> Elevated body temperature prior to death

<sup>c</sup> Ribavirin-treated animals

<sup>d</sup> Aerosol challenge

ND, not determined; NEI, not enough information. NEI.

we have characterized a model of s.c. RVFV infection in hamsters based on challenge with the ZH501 strain of the virus and discuss our findings in terms of other rodent RVFV models and severe cases of disease in humans. Consistent with earlier studies reporting a high degree of susceptibility, hamsters succumbed to a 10 PFU challenge with the ZH501 strain of RVFV within 2 to 3 days. By comparison, C57BL/6J mice challenged with 100× more PFU of the same virus stock succumbed in 3 to 6 days [39], underscoring the heightened sensitivity of hamsters to acute RVFV-induced disease.

As described by Smith and colleagues [13], we found that a wide variety of tissues supported RVFV infection in hamsters. Moreover, previous hamster studies utilizing RVFV describe viremia and elevated viral loads in liver, brain, and spleen tissues similar to our findings [37,45,91]. Based on our viral titer, serum ALT, histopathology, and IHC data, the liver was clearly the primary target for RVFV infection. The severe hepatocellular necrosis seen early during infection and the intense IHC staining of affected hepatocytes suggests that the hamsters were likely succumbing from fulminant hepatitis. This is in contrast to the age-dependent gerbil RVFV infection model where liver involvement is minimal and encephalitis is believed to be the cause of death [47]. Marked elevation of serum ALT levels indicative of liver dysfunction was observed in several hamsters in the 10 PFU challenge group that had substantial liver viral titers. In contrast, despite considerably high viral loads on day 4 in the livers of most of the hamsters challenged with 1 PFU, the ALT levels were not elevated. We suspect that delayed seeding of the liver may have resulted in slower replication of RVFV in the low-dose (1 PFU) challenge group, thereby affecting the kinetics of hepatocellular damage and subsequent release of ALT into the circulation. In mouse RVFV infection models, substantial liver viral titers have been observed as early as day 2 p.i., yet increases in serum ALT levels lag behind by approximately 1 day [13,39,41].

Although infectious RVFV was present in many tissues, histopathology was restricted primarily to the liver and, to a lesser extent, the spleen. The mild increase in lymphocyte area and cellularity of the periarteriolar lymphoid sheath and lymphoid follicle of the spleen, in conjunction with the observed red and white pulp depletion, is similar to the pathology documented in the PTV hamster infection model wherein splenic necrosis involving both the red pulp and the lymphoid zone [76]. In contrast, PTV-infected C57BL/6 mice present with lesions that are more prominent in the white pulp [77]. RVFV infection in BALB/c mice displayed depletion of red pulp and lymphocyte apoptosis [13]. Although apoptotic bodies were visually identified, we did not perform a TUNEL assay or electron microscopy to confirm cellular apoptosis of the splenic white pulp.

The lack of RVFV antigen staining in tissues which contain high infectious viral loads and limited cellular damage, as observed in the spleen, could be due to a delay in the accumulation of detectable levels of antigen which may have reduced immunoreactivity due to masking by prolonged exposure to the formalin preservative. In the study by Smith et al., infectious RVFV was detected in the brain as early as day 3 p.i. yet antigen was not detected until day 6 p.i. and histological changes in the brain were not pronounced until day 8 p.i. [13]. A different study investigating chemotactic and inflammatory responses in mice reported that despite moderate amounts of necrotic debris observed in the spleen, viral antigen was not detectable in 20% of RVFV infected mice, and only very low level staining was observed in a small percentage of cells in the remaining 80% of the animals [41]. Additionally, in the related hamster PTV infection model, despite marked splenic necrosis, viral antigen was not detected [76].

Due to the inherent challenges of collecting samples from lethal cases of RVFV infection in remote regions of Africa and neighboring regions where the virus is endemic and medical infrastructure is often lacking, detailed description of RVF is limited. The development of non-

human primates (NHP) models of RVFV infection has facilitated investigations into the pathogenesis of the disease and the evaluation of potential antiviral therapies [3]. During severe infections in rhesus macaques, hemolytic anemia, extensive liver necrosis and possible disseminated intravascular coagulation (DIC) have been reported [49,50,93]. Despite limited histologic and IHC data, viremia, elevated serum ALT levels, and increased viral titers in the livers and spleens of fatally infected monkeys are consistent with our findings in RVFV-infected hamsters. Although both species develop significant lesions in the liver following RVFV challenge, the macaques exhibit a coagulative necrosis with cellular infiltrates not specifically observed in the hamster infection model [94]. Spleens from RVFV-infected rhesus macaque contained deposits of eosinophilic fibrin-like material in the red pulp of the spleen and a mild depletion of lymphocytes in the white pulp, similar to human infection, and our findings in hamsters infected with RVFV [93].

Although NHP models are considered the gold-standard when modeling RVF, they are cost-prohibitive and require special handling facilities. Thus, rodent models are better suited for initial stages of antiviral drug and vaccine development. Unlike NHP models, challenge of commonly used rodent species produces peracute disease and uniform lethality. The high mortality is favorable for antiviral and vaccine efficacy studies, but the often sublethal infection in NHPs is more representative of human infection wherein only a small percentage of those exposed progress to severe disease [10,95-97]. Table 1 provides a comparison of the principal RVFV infection animal models in terms of general aspects one may want to consider to assist in selecting the most appropriate model for their research needs. These are only generalized guidelines as many factors such as the route of infection, dose and strain of challenge virus, and the age and strain of the animal species can affect the outcome of RVFV infection and associated disease.



In summary, RVFV infection of hamsters most closely resembles the disease observed in mice, but with a more accelerated progression. Although rapid lethality makes for an abbreviated therapeutic window and translation to the human condition difficult, the uniform lethality via low-dose inoculation with an acute, fulminant hepatic disease makes the hamster RVFV infection model a cost-effective system for evaluating experimental vaccines and antivirals to demonstrate initial proof-of-concept. More specifically, the hamster model is most useful for the evaluation of host-targeted interventions that are not active in the mouse, but do cross-react with the orthologous target in hamsters [88]. In addition, the ability to reliably produce a delayed neurologic disease when treating RVFV infection with ribavirin may prove useful for future studies investigating the role of ribavirin in late-onset neuroinvasion and associated encephalitis and the evaluation of potential neuroprotective countermeasures [84]. Infection by low volume intranasal or aerosol exposure should be evaluated to determine whether neurologic disease is favored under such exposure conditions, as has been demonstrated in mice [98]. This challenge route is highly relevant in terms of biodefense, as it would mimic respiratory route exposure that could occur through intentional release, and would likely produce a slower-progressing disease model.

## CHAPTER 3

## FAVIPIRAVIR (T-705) EVALUATION STUDIES

**Introduction**

Favipiravir (T-705; 6-flouro-3-hydroxy-2-pyrazinecarboxamine) is a promising pyrazine derivative that has demonstrated potent antiviral activity against multiple RNA viruses [70]. Intracellular host enzymes act upon T-705 converting it to its active form, T-705-4-ribofuranosyl-5-triphosphate (T-705RTP) [71]. T-705RTP functions as a purine nucleotide analog that selectively inhibits RNA-dependent RNA polymerase (RdRp) of the influenza virus [99-101]. T-705 has demonstrated a 150-fold weaker inhibition of inosine monophosphate dehydrogenase than ribavirin, and unlike ribavirin it does not interfere with DNA or RNA synthesis. The specificity of T-705 likely contributes to its low toxicity. Recently, the compound has received approval as an influenza inhibitor in Japan ("AVIGAN®Tablet 200 mg") and is presently in clinical development in the United States (Phase 3 clinical trial).

T-705 has demonstrated robust activity against the MP-12 vaccine strain of RVFV in cell culture [40,74]. Additionally, the antiviral activity of T-705 *in vitro* against several other related bunyaviruses (several hantaviruses, La Crosse virus, and Punta Toro and sandfly fever phleboviruses) have been reported [40,72,73]. Punta Toro virus (PTV), a more accessible and less biohazardous agent (biosafety level 2; BSL-2) belonging to the same genus as RVFV, has been used to model severe RVFV infection in different animal models [75-77]. Consequently, initial studies evaluated the efficacy of T-705 in PTV infection models [40,74]. Based on promising results demonstrating T-705 inhibition of PTV infection in established rodent models and *in vitro* activity of the compound against the MP-12 strain of RVFV, we next investigated the efficacy of T-705 against our newly established s.c. ZH501 RVFV infection model in golden Syrian hamsters.

## **Materials and Methods**

### ***Virus and cells***

RVFV, strain ZH501, was obtained from Dr. Stuart Nichol (CDC, Atlanta, GA). The virus stock (1 passage in BSRT7 cells and 3 passages in Vero E6 cells) was derived from a clarified cell culture lysate and titrated to be at a concentration of  $1.1 \times 10^8$  plaque-forming units (PFU)/ml. The African green monkey kidney cell line, Vero 76, was purchased from the American Type Culture Collection (ATCC) (Manassas, VA) and maintained in minimal essential medium (MEM) supplemented with 10% heat-inactivated fetal bovine serum (FBS) (Thermo Fisher Scientific HyClone, Logan, UT). For *in vitro* antiviral assays, the serum was reduced to 2% FBS and gentamicin (Sigma-Aldrich, St. Louis, MO) was added to the medium to a final concentration of 50 µg/ml.

### ***Compounds***

T-705 was provided by the Toyama Chemical Company, Ltd. (Toyama, Japan). Ribavirin was from ICN Pharmaceuticals, Inc. (Costa Mesa, CA). For *in vivo* studies, both compounds were suspended in 0.4% carboxymethylcellulose (CMC) (Sigma-Aldrich, St. Louis, MO) prior to administration. For cell culture testing, T-705 and ribavirin were dissolved in MEM containing 50 µg/mL gentamicin.

### ***In vitro antiviral testing***

RVFV was titrated on Vero 76 cells (~80% confluent) plated in 96-well microplates in culture medium containing 2% FBS to a cell culture infectious dose (CCID) that produced maximal cytopathic effects (CPE) in 3 days. Half-log dilutions of T-705 and ribavirin were added in triplicate to test wells at the time of infection with the highest test compound concentration of 1000 µM. For toxicity determinations, drugs were added in the prior to virus challenge.

Plates were incubated at 37°C and 5% CO<sub>2</sub> until virus-infected control wells were observed to have > 90% CPE (day 3). The neutral red (NR) assay was performed using a modified method of Cavanaugh et al. [102] as described [103]. Briefly, the supernatants were removed for virus yield reduction (VYR) assays and infected cells and controls were subsequently stained with 0.011% NR solution for 2 h at 37°C and 5% CO<sub>2</sub>. After incubation, the NR solution was removed, the wells were rinsed with phosphate-buffered saline (PBS), and the incorporated dye extracted using ethanol buffered with Sorenson's citrate. The plates were read at 405 (primary) and 540 (reference) nanometer wavelengths using a Opsys MR<sup>TM</sup> microplate reader (Dynex Technologies, Chantilly, VA) to quantitate the extracted NR. The absorbance values were expressed as percentages of untreated, uninfected controls, which took up maximal dye. The values obtained were converted to percentages of untreated, uninfected controls. The 50% cell cytotoxic dose (CC<sub>50</sub>) and 50% effective concentration (EC<sub>50</sub>), representing the concentration at which 50% of the monolayers would show compound cytotoxicity or viral CPE, respectively, were estimated by regression analysis. The selectivity index (SI) was calculated using the formula:  $SI = CC_{50}/EC_{50}$ . For the VYR assays, viral titers were determined by endpoint dilution [92]. The VYR data are presented as the concentration of drug that reduced the virus yield by 1 log<sub>10</sub> unit (EC<sub>90</sub>) based on linear regression analysis, with SI values determined as the  $CC_{50}/EC_{90}$ .

### ***Animals and ethics regulation***

Female 90-115 g golden Syrian hamsters (The Charles River Laboratory, Willimantic, CT) were quarantined for 7 days prior to challenge and fed standard Harlan lab block and tap water *ad libitum*. All animal procedures complied with USDA guidelines and were conducted at the AAALAC-accredited Laboratory Animal Research Center at Utah State University under protocol 1502, approved by the Utah State University Animal Care and Use Committee.

***T-705 Dosing optimization for RVFV treatment***

To determine the most appropriate dose for subsequent efficacy studies, hamsters (n=15/group) were challenged by subcutaneous (s.c.) injection (ventral, right side of the abdomen) with a 0.1 ml inoculum containing 30 PFU of RVFV and varying doses of oral (p.o.) T-705 were evaluated for efficacy. Treatments, including 75 mg/kg/day of ribavirin (positive control) or 0.4% CMC placebo, were initiated 1 h post-infection (hpi) and administered twice daily for 10 days. Five animals from each treatment group were designated for sacrifice on day 3 of infection for analysis of serum, liver and spleen viral titers. The remaining animals were observed 28 days for morbidity and mortality. Sham-infected normal animals were included as baseline controls for morbidity and mortality (n=3), and virus titer assays (n=3). Serum, brain, liver and spleen samples were collected from two moribund animals with late-onset encephalitic disease for viral titer determination and histopathology.

***Extended post RVFV exposure T-705 efficacy study***

Since hamsters begin to succumb to s.c. RVFV challenge within 48 h, we performed a follow-up experiment wherein treatments with the effective dose of T-705 were initiated 1, 6, and 24 hpi. Hamsters (n=14 each for treatment and placebo groups) challenged with 30 PFU of RVFV were dosed orally, twice daily for 14 days, with T-705 (200 mg/kg/day), ribavirin (75 mg/kg/day), or placebo starting 1, 6 or 24 hpi. Four animals from each treatment group were sacrificed on day 2 of infection for analysis of viral titers. The remaining animals were observed 28 days for morbidity and mortality. Sham-infected normal animals were included as baseline controls for survival (n=3) and virus titers (n=3). As done in the first study, serum, brain, liver and spleen samples were collected from several moribund animals with late-onset encephalitic disease for viral titer determination and histopathology.

### ***Combined post-exposure treatment of RVFV Infection with T-705 and ribavirin***

The combined antiviral effects of T-705 and ribavirin were evaluated based on differences in their protective effects observed in the monotherapy studies. Hamsters (n=14 for treatment groups, n=24 for placebo group) were challenged s.c. with 30 PFU of RVFV and T-705, ribavirin and placebo were dosed separately or in combination, as described in Table 1, starting 24 hpi. Four animals from each treatment group were sacrificed on day 2 of infection for analysis of viral titers. The remaining animals were observed 28 days for morbidity and mortality. Sham-infected controls were included for comparison.

### ***Serum, liver, spleen and brain virus titers***

Virus titers were assayed using an infectious cell culture assay as previously described [39]. Briefly, a specific volume of tissue homogenate or serum was serially diluted and added to triplicate wells of Vero 76 cell monolayers in 96-well microtiter plates. The viral CPE was determined 7 days after plating and the 50% endpoints were calculated as described [92]. The lower limits of detection for virus titers were  $1.49 \log_{10}$  CCID<sub>50</sub>/ml serum and  $1.97 \log_{10}$  CCID<sub>50</sub>/g of tissue, respectively.

### ***Histopathology***

Several moribund animals were discovered between days 7-14 of the dose optimization and post-exposure T-705 efficacy study. These animals were sacrificed for determination of serum, liver, spleen and brain virus titers. In parallel, sections from these tissues preserved in 10% neutral buffered formalin were sent to the Utah Veterinary Diagnostic Laboratory (Logan, UT) for blinded histopathology examination and analysis by a board certified veterinary pathologist.

### ***Immunohistochemical staining***

Based on viral burden in the tissues and histopathology review, replicate tissue sections from euthanized moribund animals were processed for immunohistochemical (IHC) staining, as described previously (Chapter 2, Materials and Methods).

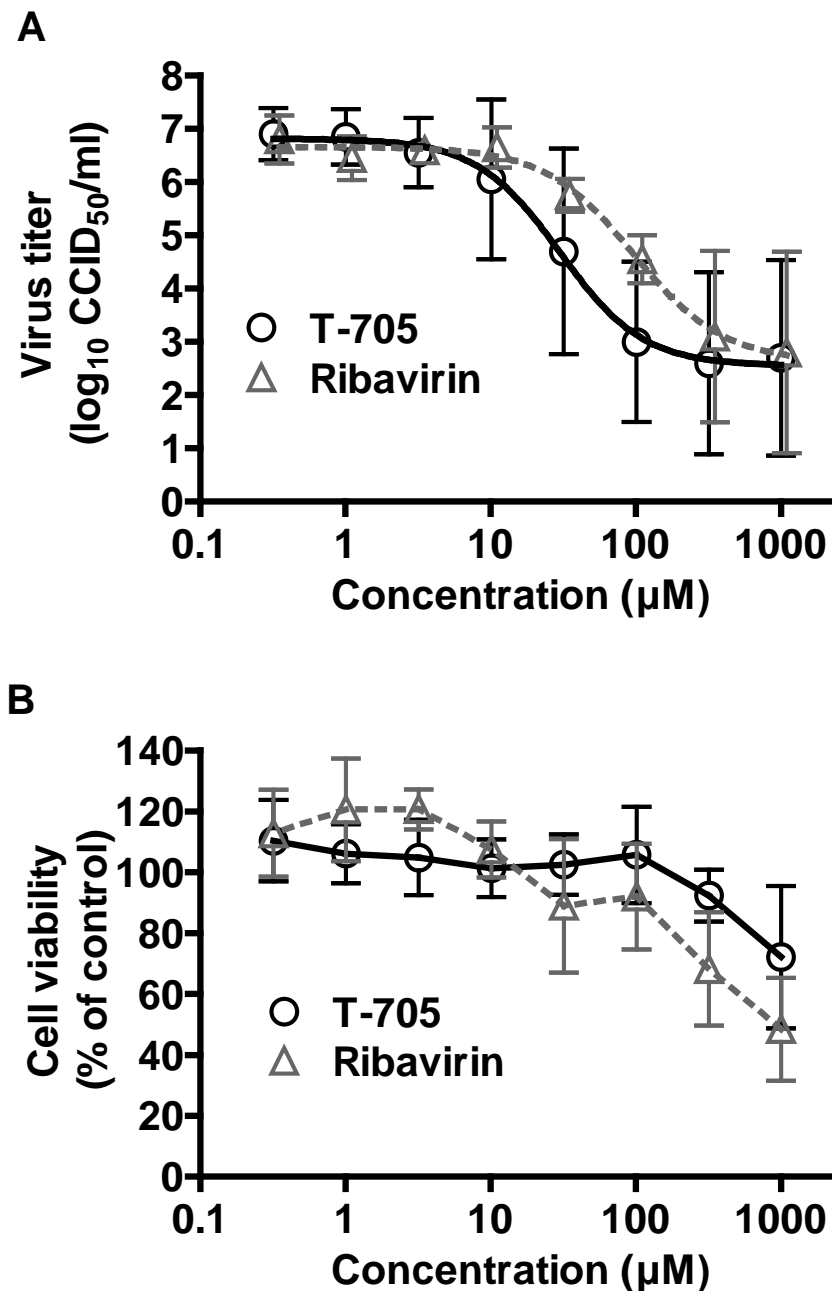
### ***Statistical analysis***

The Mantel-Cox log-rank test was used for analysis of Kaplan-Meier survival curves. A one-way analysis of variance (ANOVA) with a Newman-Keuls posttest was performed to compare differences in viral loads. All statistical evaluations were done using Prism (GraphPad Software, La Jolla, CA).

## **Results**

### ***In vitro antiviral activity of T-705 against the ZH501 strain of RVFV***

The antiviral activity of T-705 was first evaluated in cell culture against the highly virulent ZH501 strain of RVFV, and ribavirin was included as a positive control for comparison. The  $CC_{50}$  was  $>1000 \mu\text{M}$  for both compounds. The inhibitory activity ( $EC_{50}$ ) against RVFV was  $31 \mu\text{M} \pm 18$  for T-705 and  $53 \mu\text{M} \pm 22$  for ribavirin by NR CPE reduction assay, with SI values of  $>32$  and  $>19$ , respectively. The antiviral activity of T-705 was confirmed by measuring reduction in virus yield (Figure 6) by endpoint titration of the day 3 post-infection culture supernatants. The  $EC_{90}$  of T-705 was  $11 \pm 27 \mu\text{M}$  and ribavirin's was  $12 \pm 9 \mu\text{M}$  (SI  $>91$  and  $>83$ , respectively), consistent with the activity detected by the NR uptake assay. The data is consistent with the previously observed T-705 activity against the MP-12 strain of RVFV [40,74].



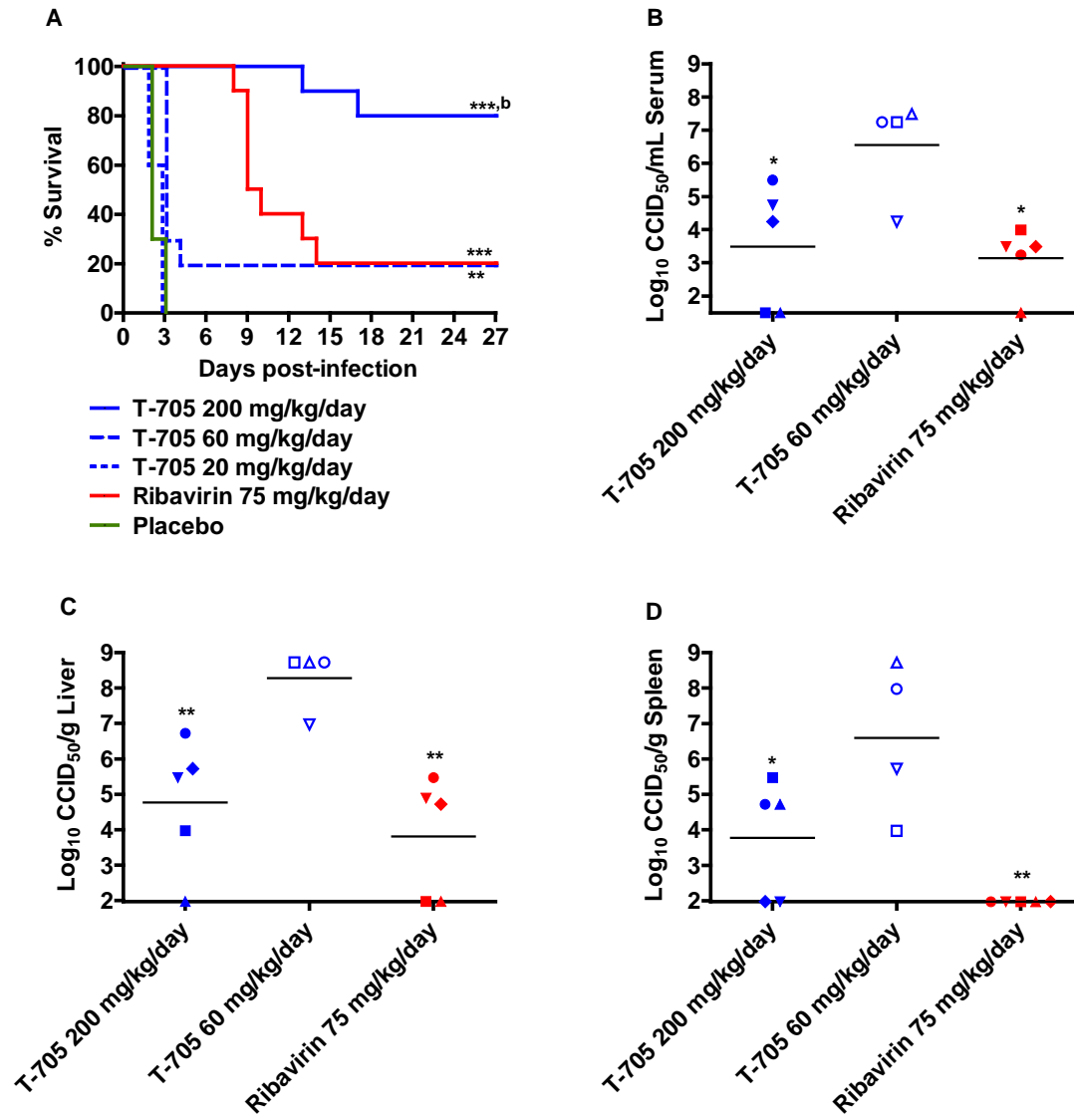
**Figure 6.** *In vitro* activity of T-705 against the ZH501 strain of RVFV. Vero 76 cell cultures were infected with RVFV, treated with various concentrations of T-705 or ribavirin, and A) the inhibition of viral replication was determined by endpoint titration of the culture supernatants. B) Cytotoxicity of the compounds was determined by neutral red dye uptake to measure cell viability in cultures of uninfected cells treated in parallel. Cytotoxicity data represent the percent cell viability after a 3-day incubation compared to untreated controls. The data are representative of 3 independent experiments and reflect the mean and standard deviations from triplicate samples.



### ***In vivo dose optimization of T-705***

We next evaluated the antiviral activity of T-705 in hamsters challenged with the ZH501 strain of RVFV. In the initial study, we assessed oral treatments of 200, 60, and 20 mg/kg/day of T-705 administered starting 1 h post s.c. RVFV infection, dosing twice-daily for a duration of 10 days. Ribavirin, previously shown to have activity against RVFV infection [104], was included for comparison. As shown in Figure 7A, treatment with 200 mg/kg/day T-705 was the most efficacious regimen, protecting 80% of the challenged animals from mortality. This dose of T-705 was significantly better than the ribavirin treatment (75 mg/kg/day), which only resulted in 20% survival. All the animals in the placebo and 20 mg/kg/day T-705 treatment groups succumbed to infection by day 3. A slight protective effect was observed at a dose of 60 mg/kg/day of T-705, with 20% survival and a slight delay in the mean day of death by approximately 1 day.

The effect of drug treatments on reducing viral titers was evaluated on day 3 in hamsters infected and treated in parallel to those observed for mortality. Due to the peracute lethality of the RVFV challenge in hamsters, one animal in the 60 mg/kg/day T-705 group, and all animals in the low-dose T-705 and placebo-treated groups, expired prior to the time of sacrifice. Viral titers in the sera, livers, and spleens of hamsters treated with 200 mg/kg/day T-705 were significantly reduced when compared to titers in hamsters treated with 60 mg/kg/day T-705 ( $P < 0.05$ ) (Figure 7B-D). Ribavirin had a similar effect on viral titers as the 200 mg/kg/day T-705 treatment. Although no virus was detected in the spleens of any RVFV-challenged hamsters treated with ribavirin, the difference was not significant compared to the high-dose T-705 group (Figure 7D).



**Figure 7. T-705 post-RVSV exposure treatment protects hamsters from lethal disease.**

Hamsters challenged s.c. with 30 PFU of RVSV-ZH501 received the indicated doses of T-705, ribavirin, or placebo (p.o., twice daily) beginning 1 h post-infection. A) Survival outcome and day 3 B) serum, C) liver, and D) spleen virus titers from animals infected and treated in parallel are shown. All animals from the 20 mg/kg/day T-705 and placebo treatment groups, and one hamster from the 60 mg/kg/day T-705 treatment group, succumbed prior to sacrifice. Unique symbols in each treatment group represent values for the same animal in B-D. For percent survival, \*\* $P < 0.01$  and \*\*\* $P < 0.001$  compared to placebo; <sup>b</sup> $P < 0.01$  compared to animals treated with ribavirin. For viral titers, \* $P < 0.05$  and \*\* $P < 0.01$  compared to animals treated with 60 mg/kg/day T-705.

In addition to the day 3 virus titer data, two animals in the ribavirin-treated group were found in a moribund state on day 9 post-infection and sacrificed for analysis of serum, liver, spleen, and brain virus titers, and histopathology. Remarkably, there was no virus present in the serum, liver, or spleen; however, approximately  $8.6 \log_{10}$  CCID<sub>50</sub>/g of tissue was present in the brains of both animals (Figure 8A), indicating that these animals were deteriorating due to virus replication in the brain and the associated late-onset encephalitis. This was corroborated by histopathologic analysis which revealed neutrophilic and lymphocytic meningoencephalitis of variable severity in the brains of both animals (Figure 8B, C).

#### ***Extended T-705 post-exposure efficacy***

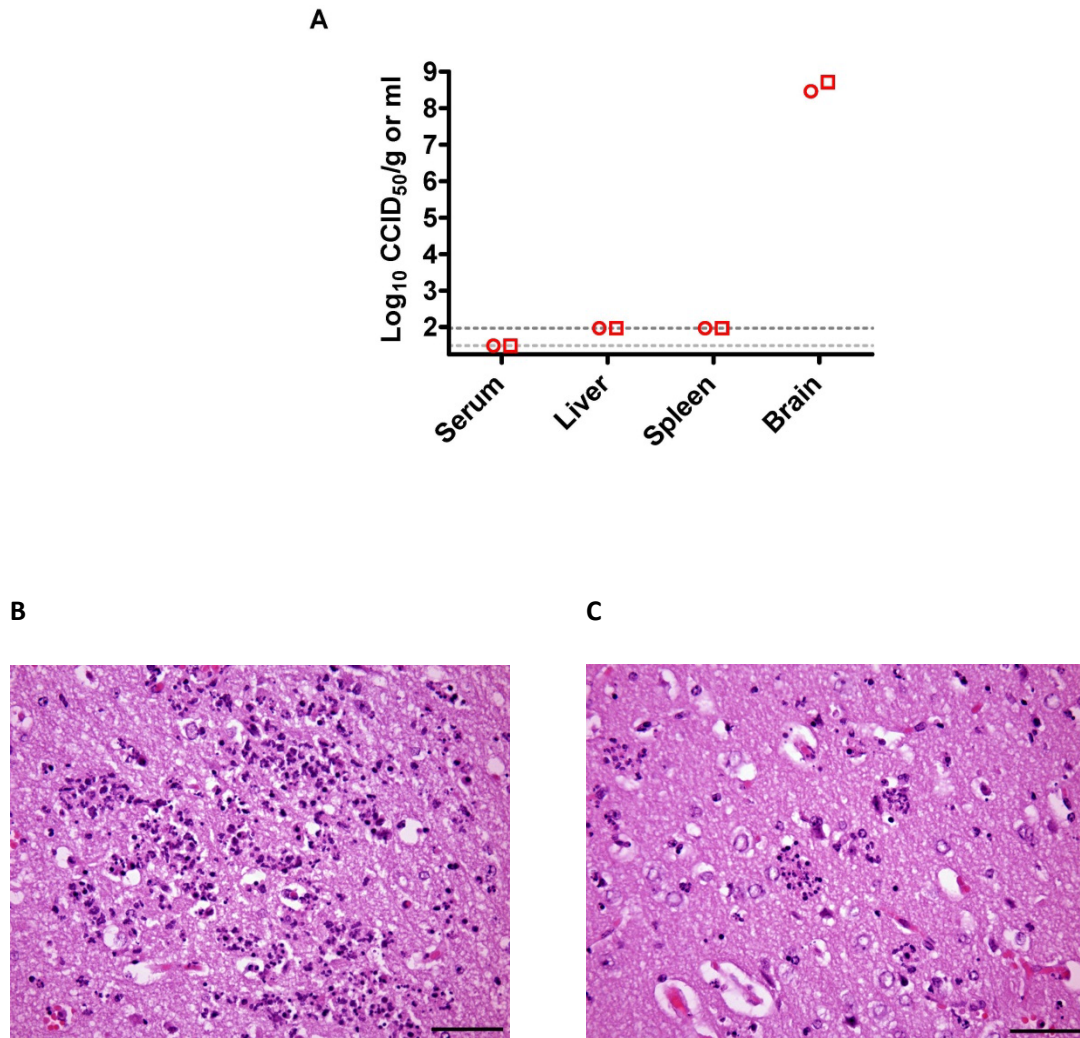
Because most hamsters succumb to RVFV challenge within 48 hpi, we next evaluated the efficacy of the twice-daily 200 mg/kg/day T-705 treatments when delayed until 1, 6, and 24 h post s.c. RVFV infection. As in the initial experiment, animals receiving high-dose T-705 treatments initiated 1 hpi fared significantly better compared to the ribavirin-treated animals ( $P < 0.001$ ; 70% vs. 10% survival), which survived the acute infection but ultimately succumbed to a late-onset neurologic disease (Figure 9A). T-705 treatment initiated at 6 hpi also demonstrated significant protection from mortality (60% overall survival), with 3 of the 10 animals succumbing from acute systemic infection, and a 4<sup>th</sup> from late-onset encephalitic disease. Interestingly, ribavirin treatment delayed until 24 hpi performed similarly to treatments initiated at 1 or 6 hpi, suggesting combination therapy with T-705 starting as late as one day after challenge may be an effective strategy for the peracute RVFV hamster infection.

The effect of treatments on reducing viral titers on day 2 post-infection is shown in Figure 9B-D; however, many of the placebo animals ultimately expired prior to sacrifice, thereby limiting statistical comparison. T-705 administered at 1 hpi was very effective at limiting viral replication as demonstrated by low or undetectable serum, liver, and spleen viral titers. Most of

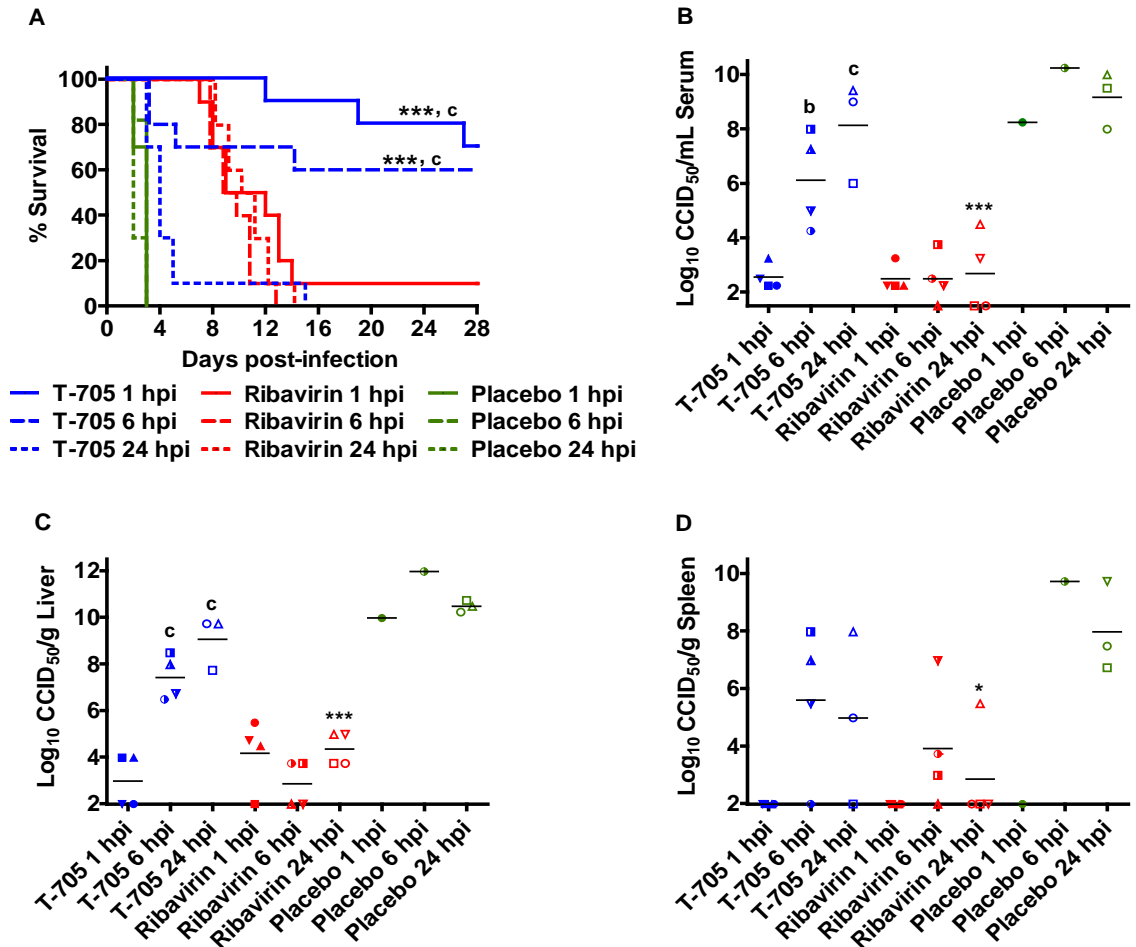
the animals in the 6 hpi T-705 group had titers considerably higher than the 1 hpi T-705-treated animals, which was remarkable considering 6 out of 10 animals in the observational group survived the challenge, and suggests even a slight reduction in titers or a delay in viral replication may be an important factor for a favorable outcome. In general, a trend of diminished viral titers was observed in the 6 and 24 hpi T-705-treated animals compared to the few placebo animals that could be included in the analysis. Consistent with survival data where ribavirin prevented death due to acute infection, ribavirin-treated animals had the lowest titers at the 6 and 24 hpi treatment groups (Figure 9B-D).

In addition to the day 2 virus titer data, four animals from the ribavirin-treated groups and one animal in the T-705 24 hpi group were found in a moribund state after the first week of the study (day 7-14). These animals were sacrificed for determination of serum, liver, spleen, and brain virus titers, and histopathology. Consistent with the previous experiment and the transition from a systemic hemorrhagic disease to a viral encephalitis disease in mice [13], there was no virus present in the serum or spleen and only one animal from the T-705 24 hpi group had detectable virus in the liver ( $5.97 \log_{10} \text{CCID}_{50}/\text{g}$ ; data not shown), whereas analysis of brain tissue revealed viral loads between  $7.72\text{-}9.47 \log_{10} \text{CCID}_{50}/\text{g}$  in all moribund animals (Figure 10A).

Similar to the observations of the previous study, histopathologic analysis of tissues from the moribund animals suggests that the deterioration of the animals was likely due to a neutrophilic and lymphocytic meningoencephalitis of variable severity (Figure 10B-E). Minimal to no lesions of hepatitis were present in most animals (data not shown). Collectively, the histopathology data is consistent with the notion that death of animals beyond day 7 is primarily due to RVFV replication in the brain. Central nervous system (CNS) infection and associated



**Figure 8. Sub-acute central nervous system RVFV infection in ribavirin-treated animals that survive the acute disease.** Hamsters were treated as described in Figure 7. Two animals in the ribavirin-treated group were found to be moribund on day 9 post-infection and were sacrificed for analysis of serum, liver, spleen, and brain virus titers, and histopathology. A) Analysis of viral titers in moribund RVFV-infected hamsters treated with ribavirin. Histopathologic findings in the cerebrum display B) multifocal neuronal necrosis and neuronophagia and C) neuropil necrosis. H&E staining, 400X, bars = 20  $\mu$ m.



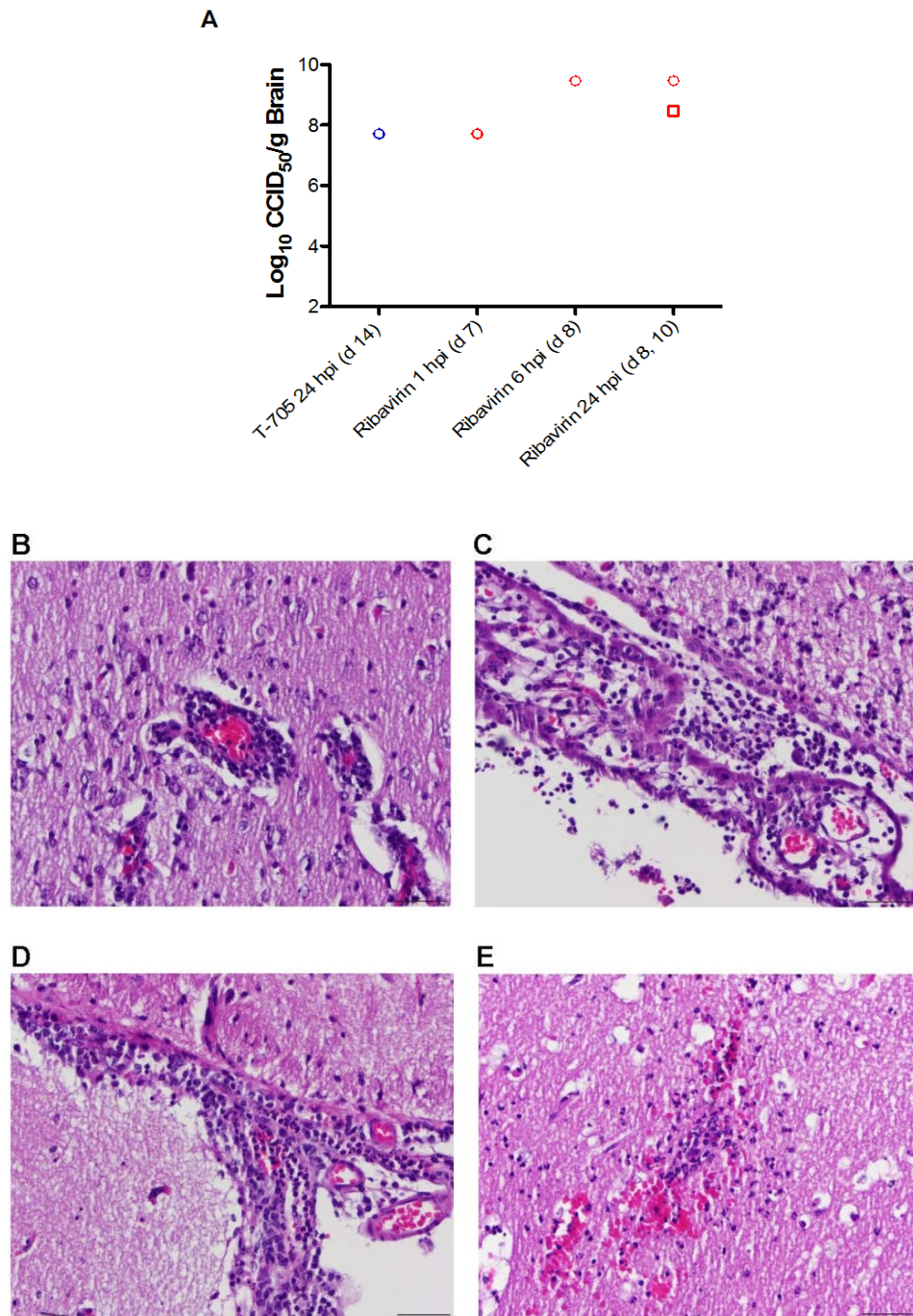
**Figure 9. T-705 intervention is effective out to 6 h post-RVSV exposure.** Hamsters were treated with T-705 (200 mg/kg/day), ribavirin (75 mg/kg/day), or placebo, twice-daily p.o. for 14 days beginning 1, 6 or 24 h post-infection (hpi). A) Percent survival and day 2 B) serum, C) liver, and D) spleen virus titers are shown. Five animals from varying placebo groups and one animal from the T-705 24 hpi group succumbed prior to sacrifice. Unique symbols in each treatment group represent values for the same animal in B-D. \* $P < 0.05$  and \*\*\* $P < 0.001$  compared to respective placebo groups; <sup>b</sup> $P < 0.01$  and <sup>c</sup> $P < 0.001$  compared to animals treated with ribavirin.

disease was likely the cause of death in the 29 ribavirin-treated animals that succumbed to the RVFV challenge.

### ***T-705 and ribavirin combination treatment of RVFV infection***

Although ribavirin effectively protected hamsters from the acute disease when initiated 24 hpi, most succumbed from late-developing brain infection and disease. Considering ribavirin's capacity to provide protection against lethality due to acute disease even when treatment is delayed until 24 hpi, and the encouraging efficacy of T-705 when given early during infection, we evaluated the two compounds as a combination therapy in an effort to provide optimal protection in hamsters challenged with RVFV. Several T-705 and ribavirin regimens (Table 2) were tested with treatment initiated at 24 hpi. Because ribavirin treatment courses commonly employ a "loading dose" strategy [68,105], we designed the combination study with this consideration in mind. In addition, a lower dose of ribavirin was also evaluated to address concerns with toxicity [106], since effectively reducing the dose requirement would greatly benefit patients.

As shown in Figure 11A, all combination treatments resulted in significant benefit compared to either drug alone. Treatments for G2 and G3 were the most effective, providing a 40% protection, whereas the treatment for G1 resulted in only 10% survival. Although G1 received the highest effective concentration of both compounds, the G2 and G3 treatments (Table 2) appeared to be superior in that there were ultimately more survivors. Notably, the combination treatment groups were the only ones to have any survivors, as all but one animal (which ultimately succumbed on day 23) from the individual drug treatment groups expired by day 11. Overall, the G2 and G3 combination therapy groups trended towards hamsters surviving longer than the ribavirin 40 mg/kg/day monotherapy.



**Figure 10. Analysis of brain viral titers in moribund RVFV-infected hamsters treated with T-705 or ribavirin.** Hamsters were treated as described in Figure 7. Five animals were discovered moribund and euthanized on the indicated day (d) post-infection for analysis of virus titers and histopathology. A) Brain viral titers in moribund RVFV-infected hamsters treated with T-705 (blue symbol) or ribavirin (red symbols). Histopathologic analysis of cerebrums displayed B) perivascular mixed inflammatory cell infiltration, C) neutrophilic choroiditis and ventriculitis, D) neutrophilic meningitis and E) neuropil vasculitis and hemorrhage. H&E staining, 400X, bars = 50  $\mu$ m.



The effect of the drug combinations on reducing viral titers on day 2 post-infection is shown in Figure 11B-D. Consistent with the survival data, a general trend of diminished viral titers was observed in all of the T-705 and ribavirin combination treatment regimens. The G2 combination treatment appeared to be the most effective at reducing viral titers in the serum, liver and spleen when compared to the T-705 monotherapy and placebo treated groups, but it was not significantly better than the ribavirin monotherapy. Collectively, the data indicates that combined oral treatment of T-705 and ribavirin significantly enhance post-exposure efficacy compared to monotherapy with either drug, but the challenge of preventing late-onset encephalitis is still problematic when treatment is postponed until 24 h after RVFV challenge.

#### ***IHC analysis of moribund T-705- and ribavirin-treated animals***

From several experiments wherein several animals receiving T-705 or ribavirin treatment succumbed to CNS infection and associated disease in the absence of detectable levels of infectious virus in serum or liver and spleen samples, we performed IHC analysis on the collected tissues. Collectively, histological examination of the brains from various moribund animals between days 7-13 p.i. showed acute multifocal random necrotizing neutrophilic and lymphocytic meningoencephalitis with neuronal necrosis, neuronophagia and vasculitis (Figure 12A). IHC staining these same sections, revealed multifocally, neurons adjacent to areas with neuronophagia displaying diffuse cytoplasmic immunoreactivity for RVFV antigen (Figure 12B).

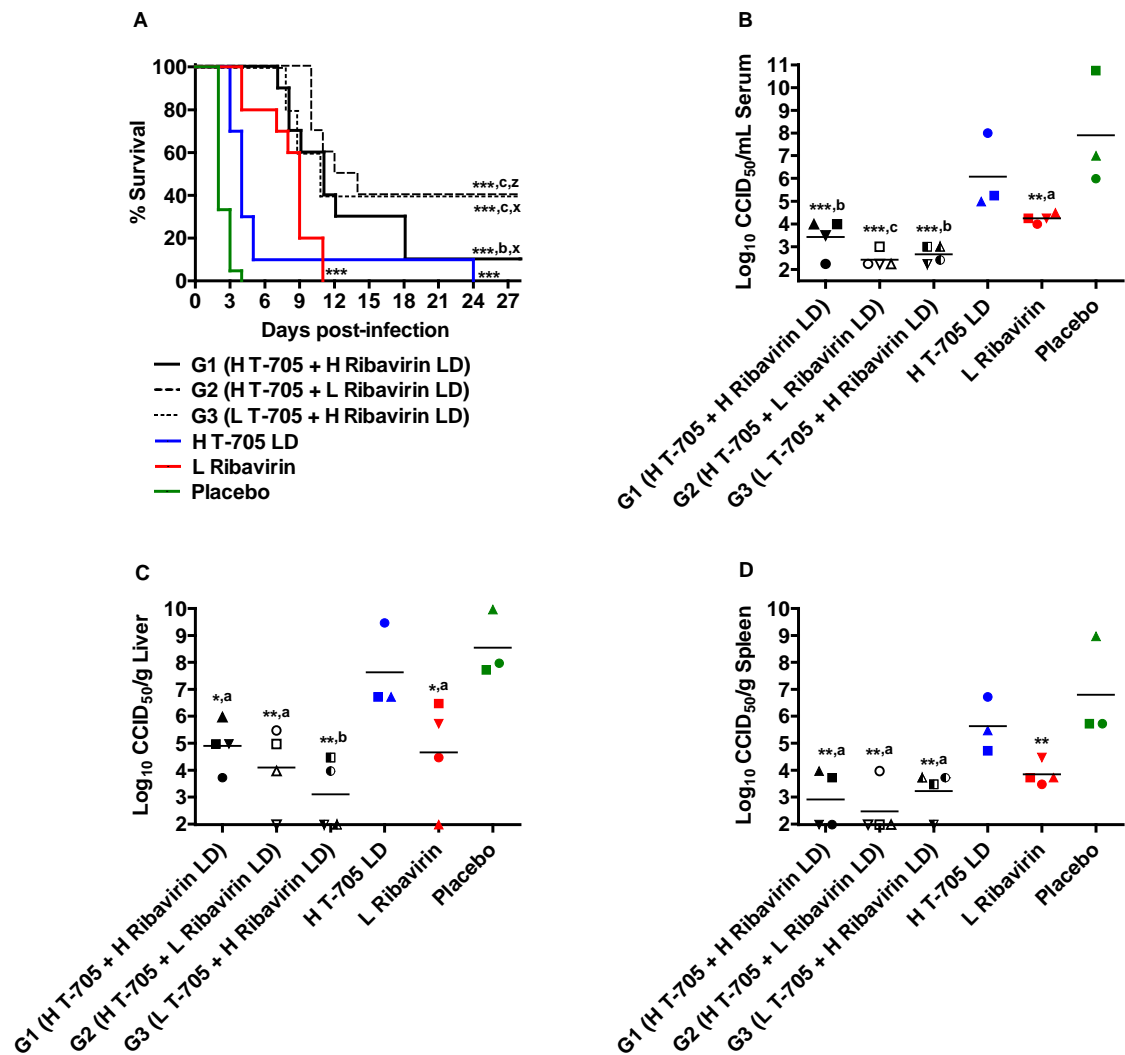
Comparing the morphologic changes over the course of infection, we noted some interesting developments in the livers and spleens from the ribavirin-treated moribund animals. Concerning the spleen, despite the increase in lymphocyte area observed on days 3 and 4 p.i., the examined tissues (days 7-13) all showed granulopoiesis (extramedullary hematopoiesis) in the spleen with an increase in circulating neutrophils in the liver sinusoids, suggesting that these

Table 2. Post-exposure T-705 plus ribavirin combination treatment regimens.

Group	Compounds	High/Low Dose <sup>a</sup>	Dosage (mg/kg/day) <sup>b</sup>		
			Day 1	Day 2	Days 3-10
G1	T-705	H	200	200	200
	Ribavirin	H (LD)	75	37.5	-
G2	T-705	H	200	200	200
	Ribavirin	L (LD)	40	20	-
G3	T-705	L	100	100	100
	Ribavirin	H (LD)	75	37.5	-
G4	T-705	-	-	-	-
	Ribavirin	L	40	40	40
G5	T-705	H (LD)	400	200	200
	Ribavirin	-	-	-	-
G6	Placebo	-	-	-	-
	Placebo	-	-	-	-

<sup>a</sup>H = high, L = low, LD = loading dose.

<sup>b</sup>Hamsters were treated p.o., twice per day, beginning 24 h post-infection.



**Figure 11. Combined T-705 and ribavirin therapies significantly improve survival outcome and reduce viral burden when starting treatment 24 h post-RVFP challenge.** Hamsters were treated p.o. with T-705, ribavirin, or a combination of both compounds starting 24 h post-infection (see Table 2 for detailed description of the treatment regimens). A) Percent survival and day 2 B) serum, C) liver, and D) spleen virus titers are shown. One animal each in the T-705 monotherapy and placebo-treated group succumbed prior to sacrifice on day 2. Unique symbols in each treatment group represent values for the same animal for B-D. \* $P < 0.05$ , \*\* $P < 0.01$ , and \*\*\* $P < 0.001$  compared to placebo-treated animals; <sup>a</sup> $P < 0.05$ , <sup>b</sup> $P < 0.01$ , <sup>c</sup> $P < 0.001$  compared to animals receiving T-705 monotherapy; <sup>x</sup> $P < 0.05$ , <sup>z</sup> $P < 0.001$  compared to hamsters treated only with ribavirin. H (high dose), L (low dose), LD (loading dose).

hamsters had neutrophilia. Diffusely, there was moderate depletion of the red and white pulps, moderate to marked lymphoid depletion of the marginal zones and lymphoid follicles, and to a lesser extent the periarteriolar lymphoid sheaths. Examination of the liver showed minimal-to-no lesions of hepatitis in half of the animals. Moreover, one of the animals displayed an undulated liver capsular surface, increased number of bi/trinucleated hepatocytes, and the mild biliary hyperplasia/ductular reaction with prominent oval cell in the canal of Hering suggesting that the hepatic progenitor cell compartment was activated and that hepatic regeneration may have occurred (data not shown).

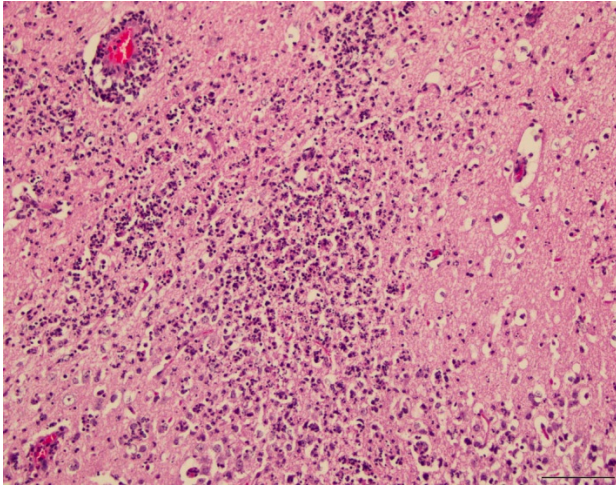
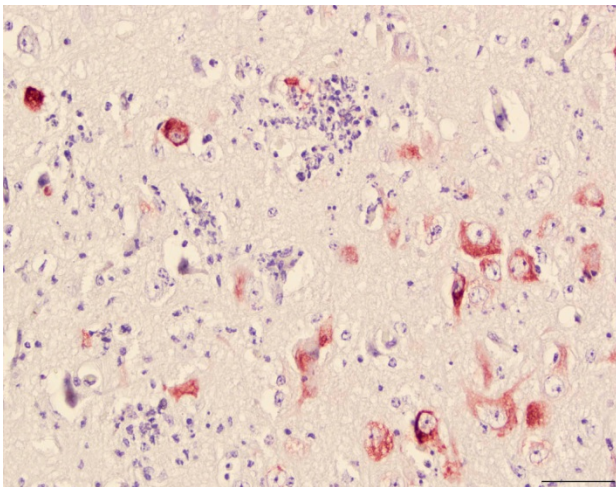
### **Discussion**

The present study demonstrates for the first time the antiviral activity of T-705 against pathogenic RVFV infection. Despite similar inhibitory concentrations in the cell culture experiments, T-705 was superior to ribavirin in terms of overall survival and preventing late-onset CNS infection in RVFV-infected hamsters. The liver is the principal target with severe hepatic disease the likely cause of death during the acute infection with a delayed-onset encephalitic disease developing after the first week [13,44]. Hamsters generally succumb within 2-3 days from acute disease, whereas mortality in mice occurs during the first 3-6 days [2]. While both species are highly susceptible to RVFV, neither reproduces the hemorrhagic fever or ocular disease observed in human cases. The rapid progression of disease in hamsters presents challenges in terms of the abbreviated therapeutic window; however, the model is very useful for evaluating experimental therapies in the context of post-exposure intervention and to demonstrate proof-of-concept in a robust small animal model.

It is possible that doses higher than 200 mg/kg/day of T-705 may have achieved complete protection against lethal RVFV challenge in hamsters. The present dose of 200 mg/kg/day is equivalent to a human dose of 27 mg/kg/day based on body surface area

conversion [107]. In the Phase 2 clinical trial evaluating T-705 as an anti-influenza drug, the high dose arm consisted of 2400 mg on day 1 and 1600 mg on days 2-5. Assuming the average weight of the participants was 60 kg, the dosages received were in the range of 40 and 27 respectively. Although a 400 mg/kg/day loading dose with subsequent transition to 200 mg/kg/day was evaluated in the third study, the therapeutic window for T-705 in the hamster model appears not to extend much further than beyond 6 h. Considering the excellent tolerability of T-705 in hamsters ( $LD_{50} > 1500$  mg/kg/day) [40], and the severity of the RVFV infection, it may be worthwhile to explore higher daily doses administered three times per day to obtain more consistent therapeutic levels systemically and in tissues.

One of the more remarkable findings from our studies was that although both ribavirin and T-705 had dramatic antiviral effects on RVFV-infected hamsters, their effects on survival were very distinct. T-705 was more effective in terms of protecting the animals from both acute and late-onset CNS disease, but the window for successful post-exposure intervention was limited to approximately 6 h. In contrast, ribavirin was highly effective at protecting all animals from the rapidly overwhelming effects of the acute infection, even when delaying treatment until 24 hpi, whereas only a slight beneficial effect could be observed with T-705 treatments. However, almost all ribavirin-treated animals ultimately succumbed to CNS infection and associated disease in the absence of detectable levels of virus in serum or liver and spleen samples. This may be explained by the inability of ribavirin or its active metabolites to effectively cross the blood-brain barrier [108]. These findings are consistent with a well characterized mouse RVFV infection model wherein late-onset neuroinvasion and encephalitis was described in animals succumbing during the latter part of the infection [13]. This secondary disease observed in hamsters could serve as a model for human cases of delayed-onset encephalitis that occur weeks to months after acute RVFV infection [2].

**A****B**

**Figure 12. Immunohistochemistry analysis of brain tissues from RVFV-infected hamsters demonstrates presence of viral antigen.** A) Hamster brain section from sham-infected control animal showing normal cells, 400X, bar = 30  $\mu\text{m}$ . Brain tissue from a ribavirin treated moribund hamster at day 13 p.i. with RVFV demonstrating B) Acute neutrophilic encephalitis with necrosis and vasculitis, 200X, bar = 100  $\mu\text{m}$ , H & E stain, and C) Immunohistochemistry staining for RVFV. Multiple neurons surrounding foci of neutrophilic inflammation and necrosis show diffuse cytoplasmic immunoreactivity for RVFV antigen. 400X, bar = 50  $\mu\text{m}$ . NovaRed stain with hematoxylin counterstain.

It is unclear why ribavirin is so effective at controlling viral replication and abrogating disease when initiating treatment at an advanced time point (24 hpi) in the peracute infection. Ribavirin may achieve higher concentrations and activation in the primary lymphatic tissues where the virus is likely to initially replicate before seeding the blood and secondary target organs including the liver. We can only speculate as to why T-705 is able to prevent CNS infection, but has a narrower window for intervention. The complexities with the biodistribution of the parent T-705 compound, the efficiency of its intracellular conversion to the active ribofuranosyl triphosphate in various cell types and tissues, and the rate of elimination all probably influence the observed efficacy and the shorter window for effective intervention. T-705 is likely to specifically target the RVFV polymerase directly affecting the virus life cycle by inhibiting viral transcription and replication, whereas ribavirin has multiple modes of action and may prevent RVFV lethality through later acting cumulative effects from depletion of ribonucleotide pools [67].

Our findings evaluating T-705 and ribavirin as monotherapies provided the rationale for combining the two antivirals with the goal of integrating the beneficial aspects of each independent treatment to extend the therapeutic window to 24 hpi. The results of the drug combination study indicated oral treatment with T-705 and ribavirin significantly enhanced post-exposure efficacy suggestive of synergy, as demonstrated by protection (up to 40% survival) against both the acute hepatic and late-onset encephalitic disease that would otherwise result in death in animals treated with either drug alone. Despite this success, the challenge of preventing late-onset encephalitis when treatment is postponed until 24 h after RVFV infection in hamsters is still largely unmet. Interestingly, our findings hint that the highest dose combination of T-705 and ribavirin was not necessarily optimal (only 10% survival), as treatments where the dose of one of the drugs was lowered resulted in improved (40%) survival

outcomes. A comprehensive drug combination matrix would be needed to clearly demonstrate possible antagonism at higher doses, as well as synergy with suboptimal dosing regimens of T-705 and ribavirin.

In summary, post-RVFPV exposure treatment of hamsters with T-705 within 6 hpi, or T-705 + ribavirin combination therapy within 24 hpi, significantly improved survival outcome and reduced viral loads in serum and tissues. In fatal cases of RVF, severe hemorrhagic disease manifestations typically lead to death within 3-6 days of the onset of clinical signs of illness [2]. Because hamsters succumb to the acute phase of the infection within a day of displaying initial clinical signs (lethargy, hunched posture, and ruffled fur), it is difficult to extrapolate to the human disease. However, considering the rapid progression and lethality of RVFPV infection and disease modeled in hamsters, the data presented are certainly encouraging. In view of the failure of ribavirin to prevent CNS infection in mice challenged through the upper respiratory tract [98], future studies investigating the efficacy of T-705 against aerosol exposure in rodents is warranted. Ultimately, investigational new drug-enabling efficacy studies in a nonhuman primate model of RVF will be required for advancing the compound towards clinical evaluation.



## CHAPTER 4

### CONCLUSIONS AND FUTURE DIRECTIONS

Rift Valley fever illness typically manifests as an acute febrile and hepatic disease in ruminant species and humans. The need to better understand the more severe manifestations of RVF disease has led to the establishment of various animal models to study the pathogenesis of RVFV infection [3,49]. Hamsters are increasingly being used in infectious disease research, with the greatest increase in the field of virology [73]. Due to the increased biohazard risk associated with RVFV, a more accessible hamster model for RVF based on challenge with the related Punta Toro virus was established [75]. Although the hamster PTV infection model has proved useful for reproducing certain features of severe human and animal RVFV infections where hepatic disease is a prominent pathological feature, other features such as encephalitis are not observed. Various murine and rat RVFV models are useful in evaluating most vaccine and antiviral drug candidates, yet certain therapeutic platforms may have little to no activity in these systems.

As previously reported details describing RVFV infection and disease in hamsters have been limited, we sought to more comprehensively characterize the RVFV infection model in golden Syrian hamsters and subsequently apply the model to evaluate the activity of the promising broadly-active compound, favipiravir. In summary, RVFV challenge in hamsters resulted in peracute disease and lethality within 2 to 3 days of challenge. High titer viremia and substantial viral loads were observed in most tissues examined and histologic analysis revealed marked hepatocellular necrosis consistent with fulminant hepatitis as the likely cause of death of RVFV-infected hamsters. Collectively, our data shows that RVFV infection of hamsters most closely resembles the disease observed in mice, but with a more accelerated progression.

Although we feel that RVFV infection in hamsters provides a robust challenge model suitable for early stage vaccine and antiviral drug efficacy studies, the model has its limitations (e.g. abbreviated therapeutic window) and additional analyses are required to better understand disease progression and make comparisons between hamster and the human condition. For example, future investigations should evaluate the clinical chemistry, hematology and coagulation. A drop in total white blood cell counts and serum glucose levels, increased ALT and bilirubin levels and an increase in clotting time have been reported in humans and various RVFV animal models [2,13,49,50]. We attempted to measure these and other clinical laboratory parameters in the present study; however, logistical and technical problems within the laboratory prevented the inclusion of such data in our analysis. It would also be of interest to study the inflammatory response through the measurement of cytokines longitudinally during the course of infection, using previously described methodologies for mRNA expression analysis in hamsters [109]. This information would provide a more complete clinical evaluation of the RVFV hamster model, as well as the host immune response to infection. Additionally, the insertion of implantable temperature transponders to continually monitor temperature would serve to determine whether RVFV-infected hamsters become febrile at any point during the acute infection or during the late-onset encephalitis that was observed with drug-treated animals that survive the systemic infection. Harvesting additional tissues such as the heart, thymus, lymph nodes, bone marrow would provide additional details useful in comparisons with the mouse infection model [13,14]. More importantly, analysis of reproductive organs could provide insights into the abortion storms that are characteristic of RVF epizootics.

Studies comparing s.c. challenge to aerosol challenge in murine, rat and marmoset systems resulted in significant differences in lethality and disease progression. Most notably, aerosol challenge typically resulted in a slower-progressing disease with an increase in

neuropathy [43,50,98]. Considering the rapid lethality in which RVFV overwhelms hamsters, aerosol challenge may provide a slower-developing disease process with an expanded therapeutic window. Considering the potential for intentional release and weaponization [30,55,68], the development of an aerosol exposure model in hamsters is warranted for the evaluation of promising vaccine and antiviral drug candidates. Future evaluation of the efficacy of T-705 and ribavirin in an aerosol exposure model is needed to confirm activity of these agents against respiratory route exposure. Studies building on our success with T-705 for the treatment of RVFV infection are also warranted. A comprehensive drug combination matrix should be examined to convincingly demonstrate synergy between the two compounds and possible antagonism at higher doses. This work would be invaluable towards future investigational new drug-enabling efficacy studies in a NHP primate model of RVFV, thereby advancing the compound towards clinical evaluation. Moreover, as of March 24, 2014, the Japanese Ministry of Health, Labour and Welfare approved T-705 (favipiravir) for the treatment of influenza in people. This exciting development represents the cornerstone for off-label use for treatment of human RVFV infection pending encouraging efficacy results in NHP models.

## REFERENCES

1. Morrill JC, McClain DJ (1996) Epidemiology and Pathogenesis of Rift Valley Fever and Other Phleboviruses. In: Elliott R, editor. *The Bunyaviridae*. New York and London: Plenum Press. pp. 281-293.
2. Ikegami T, Makino S (2011) The pathogenesis of Rift Valley fever. *Viruses* 3: 493-519.
3. Gowen BB, Holbrook MR (2008) Animal models of highly pathogenic RNA viral infections: Hemorrhagic fever viruses. *Antiviral Res* 78: 79-90.
4. WHO (2014) Rift Valley Fever. Global Alert and Response (GAR). Geneva: World Health Organization. [http://www.who.int/csr/don/archive/disease/rift\\_valley\\_fever/en/](http://www.who.int/csr/don/archive/disease/rift_valley_fever/en/)
5. Schmaljohn CS, Nichol ST (2007) Bunyaviridae. In: Knipe D, Howley P, editors. *Fields Virology*. Fifth ed. Philadelphia: Lippincott Williams & Wilkins. pp. 1741-1178.
6. Chevalier V, de la Rocque S, Baldet T, Vial L, Roger F (2004) Epidemiological processes involved in the emergence of vector-borne diseases: West Nile fever, Rift Valley fever, Japanese encephalitis and Crimean-Congo haemorrhagic fever. *Rev Sci Tech* 23: 535-555.
7. Filone CM, Hanna SL, Caino MC, Bambina S, Doms RW, et al. (2010) Rift valley fever virus infection of human cells and insect hosts is promoted by protein kinase C epsilon. *PLoS One* 5: e15483.
8. Filone CM, Heise M, Doms RW, Bertolotti-Ciarlet A (2006) Development and characterization of a Rift Valley fever virus cell-cell fusion assay using alphavirus replicon vectors. *Virology* 356: 155-164.
9. Piper ME, Sorenson DR, Gerrard SR (2011) Efficient cellular release of Rift Valley fever virus requires genomic RNA. *PLoS One* 6: e18070.
10. Pepin M, Bouloy M, Bird BH, Kemp A, Paweska J (2010) Rift Valley fever virus(Bunyaviridae: Phlebovirus): an update on pathogenesis, molecular epidemiology, vectors, diagnostics and prevention. *Vet Res* 41: 61.
11. Gerrard SR, Nichol ST (2002) Characterization of the Golgi retention motif of Rift Valley fever virus G(N) glycoprotein. *J Virol* 76: 12200-12210.
12. Gomet C, Billecocq A, Jouvion G, Hasan M, Zaverucha do Valle T, et al. (2011) Tissue tropism and target cells of NSs-deleted rift valley fever virus in live immunodeficient mice. *PLoS Negl Trop Dis* 5: e1421.
13. Smith D, Steele K, Shamblin J, Honko A, Johnson J, et al. (2010) The pathogenesis of Rift Valley fever virus in the mouse model. *Virology* 407: 256-267.
14. Reed C, Steele KE, Honko A, Shamblin J, Hensley LE, et al. (2012) Ultrastructural study of Rift Valley fever virus in the mouse model. *Virology* 431: 58-70.

15. Swanepoel R, Coetzer JAW (2004) Rift Valley fever; Coetzer J, Tustin R, editors. Cape Town: Oxford University Press. 1037-1070 p.
16. Fontenille D, Traore-Lamizana M, Diallo M, Thonnon J, Digoutte JP, et al. (1998) New vectors of Rift Valley fever in West Africa. *Emerg Infect Dis* 4: 289-293.
17. Bird BH, Khristova ML, Rollin PE, Ksiazek TG, Nichol ST (2007) Complete genome analysis of 33 ecologically and biologically diverse Rift Valley fever virus strains reveals widespread virus movement and low genetic diversity due to recent common ancestry. *J Virol* 81: 2805-2816.
18. Fontenille D, Traore-Lamizana M, Zeller H, Mondo M, Diallo M, et al. (1995) Short report: Rift Valley fever in western Africa: isolations from *Aedes* mosquitoes during an interepizootic period. *Am J Trop Med Hyg* 52: 403-404.
19. Nichol ST (2001) Bunyaviruses. In: Knipe D, Howley P, editors. *Fields Virology*. Fourth ed. Philadelphia: Lipincott, Williams & Wilkins. pp. 1603-1633.
20. Linthicum KJ, Bailey CL, Davies FG, Kairo A, Logan TM (1988) The horizontal distribution of *Aedes* pupae and their subsequent adults within a flooded dambo in Kenya: implications for Rift Valley fever virus control. *J Am Mosq Control Assoc* 4: 551-554.
21. Gargan TP, 2nd, Clark GG, Dohm DJ, Turell MJ, Bailey CL (1988) Vector potential of selected North American mosquito species for Rift Valley fever virus. *Am J Trop Med Hyg* 38: 440-446.
22. Traoré-lamizana M, Fontenille D, Diallo M, Bâ Y, Zeller HG, et al. (2001) Arbovirus Surveillance from 1990 to 1995 in the Barkedji Area (Ferlo) of Senegal, a Possible Natural Focus of Rift Valley Fever Virus. *J Med Entomology* 38: 480-492.
23. Woods CW, Karpati AM, Grein T, McCarthy N, Gaturuku P, et al. (2002) An outbreak of Rift Valley fever in Northeastern Kenya, 1997-98. *Emerg Infect Dis* 8: 138-144.
24. Balkhy HH, Memish ZA (2003) Rift Valley fever: an uninvited zoonosis in the Arabian peninsula. *Int J Antimicrob Agents* 21: 153-157.
25. Lutwick LI, Nierengarten MB (2002) Vaccines for Category A bioterrorism diseases. *Expert Opin Biol Ther* 2: 883-893.
26. Daubney R, Hudson J, Garnham P (1931) Enzootic hepatitis or Rift Valley fever: an undescribed virus disease of sheep, cattle and man from East Africa. *J Pathol Bacteriol* 34: 545-579.
27. Meegan JM (1979) The Rift Valley fever epizootic in Egypt 1977-78. 1. Description of the epizootic and virological studies. *Trans R Soc Trop Med Hyg* 73: 618-623.
28. Sissoko D, Giry C, Gabrie P, Tarantola A, Pettinelli F, et al. (2009) Rift Valley fever, Mayotte, 2007-2008. *Emerg Infect Dis* 15: 568-570.

29. WHO (2007) Outbreaks of Rift Valley fever in Kenya, Somalia and United Republic of Tanzania, December 2006-April 2007. Geneva. 169-178 p.
30. Hartley DM, Rinderknecht JL, Nipp TL, Clarke NP, Snowden GD, et al. (2011) Potential effects of Rift Valley fever in the United States. *Emerg Infect Dis* 17: e1.
31. Weaver SC, Reisen WK (2010) Present and future arboviral threats. *Antiviral Res* 85: 328-345.
32. Flick R, Bouloy M (2005) Rift Valley fever virus. *Current Molecular Methods* 5: 827-834.
33. Gerdes GH (2004) Rift Valley fever. *Revue scientifique et technique: Office International des Épizooties*. pp. 613-623.
34. Swanepoel R (2003) Classification, epidemiology and control of arthropod-borne viruses; Coetzer J, Tustin R, editors. Cape Town: Oxford University Press (SA). 2352 p.
35. Easterday BC, Murphy LC, Bennett DG (1962) Experimental Rift Valley fever in calves, goats and pigs. *Am J Vet Res* 23: 1224-1230.
36. Davies FG, Martin V (2006) Recognizing Rift Valley Fever. *Vet Ital* 42: 31-53.
37. Findlay G, Daubney R (1931) The virus of rift vally fever or enzootic hepatitis. *Lancet* 221: 1350-1351.
38. Ross TM, Bhardwaj N, Bissel SJ, Hartman AL, Smith DR (2012) Animal models of Rift Valley fever virus infection. *Virus Res* 163: 417-423.
39. Gowen B, Bailey K, Scharton D, Vest Z, Westover J, et al. (2013) Post-exposure vaccination with MP-12 lacking NSs protects mice against lethal Rift Valley fever virus challenge. *Antiviral Research* 98: 135-143.
40. Gowen BB, Wong MH, Jung KH, Sanders AB, Mendenhall M, et al. (2007) In Vitro and In Vivo Activities of T-705 against Arenavirus and Bunyavirus Infections. *Antimicrob Agents Chemother* 51: 3168-3176.
41. Gray K, Worthy M, Juelich T, Agar S, Poussard A, et al. (2012) Chemotactic and inflammatory responses in the liver and brain are associated with pathogenesis of Rift Valley fever virus infection in the mouse. *PLoS Negl Trop Dis* 6: e1529.
42. Bales JM, Powell DS, Bethel LM, Reed DS, Hartman AL (2012) Choice of inbred rat strain impacts lethality and disease course after respiratory infection with Rift Valley Fever Virus. *Front Cell Infect Microbiol* 2: 105.
43. Peters CJ, Slone TW (1982) Inbred rat strains mimic the disparate human response to Rift Valley fever virus infection. *J Med Virol* 10: 45-54.

44. Niklasson BS, Meadors GF, Peters CJ (1984) Active and passive immunization against Rift Valley fever virus infection in Syrian hamsters. *Acta Pathol Microbiol Immunol Scand C* 92: 197-200.
45. Rossie CA, Turell MJ (1988) Characterization of Attenuated Strains of Rift Valley Fever Virus. *J Gen Virol* 69: 817-823.
46. Anderson GW, Jr., Saluzzo JF, Ksiazek TG, Smith JF, Ennis W, et al. (1989) Comparison of in vitro and in vivo systems for propagation of Rift Valley fever virus from clinical specimens. *Res Virol* 140: 129-138.
47. Anderson GW, Jr., Slone TW, Jr., Peters CJ (1988) The gerbil, *Meriones unguiculatus*, a model for Rift Valley fever viral encephalitis. *Arch Virology* 102: 187-196.
48. Findlay G, MacKenzie R, Stern R (1936) The susceptibility of sheep and monkeys. *Br J Exp Pathol* 17: 431-441.
49. Smith DR, Bird BH, Lewis B, Johnston SC, McCarthy S, et al. (2012) Development of a novel nonhuman primate model for Rift Valley fever. *J Virol* 86: 2109-2120.
50. Hartman AL, Powell DS, Bethel LM, Caroline AL, Schmid RJ, et al. (2014) Aerosolized rift valley fever virus causes fatal encephalitis in african green monkeys and common marmosets. *J Virol* 88: 2235-2245.
51. Assad F, Davies FG, Eddy GA (1983) The use of veterinary vaccines for prevention and control of Rift Valley fever. *Bull WHO* 61: 261-268.
52. Coetzer JA, Barnard BJ (1977) Hydrops amnii in sheep associated with hydranencephaly and arthrogryposis with wesselsbron disease and rift valley fever viruses as aetiological agents. *Onderstepoort J Vet Res* 44: 119-126.
53. Botros B, Omar A, Elian K, Mohamed G, Soliman A, et al. (2006) Adverse response of non-indigenous cattle of European breeds to live attenuated Smithburn Rift Valley fever vaccine. *J Med Virol* 78: 787-791.
54. von Teichman B, Engelbrecht A, Zulu G, Dungu B, Pardini A, et al. (2011) Safety and efficacy of Rift Valley fever Smithburn and Clone 13 vaccines in calves. *Vaccine* 29: 5771-5777.
55. Bouloy M, Flick R (2009) Reverse genetics technology for Rift Valley fever virus: current and future applications for the development of therapeutics and vaccines. *Antiviral Res* 84: 101-118.
56. Pittman PR, Liu CT, Cannon TL, Makuch RS, Mangiafico JA, et al. (1999) Immunogenicity of an inactivated Rift Valley fever vaccine in humans: a 12-year experience. *Vaccine* 18: 181-189.
57. Frank-Peterside N (2000) Response of laboratory staff to vaccination with an inactivated Rift Valley fever vaccine--TSI-GSD 200. *Afr J Med Med Sci* 29: 89-92.

58. Caplen H, Peters CJ, Bishop DH (1985) Mutagen-directed attenuation of Rift Valley fever virus as a method for vaccine development. *J Gen Virol* 66 ( Pt 10): 2271-2277.
59. Lokugamage N, Freiberg AN, Morrill JC, Ikegami T (2012) Genetic subpopulations of Rift Valley fever virus strains ZH548 and MP-12 and recombinant MP-12 strains. *J Virol* 86: 13566-13575.
60. Morrill JC, Carpenter L, Taylor D, Ramsburg HH, Quance J, et al. (1991) Further evaluation of a mutagen-attenuated Rift Valley fever vaccine in sheep. *Vaccine* 9: 35-41.
61. Morrill JC, Mebus CA, Peters CJ (1997) Safety of a mutagen-attenuated Rift Valley fever virus vaccine in fetal and neonatal bovids. *Am J Vet Res* 58: 1110-1114.
62. Hunter P, Erasmus BJ, Vorster JH (2002) Teratogenicity of a mutagenised Rift Valley fever virus (MVP 12) in sheep. *Onderstepoort J Vet Res* 69: 95-98.
63. Bettinger GE (2011) Rift Valley fever virus: Coming to a country near you? 61st James Steele Conference, Diseases in Nature Transmissible to Man.  
<http://www.dshs.state.tx.us/WorkArea/linkit.aspx?LinkIdentifier=id&ItemID=8589961497>
64. Plotkin SA (2005) Vaccines: past, present and future. *Nat Med* 11: S5-11.
65. Bray M (2008) Highly pathogenic RNA viral infections: challenges for antiviral research. *Antiviral Res* 78: 1-8.
66. Graci J, Cameron C (2005) Mechanism of action of ribavirin against distinct viruses. *Reviews in Medical Virol* 16: 37-48.
67. Leyssen P, De Clercq E, Neyts J (2008) Molecular strategies to inhibit the replication of RNA viruses. *Antiviral Res* 78: 9-25.
68. Borio L, Inglesby T, Peters C, Schmaljohn A, Hughes J, et al. (2002) Hemorrhagic fever viruses as biological weapons: medical and public health management. *JAMA* 287: 2391-2405.
69. Snell N (2001) Ribavirin--current status of a broad spectrum antiviral agent. *Expert Opinion on Pharmacother* 2: 1317-1324.
70. Furuta Y, Gowen BB, Takahashi K, Shiraki K, Smee DF, et al. (2013) Favipiravir (T-705), a novel viral RNA polymerase inhibitor. *Antiviral Res* 100: 446-454.
71. Naesens L, Guddat LW, Keough DT, van Kuilenburg AB, Meijer J, et al. (2013) Role of human hypoxanthine guanine phosphoribosyltransferase in activation of the antiviral agent T-705 (favipiravir). *Mol Pharmacol* 84: 615-629.
72. Buys K, Jung K, Smee D, Furuta Y, Gowen B (2011) Maporal virus as a surrogate for pathogenic New World hantaviruses and its inhibition by favipiravir. *Antiviral Chemistry & Chemother* 21: 193-200.



73. Safronetz D, Falzarano D, Scott DP, Furuta Y, Feldmann H, et al. (2013) Antiviral efficacy of favipiravir against two prominent etiological agents of hantavirus pulmonary syndrome. *Antimicrobial Agents and Chemotherapy* 10.1128/aac.00886-13.
74. Gowen B, Wong M, Jung K, Smee D, Morrey J, et al. (2010) Efficacy of favipiravir (T-705) and T-1106 pyrazine derivatives in phlebovirus disease models. *Antiviral Res* 86: 121-127.
75. Anderson GW, Jr., Slayter MV, Hall W, Peters CJ (1990) Pathogenesis of a phleboviral infection (Punta Toro virus) in golden Syrian hamsters. *Archives Virol* 114: 203-212.
76. Fisher A, Tesh R, Tonry J, Guzman H, Liu D, et al. (2003) Induction of severe disease in hamsters by two sandfly fever group viruses, Punta toro and Gabek Forest (Phlebovirus, Bunyaviridae), similar to that caused by Rift Valley fever virus. *Am J Trop Med Hyg* 69: 269-276.
77. Pifat D, Smith J (1987) Punta Toro virus infection of C57BL/6J mice: a model for phlebovirus-induced disease. *Microb Pathog*, 3: 409-422.
78. Mandell R, Flick R (2011) Rift Valley Fever Virus: a real bioterror threat. *J Bioterrorism & Biodefense* 2: 108.
79. NIAID (2014) Category A, B, and C Priority Pathogens. Bethesda: National Institute of Allergy and Infectious Diseases. <http://www.niaid.nih.gov/topics/biodefenserelated/biodefense/pages/cata.aspx>
80. HHS (2005) Department of Health and Human Services. Possession, use, and transfer of biological agents and toxins. *Federal Register*. pp. 13294-13325.
81. USDA (2005) 7 CFR Part 331 and 9 CFR Part 121 Agricultural Bioterrorism Protection Act of 2002; Possession, use, and transfer of biological agents and toxins. *Federal Register*. pp. 13241-13292. <http://www.fas.org/sgp/news/2005/03/fr031805usda.html>
82. Kasari TR, Carr DA, Lynn TV, Weaver JT (2008) Evaluation of pathways for release of Rift Valley fever virus into domestic ruminant livestock, ruminant wildlife, and human populations in the continental United States. *J Am Vet Med Assoc* 232: 514-529.
83. Fischer EA, Boender GJ, Nodelijk G, de Koeijer AA, van Roermund HJ (2013) The transmission potential of Rift Valley fever virus among livestock in the Netherlands: a modelling study. *Vet Res* 44: 58.
84. Scharton D, Bailey KW, Vest Z, Westover JB, Kumaki Y, et al. (2014) Favipiravir (T-705) protects against peracute Rift Valley fever virus infection and reduces delayed-onset neurologic disease observed with ribavirin treatment. *Antiviral Res* 104: 84-92.
85. Gowen B, Ennis J, Sefing E, Wong M, Jung K, et al. (2012) Extended protection against phlebovirus infection conferred by recombinant adenovirus expressing consensus interferon (DEF201). *Antimicrobial Agents Chemother* 56: 4168-4174.

86. Gowen B, Wong M, Jung K, Blatt L, Sidwell R (2008) Prophylactic and therapeutic intervention of Punta Toro virus (Phlebovirus, Bunyaviridae) infection in hamsters with interferon alfacon-1. *Antiviral Research* 77: 215-224.
87. Wahl-Jensen V, Bollinger L, Safronetz D, de Kok-Mercado F, Scott DP, et al. (2012) Use of the Syrian hamster as a new model of ebola virus disease and other viral hemorrhagic fevers. *Viruses* 4: 3754-3784.
88. Gowen BB, Ennis J, Bailey KW, Vest Z, Scharton D, et al. (2014) Single-dose intranasal treatment with DEF201 (Adenovirus Vectors Consensus Interferon) prevents lethal disease due to Rift Valley fever virus challenge. *Viruses* 6: 1410-1423.
89. Peters CJ, Reynolds JA, Slone TW, Jones DE, Stephen EL (1986) Prophylaxis of Rift Valley fever with antiviral drugs, immune serum, an interferon inducer, and a macrophage activator. *Antiviral Res* 6: 285-297.
90. Saluzzo JF, Anderson GW, Jr., Hodgson LA, Digoutte JP, Smith JF (1989) Antigenic and biological properties of Rift Valley fever virus isolated during the 1987 Mauritanian epidemic. *Res Virol* 140: 155-164.
91. Easterday BC (1965) Rift Valley fever. *Adv Vet Sci* 10: 65-127.
92. Reed LJ, Muench H (1938) A simple method of estimating fifty percent endpoints. *Am J Hyg* 27: 493-497.
93. Peters CJ, Jones D, Trotter R, Donaldson J, White J, et al. (1988) Experimental Rift Valley fever in rhesus macaques. *Arch Virol* 99: 31-44.
94. Morrill JC, Jennings GB, Johnson AJ, Cosgriff TM, Gibbs PH, et al. (1990) Pathogenesis of Rift Valley fever in rhesus monkeys: role of interferon response. *Arch of Virol* 110: 195-212.
95. Laughlin LW, Meegan JM, Strausbaugh LJ, Morens DM, Watten RH (1979) Epidemic Rift Valley fever in Egypt: observations of the spectrum of human illness. *Trans R Soc Trop Med Hyg* 73: 630-633.
96. Madani TA, Al-Mazrou YY, Al-Jeffri MH, Mishkhas AA, Al-Rabeah AM, et al. (2003) Rift Valley fever epidemic in Saudi Arabia: epidemiological, clinical, and laboratory characteristics. *Clin Infect Dis* 37: 1084-1092.
97. Nguku PM, Sharif SK, Mutonga D, Amwayi S, Omolo J, et al. (2010) An Investigation of a Major Outbreak of Rift Valley Fever in Kenya: 2006–2007. *Am J Tropical Med Hyg* 83: 05-13.
98. Reed C, Lin K, Wilhelmsen C, Friedrich B, Nalca A, et al. (2013) Aerosol exposure to Rift Valley fever virus causes earlier and more severe neuropathology in the murine model, which has important implications for therapeutic development. *PLoS Negl Trop Dis* 7: e2156.

99. Sangawa H, Komeno T, Nishikawa H, Yoshida A, Takahashi K, et al. (2013) Mechanism of action of T-705 ribosyl triphosphate against influenza virus RNA polymerase. *Antimicrob Agents Chemother*.
100. Furuta Y, Takahashi K, Kuno-Maekawa M, Sangawa H, Uehara S, et al. (2005) Mechanism of action of T-705 against influenza virus. *Antimicrob Agents Chemother* 46: 981-986.
101. Jin Z, Smith LK, Rajwanshi VK, Kim B, Deval J (2013) The ambiguous base-pairing and high substrate efficiency of T-705 (Favipiravir) Ribofuranosyl 5'-Triphosphate towards Influenza A virus polymerase. *PLoS One* 8: e68347.
102. Cavanaugh PF, Jr., Moskwa PS, Donish WH, Pera PJ, Richardson D, et al. (1990) A semi-automated neutral red based chemosensitivity assay for drug screening. *Invest New Drugs* 8: 347-354.
103. Kumaki Y, Wandersee MK, Smith AJ, Zhou Y, Simmons G, et al. (2011) Inhibition of severe acute respiratory syndrome coronavirus replication in a lethal SARS-CoV BALB/c mouse model by stinging nettle lectin, *Urtica dioica* agglutinin. *Antiviral Res* 90: 22-32.
104. Peters C, Reynolds J, Slone T, Jones D, Stephen E (1986) Prophylaxis of Rift Valley fever with antiviral drugs, immune serum, an interferon inducer, and a macrophage activator. *Antiviral Res* 6: 285-297.
105. McCormick JB, King I, Webb P, Scribner C, Craven R, et al. (1986) Lassa fever. Effective therapy with ribavirin. *N Engl J Med* 314: 20-26.
106. Russmann S, Grattagliano I, Portincasa P, Palmieri VO, Palasciano G (2006) Ribavirin-induced anemia: mechanisms, risk factors and related targets for future research. *Curr Med Chem*. 2006/12/16 ed. pp. 3351-3357.
107. Reagan-Shaw S, Nihal M, Ahmad N (2008) Dose translation from animal to human studies revisited. *The FASEB J* 22: 659-661.
108. Canonico PG, Kende M, Luscri BJ, Huggins JW (1984) In-vivo activity of antivirals against exotic RNA viral infections. *J Antimicrobial Chemother* 14: 27-41.
109. Zivcec M, Safronetz D, Haddock E, Feldmann H, Ebihara H (2011) Validation of assays to monitor immune responses in the Syrian golden hamster (*Mesocricetus auratus*). *J Immunol Methods* 368: 24-35.