



Update on the diagnosis and management of autoimmune encephalitis

Journal:	<i>Clinical Medicine</i>
Manuscript ID	CM-2020-0241.R1
Manuscript Type:	CME
Keywords:	Encephalitis, Autoimmune

SCHOLARONE™
Manuscripts

Update on the diagnosis and management of autoimmune encephalitis

Ellul M^{1,2,3}, Wood G², Van Den Tooren H¹, Babu A¹, Easton A^{2,4}, Michael BD^{1,2,3}

1. The Walton Centre NHS Foundation Trust, Liverpool, UK

2. Institute for Infection and Global Health, University of Liverpool, UK

3. The NIHR Health Protection Research Unit for Emerging and Zoonotic Infection, Liverpool, UK

4. The Encephalitis Society, Yorkshire, UK

Abstract

In recent years, autoimmunity has been increasingly recognised as an important cause of encephalitis. Many different antibodies are now known to target antigens on the neuronal surface, and some of these are associated with characteristic clinical presentations, although seronegative cases are also recognised. Autoimmune encephalitis may mimic other conditions, including primary psychiatric disorders, particularly early in the disease. Because early immune treatment of autoimmune encephalitis improves patient outcomes, and indeed many make a good recovery, it is important to recognise these syndromes promptly.

Introduction

Encephalitis, a disease of inflammation of the brain, may be caused by an infectious pathogen or by autoimmune processes. Over the last 5-10 years encephalitis associated with antibodies against neuronal surface antigens has been increasingly recognised.

Autoimmune encephalitis is thought to account for at least 20 percent of cases of encephalitis,¹ therefore the UK might expect approximately 1000 cases/year.² Many patients with autoimmune encephalitis (AE) have the capacity to make a good recovery if treated appropriately, despite a stormy disease course. Therefore, it is important to have a high index of suspicion to recognise cases early. However, the myriad antibodies now available for testing have the potential to cause confusion.

This CME article will explore recent developments in AE research and practical implications for physicians. Antibodies associated with intracellular antigens are often paraneoplastic and immune-therapy responses may be limited. Also, some antibodies, such as thyroid peroxidase antibodies, are thought to represent an epiphenomenon. Therefore, this article will focus on encephalitis in adults with antibodies directed against neuronal surface antibodies, where early diagnosis and management can substantively improve outcomes.

Clinical syndromes

The spectrum of clinical presentations associated with AE is wide and partly reflects the antibody involved (table 1). The most recognisable clinical syndromes are limbic encephalitis and NMDA-R encephalitis.

Limbic encephalitis, reflecting inflammation of the medial temporal lobe, may present with changes in behaviour, seizures or memory difficulties. Two of the most common and well characterised antibodies which are associated with limbic encephalitis are those directed against leucine-rich glioma-inactivated 1 (LGI1) and Contactin-associated protein-like 2 (CASPR2). AE associated with LGI1 antibodies generally affects older patients and is unusual in those <40 years. LGI1 antibodies may be associated with faciobrachial dystonic seizures: brief jerking movements affecting ipsilateral arm and face, which when seen are highly specific to LGI1 and may precede the onset of encephalitis, however they may not be present in many.³ Hyponatraemia is also a common finding.⁴ CASPR2 antibody encephalitis can present with a crossover of central and peripheral nervous system features including memory difficulties, sleep disturbances and peripheral nerve hyperexcitability syndromes. Testing for VGKC-complex antibodies should now be abandoned in favour of testing for LGI1 and CASPR2 antibodies, which target proteins associated with the ion channel. VGKC positivity in the absence of LGI1 or CASPR2 antibodies has been reported in a heterogeneous group of clinical syndromes, but is not thought to be a true marker of disease.⁵

NMDA-R encephalitis most often affects children and younger adults, has a 4:1 female predominance and is associated with ovarian teratoma in around half of the females. The disorder begins with abnormal behaviour, often with psychotic or affective features, developing by one month into a characteristic clinical picture. This may include seizures, movement disorder (classically orofacial dyskinesia, but limb dyskinesia/chorea is often predominant), reduced conscious level and autonomic dysfunction (particularly bradycardia/tachycardia, hyperthermia and fluctuating blood pressure).⁶ NMDA-R encephalitis can occasionally be triggered by herpes simplex virus (HSV) encephalitis: in a recent prospective study of 51 patients with HSV encephalitis, 14 developed secondary autoimmune encephalitis associated with neuronal antibodies, although 3 also developed NMDA-R antibodies in the absence of clinical evidence of encephalitis.⁷

Other, more recently described syndromes are associated with antibodies against γ -aminobutyric acid receptors (GABAR) type A or B, the α -amino-3-hydroxy-5-methyl-4-isoxazolepropionic acid receptor (AMPA) and dipeptidyl-peptidase-like protein 6 (DPPX) (Table 1).

Clinicians should be aware of *formes frustes* within these classical syndromes, for example some patients incipient NMDA-R encephalitis may present with first episode psychosis or prominent movement disorder.

3. Diagnosis

Patients presenting with symptoms suggestive of encephalitis should be admitted urgently and undergo lumbar puncture and neuroimaging. The main concern at the outset is to exclude an infectious cause such as HSV, which can cause rapidly progressive brain oedema, necrosis and death. Aciclovir treatment in HSV encephalitis is a life-saving intervention. Several antibody-associated encephalitides, particularly NMDA-R encephalitis, can present similarly to primary **psychiatric** illness. “Red flag” early features for AE include an infectious prodrome, rapid progression, movement disorder, focal neurological signs, seizures or unexplained hyponatraemia.⁸

Although autoimmune encephalitis is now usually a positive diagnosis, other mimics of AE should be excluded, including primary central nervous system (CNS) lymphoma, neurosarcoidosis, CNS vasculitis, tumours, genetic epilepsy syndromes, mitochondrial encephalomyopathies, and prion disease.

CSF findings are often abnormal in AE, with a mild lymphocytic pleocytosis and/or moderately raised CSF protein. However, a completely normal CSF occurs in up to a third of patients and does not exclude the diagnosis.⁹

Neuroimaging with magnetic resonance imaging (MRI) is essential, although this may also be normal in up to a third of cases.¹⁰ In general, MRI findings are nonspecific although medial temporal lobe signal change frequently occurs in limbic encephalitis (e.g. figure 1 A and B).

Electroencephalography (EEG) often reveals encephalopathic changes which can support the diagnosis but are nonspecific. Caution is required as psychiatric and antiepileptic drugs can cause similar features.¹¹ EEG is helpful in diagnosing non-convulsive status epilepticus, or in distinguishing seizures (e.g. epilepsia partialis continua (EPC)) from a movement disorder. NMDA-R encephalitis may be associated with characteristic extreme delta brush pattern (figure 1 C).

Antibody testing for encephalitis is a rapidly evolving area of neuroimmunology. Certain autoimmune encephalitides, particularly those associated with NMDA-R and LGI1 antibodies, present with recognisable clinical syndromes and diagnostic suspicion may already be high so that antibody testing can be targeted. In other cases without distinguishing features, testing for a wider range of antibodies may be necessary, in consultation with a neurologist and neuroimmunology laboratory. Panels of immunofluorescence tests have been developed commercially and their role is still evolving, considering the balance between increased chance of detecting a pathogenic antibody versus the potential for false positives. Antibodies have hitherto mostly been tested in serum. However, intrathecal antibody synthesis occurs in most forms of AE and, particularly for NMDA-R antibodies, **CSF testing is more specific than serum and should be undertaken where clinical suspicion is high and in challenging cases.**

Consensus criteria also allow for a diagnosis of ‘**seronegative AE**’, based on clinical features in the absence of antibodies which may respond to immune therapy.^{6,12} (box 1)

1
2
3 Because of the paraneoplastic associations of several antibodies, **investigation for malignancy** is crucial. Computed tomography of the chest, abdomen, and pelvis is
4 indicated in all patients with suspected AE. For those with particular associations,
5 such as GABA_BR, positron emission tomography scanning is advised and, if
6 negative, should be repeated at 3-6 months.¹³ Additionally, in NMDA-R encephalitis,
7 because of the association with teratoma, ultrasound of the ovaries or testes should
8 be performed.
9
10
11
12
13

14 **4. Management and outcome**

16 Evidence for optimal management of AE is largely based on retrospective studies,
17 together with principles adapted from other antibody mediated diseases, e.g.
18 myasthenia gravis. **Patients with encephalitis should be managed at a centre with
19 appropriate facilities and specialist expertise, ideally a regional neuroscience centre,
20 in accordance with the national guidelines of the Association of British Neurologists
21 and British Infection Association.**
22
23

24 **First line therapy**, aimed at reducing antibody levels rapidly, normally comprises
25 intravenous corticosteroids often in combination with intravenous immunoglobulin or
26 plasma exchange. In those who fail to respond, more aggressive immune therapy is
27 usually started, with concomitant higher risk of adverse effects, including
28 cyclophosphamide or rituximab.¹⁴ In NMDA-R encephalitis other agents such as
29 bortezomib have been used in a small number of refractory cases. Relapses may
30 occur when immune therapy is reduced, or may reflect tumour recurrence or
31 persistence of missed tumour.¹⁵
32
33
34

35 Starting immune therapy early has been associated with improved outcome in
36 **NMDA-R encephalitis** in retrospective series. Also, in those who fail to respond to
37 first-line therapy, moving to more aggressive second line treatments **is associated
38 with better outcome and reduced rate of relapse.**¹⁶ In patients with ovarian teratoma,
39 tumour resection is associated with **faster rate of recovery** and reduced relapse
40 rate.¹⁶
41
42

43 **LG11 encephalitis** generally responds well to first-line treatment, particularly
44 corticosteroids, and outcomes are generally good, however, in the long-term
45 cognitive problems are common.^{17,18}
46

47 Patients with autoimmune encephalitis often require extensive **supportive care**,
48 including prolonged intensive care unit stays. Issues may include managing
49 seizures, autonomic instability, infective complications, and agitation. Antipsychotic
50 medications may be required, but should be used with caution due to the risk of
51 extrapyramidal side effects or neuroleptic malignant syndrome, which may be higher
52 in NMDA-R encephalitis.¹⁹
53
54

55 With appropriate treatment, **outcome** overall compares favourably with infectious
56 encephalitis, with >80% of patients with NMDA-R encephalitis having no more than
57 slight disability (modified Rankin Scale 2) at 2 years.¹⁶ However, evidence is
58 emerging that subtle neurocognitive/psychosocial issues may be more prevalent
59
60

1
2
3 than previously appreciated.²⁰ Support from psychology/counselling services and
4 charitable groups, such as the Encephalitis Society, is vital in the recovery phase.
5
6
7

8 **5. Conclusions**

9
10 It is increasingly possible to make a positive diagnosis of AE given consensus
11 clinical criteria and increased availability of antibody tests. However, this relies on a
12 high index of suspicion, especially in those presenting with primarily psychiatric
13 features. The diagnosis is often supported by the development of 'neurological'
14 features, such as movement disorders and seizures, laboratory tests, and MRI, but
15 these may be normal in some. Antibody testing should be organised in consultation
16 with a neurologist and neuroimmunology laboratory, with a pragmatic strategy based
17 on careful clinical assessment. Even in the absence of antibodies, it may be possible
18 to make a syndromic diagnosis.
19
20
21

22 Many with AE have a good outcome with early immune therapy, tumour resection if
23 needed, and supportive care. Randomised controlled trials are needed to guide
24 treatment strategies.
25
26
27
28
29

30 **Key points**

31
32 Autoimmune encephalitis should be a key part of the differential diagnosis in patients
33 with alterations in cognition, consciousness, personality, or behaviour.
34

35 Antibody testing should be guided by recognisable clinical syndromes, but also
36 should account for the expanding numbers of recognised antibodies and overlapping
37 phenotypes.
38

39 Autoimmune encephalitis may present sub-acutely with normal or subtly abnormal
40 CSF findings and neuroimaging.
41

42 Despite severe symptoms and long ITU stays, the outcome of AE is good in most
43 cases if early immune therapy is given.
44

45 The optimum first and second line treatment strategy for AE is unclear and well-
46 designed clinical trials are needed.
47
48
49
50

51 **Key words**

52 Neuroimmunology, encephalitis, autoimmunity, NMDA-R encephalitis, limbic
53 encephalitis.
54
55
56
57
58
59
60

1
2
3
4
5
6
7
8
9
10
11
12
13
14
15
16
17
18
19
20
21
22
23
24
25
26
27
28
29
30
31
32
33
34
35
36
37
38
39
40
41
42
43
44
45
46
47
48
49
50
51
52
53
54
55
56
57
58
59
60

For Review Only

Self-assessment questions

1. A 72 year old man presented with a 3 month history of gradually worsening memory difficulties and unusual behaviour, including emotional lability. Family had noticed some jerky movements of his left arm and face on a few occasions over the preceding three weeks. On examination he was alert but distracted and his mini mental state examination (MMSE) score was 9/30. MRI brain showed age-appropriate brain atrophy with T2 signal hyperintensity in the right medial temporal lobe. CSF showed white cell count of $8/\text{mm}^3$ (normal range <5), protein of 0.7 g/L (normal <0.5) with normal glucose ratio. Which antibody is most likely to be found in association with this presentation?

- A. AMPAR
- B. CASPR2
- C. GABA_BR
- D. LGI1
- E. NMDA-R

Answer: D.

The patient had limbic encephalitis, with typically prominent memory and cognitive problems with a subacute onset and inflammation in the medial temporal lobe. The most common antibody identified in this situation is LGI1, and the jerky movements seen by his family are suspicious for faciobrachial dystonic seizures which may be pathognomonic for this disorder.

2. A 23 year old woman was referred from the psychiatric hospital for assessment of suspected seizures and hyperthermia. She had been an inpatient there for 6 weeks receiving treatment for a first episode of psychosis with neuroleptic medications. On clinical examination she was drowsy, had writhing movements of her left hand and was repeatedly protruding her tongue. Her temperature was 38.2°C and heart rate was 135. MRI brain was normal and CSF showed white cell count of 35 (normal range <5), protein of 0.4 g/L (normal range <0.5). CT scan of the chest, abdomen and pelvis revealed an ovarian mass. What is the most likely diagnosis?

- A. Juvenile myoclonic epilepsy
- B. LGI1 encephalitis
- C. NMDA-R encephalitis
- D. Primary psychiatric diagnosis

1
2
3 E. Tardive dyskinesia
4
5
6

7 **Answer: C**
8

9 The combination of psychiatric features with autonomic instability, movement
10 disorder and encephalopathy is characteristic of NMDA-R encephalitis. The
11 presence of CSF pleocytosis, and an ovarian mass (most likely a teratoma) is also
12 supportive, and the mass should be resected urgently. MRI brain is frequently
13 normal in AE. Juvenile myoclonic epilepsy presents with myoclonus (which are not
14 writhing movements) and generalised seizures. LGI1 encephalitis causes a limbic
15 encephalitis, usually in older adults. Tardive dyskinesia would be unusual after only a
16 few weeks of treatment and does not explain the addition features.
17
18
19

20
21 3. A 52 year old woman, previously fit and well, presented to the emergency
22 department with a 4 day history of flu-like illness and increasing drowsiness, with a
23 single generalised tonic-clonic seizure. Her family reported that she had been
24 agitated and aggressive when rousable. On examination her Glasgow coma scale
25 (GCS) score was 10 (E3, V2, M5), she was moving all four limbs. CT brain showed
26 subtle diffuse hypodensity in bilateral medial temporal lobes of uncertain aetiology,
27 more prominent on the left. What is the most appropriate initial management?
28
29

- 30
31 A. Intravenous alteplase
32
33 B. Intravenous corticosteroids
34
35 C. Intravenous immunoglobulin
36
37 D. Plasma exchange
38
39 E. Intravenous aciclovir
40
41

42 **Answer: E**
43

44 In a patient with acute decrease in conscious level and seizures, infectious
45 encephalitis (most commonly HSV encephalitis in the UK) is the most important
46 diagnosis to rule out. Lumbar puncture (LP) should be performed urgently, and
47 intravenous aciclovir (which decreases morbidity and mortality) should be given
48 either immediately after the LP, or before if LP is delayed for any reason.
49
50
51
52
53
54
55
56
57
58
59
60

1. Granerod J, Ambrose HE, Davies NW, et al. Causes of encephalitis and differences in their clinical presentations in England: a multicentre, population-based prospective study. *The Lancet. Infectious diseases* 2010;10:835-44.
2. Granerod J, Cousens S, Davies NW, et al. New estimates of incidence of encephalitis in England. *Emerg Infect Dis* 2013;19.
3. Irani SR, Michell AW, Lang B, et al. Faciobrachial dystonic seizures precede Lgi1 antibody limbic encephalitis. *Annals of neurology* 2011;69:892-900.
4. O'Sullivan BJ, Steele T, Ellul MA, et al. When should we test for voltage-gated potassium channel complex antibodies? A retrospective case control study. *Journal of clinical neuroscience : official journal of the Neurosurgical Society of Australasia* 2016;33:198-204.
5. van Sonderen A, Schreurs MW, Wirtz PW, et al. From VGKC to LGI1 and Caspr2 encephalitis: The evolution of a disease entity over time. *Autoimmun Rev* 2016;15:970-4.
6. Graus F, Titulaer MJ, Balu R, et al. A clinical approach to diagnosis of autoimmune encephalitis. *Lancet Neurol* 2016;15:391-404.
7. Armangue T, Spatola M, Vlasea A, et al. Frequency, symptoms, risk factors, and outcomes of autoimmune encephalitis after herpes simplex encephalitis: a prospective observational study and retrospective analysis. *Lancet Neurol* 2018.
8. Pollak TA, Lennox BR, Muller S, et al. Autoimmune psychosis: an international consensus on an approach to the diagnosis and management of psychosis of suspected autoimmune origin. *Lancet Psychiatry* 2020;7:93-108.
9. Dubey D, Pittock SJ, Kelly CR, et al. Autoimmune encephalitis epidemiology and a comparison to infectious encephalitis. *Annals of neurology* 2018;83:166-77.
10. Baumgartner A, Rauer S, Mader I, et al. Cerebral FDG-PET and MRI findings in autoimmune limbic encephalitis: correlation with autoantibody types. *Journal of neurology* 2013;260:2744-53.
11. Venkatesan A, Michael BD, Probasco JC, et al. Acute encephalitis in immunocompetent adults. *Lancet* 2019;393:702-16.
12. Graus F, Escudero D, Oleaga L, et al. Syndrome and outcome of antibody-negative limbic encephalitis. *European journal of neurology : the official journal of the European Federation of Neurological Societies* 2018;25:1011-6.
13. Titulaer MJ, Soffietti R, Dalmau J, et al. Screening for tumours in paraneoplastic syndromes: report of an EFNS task force. *European journal of neurology : the official journal of the European Federation of Neurological Societies* 2011;18:19-e3.
14. Nosadini M, Mohammad SS, Ramanathan S, et al. Immune therapy in autoimmune encephalitis: a systematic review. *Expert review of neurotherapeutics* 2015;15:1391-419.
15. Dalmau J, Graus F. Antibody-Mediated Encephalitis. *The New England journal of medicine* 2018;378:840-51.
16. Titulaer MJ, McCracken L, Gabilondo I, et al. Treatment and prognostic factors for long-term outcome in patients with anti-NMDA receptor encephalitis: an observational cohort study. *Lancet Neurol* 2013;12:157-65.
17. Irani SR, Gelfand JM, Bettcher BM, et al. Effect of rituximab in patients with leucine-rich, glioma-inactivated 1 antibody-associated encephalopathy. *JAMA neurology* 2014;71:896-900.
18. Arino H, Armangue T, Petit-Pedrol M, et al. Anti-LGI1-associated cognitive impairment: Presentation and long-term outcome. *Neurology* 2016;87:759-65.
19. Lejoste F, Thomas L, Picard G, et al. Neuroleptic intolerance in patients with anti-NMDAR encephalitis. *Neurol Neuroimmunol Neuroinflamm* 2016;3:e280.
20. Yeshokumar AK, Gordon-Lipkin E, Arenivas A, et al. Neurobehavioral outcomes in autoimmune encephalitis. *J Neuroimmunol* 2017;312:8-14.

Table 1. Key features of syndromes associated with neuronal surface antibodies

Antibody	Demographics		Key distinguishing features	Tumour associations
	Age predominance	F:M ratio		
NMDAR	Children Adults <40 years	4:1	Psychiatric features followed by movement disorder (classically orofacial dyskinesia), seizures, encephalopathy and autonomic dysfunction	About 50% of female patients have ovarian teratoma. Other tumour associations have been described
LGI1	Older adults	1:2	Faciobrachial dystonic seizures, amnesia, hyponatraemia	<10% Breast, lymphoma, thymoma, thyroid
CASPR2	Older adults	1:9	Sleep disorders (insomnia, sleep-wake cycle disturbance), peripheral nerve hyperexcitability, ataxia	<5%, various tumours
GABA_AR	Children or adults	1:1	Seizures	Thymoma in 30%
GABA_BR	Older adults	1:1.5	Seizures, amnesia	SCLC in 50%
AMPA	Older adults	2:1	Amnesia	65% Breast, SCLC, thymoma
DPPX	Adults	1:2	Severe diarrhoea and weight loss, myoclonus, hyperekplexia	<10% Lymphoma

NMDAR = N-methyl -aspartate receptor; LGI1 = leucine rich glioma inactivated-1; CASPR2 = contactin-associated protein-like 2; GABA_AR = γ -aminobutyric acid type A receptor; GABA_BR = γ -aminobutyric acid type B receptor; AMPAR = α -amino-3-hydroxy-5-methyl-4-isoxazolepropionic acid receptor; DPPX = dipeptidyl-peptidase-like protein 6; SCLC = small cell lung cancer.

Box 1. Diagnostic criteria for possible autoimmune encephalitis ⁶

Diagnosis can be made when all three of the following criteria have been met:

1. Subacute onset (rapid progression of less than three months) of working memory deficits (short-term memory loss), altered mental status, or psychiatric symptoms.
2. At least one of the following:
 - New focal CNS findings
 - Seizures not explained by a previously known seizure disorder
 - CSF pleocytosis
 - MRI features suggestive of encephalitis
3. Reasonable exclusion of alternative causes (e.g. HSV encephalitis).

CNS = central nervous symptoms; CSF = cerebrospinal fluid; MRI = magnetic resonance imaging.

Update on the diagnosis and management of autoimmune encephalitis

Ellul M^{1,2,3}, Wood G², Van Den Tooren H¹, Babu A¹, Easton A^{2,4}, Michael BD^{1,2,3}

1. The Walton Centre NHS Foundation Trust, Liverpool, UK

2. Institute for Infection and Global Health, University of Liverpool, UK

3. The NIHR Health Protection Research Unit for Emerging and Zoonotic Infection, Liverpool, UK

4. The Encephalitis Society, Yorkshire, UK

Abstract

In recent years, autoimmunity has been increasingly recognised as an important cause of encephalitis. Many different antibodies are now known to target antigens on the neuronal surface, and some of these are associated with characteristic clinical presentations, although seronegative cases are also recognised. Autoimmune encephalitis may mimic other conditions, including primary psychiatric disorders, particularly early in the disease. Because early immune treatment of autoimmune encephalitis improves patient outcomes, and indeed many make a good recovery, it is important to recognise these syndromes promptly.

Introduction

Encephalitis, a disease of inflammation of the brain, may be caused by an infectious pathogen or by autoimmune processes. Over the last 5-10 years encephalitis associated with antibodies against neuronal surface antigens has been increasingly recognised.

Autoimmune encephalitis is thought to account for at least 20 percent of cases of encephalitis,¹ therefore the UK might expect approximately 1000 cases/year.² Many patients with autoimmune encephalitis (AE) have the capacity to make a good recovery if treated appropriately, despite a stormy disease course. Therefore, it is important to have a high index of suspicion to recognise cases early. However, the myriad antibodies now available for testing have the potential to cause confusion.

This CME article will explore recent developments in AE research and practical implications for physicians. Antibodies associated with intracellular antigens are often paraneoplastic and immune-therapy responses may be limited. Also, some antibodies, such as thyroid peroxidase antibodies, are thought to represent an epiphenomenon. Therefore, this article will focus on encephalitis in adults with antibodies directed against neuronal surface antibodies, where early diagnosis and management can substantively improve outcomes.

Clinical syndromes

The spectrum of clinical presentations associated with AE is wide and partly reflects the antibody involved (table 1). The most recognisable clinical syndromes are limbic encephalitis and NMDA-R encephalitis.

Limbic encephalitis, reflecting inflammation of the medial temporal lobe, may present with changes in behaviour, seizures or memory difficulties. Two of the most common and well characterised antibodies which are associated with limbic encephalitis are those directed against leucine-rich glioma-inactivated 1 (LGI1) and Contactin-associated protein-like 2 (CASPR2). AE associated with LGI1 antibodies generally affects older patients and is unusual in those <40 years. LGI1 antibodies may be associated with faciobrachial dystonic seizures: brief jerking movements affecting ipsilateral arm and face, which when seen are highly specific to LGI1 and may precede the onset of encephalitis, however they may not be present in many.³ Hyponatraemia is also a common finding.⁴ CASPR2 antibody encephalitis can present with a crossover of central and peripheral nervous system features including memory difficulties, sleep disturbances and peripheral nerve hyperexcitability syndromes. Testing for VGKC-complex antibodies should now be abandoned in favour of testing for LGI1 and CASPR2 antibodies, which target proteins associated with the ion channel. VGKC positivity in the absence of LGI1 or CASPR2 antibodies has been reported in a heterogeneous group of clinical syndromes, but is not thought to be a true marker of disease.⁵

NMDA-R encephalitis most often affects children and younger adults, has a 4:1 female predominance and is associated with ovarian teratoma in around half of the females. The disorder begins with abnormal behaviour, often with psychotic or affective features, developing by one month into a characteristic clinical picture. This may include seizures, movement disorder (classically orofacial dyskinesia, but limb dyskinesia/chorea is often predominant), reduced conscious level and autonomic dysfunction (particularly bradycardia/tachycardia, hyperthermia and fluctuating blood pressure).⁶ NMDA-R encephalitis can occasionally be triggered by herpes simplex virus (HSV) encephalitis: in a recent prospective study of 51 patients with HSV encephalitis, 14 developed secondary autoimmune encephalitis associated with neuronal antibodies, although 3 also developed NMDA-R antibodies in the absence of clinical evidence of encephalitis.⁷

Other, more recently described syndromes are associated with antibodies against γ -aminobutyric acid receptors (GABAR) type A or B, the α -amino-3-hydroxy-5-methyl-4-isoxazolepropionic acid receptor (AMPA) and dipeptidyl-peptidase-like protein 6 (DPPX) (Table 1).

Clinicians should be aware of *formes frustes* within these classical syndromes, for example some patients incipient NMDA-R encephalitis may present with first episode psychosis or prominent movement disorder.

3. Diagnosis

Patients presenting with symptoms suggestive of encephalitis should be admitted urgently and undergo lumbar puncture and neuroimaging. The main concern at the outset is to exclude an infectious cause such as HSV, which can cause rapidly progressive brain oedema, necrosis and death. Aciclovir treatment in HSV encephalitis is a life-saving intervention. Several antibody-associated encephalitides, particularly NMDA-R encephalitis, can present similarly to primary **psychiatric** illness. “Red flag” early features for AE include an infectious prodrome, rapid progression, movement disorder, focal neurological signs, seizures or unexplained hyponatraemia.⁸

Although autoimmune encephalitis is now usually a positive diagnosis, other **mimics** of AE should be excluded, including primary central nervous system (CNS) lymphoma, neurosarcoidosis, CNS vasculitis, tumours, genetic epilepsy syndromes, mitochondrial encephalomyopathies, and prion disease.

CSF findings are often abnormal in AE, with a mild lymphocytic pleocytosis and/or moderately raised CSF protein. However, a completely normal CSF occurs in up to a third of patients and does not exclude the diagnosis.⁹

Neuroimaging with magnetic resonance imaging (MRI) is essential, although this may also be normal in up to a third of cases.¹⁰ In general, MRI findings are nonspecific although medial temporal lobe signal change frequently occurs in limbic encephalitis (e.g. figure 1 A and B).

Electroencephalography (EEG) often reveals encephalopathic changes which can support the diagnosis but are nonspecific. Caution is required as psychiatric and antiepileptic drugs can cause similar features.¹¹ EEG is helpful in diagnosing non-convulsive status epilepticus, or in distinguishing seizures (e.g. epilepsia partialis continua (EPC)) from a movement disorder. NMDA-R encephalitis may be associated with characteristic extreme delta brush pattern (figure 1 C).

Antibody testing for encephalitis is a rapidly evolving area of neuroimmunology. Certain autoimmune encephalitides, particularly those associated with NMDA-R and LGI1 antibodies, present with recognisable clinical syndromes and diagnostic suspicion may already be high so that antibody testing can be targeted. In other cases without distinguishing features, testing for a wider range of antibodies may be necessary, in consultation with a neurologist and neuroimmunology laboratory. Panels of immunofluorescence tests have been developed commercially and their role is still evolving, considering the balance between increased chance of detecting a pathogenic antibody versus the potential for false positives. Antibodies have hitherto mostly been tested in serum. However, intrathecal antibody synthesis occurs in most forms of AE and, particularly for NMDA-R antibodies, CSF testing is more sensitive and specific than serum and should be undertaken where clinical suspicion is high and in challenging cases.

Consensus criteria also allow for a diagnosis of ‘**seronegative AE**’, based on clinical features in the absence of antibodies which may respond to immune therapy.^{6,12} (box 1)

1
2
3 Because of the paraneoplastic associations of several antibodies, **investigation for malignancy** is crucial. Computed tomography of the chest, abdomen, and pelvis is
4 indicated in all patients with suspected AE. For those with particular associations,
5 such as GABA_BR, positron emission tomography scanning is advised and, if
6 negative, should be repeated at 3-6 months.¹³ Additionally, in NMDA-R encephalitis,
7 because of the association with teratoma, ultrasound of the ovaries or testes should
8 be performed.
9
10
11
12
13

14 **4. Management and outcome**

16 Evidence for optimal management of AE is largely based on retrospective studies,
17 together with principles adapted from other antibody mediated diseases, e.g.
18 myasthenia gravis. Patients with encephalitis should be managed at a centre with
19 appropriate facilities and specialist expertise, ideally a regional neuroscience centre.
20
21

22 **First line therapy**, aimed at reducing antibody levels rapidly, normally comprises
23 intravenous corticosteroids often in combination with intravenous immunoglobulin or
24 plasma exchange. In those who fail to respond, more aggressive immune therapy is
25 usually started, with concomitant higher risk of adverse effects, including
26 cyclophosphamide or rituximab.¹⁴ In NMDA-R encephalitis other agents such as
27 bortezomib have been used in a small number of refractory cases. Relapses may
28 occur when immune therapy is reduced, or may reflect tumour recurrence or
29 persistence of missed tumour.¹⁵
30
31

32 Starting immune therapy early has been associated with improved outcome in
33 **NMDA-R encephalitis** in retrospective series. Also, in those who fail to respond to
34 first-line therapy, moving to more aggressive second line treatments is associated
35 with better outcome and reduced rate of relapse.¹⁶ In patients with ovarian teratoma,
36 tumour resection is associated with faster rate of recovery and reduced relapse
37 rate.¹⁶
38
39

40 **LGI1 encephalitis** generally responds well to first-line treatment, particularly
41 corticosteroids, and outcomes are generally good, however, in the long-term
42 cognitive problems are common.^{17,18}
43
44

45 Patients with autoimmune encephalitis often require extensive **supportive care**,
46 including prolonged intensive care unit stays. Issues may include managing
47 seizures, autonomic instability, infective complications, and agitation. Antipsychotic
48 medications may be required, but should be used with caution due to the risk of
49 extrapyramidal side effects or neuroleptic malignant syndrome, which may be higher
50 in NMDA-R encephalitis.¹⁹
51
52

53 With appropriate treatment, **outcome** overall compares favourably with infectious
54 encephalitis, with >80% of patients with NMDA-R encephalitis having no more than
55 slight disability (modified Rankin Scale 2) at 2 years.¹⁶ However, evidence is
56 emerging that subtle neurocognitive/psychosocial issues may be more prevalent
57 than previously appreciated.²⁰ Support from psychology/counselling services and
58 charitable groups, such as the Encephalitis Society, is vital in the recovery phase.
59
60

5. Conclusions

It is increasingly possible to make a positive diagnosis of AE given consensus clinical criteria and increased availability of antibody tests. However, this relies on a high index of suspicion, especially in those presenting with primarily psychiatric features. The diagnosis is often supported by the development of 'neurological' features, such as movement disorders and seizures, laboratory tests, and MRI, but these may be normal in some. Antibody testing should be organised in consultation with a neurologist and neuroimmunology laboratory, with a pragmatic strategy based on careful clinical assessment. Even in the absence of antibodies, it may be possible to make a syndromic diagnosis.

Many with AE have a good outcome with early immune therapy, tumour resection if needed, and supportive care. Randomised controlled trials are needed to guide treatment strategies.

Key points

Autoimmune encephalitis should be a key part of the differential diagnosis in patients with alterations in cognition, consciousness, personality, or behaviour.

Antibody testing should be guided by recognisable clinical syndromes, but also should account for the expanding numbers of recognised antibodies and overlapping phenotypes.

Autoimmune encephalitis may present sub-acutely with normal or subtly abnormal CSF findings and neuroimaging.

Despite severe symptoms and long ITU stays, the outcome of AE is good in most cases if early immune therapy is given.

The optimum first and second line treatment strategy for AE is unclear and well-designed clinical trials are needed.

Key words

Neuroimmunology, encephalitis, autoimmunity, NMDA-R encephalitis, limbic encephalitis.

1
2
3
4
5
6
7
8
9
10
11
12
13
14
15
16
17
18
19
20
21
22
23
24
25
26
27
28
29
30
31
32
33
34
35
36
37
38
39
40
41
42
43
44
45
46
47
48
49
50
51
52
53
54
55
56
57
58
59
60

For Review Only

Self-assessment questions

1. A 72 year old man presented with a 3 month history of gradually worsening memory difficulties and unusual behaviour, including emotional lability. Family had noticed some jerky movements of his left arm and face on a few occasions over the preceding three weeks. On examination he was alert but distracted and his mini mental state examination (MMSE) score was 9/30. MRI brain showed age-appropriate brain atrophy with T2 signal hyperintensity in the right medial temporal lobe. CSF showed white cell count of $8/\text{mm}^3$ (normal range <5), protein of 0.7 g/L (normal <0.5) with normal glucose ratio. Which antibody is most likely to be found in association with this presentation?

- A. AMPAR
- B. CASPR2
- C. GABA_BR
- D. LGI1
- E. NMDA-R

Answer: D.

The patient had limbic encephalitis, with typically prominent memory and cognitive problems with a subacute onset and inflammation in the medial temporal lobe. The most common antibody identified in this situation is LGI1, and the jerky movements seen by his family are suspicious for faciobrachial dystonic seizures which may be pathognomonic for this disorder.

2. A 23 year old woman was referred from the psychiatric hospital for assessment of suspected seizures and hyperthermia. She had been an inpatient there for 6 weeks receiving treatment for a first episode of psychosis with neuroleptic medications. On clinical examination she was drowsy, had writhing movements of her left hand and was repeatedly protruding her tongue. Her temperature was 38.2°C and heart rate was 135. MRI brain was normal and CSF showed white cell count of 35 (normal range <5), protein of 0.4 g/L (normal range <0.5). CT scan of the chest, abdomen and pelvis revealed an ovarian mass. What is the most likely diagnosis?

- A. Juvenile myoclonic epilepsy
- B. LGI1 encephalitis
- C. NMDA-R encephalitis
- D. Primary psychiatric diagnosis

1
2
3 E. Tardive dyskinesia
4
5
6

7 **Answer: C**
8

9 The combination of psychiatric features with autonomic instability, movement
10 disorder and encephalopathy is characteristic of NMDA-R encephalitis. The
11 presence of CSF pleocytosis, and an ovarian mass (most likely a teratoma) is also
12 supportive, and the mass should be resected urgently. MRI brain is frequently
13 normal in AE. Juvenile myoclonic epilepsy presents with myoclonus (which are not
14 writhing movements) and generalised seizures. LGI1 encephalitis causes a limbic
15 encephalitis, usually in older adults. Tardive dyskinesia would be unusual after only a
16 few weeks of treatment and does not explain the addition features.
17
18
19

20
21 3. A 52 year old woman, previously fit and well, presented to the emergency
22 department with a 4 day history of flu-like illness and increasing drowsiness, with a
23 single generalised tonic-clonic seizure. Her family reported that she had been
24 agitated and aggressive when rousable. On examination her Glasgow coma scale
25 (GCS) score was 10 (E3, V2, M5), she was moving all four limbs. CT brain showed
26 subtle diffuse hypodensity in bilateral medial temporal lobes of uncertain aetiology,
27 more prominent on the left. What is the most appropriate initial management?
28
29

- 30 A. Intravenous alteplase
31
32 B. Intravenous corticosteroids
33
34 C. Intravenous immunoglobulin
35
36 D. Plasma exchange
37
38 E. Intravenous aciclovir
39
40
41

42 **Answer: E**
43

44 In a patient with acute decrease in conscious level and seizures, infectious
45 encephalitis (most commonly HSV encephalitis in the UK) is the most important
46 diagnosis to rule out. Lumbar puncture (LP) should be performed urgently, and
47 intravenous aciclovir (which decreases morbidity and mortality) should be given
48 either immediately after the LP, or before if LP is delayed for any reason.
49
50
51
52
53
54
55
56
57
58
59
60

1. Granerod J, Ambrose HE, Davies NW, et al. Causes of encephalitis and differences in their clinical presentations in England: a multicentre, population-based prospective study. *The Lancet. Infectious diseases* 2010;10:835-44.
2. Granerod J, Cousens S, Davies NW, et al. New estimates of incidence of encephalitis in England. *Emerg Infect Dis* 2013;19.
3. Irani SR, Michell AW, Lang B, et al. Faciobrachial dystonic seizures precede Lgi1 antibody limbic encephalitis. *Annals of neurology* 2011;69:892-900.
4. O'Sullivan BJ, Steele T, Ellul MA, et al. When should we test for voltage-gated potassium channel complex antibodies? A retrospective case control study. *Journal of clinical neuroscience : official journal of the Neurosurgical Society of Australasia* 2016;33:198-204.
5. van Sonderen A, Schreurs MW, Wirtz PW, et al. From VGKC to LGI1 and Caspr2 encephalitis: The evolution of a disease entity over time. *Autoimmun Rev* 2016;15:970-4.
6. Graus F, Titulaer MJ, Balu R, et al. A clinical approach to diagnosis of autoimmune encephalitis. *Lancet Neurol* 2016;15:391-404.
7. Armangue T, Spatola M, Vlasea A, et al. Frequency, symptoms, risk factors, and outcomes of autoimmune encephalitis after herpes simplex encephalitis: a prospective observational study and retrospective analysis. *Lancet Neurol* 2018.
8. Pollak TA, Lennox BR, Muller S, et al. Autoimmune psychosis: an international consensus on an approach to the diagnosis and management of psychosis of suspected autoimmune origin. *Lancet Psychiatry* 2020;7:93-108.
9. Dubey D, Pittock SJ, Kelly CR, et al. Autoimmune encephalitis epidemiology and a comparison to infectious encephalitis. *Annals of neurology* 2018;83:166-77.
10. Baumgartner A, Rauer S, Mader I, et al. Cerebral FDG-PET and MRI findings in autoimmune limbic encephalitis: correlation with autoantibody types. *Journal of neurology* 2013;260:2744-53.
11. Venkatesan A, Michael BD, Probasco JC, et al. Acute encephalitis in immunocompetent adults. *Lancet* 2019;393:702-16.
12. Graus F, Escudero D, Oleaga L, et al. Syndrome and outcome of antibody-negative limbic encephalitis. *European journal of neurology : the official journal of the European Federation of Neurological Societies* 2018;25:1011-6.
13. Titulaer MJ, Soffietti R, Dalmau J, et al. Screening for tumours in paraneoplastic syndromes: report of an EFNS task force. *European journal of neurology : the official journal of the European Federation of Neurological Societies* 2011;18:19-e3.
14. Nosadini M, Mohammad SS, Ramanathan S, et al. Immune therapy in autoimmune encephalitis: a systematic review. *Expert review of neurotherapeutics* 2015;15:1391-419.
15. Dalmau J, Graus F. Antibody-Mediated Encephalitis. *The New England journal of medicine* 2018;378:840-51.
16. Titulaer MJ, McCracken L, Gabilondo I, et al. Treatment and prognostic factors for long-term outcome in patients with anti-NMDA receptor encephalitis: an observational cohort study. *Lancet Neurol* 2013;12:157-65.
17. Irani SR, Gelfand JM, Bettcher BM, et al. Effect of rituximab in patients with leucine-rich, glioma-inactivated 1 antibody-associated encephalopathy. *JAMA neurology* 2014;71:896-900.
18. Arino H, Armangue T, Petit-Pedrol M, et al. Anti-LGI1-associated cognitive impairment: Presentation and long-term outcome. *Neurology* 2016;87:759-65.
19. Lejoste F, Thomas L, Picard G, et al. Neuroleptic intolerance in patients with anti-NMDAR encephalitis. *Neurol Neuroimmunol Neuroinflamm* 2016;3:e280.
20. Yeshokumar AK, Gordon-Lipkin E, Arenivas A, et al. Neurobehavioral outcomes in autoimmune encephalitis. *J Neuroimmunol* 2017;312:8-14.

Table 1. Key features of syndromes associated with neuronal surface antibodies

Antibody	Demographics		Key distinguishing features	Tumour associations
	Age predominance	F:M ratio		
NMDAR	Children Adults <40 years	4:1	Psychiatric features followed by movement disorder (classically orofacial dyskinesia), seizures, encephalopathy and autonomic dysfunction	About 50% of female patients have ovarian teratoma. Other tumour associations have been described
LGI1	Older adults	1:2	Faciobrachial dystonic seizures, amnesia, hyponatraemia	<10% Breast, lymphoma, thymoma, thyroid
CASPR2	Older adults	1:9	Sleep disorders (insomnia, sleep-wake cycle disturbance), peripheral nerve hyperexcitability, ataxia	<5%, various tumours
GABA_AR	Children or adults	1:1	Seizures	Thymoma in 30%
GABA_BR	Older adults	1:1.5	Seizures, amnesia	SCLC in 50%
AMPA	Older adults	2:1	Amnesia	65% Breast, SCLC, thymoma
DPPX	Adults	1:2	Severe diarrhoea and weight loss, myoclonus, hyperekplexia	<10% Lymphoma

NMDAR = *N*-methyl -aspartate receptor; **LGI1** = leucine rich glioma inactivated-1; **CASPR2** = contactin-associated protein-like 2; **GABA_AR** = γ -aminobutyric acid type A receptor; **GABA_BR** = γ -aminobutyric acid type B receptor; **AMPA** = α -amino-3-hydroxy-5-methyl-4-isoxazolepropionic acid receptor; **DPPX** = dipeptidyl-peptidase-like protein 6; **SCLC** = small cell lung cancer.

Box 1. Diagnostic criteria for possible autoimmune encephalitis ⁶

Diagnosis can be made when all three of the following criteria have been met:

1. Subacute onset (rapid progression of less than three months) of working memory deficits (short-term memory loss), altered mental status, or psychiatric symptoms.
2. At least one of the following:
 - New focal CNS findings
 - Seizures not explained by a previously known seizure disorder
 - CSF pleocytosis
 - MRI features suggestive of encephalitis
3. Reasonable exclusion of alternative causes (e.g. HSV encephalitis).

CNS = central nervous symptoms; CSF = cerebrospinal fluid; MRI = magnetic resonance imaging.

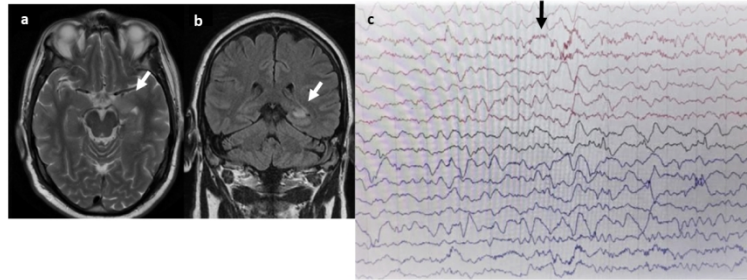


Figure 1. Imaging and EEG findings

- a) T2 weighted axial MRI of 55 year old male with LGI-1 antibody encephalitis showing high signal in left medial temporal lobe.
b) Coronal T2 FLAIR from same patient showing high signal in the left medial temporal lobe.
c) EEG of patient with NMDAR antibody encephalitis showing characteristic finding of extreme delta brush.

- a) T2 weighted axial MRI of 55 year old male with LGI-1 antibody encephalitis showing high signal in the left medial temporal lobe. b) Coronal T2 FLAIR from the same patient showing high signal in the left medial temporal lobe. c) EEG of a patient with NMDA-R antibody encephalitis showing the characteristic finding of extreme delta brush