



Citation for published version:

Merle, C, Innmann, M, Waldstein, W, Pegg, E, Aldinger, PR, Gill, H, Murray, DW & Grammatopoulos, G 2019, 'High Variability of Acetabular Offset in Primary Hip Osteoarthritis Influences Acetabular Reaming—A Computed Tomography–Based Anatomic Study', *Journal of Arthroplasty*, vol. 34, no. 8, pp. 1808-1814.
<https://doi.org/10.1016/j.arth.2019.03.065>

DOI:

[10.1016/j.arth.2019.03.065](https://doi.org/10.1016/j.arth.2019.03.065)

Publication date:

2019

Document Version

Peer reviewed version

[Link to publication](#)

Publisher Rights

CC BY-NC-ND

University of Bath

General rights

Copyright and moral rights for the publications made accessible in the public portal are retained by the authors and/or other copyright owners and it is a condition of accessing publications that users recognise and abide by the legal requirements associated with these rights.

Take down policy

If you believe that this document breaches copyright please contact us providing details, and we will remove access to the work immediately and investigate your claim.

High Variability of Acetabular Offset in Primary Hip Osteoarthritis Influences Acetabular Reaming — A Computed Tomography – Based Anatomic Study

Christian Merle ^{a*}, Moritz M. Innmann ^a, Wenzel Waldstein ^b, Elise C. Pegg ^c, Peter R. Aldinger ^d, Harinderjit S. Gill ^c, David W. Murray ^e, George Grammatopoulos ^f

^a Department of Orthopaedic and Trauma Surgery, University Hospital Heidelberg, Heidelberg, Germany

^b Department of Orthopaedic and Trauma Surgery AKH, University of Vienna, Vienna, Austria

^c Department of Mechanical Engineering, University of Bath, Bath, UK

^d Department of Orthopaedic Surgery, Paulinenhilfe, Diakonieklinikum, Stuttgart, Germany

^e Nuffield Department of Orthopaedics, Rheumatology and Musculoskeletal Sciences, University of Oxford, Oxford, UK

^f The Ottawa Hospital, University of Ottawa, Ottawa, Ontario, Canada

* Reprint requests: Christian Merle, MD, MSc, Department of Orthopaedic and Trauma Surgery, University Hospital Heidelberg, Schlierbacher Landstr. 200 A, 68118 Heidelberg, Germany.

One or more of the authors of this paper have disclosed potential or pertinent conflicts of interest, which may include receipt of payment, either direct or indirect, institutional support, or association with an entity in the biomedical field which may be perceived to have potential conflict of interest with this work. For full disclosure statements refer to <https://doi.org/10.1016/j.arth.2019.03.065>.

Abstract

Background

The objectives of the present study were to (1) evaluate the accuracy and reliability of native acetabular offset (AO) measurements performed on conventional supine anterior-posterior (ap) pelvis radiographs with reference to computed tomography (CT) in patients with end-stage hip osteoarthritis (OA); (2) determine the minimum and maximum amount of medialization of the center of rotation (COR) simulating different reaming techniques for acetabular preparation; and (3) identify patients at increased risk of excessive medialization of the COR.

Methods

A consecutive series of corresponding 131 CT scans and radiographs of patients with primary hip OA was evaluated using validated software for three-dimensional measurements. Acetabular and femoral parameters were evaluated. We simulated the implantation of a hemispherical press-fit cup comparing anatomic and conventional reaming techniques and assessed corresponding changes in AO. A medialization greater than 8 mm was considered as clinically relevant.

Results

Standardized ap pelvis radiographs allowed for an accurate and reliable assessment of AO compared with CT-based measurements. Cup placement in the most lateral position (anatomic reaming technique) resulted in a mean implant-related medialization of 5.9 ± 3.4 mm. On average, the most medial aspect of the cup remained at the level of the acetabular “true floor”; however, anatomic cup placement did not require reaming to the true floor in 64 hips (49%). With the conventional reaming technique, the total medialization of the COR (implant-related and reaming-related) was 6.8 ± 2.9 , with 34% of cases having a medialization ≥ 8 mm. There was no difference in the number of patients with high femoral offset and Dorr type A femora at high risk for excessive reaming between anatomic (16%) and conventional (24%) reaming.

Conclusion

The present study quantifies potential changes of native COR with different acetabular reaming techniques and highlights the variability of acetabular anatomy in patients with primary OA. AO can be accurately and reliably determined on conventional ap pelvis radiographs and appears to be independent of femoral shape or geometry. Depending on the preferred reaming technique a substantial number of patients appear at risk for excessive cup medialization. The present findings support the use of preoperative AO assessment and templating to improve individual restoration of hip offset in patients with primary hip OA.

Keywords: hip; osteoarthritis; arthroplasty; offset; reaming

Introduction

In total hip arthroplasty (THA), the restoration of hip offset (HO), which is defined as the sum of acetabular offset (AO) and femoral offset (FO) [1] (Fig. 1), determines abductor muscle function [2] and is considered essential to prevent adverse events such as impingement [3], dislocation [4], and excessive wear [5]. Accurate and reliable assessment of HO is crucial during preoperative templating as it guides for selection of an appropriate implant design, size, and position. A number of studies have investigated the radiographic assessment of FO in healthy and degenerative hips on both radiographs and computed tomography (CT) scans [6,7], but less attention has been paid to the assessment of AO and its relevance for acetabular preparation and cup placement. It has previously been demonstrated that FO is significantly underestimated on anteroposterior (AP) pelvis radiographs [7], but it remains unclear whether AO is accurately and reliably assessed on AP pelvis radiographs.

The major difference between the native acetabulum and a hemispheric cup design is that the native acetabulum is not hemispherical; its rim has an irregular succession of valleys and troughs and typically has a mean subtended angle of less than 180°, representing less than a hemisphere [8–10]. Consequently, in the majority of hips, the center of rotation (COR) will be medialized when a hemispherical cup is implanted to achieve secure press fit and sufficient bony coverage without overhang [10] of the acetabular component (implant-related medialization). Additionally, the extent of further medialization of the COR is influenced by the surgeon's preferred reaming technique [11] (reaming-related medialization). Whereas, some surgeons believe that the reaming in the transverse plane should at least extend to the lateral lamina ("true floor") of the acetabular fossa (conventional reaming technique), others prefer to ream just enough to get circumferential bony cup coverage (anatomic reaming technique), ensuring there is no component overhang, especially anteriorly over the psoas valley. The anatomic technique, which only relates to implant-related medialization, has been associated with less medialization of the COR as shown in both CT-based modeling [11,12] studies of healthy hips and in radiographic *in vivo* studies [13].

Excessive medialization of the COR may increase the risk of bony impingement and abductor muscle weakness [12,14], potentially compromising the clinical outcome as HO may not be fully restored, even by increasing FO with a high offset femoral component. This occurs if the AO is reduced by a greater amount than the maximum possible increase in FO. The ability to adjust FO is highly dependent upon the offset options of the femoral component and the individual FO and endosteal canal shape of the proximal femur; patients with high FO and Dorr type A femora are potentially at risk for underreconstruction of HO, particularly when an uncemented implant is used [15]. While previous modeling studies have characterized the effect of reaming on AO, they did not assess the associated femoral morphology. It is, therefore, of relevance to determine whether the hips at increased risk of AO reduction have specific femoral canal shapes to accommodate for a femoral implant that increases native FO thereby preventing an overall reduction in HO.

The objectives of the present study were to (1) evaluate the accuracy and reliability of native AO measurements performed on conventional supine AP pelvis radiographs with reference to CT in patients with end-stage primary hip osteoarthritis (OA); (2) determine the minimum (anatomic reaming technique and implant-related medialization) and maximum (conventional reaming technique, implant-related medialization, and reaming-related medialization) amount of COR medialization by simulating cup placement using a CT-based model; and (3) identify what proportion of patients may be at increased risk of excessive COR medialization with potential inability to fully restore HO.

Methods

Study Cohort

In this institutional review board approved study (reference S-272/2009), a retrospective review of an institutional database was performed.

A consecutive series of 131 patients who had undergone cementless THA for end-stage primary hip OA between January and December 2009 formed the study cohort [16]. The majority were females ($n = 74$, 56%), the mean age at THA was 60 years (range: 42-79), and the mean BMI was 27 (range: 12-45) (Table 1). All patients received a cementless custom-made titanium femoral component. The stem was manufactured based on standardized preoperative CT scans of the affected hip. All patients had given informed consent for the CT scan with the understanding that the CT scan would be obtained for manufacturing the femoral component but would not likely alter the planned THA treatment. Clinical

results of this individual femoral component have been previously reported [17]. Inclusion criteria for study participation were the presence of end-stage primary hip OA and adequate quality radiographs and CT scans for radiographic assessment. Criteria for exclusion included history of trauma, infection, rheumatic disease, hip dysplasia, previous pelvic and/or femoral osteotomy, avascular necrosis of the femoral head, Legg-Calvé-Perthes disease, or slipped capital femoral epiphysis. To identify patients with hip dysplasia, exclusion criteria were defined as a center-edge angle <20 degrees [18], an acetabular angle >42 degrees [19], and an acetabular index of depth to width $<38\%$ [20]. This study cohort has previously been investigated demonstrating that the native bony anatomy of the acetabulum in primary hip OA can be used as landmark for intraoperative cup orientation [16].

Imaging Protocols

Preoperatively, all patients received standardized digital anterior-posterior (ap) pelvis radiographs and CT scans of the affected hip stored in DICOM format. Patients in whom THA was performed bilaterally during the study period were only included for the first procedure side. Details of the standardized protocols for ap pelvis radiographs and CT scans have been previously reported [7]. In brief, low-centered ap pelvis radiographs were taken in a supine position. To correct for effects of magnification, a metal calibration sphere of 25 mm was positioned on the inner thigh at the ap level of the femoral head. The crosshair of the beam was centered on the pubic symphysis and both legs were internally rotated by 15 degrees using a foot retainer. The tube-to-film distance was 1150 mm, with the tube orientation perpendicular to the table. During the study period, 2 X-ray tubes were used: Canon CXDI series (Canon Inc., Tokyo, Japan) and Philips Bucky Diagnost VE VT (Royal Philips Electronics Inc., Amsterdam, The Netherlands).

Corresponding hip CT scans were performed in all patients preoperatively using a Toshiba Aquilion 16 CT scanner (Toshiba Corp., Tokyo, Japan). Patients were positioned supine with legs retained in neutral rotation as confirmed by scout views. The following scans were obtained (1) from the cranial aspect of the acetabulum to below the lesser trochanter (slice spacing 4 mm) and (2) from below the lesser trochanter to a point 50 mm distally of the femoral isthmus (slice spacing 8 mm). All scans were recorded with gantry tilt 0° , 120 kV, and a field of view of 250 mm.

Radiographic and CT Measurements

Point-based measurements on calibrated ap pelvis radiographs were performed using a validated MATLAB program [7] (version 7.10; The MathWorks Inc, Natick, MA). All points were defined by manual location on the image and automatically saved. First the trans-teardrop line was located as horizontal reference between the distal aspects of the teardrops. A least squares-fit circle tool was used to define the femoral head diameter and the co-ordinates of the COR. On the femoral diaphysis, 2 points on the medial and lateral cortex 20 mm below the lesser trochanter and 2 points on the medial and lateral cortex at the level of the femoral isthmus were marked. The midpoints of these point pairs determined the proximal femoral shaft axis. The femoral shaft axis was defined by the centroid [21,22] and the center of the isthmus; FO was then calculated as the perpendicular distance from the femoral shaft axis to the center of the femoral head. To quantify variation in the endosteal shape of the proximal femur on ap hip radiographs [23], the radiographic canal flare index as described by Noble [24] and the canal-to-calcaneal ratio and morphological Dorr Type as described by Dorr [25] were calculated. In addition, canal flare indices of the medial and lateral cortex were calculated as ratio of the distances from the determined endosteal points perpendicular to the femoral shaft axis.

A second custom MATLAB program (version 7.10; The MathWorks Inc) was used to perform CT-based measurements. The program allowed to mark points from preselected axial CT slices and performed vector-based calculations in the three-dimensional (3D) co-ordinate system of the CT scanner [16]. To determine acetabular orientation, 5 equidistant CT slices were selected between the top and bottom of the femoral head in the transverse plane (Fig. 2). Thirty points (6 on each slice) defined the native lunata surface, 10 points (2 on each slice) defined the bony acetabular rim, and 30 points (6 on each slice) defined the femoral head. A sphere was fitted to the outline of the femoral head to determine the 3D femoral head center and diameter. Acetabular orientation was assessed by fitting a plane to the vertices along the rim, and a sphere was fitted to the native lunata surface to represent the COR. The diameter of the bony rim was calculated with a best fit circle fitted to the points on the vertices [9].

AO was calculated in the transverse plane at the level of the acetabular COR as the distance between the COR and the midpoint between the medial and lateral lamina of the acetabular floor. Similarly, the acetabular floor width (AFW) was defined as the distance between the medial and lateral lamina of the acetabular floor at the level of the acetabular COR. The subtended angle of the acetabulum was determined as mean angle between the COR and the vertices of the rim. Osteophytes related to the osteoarthritic process were differentiated from the underlying native bony anatomy based on the cortical outline of the outer lamina of the lunata fossa. HO was calculated as the sum of AO and FO.

We simulated the 3D press-fit implantation of a hemispheric cementless cup. The cup was anatomically oriented so that its anterior and posterior aspect were seated just below the native acetabular rim in line with the orientation of native acetabular anteversion as defined by the rim plane, ensuring that the cup was not extending laterally over the bony rim (Fig. 3). The cup diameter was chosen to match the level of the subchondral bone at the anterior and posterior wall to enable equatorial press-fit in the transverse plane. The implant-related medialization of the COR was calculated as the distance between the COR of the native acetabulum and the COR of the anatomically placed virtual cup. Additionally, the distance of the most medial cup aspect to the outer lamina of the acetabular floor ("true floor") and inner lamina of the acetabular floor were calculated and hence allowed for quantification of the implant- and reaming-related medialization of COR.

A medialization greater than 8 mm was considered as clinically relevant, as this represents the greatest difference possible between standard and high offset stems for the most commonly used stems in the National Joint Registry of England, Wales, Northern Ireland, and Island of Man [13].

Measurement Reliability and Accuracy

Intraobserver and interobserver reliabilities for 20 randomly selected patients were evaluated by 2 independent and blinded observers (one resident in orthopedic surgery, one consultant orthopedic surgeon specialized in hip arthroplasty) using single-measure intraclass-correlation coefficients (ICC) with a 2-way random effects model for absolute agreement. ICCs demonstrated a high interobserver and intraobserver reliability for all measured parameters (ICC range: 0.89-0.99). The standard deviation (SD) of the residuals for the sphere fits was 0.57 mm for the femoral head and 0.73 mm for the lunata surface. The SD of the residuals for the plane fit to the rim was 1.92 mm.

Statistical Analysis

For descriptive analysis, absolute mean values and differences were expressed in mm with SD. The distributions of variables were examined in exploratory data analysis and tested for normality using Kolmogorov-Smirnov tests. Differences of obtained values were compared using parametric and nonparametric testing as appropriate. Venn diagrams were used to illustrate the distribution of hips with regard to morphologic parameters. Spearman's correlation (r_s) was used to evaluate associations between continuous variables. Correlation was characterized as poor (0.00-0.20), fair (0.21-0.40), moderate (0.41-0.60), good (0.61-0.80), or excellent (0.81-1.00). Measurement agreement between corresponding radiographs and CT scans was assessed using Bland-Altman plots. Odds ratios (ORs) were calculated to compare the proportions of patients at risk. Results with P values < 0.05 were considered as statistically significant. Statistical analysis was carried out using PASW Statistics 18 (SPSS Inc, an IBM company, Chicago, IL).

Results

Acetabular Measurements

No difference in AO was seen on corresponding ap pelvis radiographs (33.9 ± 7.3 mm) and CT scans (33.7 ± 4.9 mm, $P = .829$). AO measurements on ap pelvis radiographs and CT showed a good correlation ($R = 0.74$, $P < .001$). Bland-Altman plotting illustrating the agreement between radiographs and CT scans are presented in Figure 4. Mean acetabular rim diameter was 54.2 ± 5.1 mm, and mean subtended angle was $156 \pm 13^\circ$. Mean AFW was 2.6 ± 1.3 mm and was significantly greater in males (3.2 ± 1.4 mm) than females (2.1 ± 0.8 mm, $P < .001$). There was no correlation between patient body mass index and measures of acetabular morphology ($P > .05$). Details for acetabular measurements are presented in Table 2.

Modeling of Cup Implantation

Using the anatomic reaming technique, the most medial aspect of the cup was on average placed at the level of the true floor (mean 0.1 mm lateral, SD: 2.2 mm, range: 7.8 mm lateral to 6.4 mm medial) to the outer lamina of the acetabular floor. Placing the cup in the anatomic position did not require reaming to the true floor in 64 cases (49%). Cup placement using the anatomic reaming technique would result in a mean implant-related medialization of the COR of 5.9 ± 3.4 mm, (range: 4.7 mm lateral to 17.5 mm medial), and in 31/131 (24%) patients, a medialization ≥ 8 mm was observed.

The mean reaming-related medialization of the COR simulating reaming to the lateral lamina of the acetabular floor ("true floor") was 0.9 ± 1.4 mm (range: 0 to 7.8 mm); simulating reaming to the medial lamina, it was 3.4 ± 3.5 mm (range: 0.9 to 8.8 mm). Therefore, the total medialization (implant-related and reaming-related) was 6.8 ± 2.9 mm (range: - 0.3 to 17.5 mm) for the conventional technique with reaming to the lateral lamina, with 45/131 patients (34%) having a medialization ≥ 8 mm; the total medialization (implant-related and reaming-related) was 9.4 ± 3.4 mm (range: 1.1 to 18.5 mm) for the conventional technique with reaming to the inner lamina, with 91/131 patients (69%) having a medialization ≥ 8 mm.

Femoral Measurements

There was a moderate correlation between acetabular and femoral offset as measured on CT scans ($R = 0.428$, $P < .001$). We could not detect any relevant association of femoral or acetabular offset with measures of endosteal femoral canal shape as represented by Dorr type, canal-to-calcar ratio, and canal flare index. In the entire cohort, 28/131 hips demonstrated a femoral morphology with high FO and Dorr type A canal shape. Details for femoral measurements are presented in Table 2.

There was no difference in the number of patients with either high FO or Dorr type A femora at risk for underreconstruction between anatomic reaming ($n = 21$, 16%) and reaming to the outer lamina ($n = 32$, 24%, OR 1.7, $P = .09$). Compared with anatomic reaming ($n = 21$, 16%), a significantly higher proportion of patients were at high risk for offset underreconstruction (OR 5.5, $P < .001$) with reaming to the inner lamina ($n = 67$, 51%). Details of the distribution of hips at risk for HO underreconstruction depending on the reaming technique are presented in Venn diagrams (Fig. 5 A- C).

Discussion

The present study demonstrates that native AO of patients with primary end-stage hip OA can be accurately and reliably determined on conventional AP pelvis radiographs. It also highlights the great variability of AO in patients with primary OA and quantifies the potential changes of the native COR that may occur during cup implantation with different reaming techniques. Cup positioning using an anatomic reaming technique was associated with the least reduction in AO; on average, reaming to the lateral lamina of the acetabular fossa ("true floor") did achieve anatomic positioning, but as a result of the high anatomic variation seen in the present cohort, it would also lead to a clinically relevant (≥ 8 mm) reduction of AO in 31% of the hips compared with 24% for the anatomic reaming technique. Even with anatomic cup positioning, AO was reduced by a mean of 6 mm in the present cohort (implant-related medialization). Depending on reaming practice and implant design, excessive medialization of the COR up to 19 mm was observed for individual patients, and owing to the proportion of patients at risk for excessive medialization, vigilant preoperative templating and extra caution when reaming past the outer lamina is recommended, particularly in patients with high AO and wide AFW. Furthermore, a preoperative assessment of the anticipated reduction in AO should be accompanied by an appropriate increase of the FO by choosing an appropriate femoral component. This is especially crucial as recent data have suggested that an underreconstruction of HO might result in lower functional improvement with the operation [15]. Hence, an accurate and reliable preoperative assessment is critical to avoid excessive medialization of the cup when reaming.

The present study clearly demonstrates that accurate and reliable templating can be achieved on calibrated AP pelvis radiographs and that there is no need to routinely perform CT scans for acetabular templating in patients with primary OA. This confirms previous findings that templating can be accurately performed on plain radiographs in patients with primary OA [7] and stands in contrast to other reports in the literature that favor CT-based preoperative planning even in cases without higher degree of deformities [26].

In contrast to previous studies evaluating AO and reaming techniques, the present study is the first to assess both acetabular and femoral (patho-) anatomy as both are equally relevant for adequate intraoperative restoration of HO. Interestingly, there was a high overall variability of the hip anatomy in both males and females in the present cohort, and measures of size and geometry of the hip joint and the proximal femur did not show any meaningful association. This finding implies that all possible combinations of hip geometry and endosteal femoral canal shape can be encountered in patients with primary hip OA and that consequently, femoral components with multiple offset options should be available to compensate for the highly variable amount of medialization of the COR that inevitably occurs during cup implantation.

The findings of the present study highlight that the restoration of HO cannot be limited to the concept of FO reconstruction; an anatomic reaming technique seems to be advantageous with regard to the restoration of AO. As medialization of the COR occurs inevitably during acetabular reaming, the amount of medialization of the COR must be related to the FO reconstruction. A cutoff of 8 mm was assumed to be of clinical relevance as it reflects the greatest difference possible between standard and high offset stems for the most commonly used stems in the National Joint Registry of England, Wales, Northern Ireland, and Island of Man [13]. The cutoff value is further supported by a recent study with CT-based 3D motion analysis [27] demonstrating that a change in the COR of ± 4 mm with the same stem offset had negative effects on hip range of motion owing to bony impingement. However, surgeons should be aware that the attempt to preserve acetabular bone stock may potentially compromise the cup fixation or lead to anterior component overhang increasing the risk of psoas irritation. In the literature, there is limited information on how much medialization is necessary to obtain enough press-fit and sufficient bone contact to allow for primary stability and secondary osteointegration of cementless cups. It has been demonstrated that a bony coverage of $>50\%$ [28] and a cup center-edge angle $>8^\circ$ [29] are acceptable in cementless acetabular reconstruction in patients with hip dysplasia. However, these results must be interpreted with caution as fixation is also dependent on individual bone biology and implant design features. The literature is also limited and ambiguous for the effect of offset reconstruction and cup placement on the joint reaction force and on polyethylene (PE) wear. While it is generally believed that cup medialization decreases the joint reaction force, reconstruction of FO within 5 mm has been associated with lower PE wear [30]. It is generally believed that the reconstruction of offset is essential to maintain abductor power, but in the literature, there is no sufficient evidence to define cut-off values for the complex biomechanical in vivo interaction between abductor lever arm and FO/AO reconstruction.

The reported values for AO changes in THA in the literature vary significantly. Bonnin et al [12] evaluated 100 CT-scans of healthy hips and found a mean AO of 30.8 mm. In this study, the medial shift of the COR was 1.6 mm with the anatomic and 4.8 mm with the conventional technique. Meermans et al [13] performed radiographic measurements and reported a lower mean cup medialization in a peripheral reaming group (0.8 mm) compared with a standard reaming group (5.0 mm).

The amount of medialization reported in the present study (5.9 mm with the anatomic technique) is higher than the abovementioned studies have suggested, and this may be attributed to the present study cohort comprised of patients with end-stage hip OA with degenerative bony alterations and different morphologies of arthritic hip pathoanatomy. We consider this as a particular strength of the present study as this is the first CT-based investigation of patients who were symptomatic and received a primary THA. A further strength is the additional evaluation of FO which is also highly variable and appears to be independent of acetabular morphology. This study, therefore, suggests that in patients with end-stage hip OA, restoration of HO might be more critical than expected given the fact that some surgeons, depending on experience, also tend to shift the COR superiorly [13,31], bib31 (Please correct citation) which can further compromise the overall reconstruction of HO. Great care must be taken during intraoperative reaming and the used reaming technique should be adapted to the individual (patho-) anatomy in primary OA.

This study has some limitations; first, it simulated the acetabular component placement in various depths ensuring equatorial fixation in the transverse plane and coverage at the level of maximum ap diameters. However, in vivo reaming depends on many patient-related factors (eg, bone quality, which influences the ability to obtain secure fixation). Second, only axial measurements were performed; recent work has highlighted that the reaming technique can also influence the COR in the coronal plane which was not assessed in the present study. Third, we assumed that all cups were hemispherical in nature, although certain cup designs (eg, resurfacings) are not hemispherical or have a flattened pole

area [32]. Fourth, we only simulated impaction of an uncemented hemispherical cup rather than cemented components; however, Wegner et al [33] showed no difference in the ability to restore COR with different acetabular component fixation modes. Finally, the present cohort comprised only patients with primary OA, so the findings may not be applicable to patients with secondary OA hips.

In summary, the present study shows that native AO of patients with primary end-stage hip OA can be accurately and reliably determined on conventional ap pelvis radiographs. AO is highly variable and independent of femoral geometry. Depending on the preferred reaming technique, a substantial number of patients appear at risk for excessive cup medialization. The present findings support the surgeon in preoperative templating and may improve individual restoration of HO in patients with primary hip OA.

Acknowledgements

Source of Funding: Financial support has been received from the nonprofit foundation Stiftung Endoprothetik, Hamburg, Germany.

References

- [1] M. Dastane, L.D. Dorr, R. Tarwala and Z. Wan, Hip offset in total hip arthroplasty: quantitative measurement with navigation, *Clin Orthop Relat Res* 469, 2011, 429 – 436.
- [2] I. Asayama, S. Chamnongkitch, K.J. Simpson, T.L. Kinsey and O.M. Mahoney, Reconstructed hip joint position and abductor muscle strength after total hip arthroplasty, *J Arthroplasty* 20, 2005, 414 – 420.
- [3] W.B. Kurtz, T.M. Ecker, W.M. Reichmann and S.B. Murphy, Factors affecting bony impingement in hip arthroplasty, *J Arthroplasty* 25, 2010, 624 – 634, e1-2.
- [4] C.D. Fackler and R. Poss, Dislocation in total hip arthroplasties, *Clin Orthop Relat Res* 151, 1980, 169 – 178.
- [5] D.P. Sakalkale, P.F. Sharkey, K. Eng, W.J. Hozack and R.H. Rothman, Effect of femoral component offset on polyethylene wear in total hip arthroplasty, *Clin Orthop Relat Res* 388, 2001, 125 – 134.
- [6] E. Sariali, A. Mouttet, G. Pasquier and E. Durante, Three-dimensional hip anatomy in osteoarthritis. Analysis of the femoral offset, *J Arthroplasty* 24, 2009, 990 – 997.
- [7] C. Merle, W. Waldstein, E. Pegg, M.R. Streit, T. Gotterbarm, P.R. Aldinger, et al., Femoral offset is underestimated on anteroposterior radiographs of the pelvis but accurately assessed on anteroposterior radiographs of the hip, *J Bone Joint Surg Br* 94, 2012, 477 – 482.
- [8] M.S. Thompson, T. Dawson, J.H. Kuiper, M.D. Northmore-Ball and K.E. Tanner, Acetabular morphology and resurfacing design, *J Biomech* 33, 2000, 1645 – 1653.
- [9] J. Cobb, K. Logishetty, K. Davda and F. Iranpour, Cams and pincer impingement are distinct, not mixed: the acetabular pathomorphology of femoroacetabular impingement, *Clin Orthop Relat Res* 468, 2010, 2143 – 2151.
- [10] E. Vandenbussche, M. Saffarini, F. Taillieu and C. Mutschler, The asymmetric profile of the acetabulum, *Clin Orthop Relat Res* 466, 2008, 417 – 423.
- [11] M.P. Bonnin, P.H. Archbold, L. Basigliani, M.H. Fessy and D.E. Beverland, Do we medialise the hip centre of rotation in total hip arthroplasty? Influence of acetabular offset and surgical technique, *Hip Int* 22, 2012, 371 – 378.
- [12] M.P. Bonnin, P.H. Archbold, L. Basigliani, T.A. Selmi and D.E. Beverland, Should the acetabular cup be medialised in total hip arthroplasty, *Hip Int* 21, 2011, 428 – 435.
- [13] G. Meermans, J.V. Doorn and J.J. Kats, Restoration of the centre of rotation in primary total hip arthroplasty: the influence of acetabular floor depth and reaming technique, *Bone Joint J* 98-B, 2016, 1597 – 1603.
- [14] A. Malik, A. Maheshwari and L.D. Dorr, Impingement with total hip replacement, *J Bone Joint Surg Am* 89, 2007, 1832 – 1842.
- [15] M.M. Innmann, M.W. Maier, M.R. Streit, G. Grammatopoulos, T. Bruckner, T. Gotterbarm, et al., Additive influence of hip offset and leg length reconstruction on postoperative improvement in clinical outcome after total hip arthroplasty, *J Arthroplasty* 33, 2018, 156 – 161.
- [16] C. Merle, G. Grammatopoulos, W. Waldstein, E. Pegg, H. Pandit, P.R. Aldinger, et al., Comparison of native anatomy with recommended safe component orientation in total hip arthroplasty for primary osteoarthritis, *J Bone Joint Surg Am* 95, 2013, e172.
- [17] M. Akbar, G. Aldinger, K. Krahmer, T. Bruckner and P.R. Aldinger, Custom stems for femoral deformity in patients less than 40 years of age: 70 hips followed for an average of 14 years, *Acta Orthop* 80, 2009, 420 – 425.

- [18] G. Wiberg, Shelf operation in congenital dysplasia of the acetabulum and in subluxation and dislocation of the hip, *J Bone Joint Surg Am* 35-A, 1953, 65 – 80.
- [19] I.K. Sharp, Acetabular dysplasia - the acetabular angle, *J Bone Joint Surg Br* 43, 1961, 268 – 272.
- [20] S.B. Murphy, R. Ganz and M.E. Muller, The prognosis in untreated dysplasia of the hip - a study of radiographic factors that predict the outcome, *J Bone Joint Surg Am* 77a, 1995, 985 – 989.
- [21] L. Billing, Roentgen examination of the proximal femur end in children and adolescents; a standardized technique also suitable for determination of the collum-, anteversion-, and epiphyseal angles; a study of slipped epiphysis and coxa plana, *Acta Radiol Suppl* 110, 1954, 1 – 80.
- [22] S.B. Murphy, S.R. Simon, P.K. Kijewski, R.H. Wilkinson and N.T. Griscom, Femoral anteversion, *J Bone Joint Surg Am* 69, 1987, 1169 – 1176.
- [23] C. Merle, W. Waldstein, J.S. Gregory, S.R. Goodyear, R.M. Aspden, P.R. Aldinger, et al., How many different types of femora are there in primary hip osteoarthritis? An active shape modeling study, *J Orthop Res* 32, 2014, 413 – 422.
- [24] P.C. Noble, J.W. Alexander, L.J. Lindahl, D.T. Yew, W.M. Granberry and H.S. Tullos, The anatomic basis of femoral component design, *Clin Orthop Relat Res* 235, 1988, 148 – 165.
- [25] L.D. Dorr, M.C. Faugere, A.M. Mackel, T.A. Gruen, B. Bogner and H.H. Malluche, Structural and cellular assessment of bone quality of proximal femur, *Bone* 14, 1993, 231 – 242.
- [26] E. Sariali, A. Mouttet, G. Pasquier, E. Durante and Y. Catone, Accuracy of reconstruction of the hip using computerised three-dimensional pre-operative planning and a cementless modular neck, *J Bone Joint Surg Br* 91, 2009, 333 – 340.
- [27] T. Shoji, T. Yamasaki, S. Izumi, M. Kenji, M. Sawa, Y. Yasunaga, et al., The effect of cup medialization and lateralization on hip range of motion in total hip arthroplasty, *Clin Biomech (Bristol, Avon)* 57, 2018, 121 – 128.
- [28] M. Fujii, Y. Nakashima, T. Nakamura, Y. Ito and T. Hara, Minimum lateral bone coverage required for securing fixation of cementless acetabular components in hip dysplasia, *Biomed Res Int* 2017, 2017, 4937151.
- [29] M. Takao, N. Nakamura, K. Ohzono, T. Sakai, T. Nishii and N. Sugano, The results of a press-fit-only technique for acetabular fixation in hip dysplasia, *J Arthroplasty* 26, 2011, 562 – 568.
- [30] N.J. Little, C.A. Busch, J.A. Gallagher, C.H. Rorabeck and R.B. Bourne, Acetabular polyethylene wear and acetabular inclination and femoral offset, *Clin Orthop Relat Res* 467, 2009, 2895 – 2900.
- [31] S.C. Kim, Y.W. Lim, S.Y. Kwon, W.L. Jo, S.H. Ju, C.J. Park, et al., Level of surgical experience is associated with change in hip center of rotation following cementless total hip arthroplasty: a radiographic assessment, *PLoS One* 12, 2017, e0178300.
- [32] M.R. Streit, S. Weiss, F. Andreas, T. Bruckner, T. Walker, J.P. Kretzer, et al., 10-year results of the uncemented Allofit press-fit cup in young patients, *Acta Orthop* 85, 2014, 368 – 374.
- [33] A. Wegner, M.D. Kauther, S. Landgraeber and M. von Knoch, Fixation method does not affect restoration of rotation center in hip replacements: a single-site retrospective study, *J Orthop Surg Res* 7, 2012, 25.

Figures

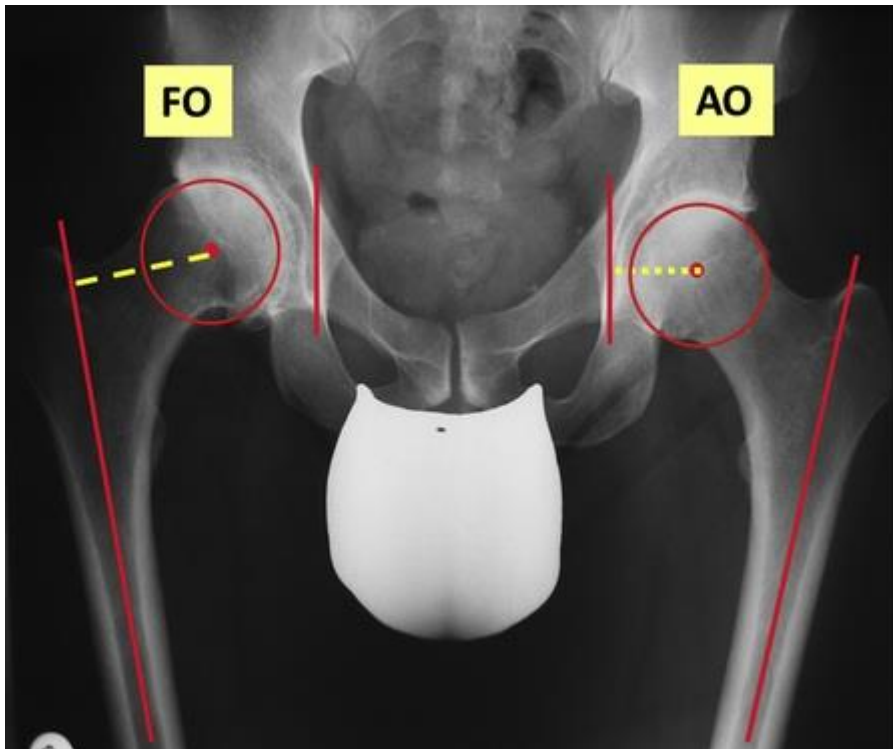


Fig. 1. AP pelvis radiograph. AO, acetabular offset; FO, femoral offset; AP, anteroposterior.

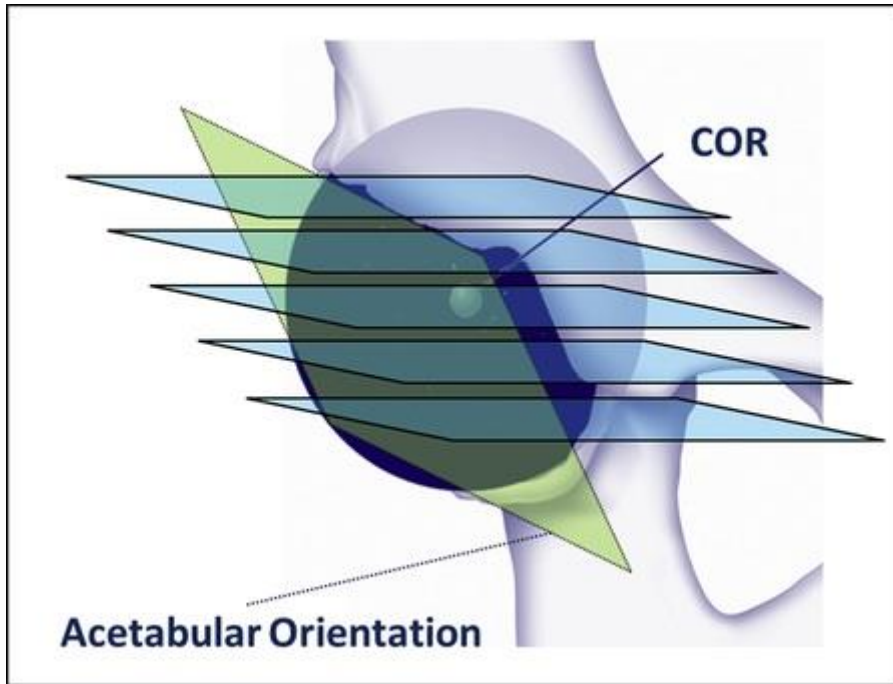


Fig. 2. Acetabular orientation as measured on CT. COR, center of rotation; CT, computed tomography.

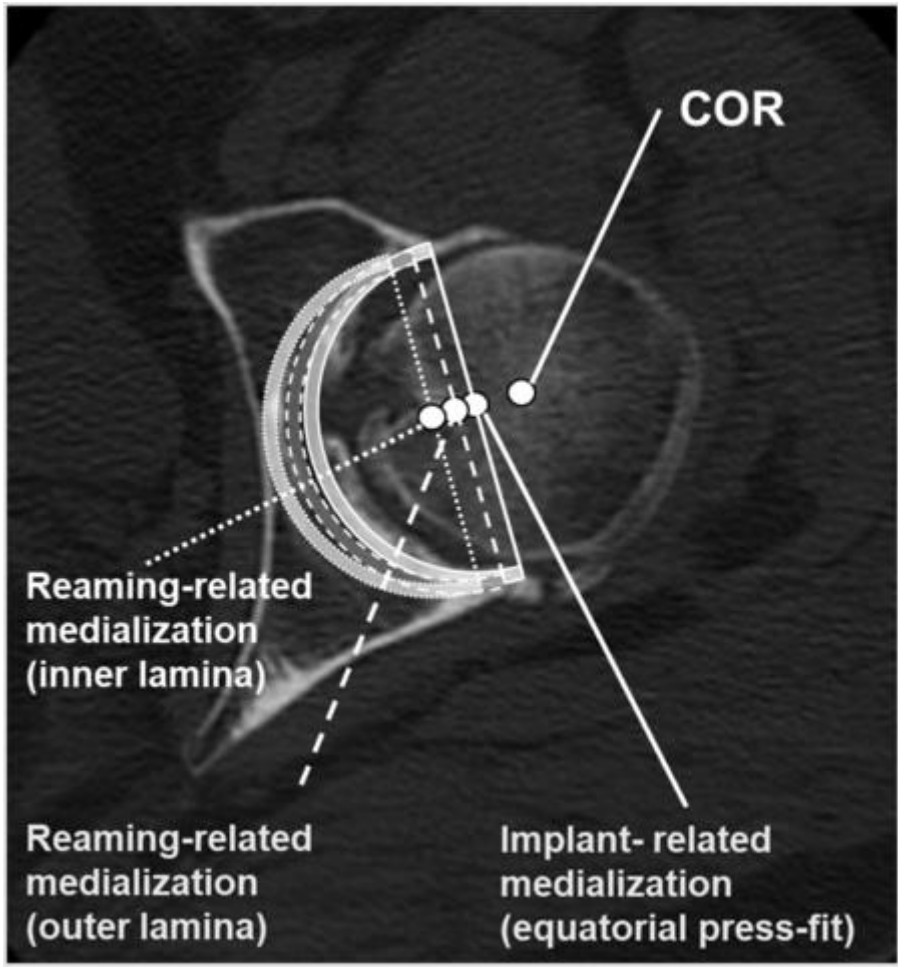


Fig. 3. CT-based cup simulation. AOp, AO measurements on ap pelvis radiographs; AOct, AO measurements on CT.

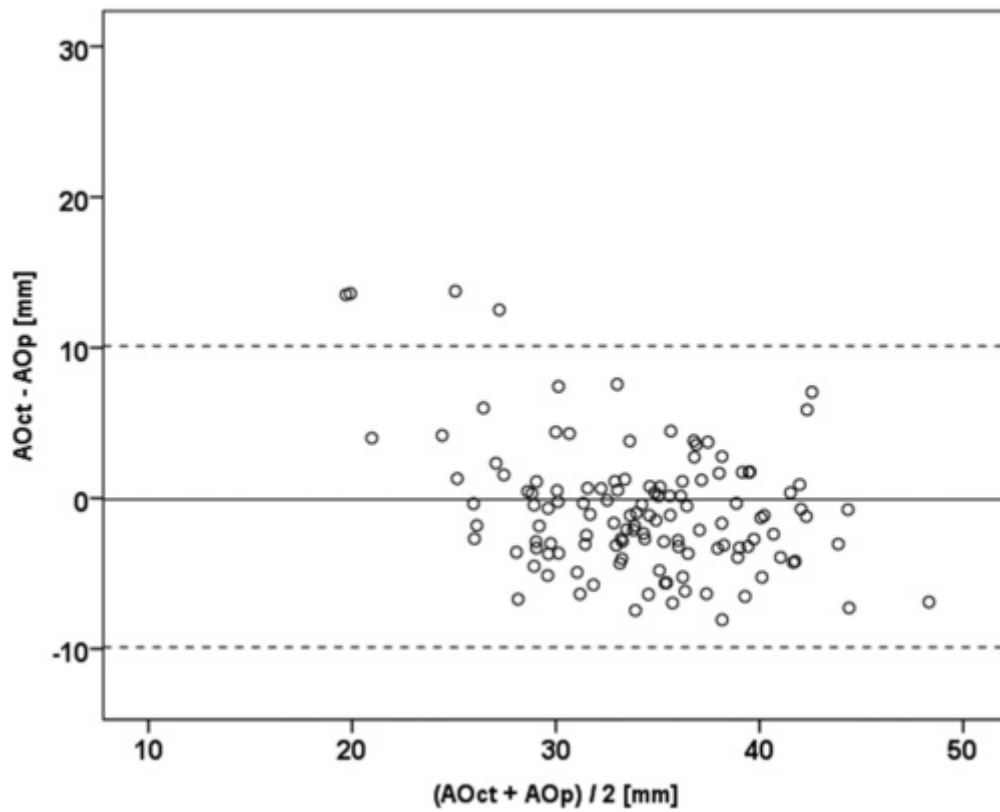


Fig. 4. Bland-Altman plot illustrating the agreement between CT (ct) and pelvis X-ray (p) acetabular offset measurements. The solid line represents the mean difference (-0.1 mm, 95% CI: -1.11 to 0.89 mm); dashed lines represent ± 1.96 SD borders. CI, confidence interval; SD, standard deviation.

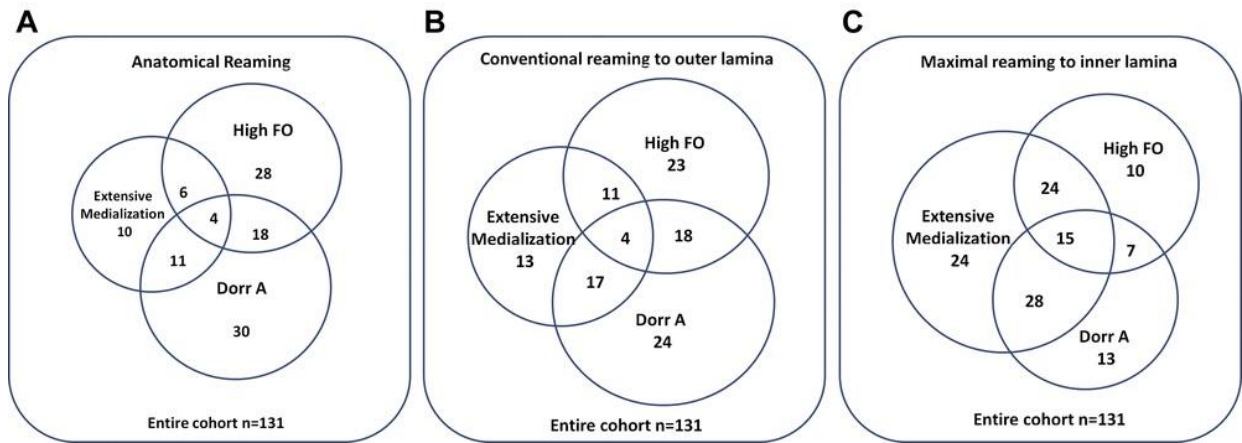


Fig. 5. Venn diagrams quantifying patients at risk for underreconstruction of hip offset, A: results for anatomical reaming technique; B: results for conventional reaming to the lateral lamina ("true floor"); C: results for reaming to the inner lamina.

Tables

Table 1. Study Cohort.

Demographic Parameter	Cohort (n=131)	Males (n=57)	Females (n=74)	P Value
Age (y)	60.3	59.8	60.6	.073
SD	7.49	7.37	7.61	
Range	42-79	43.72	42-79	
BMI [kg/m ²]	27.0	27.6	26.6	.603
SD	4.38	3.56	4.90	
Range	19.4-44.6	20.3-35.7	19.4-44.6	

BMI, body mass index; SD, standard deviation

Table 2. Acetabular and Femoral Measurements

Measurements	Cohort (n=131)	Males (n=57)	Females (n=74)	P Value
AO X-ray pelvis [mm]	33.9	37.4	31.3	<.001
SD	7.28	6.72	6.60	
Range	10.1-51.8	10.1-51.8	10.7-44.7	
AOct [mm]	33.8	36.9	31.4	<.001
SD	4.89	3.52	4.47	
Range	23.0-46.1	28.3-46.1	23.0-45.2	
Acetabular inclination ct [°]	62.0	61.9	62.0	.918
SD	7.48	6.64	8.12	
Range	30.2-75.7	37.1-75.7	30.2-75.6	
Acetabular version ct [°]	13.9	11.7	15.6	<.001
SD	5.80	5.21	5.70	
Range	2.8-31.7	2.8-23.3	3.0-31.7	
Acetabular subtended angle ct [°]	155.8	155.1	156.4	.638
SD	13.07	9.96	15.07	
Range	126.5-200.7	137.4-175.3	126.5-200.7	
Acetabular diameter ct [mm]	54.2	58.2	51.2	<.001
SD	5.72	4.43	4.65	
Range	41.3-73.6	49.8-73.6	41.3-72.4	
Floor with ct [mm]	2.6	3.3	2.1	<.001
SD	1.27	1.37	0.90	
Range	0.8-7.3	0.8-7.3	0.9-4.3	
FO ct[mm]	45.2	48.6	42.8	<.001
SD	5.82	5.48	4.72	
Range	30.9-66.2	40.2-66.4	30.9-61.0	
CCT X-ray	0.45	0.45	0.45	.744
SD	0.042	0.038	0.045	
Range	0.34-0.6	0.34-0.53	0.46-0.60	
CFI X-ray	4.0	4.0	4.0	.583
SD	0.39	0.38	0.40	
Range	2.9-5.5	3.5-5.5	2.9-4.8	

CT, computed tomography; AO, acetabular offset; SD, standard deviation; CFI, canal flare index; CCR, canal-to-calcar ratio; FO, femoral offset; AOct, AO measurements on CT.