



VCU

Virginia Commonwealth University
VCU Scholars Compass

Graduate Medical Education (GME) Resident
and Fellow Research Day Posters

VCU Health

2020

Hip Labral Injury Worsens After Platelet Rich Plasma Injections: A Case Report

Brennan M. Wright
Virginia Commonwealth University

Carmen Wong
Central Virginia VA Health Care System

Follow this and additional works at: https://scholarscompass.vcu.edu/gme_posters



Part of the [Sports Medicine Commons](#)

© The Author

Downloaded from

https://scholarscompass.vcu.edu/gme_posters/27

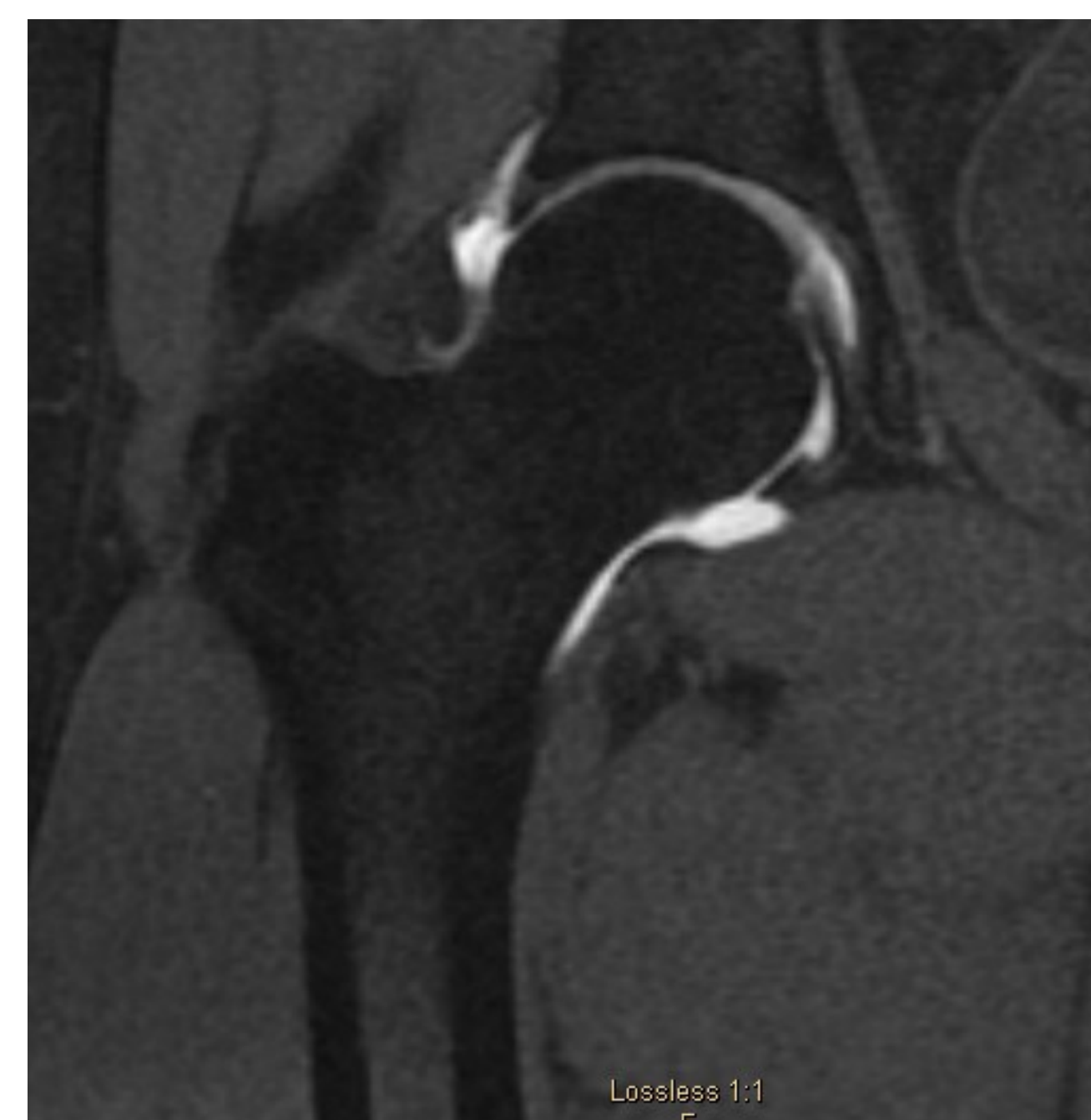This Clinical Case Reports is brought to you for free and open access by the VCU Health at VCU Scholars Compass. It has been accepted for inclusion in Graduate Medical Education (GME) Resident and Fellow Research Day Posters by an authorized administrator of VCU Scholars Compass. For more information, please contact libcompass@vcu.edu.

Hip Labral Injury Worsens After Platelet Rich Plasma Injections: A Case Report

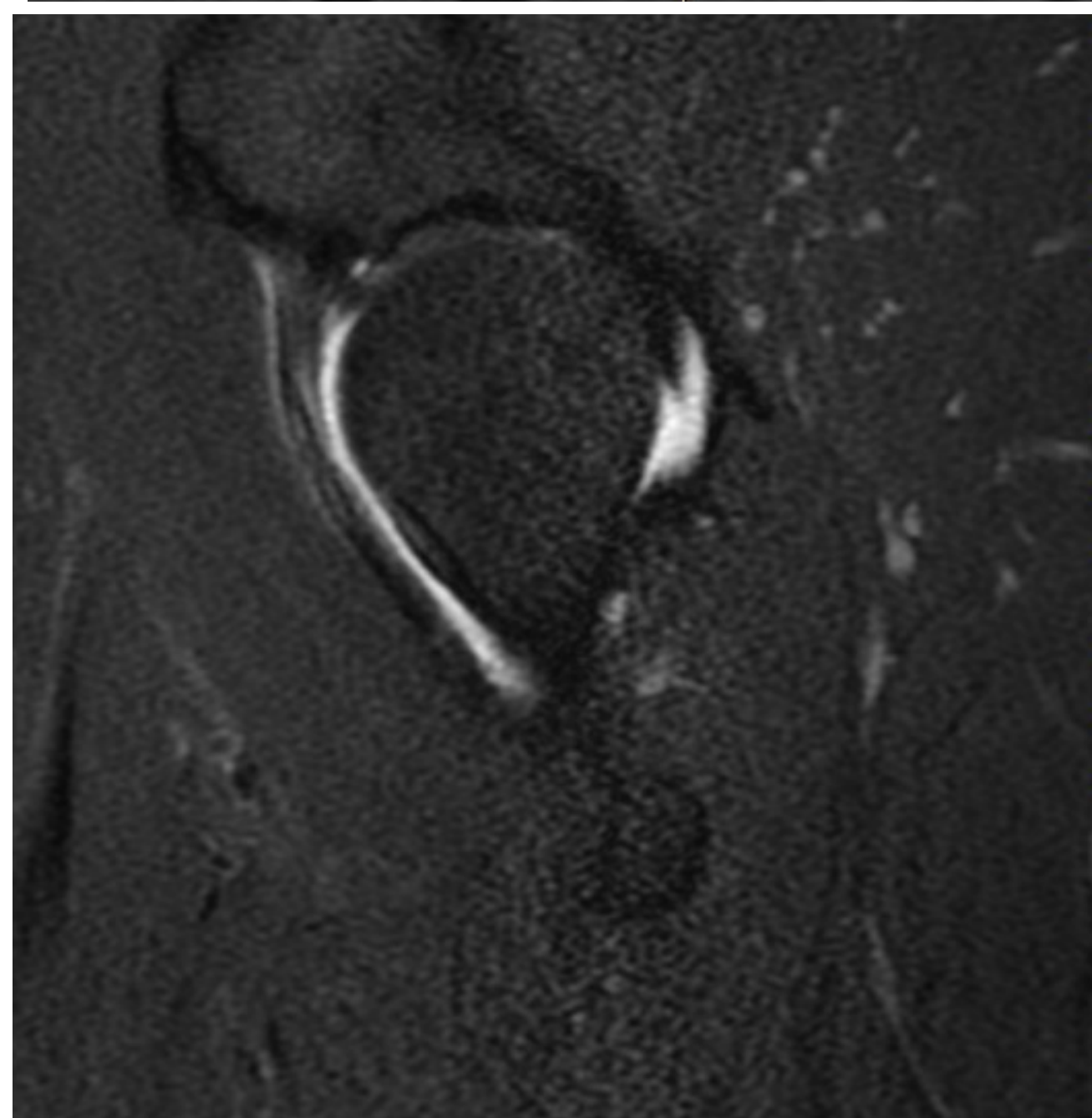
Authors: Brennan Wright, MD and Carmen Wong, MD

Case

A 47-year-old active male presented with 2.5 years of right hip pain suggestive of labral pathology. Ice, heat, celecoxib, ibuprofen, diclofenac gel, and physical therapy provided minimal relief. A diagnostic intra-articular bupivacaine injection resolved the pain. A subsequent MR arthrogram revealed a non-displaced tear of the right anterior superior acetabular labrum.



MRA prior to PRP

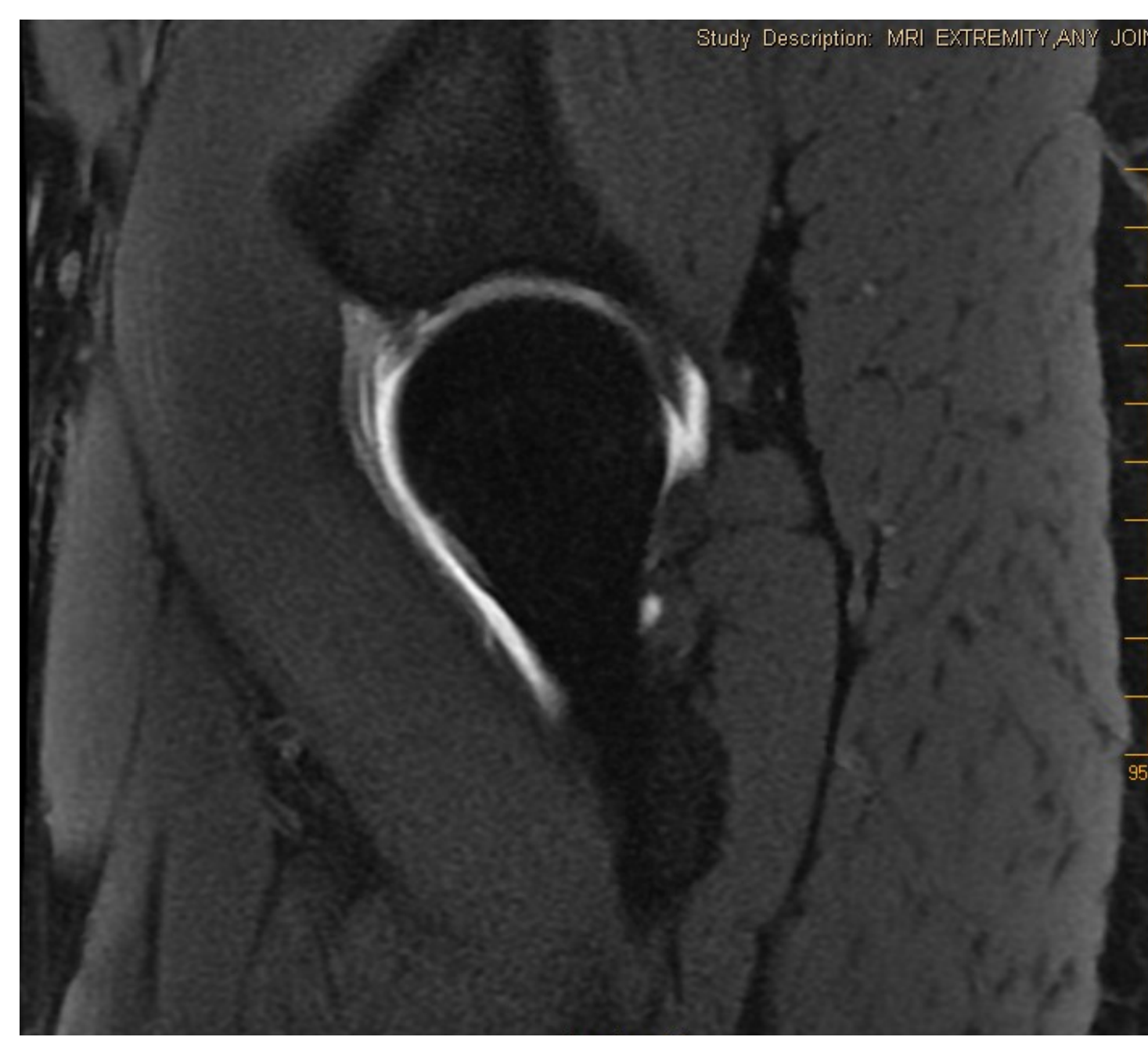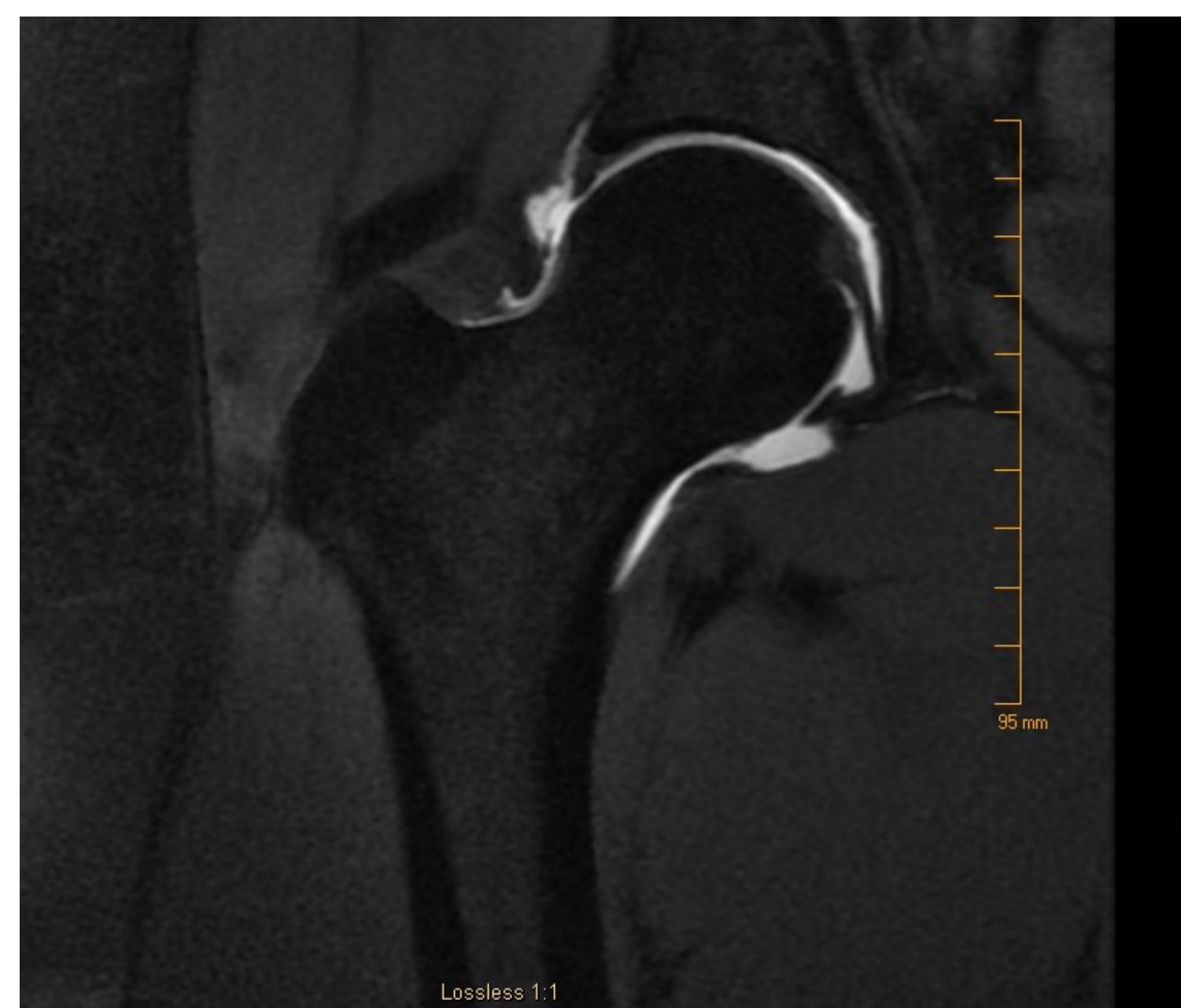


MRA 4 months after first PRP injection and 2 months after second PRP injection

Intervention and Results

In pursuit of conservative treatment, the patient agreed to a series of 3 right hip intra-articular PRP (platelet rich plasma) injections. When he presented for the second injection, he reported his pain had decreased by 20% and he was tolerating light running. Due to improvement in symptoms, an MR arthrogram was ordered to evaluate for structural change.

The repeat MR arthrogram showed slightly increased displacement of the labral tear.



Conclusion

There is evidence that PRP can improve pain and function in patients with hip labral tears¹. Structural change through PRP injection for hip labral tears has not been previously evaluated. In this case, PRP appeared to decrease the patient's pain and improve function, but subsequent imaging showed worsening of the labral injury. Functional improvement did not correlate with structural improvement. This may be due to a variety of factors, such as increased activity following PRP procedures, or improved anti-inflammatory and cytokine involvement in the hip joint following PRP leading to pain relief rather than tissue regeneration.

Discussion

PRP appears to be a safe and conservative option for decreasing pain and improving function in hip labral tears. However, more studies are needed to delineate the etiology of pain relief following PRP, as MRI imaging revealed apparent worsening of labral injury despite patient's improvement in pain. Future large studies should include follow-up imaging to assess for correlation of functional change and structural change.

References

- 1 - De Luigi AJ, Blatz D, Karam C, Gustin Z, Gordon AH. Use of Platelet-Rich Plasma for the Treatment of Acetabular Labral Tear of the Hip: A Pilot Study. *Am J Phys Med Rehabil.* 2019;98(11):1010–1017. doi:10.1097/PHM.0000000000001237