



TITLE:

Association between contrast extravasation on computed tomography scans and pseudoaneurysm formation in pediatric blunt splenic and hepatic injury: A multi-institutional observational study

AUTHOR(S):

Katsura, Morihiro; Fukuma, Shingo; Kuriyama, Akira; Takada, Tadaaki; Ueda, Yasuhiro; Asano, Shima; Kondo, Yutaka; ... Osaki, Nobuhiro; Mototake, Hidemitsu; Fukuhara, Shunichi

---

CITATION:

Katsura, Morihiro ...[et al]. Association between contrast extravasation on computed tomography scans and pseudoaneurysm formation in pediatric blunt splenic and hepatic injury: A multi-institutional observational study. *Journal of pediatric surgery* 2020, 55(4): 681-687

ISSUE DATE:

2020-04

URL:

<http://hdl.handle.net/2433/251015>

RIGHT:

© 2019. This manuscript version is made available under the CC-BY-NC-ND 4.0 license <http://creativecommons.org/licenses/by-nc-nd/4.0/>; The full-text file will be made open to the public on 01 April 2021 in accordance with publisher's 'Terms and Conditions for Self-Archiving'; この論文は出版社版ではありません。引用の際には出版社版をご確認ご利用ください。; This is not the published version. Please cite only the published version.

Original Article

**Association between contrast extravasation on computed tomography scans and pseudoaneurysm formation in pediatric blunt splenic and hepatic injury: A multi-institutional observational study**

Morihiro Katsura<sup>a,b</sup>, Shingo Fukuma<sup>c,\*</sup>, Akira Kuriyama MD<sup>d</sup>, Tadaaki Takada<sup>e</sup>, Yasuhiro Ueda<sup>f</sup>, Shima Asano MD<sup>g</sup>, Yutaka Kondo<sup>h,i</sup>, Masafumi Ie<sup>a</sup>, Kazuhide Matsushima<sup>j</sup>, Takahiro Murakami<sup>a</sup>, Yoshimitsu Fukuzato<sup>k</sup>, Nobuhiro Osaki<sup>l</sup>, Hidemitsu Mototake<sup>a</sup>, Shunichi Fukuhara<sup>b</sup>

<sup>a</sup>Department of General Surgery, Okinawa Chubu Hospital, Okinawa, Japan

<sup>b</sup>Department of Healthcare Epidemiology, School of Public Health in the Graduate School of Medicine, Kyoto University, Kyoto, Japan

<sup>c</sup>Human Health Sciences, Kyoto University Graduate School of Medicine, Kyoto, Japan

<sup>d</sup>Emergency and Critical Care Center, Kurashiki Central Hospital, Okayama, Japan

<sup>e</sup>Department of Emergency and Critical Care Medicine, Tokushima Red Cross Hospital, Tokushima, Japan

<sup>f</sup>Tajimay Emergency and Critical Care Medical Center, Toyooka Public Hospital, Hyogo, Japan

<sup>g</sup>Department of Surgery, Okinawa Miyako Hospital, Okinawa, Japan

<sup>h</sup>Department of Emergency and Critical Care Medicine, Graduate School of Medicine,  
University of the Ryukyus, Okinawa, Japan

<sup>i</sup>Department of Emergency and Critical Care Medicine, Juntendo University Urayasu Hospital,  
Chiba, Japan

<sup>j</sup>Division of Acute Care Surgery, University of Southern California, Los Angeles, California,  
USA

<sup>k</sup>Department of Pediatric Surgery, Okinawa Nanbu Medical Center & Children's Medical  
Center, Okinawa, Japan

<sup>l</sup>Department of Surgery, Okinawa Yaeyama Hospital, Okinawa, Japan

**\*Corresponding author and address for reprints:**

Shingo Fukuma, MD, PhD

Human Health Sciences, Kyoto University Graduate School of Medicine

Address: 53 Shogoin-Kawahara, Sakyo, Kyoto 606-8507, Japan

Tel: 81-75-751-3925

E-mail: [fukuma.shingo.3m@kyoto-u.ac.jp](mailto:fukuma.shingo.3m@kyoto-u.ac.jp)

**Conflicts of Interest and Sources of Funding:**

The authors declare no conflicts of interest or sources of funding regarding this work.

## ABSTRACT

*Purpose:* We aimed to examine the association between contrast extravasation (CE) on initial computed tomography (CT) scan and pseudoaneurysm (PSA) development in pediatric blunt splenic and/or liver injury.

*Methods:* We conducted a multi-institutional retrospective study in cases of blunt splenic and/or hepatic injury who underwent an initial attempt of non-operative management. A logistic regression model was used to compare PSA formation and CE on initial CT scan, and the area under the receiver operating characteristic curve (AUC) with and without CE was used to assess the predictive performance of CE for PSA formation.

*Results:* Of 236 cases enrolled from 10 institutions, PSA formation was observed in 17 (7.2%).

Multivariate analysis showed a significant association between CE on initial CT scan and increased incidence of PSA formation (odds ratio, 4.96; 95% confidence interval, 1.37–18.0).

There was no statistically significant association between the grade of injury and PSA formation. The AUC improved from 0.75 (0.64–0.87) to 0.80 (0.70–0.91) with CE.

*Conclusion:* Active CE on initial CT scan was an independent predictor of PSA formation.

Selective use of follow-up CT in children who showed CE on initial CT may provide early identification of PSA formation, regardless of injury grade.

**LEVEL OF EVIDENCE:** Prognostic and Epidemiological, Level III

**KEYWORDS:** pediatric trauma; spleen and liver injury; contrast extravasation; CT blush; pseudoaneurysm

The presence of active contrast extravasation (CE)<sup>1</sup> (the “blush sign”) on a computed tomography (CT)<sup>2</sup> scan is a known risk factor for non-operative management (NOM)<sup>3</sup> failure in adults with blunt splenic and/or hepatic injury [1–4]. However, the significance of these findings in the pediatric population is not clearly established [5–7]. The development of a splenic and/or hepatic artery pseudoaneurysm (PSA)<sup>4</sup> after NOM of blunt splenic and/or hepatic injury has been reported in approximately 2–5% of pediatric patients [7–9]. PSA can undergo life-threatening delayed rupture [8, 10]. The true incidence and natural history of PSA have yet to be clearly described because of insufficient evidence to support routine followup imaging in children [5, 7].

A systematic review of observational studies evaluating the NOM failure rate in pediatric patients with splenic and/or hepatic injury recommended consideration of both the physiological response and presence of CE on the CT scan [11]. Conversely, some retrospective studies have suggested that CE on the CT scan can be safely managed non-operatively and that physiological changes should dictate treatment [12, 13]. Such conflicting opinions can confuse and mislead clinicians, who are required to make critical decisions as to whether to aggressively proceed with an intervention or simply make observations. It remains unknown whether active CE on initial CT scan is linked to PSA formation and delayed rupture because of the existence of only a few retrospective descriptive

---

<sup>1</sup> CE = contrast extravasation

<sup>2</sup> CT = computed tomography

<sup>3</sup> NOM = non-operative management

<sup>4</sup> PSA = pseudoaneurysm

studies derived from a single institution on this topic [10, 14].

To our knowledge, there is currently no large comparative analytical study to have examined the association between active CE on initial CT scan and PSA formation in pediatric blunt splenic and/or hepatic injury. We conducted a multi-institutional study to gather large amounts of data with the following objectives: 1) to describe the natural history of vascular injury and unique practice patterns in pediatric patients with blunt splenic and/or hepatic injury in Japan, and 2) to determine whether active CE on initial CT scan is associated with the incidence of post-traumatic PSA formation.

## 1. Material and Methods

### *1.1 Study design and data source*

We conducted a retrospective cohort study using data collected from 10 emergency departments between 1990 and 2016 in Japan. Data collection for this study was approved by the institutional review board (IRB)<sup>5</sup> of each participating hospital. As this study was non-interventional and of minimal risk to subjects, the need for informed consent from each patient was waived in all hospitals. To ensure that all institutions used the same definitions, standardized datasheet templates were developed and utilized by staff at all sites.

### *1.2 Patient selection and definitions*

---

<sup>5</sup> IRB = institutional review board

This study included subjects aged  $\leq 16$  years with an acute blunt splenic and/or hepatic injury. Injury grade was determined according to the American Association for Surgery of Trauma (AAST)<sup>6</sup> solid organ scale [15]. Eligible patients included those admitted to an emergency care setting for at least 24 hours with  $\geq$  AAST grade I splenic and/or hepatic injury detected by any imaging method. We excluded the following subjects: those who (1) underwent an emergency laparotomy for splenic and/or hepatic injury within 6 hours of admission; (2) were dead on arrival; (3) died within 5 days of admission; or (4) were transferred to other institutions within 5 days of admission because we could not accurately determine whether patients developed PSA or not.

The standardized datasheet contained the subject's demographic data (age, gender, initial emergency department vital signs, Glasgow Coma Scale [GCS]<sup>7</sup>); situation of injury; injury severity (the highest Abbreviated Injury Scale [AIS]<sup>8</sup> score in each anatomic lesion, Injury Severity Score [ISS]<sup>9</sup>, AAST grade of splenic and hepatic injury); the presence or absence of active CE on initial CT scan; amount of hemoperitoneum; blood transfusion requirement; main treatment (conservative, catheter intervention, other); the presence and timing of follow-up imaging; post-traumatic PSA formation; hospital length of stay; and in-hospital mortality. We categorized the amount of hemoperitoneum into three scales according to a previous study [16], which estimated the hemoperitoneum volume by totaling

---

<sup>6</sup> AAST = American Association for Surgery of Trauma

<sup>7</sup> GCS = Glasgow Coma Scale

<sup>8</sup> AIS = Abbreviated Injury Scale

<sup>9</sup> ISS = Injury Severity Score

the number of intra-abdominal regions (right upper quadrant, left upper quadrant, right paracolic gutter, left paracolic gutter, and pelvis) in which free fluid was identified upon initial imaging. The definitions were: small, one region; moderate, two regions; large, three regions or more. Our primary outcome was post-traumatic PSA formation, diagnosed by follow-up CT scan, abdominal ultrasonography (AUS)<sup>10</sup>, or angiography. A post-traumatic PSA usually appears as an arterial phase-enhancing outpouching from intrasplenic/intrahepatic branches of the splenic/hepatic artery and is surrounded by a hematoma [17]. Delayed PSA rupture was defined as significant intra-abdominal re-bleeding from a PSA rupture more than 48 hours after injury. In the event of sudden-onset abdominal pain, the presence/absence of delayed PSA rupture was determined by CT and/or angiography. The independent variable was active CE detected by initial CT scan. We obtained a consensus regarding the definition of CE and PSA among the principal investigators of each institution, and trained researchers performed final interpretations to determine whether active CE and PSA formation were detected on CT scans. Any disagreements were resolved through involvement of interventional radiologists. Failure of NOM was defined as patients undergoing any surgical procedure in their abdominal cavity; the need for angiography and embolization were not considered as failure of NOM [18].

### *1.3 Statistical analysis*

---

<sup>10</sup> AUS = abdominal ultrasonography



Descriptive analysis was performed to summarize the characteristics of the entire cohort. Data were summarized as mean  $\pm$  standard deviation ( $SD^{11}$ ), median  $\pm$  interquartile range ( $IQR^{12}$ ), or number and percentage (%), as appropriate. We used the chi-squared test to compare the proportion of categorical variables and Student's *t*-test or Mann-Whitney *U*-test to compare the average of continuous variables.

We conducted a univariate analysis to compare the PSA incidence between the presence and absence of CE on the CT scan. Next, we performed multivariate logistic regression to identify factors associated with PSA formation. Covariates in this regression model, in addition to the presence of CE on the CT scan, included the grade of splenic and hepatic injury, ISS, and hemoperitoneum volume. Results were presented as odds ratios ( $ORs^{13}$ ) with 95% confidence intervals ( $CI_s^{14}$ ). Finally, we determined the area under the receiver operating characteristic curve ( $AUC^{15}$ ) to assess the predictive performance of CE. We used the same covariates in the multivariate logistic regression as in the AUC analysis. There was no missing data in the multivariate logistic regression. Statistical analyses were two-sided, with a *p* value of 0.05 indicating statistical significance. All analyses were performed using commercial software Stata/SE 11 (StataCorp, College Station, TX, USA).

---

<sup>11</sup> SD = standard deviation

<sup>12</sup> IQR = interquartile range

<sup>13</sup> OR = odds ratio

<sup>14</sup> CI = confidence interval

<sup>15</sup> AUC = area under the receiver operating characteristic curve

## 2. Results

### 2.1 Study populations and baseline characteristics

Of 264 pediatric cases of blunt splenic and/or hepatic injury admitted to the 10 participating institutions between 1990 and 2016, 236 cases met our inclusion criteria. Exclusions included emergency laparotomy for splenic and/or hepatic injury within 6 hours of admission ( $n = 18$ ), death on arrival ( $n = 2$ ), death within 5 days of admission ( $n = 4$ ), and transfer to other institutions within 5 days of admission ( $n = 4$ ) (Figure 1).

The baseline demographics and clinical characteristics of all participants in this study are summarized in Table 1. Of the 236 patients, 150 (64%) had a liver injury, 90 (38%) had a splenic injury, and four (2%) had both liver and splenic injuries. The most common injury mechanism was trauma by a motor vehicle (25%), followed by falls (19%). The median abdominal AIS score was 3 (IQR, 2–3), whereas that for other body regions was 0. Of the 236 patients, 157 (67%) sustained an isolated solid abdominal injury without other severe associated injuries (other body regions with an AIS greater than 3). Twenty-one subjects (9%) had active CE detected on initial CT scan.

### 2.2 Practice pattern and natural history of injury

Our practice pattern, the natural history of vascular injury, and other outcomes are summarized in Table 2. A follow-up (second) CT scan was performed in 188 patients (80%) during the same hospital stay. Sixty patients (25%) underwent an additional two or three

series of follow-up CT scans. Follow-up (repeated) AUS was also performed in 192 patients (82%). A total of 16 cases (7% of all cases; 10 with liver injury and 6 with splenic injury) had PSAs, of which 4 (2 with liver injury and 2 with splenic injury) were diagnosed when delayed PSA rupture occurred. Of the 4 cases with PSA rupture, 3 developed sudden-onset abdominal pain, and the diagnosis was established by CT scan on days 3, 8, and 21 post-hospitalization; these patients underwent emergent transcatheter arterial embolization (TAE<sup>16</sup>). In the other case (splenic injury), the subject developed sudden-onset abdominal pain, and PSA rupture was diagnosed by CT scan, 3 days after hospitalization; this subject received conservative treatment. No subject developed hemobilia as a result of PSA rupture.

The median time to PSA diagnosis was 6 days. Conservative treatment was successful in 196 cases (83%); abdominal angiography with/without TAE was performed in 33 cases (14%). Blood transfusions were required in 14 patients (6%). The median length of hospital stay was 12 days.

A variety of practice patterns were used to treat pediatric blunt splenic and/or hepatic injury (Figure 2). Of the 21 patients who showed active CE on initial CT scan, 14 underwent emergency abdominal angiography with/without TAE on the day of admission. Of the 16 patients who showed PSA formation, 7 underwent TAE on the day of detection. In contrast, 9 patients were monitored closely, with PSA subsequently resolving on the repeat CT scan. Of the 4 patients with delayed PSA rupture, 3 underwent emergency TAE, while the other

---

<sup>16</sup> TAE = transcatheter arterial embolization

patient's PSA underwent spontaneous thrombosis without any intervention. No patient required emergency laparotomy due to PSA, and there were no NOM failure cases. No complications of angiography were reported. We did not observe any significant changes in the practice patterns over the study period.

### *3.3 Association between the presence of active CE on initial CT scan and post-traumatic PSA formation*

The incidence of PSA was 29% (6/21) in the group with active CE on initial CT scan, and 5% (10/215) in the group with no CE on initial CT scan. Univariate analysis showed that the incidence of PSA formation was significantly higher in the group with active CE on initial CT scan ( $p < 0.001$ ).

Subsequently, multivariate analysis using a logistic regression model was performed to determine the association between active CE on initial CT scan and PSA formation (Table 3). This model also showed that active CE on initial CT scan was significantly associated with a higher incidence of PSA formation (OR, 4.96; 95% CI, 1.37–18.0). The AAST grade of injury, hemoperitoneum volume, and patient age were not significantly associated with PSA incidence.

In a core model that included the AAST grade of splenic and/or hepatic injury, ISS, and hemoperitoneum volume (Figure 3), the AUC was 0.75 (95% CI, 0.64–0.87). When this core model was extended to include CE on initial CT scan as a covariate, the AUC was 0.80

(95% CI, 0.70–0.91). After the addition of the patient age to this prediction model (supplementary file), the AUC was 0.82 (95% CI, 0.72–0.92).

We performed subgroup analyses according to the injured organ (liver or spleen). The association between active CE on initial CT scan and PSA formation was similar across the subgroups (liver injury: OR, 6.80; 95% CI, 1.39–33.4 and splenic injury: OR, 6.06; 95% CI, 0.71–51.6). We also performed sensitivity analysis after excluding older cases (those injured before 2000). The association between active CE on initial CT scan and PSA formation was consistent among older and newer cases (OR, 4.12; 95% CI, 1.12–15.2). We performed another sensitivity analysis, in which the year of injury was added as a covariate to the logistic regression model. This sensitivity analysis also showed a consistent association (OR, 3.93; 95% CI, 1.05–14.7).

### 3. Discussion

This study elucidated the natural history and practice patterns for pediatric patients with blunt splenic and/or hepatic injury in Japan. A follow-up CT scan was frequently performed, and angiographic intervention was considered the treatment modality of choice in a large proportion of cases with active CE on the day of admission. This study also examined the association between active CE on initial CT scan and the incidence of PSA formation in multiple medical centers. The results showed that evidence of active CE on initial CT scan was an independent predictor of PSA formation. In contrast, we did not find a statistically

significant association between the AAST grade of injury and PSA formation.

We evaluated 236 pediatric cases undergoing an initial attempt of NOM. Abdominal angiographic interventions were performed in 33 cases (14%), and the rate of NOM failure was 0%. Based on these results, screening and treatment for PSA may prevent lethal delayed bleeding events and decrease the rate of NOM failure. We confirmed that a selective follow-up CT scan can be useful if the patient shows active CE on initial CT scan, regardless of the injury grade.

Previous studies have suggested that routine follow-up imaging is not necessary for blunt splenic and/or hepatic injury in children because of the high success rate of NOM [5, 6, 16]. As a result, even though the main anticipated finding of follow-up imaging is PSA formation, the true incidence and natural history of these lesions have not been clearly described. Some retrospective observational studies have stated that routine follow-up screening using ultrasonography is warranted for pediatric patients [8, 19]; however, these studies did not compare ultrasonography with routine follow-up CT imaging. We showed clinically relevant results according to the unique practice patterns in Japan, where follow-up CT scans are frequently performed, which may closely reflect the true incidence and natural history of these lesions.

The incidence and timing of PSA formation have not been thoroughly investigated in previous studies, and the timing of the follow-up CT is also controversial. A multi-institutional study of adult patients with blunt splenic injury from Japan showed that up

to 15.4% of patients developed PSAs, which were diagnosed with enhanced CT at a mean (SD) of 4.6 (2.1) days after admission [20]. This previous study suggested that follow-up enhanced CT performed approximately 1 week after injury may be useful to detect delayed SPA formation. Another retrospective observation study of adult patients with blunt injury to the torso visceral organs from Japan showed that the undesirable delayed events were recognized on follow-up CT scans in 11.4% of NOM patients at 6-7 days after hospitalization [21]. This previous study suggested that the second follow-up CT scan that was performed 1–2 days after admission did not help predict undesirable results of delayed events. The results of our study revealed that repeat CT is usually obtained at around 5 days after hospitalization because of concerns regarding PSA formation and its rupture risk shown in previous studies from Japan, even in the absence of alarming signs of PSA formation.

Accurate selection of candidates for NOM after blunt splenic and/or hepatic injury in the pediatric population remains problematic. The key questions are “what is the risk of NOM failure?” and “is further angiographic or operative intervention warranted?” Several studies in adults have suggested that vascular injuries, including active CE and PSA, pose a risk for NOM failure [1–4, 22]. However, there are controversial opinions in the pediatric literature regarding whether the presence of active CE on initial CT scan is associated with NOM failure. Despite the low level of evidence, most retrospective studies suggest that the presence of active CE on initial CT scan alone is not associated with negative outcomes and that it can be safely managed without surgical or angiographic intervention [12–14, 23, 24]. Although

few have examined this in a pediatric population, some retrospective studies have reported that active CE on initial CT scan correlates with delayed bleeding and may predict the need for subsequent intervention [10, 25]. A systematic review and meta-analysis that pooled data from observational descriptive studies emphasized the high failure rate of NOM in children with CE on initial CT scan [11]. Our results using data from multiple institutions support the latter opinion. To our knowledge, this study is the first large comparative analytic study to examine the association between active CE on initial CT scan and PSA formation in children.

Higher grade injuries are generally considered more likely to result in PSA formation. However, our results showed a lack of an association between the AAST grade of injury and the incidence of PSA formation, which is in line with evidence from recent studies [17, 26]. The potential mechanisms to explain this lack of association are yet to be elucidated. Studies have reported that PSA develops even in relatively low-grade injuries (grade II) in pediatric and adult patients [17, 20, 26]. We hypothesize that high-grade injuries cause damage to major hilar vessels, resulting in devascularization of the organ, whereas low-grade injuries cause damage to peripheral vessels with minimal involvement by ischemic changes, leading to PSA formation.

In general, catheter angiography was performed in pediatric patients who had uncontrolled, ongoing abdominal hemorrhage who were hemodynamically stable or a rapid responder to resuscitation, especially those who showed CE and who did not meet the criteria for emergent laparotomy [27]. In daily practice, angioembolization is reserved for patients



with a higher injury grade and the presence of CE; however, there is a lack of well-defined criteria for embolization in adult and pediatric patients [28]. The role of angiographic intervention in the management of pediatric trauma is controversial, and its use varies widely among institutions [27]. Angiographic findings that prompted TAE included CE, major vessel truncation, petechial hemorrhage, arterial spasm located in the distribution of hemorrhage, PSA, vessel transection, and arteriovenous fistula [29]. In Japan, TAE is not only used for persistent bleeding immediately after trauma, but also for preventing subacute phase re-bleeding from PSA rupture.

Another question is whether all PSAs should be treated equally. There is ongoing controversy regarding the optimal management of PSA in children. As in previous studies, this study found that some PSAs thrombosed or resolved spontaneously without TAE, whereas others underwent delayed rupture, leading to life-threatening hemorrhage requiring an emergency intervention or laparotomy under unstable conditions [8, 9, 14, 19, 23, 30]. The fear of delayed rupture is often reported as a reason for the aggressive prophylactic intervention in otherwise stable children [8, 9, 31, 32]. There is no data available as to what kind of PSA would be susceptible to rupture. We have previously reported that there is no correlation between the size of aneurysm and the rate of its rupture in true aneurysm of pancreaticoduodenal arteries [33]. This finding implies that clinicians should pay attention to PSAs of any size because they have the risk of rupture. In addition, even though the rate of PSA rupture is as low as around 1-2%, conservative treatment is a gutsy action. The

guidelines of the World Society of Emergency Surgery recommended that angioembolization may be considered for the treatment of splenic PSA prior to patient discharge [27]. While such treatment was continued over the study period, we recognize that a simple practice guideline that recommends only one approach would not be effective in the clinical setting. At present, given that the indication varies according to patients' vital signs, the experience and background of the treating physician, and institutional resources and policy, practice may have varied across institutions. However, recent reviews have shown that arterial embolization in pediatric abdominal trauma is a relatively safe procedure with a low risk of complications [6, 13, 17, 29, 32, 34], as shown in the present study. Therefore, we propose that prophylactic selective angioembolization is a safe and potentially effective therapy, and, in view of technical advances in interventional radiology, should be a treatment choice for pediatric patients.

This study confirmed that the use of repeat CT imaging is excessive, and most institutions in Japan have not adhered to the Arizona-Texas-Oklahoma-Memphis-Arkansas pediatric trauma consortium of the American College of Surgeons (ATOMAC)<sup>17</sup> protocol for NOM of blunt liver and spleen injury in children [6]. This practice pattern has been consistent over time. One reason why Japanese trauma surgeons oppose current efforts to minimize ionizing radiation in children may be immoderate concerns regarding PSA formation and its

---

<sup>17</sup> ATOMAC = Arizona-Texas-Oklahoma-Memphis-Arkansas), a pediatric trauma consortium of the American College of Surgeons

rupture risk. In addition, the number of CT scanners per million of the population in Japan is 3–7 times that of the Organisation for Economic Co-operation and Development member countries [35]. Easy access to CT scanning at low cost for patients may be linked to excessive radiation exposure.

AUS is also ideally suited for assessing vascular abnormalities in solid abdominal organs. However, there are some issues related to assessing PSA formation with AUS. For example, the accuracy of assessing PSA formation with AUS may vary across examiners (e.g. examiner dependent factors). In addition, AUS has the limited capacity to detect small-sized PSA [19]. A multi-institutional study of adult patients with blunt splenic injury from Japan reported that PSAs were 3.5-25mm in size [20]. PSA < 5mm in size can be missed by non-experienced operators and conventional ultrasound [19], and AUS alone would have difficulty to identify PSA in anatomically hindered regions. The daily conduct of AUS during hospitalization may place a burden on clinicians, and findings that are hard to interpret may prompt additional CT imaging. Therefore, we suggest that CT scan should play a greater role in confirming the diagnosis of PSA formation and determining the treatment strategy. Prior to this study, no report had identified the risk factors for PSA formation, which may have led to unnecessary repeat imaging in children. Some patients may have been hospitalized for the purpose of repeat imaging to screen for PSA, which could have partly prolonged the length of hospital stay.

Our study is noteworthy for several reasons. First, the unique practice patterns in

Japan made it possible to describe the natural history of blunt splenic and/or hepatic injury.

Second, the large cohort made it possible to statistically compare the incidence of PSA formation in the presence and absence of active CE on initial CT scan. Third, there were limited confounding factors to adjust for in the statistical analysis because most cases included single-system-injured children. We used two statistical methodologies to evaluate the robustness of our analytical methods, including AUC analysis. Consistent results obtained using both methods support the robustness of our findings.

Conversely, several limitations of the present study warrant mention. First, there may be potential residual confounders due to unavailable information in the dataset used because of the nature of the retrospective study design. Second, the techniques used for contrast injection differed, and there was subjective reader variability in abdominal CT interpretation in the diagnosis of CE and PSA formation [13, 36]. Third, there were considerable technological advances in CT scanning, medical devices, the rate of delivery and composition of intravenous contrast media, timing of scans, and angiographic interventional techniques during a long study period. Therefore, we performed two sensitivity analyses by excluding older cases (those injured before 2000) and adding a covariate (the year of injury) to the regression model to adjust for the influence of technological advances on medical devices. These sensitivity analyses showed that the association was consistent across the study period. Fourth, many practice variations across institutions, overuse of CT scanning and unnecessary radiation exposure for children make it difficult to interpret this research. Finally, many

eligible pediatric patients were treated in adult trauma centers with no established pediatric trauma protocols. However, a national trauma data bank analysis showed that there was no variation in practice between adult trauma centers and pediatric trauma centers regarding liver operation or TAE incidence [37], suggesting that this fact may have had little effect on the study results. We hope that our study will stimulate future large multi-institutional prospective cohort studies to improve the evidence level of research.

Our findings have several important clinical implications for both adult and pediatric trauma surgeons. Follow-up CT scans and angiographic intervention were frequently performed and the NOM failure rate was 0%, suggesting that screening and treatment for PSA can be effective treatment strategy in pediatric patients with blunt splenic and/or hepatic injury. Our results also revealed that active CE on initial CT scan was an independent predictor for PSA formation, while there was no association between the grade of injury and risk of PSA formation. On the basis of our study results, we recommend the selective use of follow-up CT imaging in pediatric patients who show CE on initial CT scan to facilitate early identification and angiographic treatment of PSA, regardless of injury grade. Furthermore, low-dose CT protocols are preferred, taking into account the radiation risk for children [27]. We do not recommend routine reimaging in all children with blunt liver and/or spleen injury unless there is a sudden increase in abdominal pain.

#### 4. Conclusions

In conclusion, active CE on initial CT scan was an independent predictor for PSA formation. Selective use of follow-up CT imaging as an adjunct to NOM in pediatric patients who showed CE on initial CT scan may allow early identification and angiographic treatment of PSA, regardless of injury grade but should not be routinely recommended in all pediatric patients to avoid excessive radiation exposure.

### Acknowledgements

We thank the principal investigators at each participating institution: Okinawa Chubu Hospital (MK, MI, TM, HM), Okinawa Nanbu Medical Center & Children's Medical Center (MK, YF), Okinawa Hokubu Hospital (MK), Okinawa Miyako Hospital (SA), Okinawa Yaeyama Hospital (NO), Kurashiki Central Hospital (AK), Tokushima Red Cross Hospital (TT), Urasoe General Hospital (TT), Toyooka Public Hospital (YU), and University of the Ryukyus (YK). We thank Dr. Koichiro Gibo for his support in obtaining IRB approval at Okinawa Chubu Hospital. We thank Libby Cone, MD, MA, from DMC Corp. for editing drafts of this manuscript.

### Disclosure

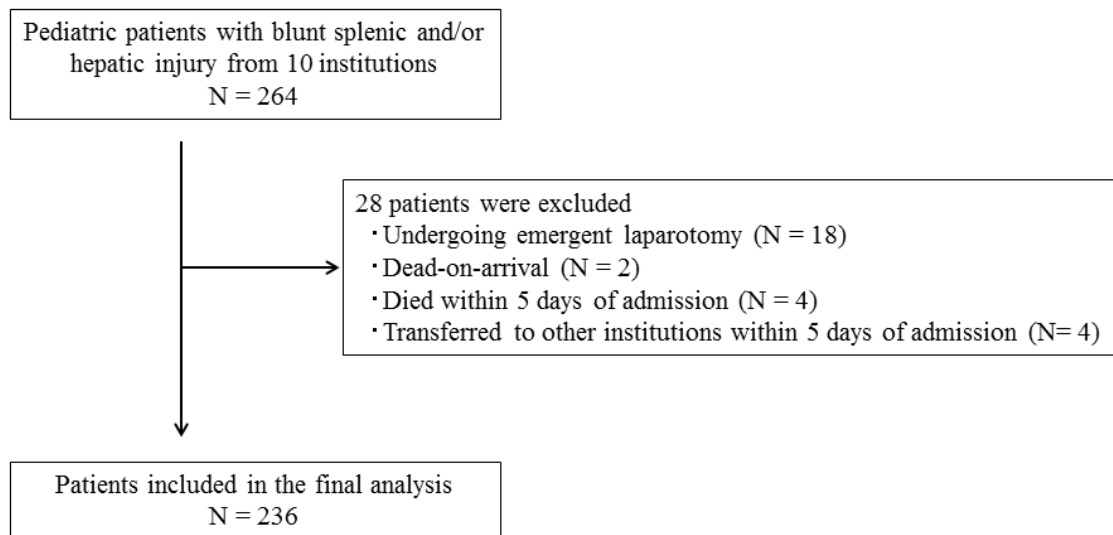
The authors declare no conflicts of interest or sources of funding regarding this work.

### Funding

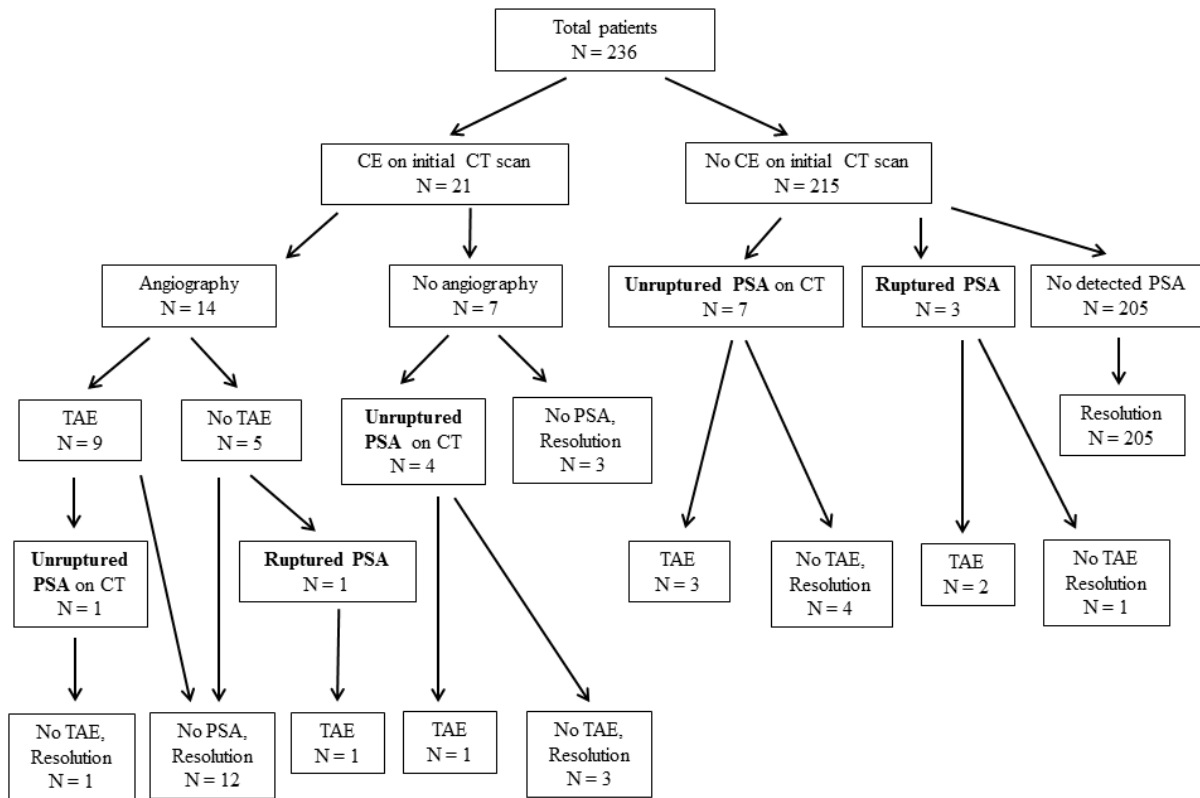
This research received no specific grant from any funding agency in the public, commercial or not-for-profit sectors.

## Figure legends

**Figure 1.** Selection process for the study population



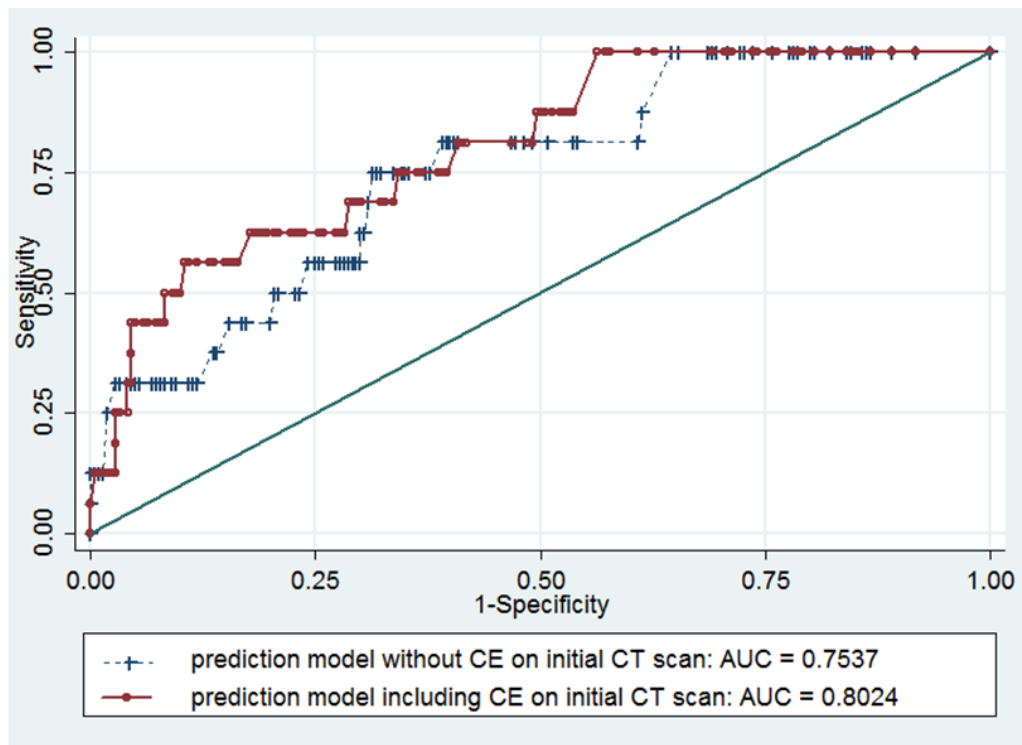
**Figure 2.** Practice variations and history of PSA in pediatric liver and/or spleen injury



CE, contrast extravasation; CT, computed tomography; PSA, pseudoaneurysm; TAE, transcatheter arterial embolization

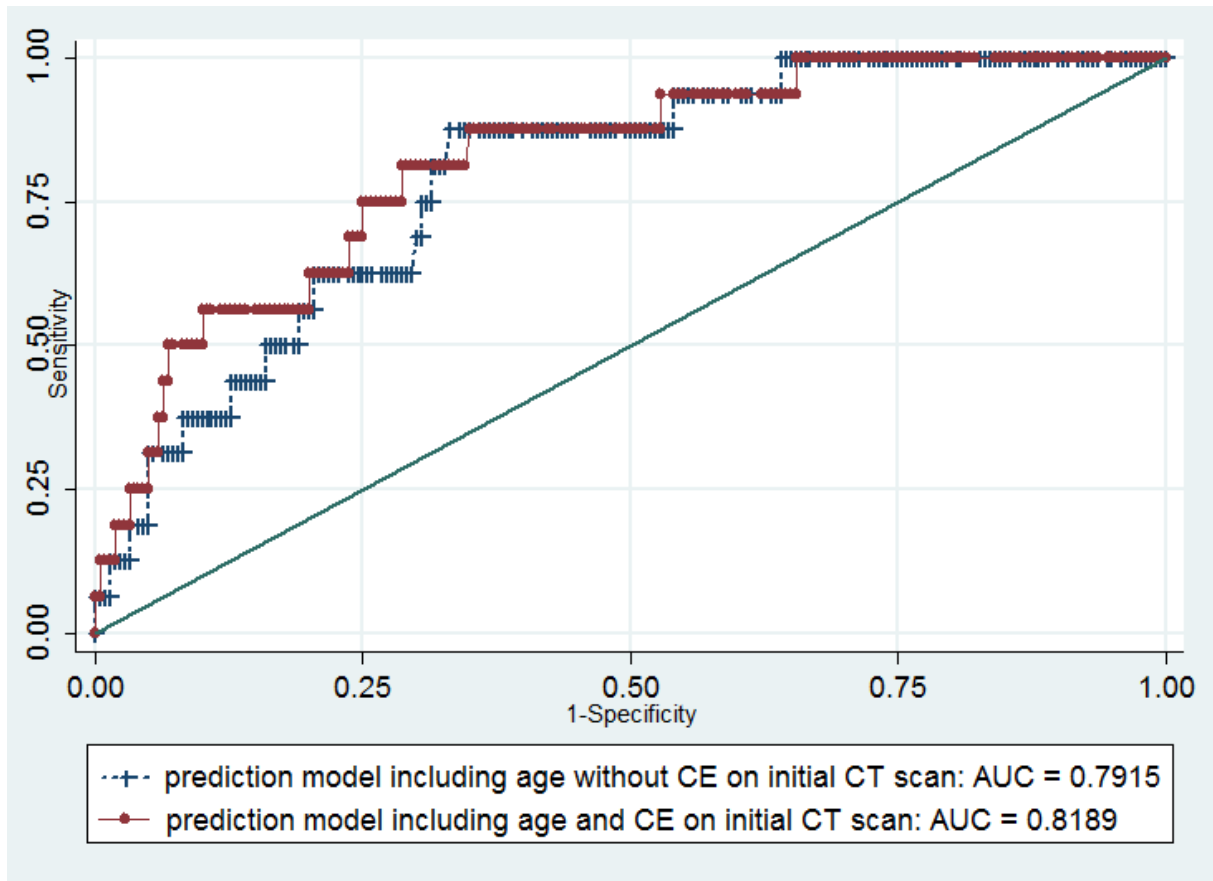


**Figure 3.** Estimated area under the receiver operating characteristic curve (AUC) for predicting traumatic pseudoaneurysm formation.



CE, contrast extravasation; CT, computed tomography

**Supplementary file.** Estimated area under the receiver operating characteristic curve (AUC) for predicting traumatic pseudoaneurysm formation.



CE, contrast extravasation; CT, computed tomography

**Table 1. Baseline demographics and clinical characteristics of the study population**

			Number (%)
			(Total number = 236)
<b>Patient characteristics</b>			
	Age	years (mean±SD)	9.3±4.5
	Gender	Male	159 (67%)
<b>Situation of injury</b>			
	Fall		46 (19%)
	Sport		7 (3%)
	Bicycle		34 (14%)
	MVC		31 (13%)
	MV vs Ped		58 (25%)
	Other		60 (25%)
<b>Physiologic status on arrival</b>			
	SBP	mmHg (mean ± SD)	109 ± 19
	HR	beats/min (mean ± SD)	106 ± 25
	GCS score (total)	(mean ± SD)	14 ± 1.7
<b>Severity of injury</b>			
		(median [IQR])	
	AIS	Skin	0 [0–1]
		Head and neck	0 [0–1]
		Face	0 [0–1]
		Chest	0 [0–3]
		Abdomen	3 [2–3]
		Extremity	0 [0–1]
	ISS	(median [IQR])	13 [9–19]
<b>Type of injury</b>			
	Liver injury only		150 (64%)
	Splenic injury only		90 (38%)
	Both liver and splenic injury		4 (2%)
<b>Grade of injury (AAST grade)</b>			
	Liver injury	I–II	67 (45%)
		III	33 (22%)
		IV–V	50 (33%)
	Splenic injury	I–II	18 (20%)
		III	63 (70%)

	IV–V	9 (10%)
Hemoperitoneum volume		
	Zero	60 (25%)
	Small	61 (26%)
	Moderate	52 (22%)
	Large	63 (27%)
CE on initial CT scan		
	Yes	21 (9%)
	No or unknown	215 (91%)

---

MVC, motor vehicle crash; MV vs Ped, motor vehicle versus pedestrian; SBP, systolic blood pressure; HR, heart rate; GCS, Glasgow coma scale; AIS, abbreviated injury scale; ISS, injury severity score; CT, computed tomography; CE, contrast extravasation; AAST, American Association for Surgery of Trauma; IQR, interquartile range.

Values are presented as N (%), mean  $\pm$ SD, or median [IQR, 25th and 75th percentile], as appropriate.

**Table 2. Practice pattern, natural history of vascular injury, and outcomes**

		Number (%)
		(Total number = 236)
Follow-up (repeated) AUS	Yes	192 (82%)
	No	44 (19%)
Follow-up (repeated) CT scan	Yes	188 (80%)
	No	48 (20%)
Hospital day of second CT scan	(median day [IQR])	8 [5–10]
Blood transfusion requirement	Yes	14 (6%)
	No	222 (94%)
Main treatment		
	Conservative	196 (83%)
	TAE/Angiography	33 (14%)
	Other	7 (3%)
PSA		
PSA formation	Yes	16 (7%)
	No or unknown	220 (94%)
Delayed rupture of PSA	Yes	4 (2%)
	No	232 (98%)
Detection of PSA	(median day [IQR])	6 [1–8]
In-hospital mortality		1 (0.4%)
Length of hospital stay	(median day [IQR])	12 [7–16]

AUS, abdominal ultrasound; CT, computed tomography, TAE, transcatheter arterial embolization; PSA, pseudoaneurysm; IQR, interquartile range.

Values are presented as N (%), mean  $\pm$ SD, or median [IQR, 25th and 75th percentile], as appropriate.

**Table 3. Multivariate analysis of traumatic pseudoaneurysm formation in all patients**

Variable	Odds ratio	95% CI	P
Age	1.09	(0.95-1.24)	0.208
Grade of injury (AAST grade)			
I–II	Reference		
III	0.85	(0.10–7.10)	0.883
IV–V	1.65	(0.18–15.4)	0.658
ISS	1.05	(1.00–1.10)	0.039
Hemoperitoneum volume			
Zero	Reference		
Small	3.66	(0.24–56.6)	0.353
Moderate	4.96	(0.28–88.5)	0.278
Large	3.12	(0.17–55.9)	0.440
CE on initial CT scan	4.96	(1.37–18.0)	0.015

CI, confidence interval; ISS, injury severity score; CT, computed tomography; CE, contrast extravasation; AAST, American

Association for Surgery of Trauma

## References

1. Zarzaur BL, Dunn JA, Leininger B, et al. Natural history of splenic vascular abnormalities after blunt injury: A Western Trauma Association multicenter trial. *J Trauma Acute Care Surg* 2017;83(6):999-1005
2. Stassen NA, Bhullar I, Cheng JD, et al. Eastern Association for the Surgery of Trauma. Selective nonoperative management of blunt splenic injury: an Eastern Association for the Surgery of Trauma practice management guideline. *J Trauma Acute Care Surg* 2012;73(5 Suppl 4):S294-300.
3. Stassen NA, Bhullar I, Cheng JD, et al. Eastern Association for the Surgery of Trauma. Nonoperative management of blunt hepatic injury: an Eastern Association for the Surgery of Trauma practice management guideline. *J Trauma Acute Care Surg* 2012;73(5 Suppl 4):S288-93.
4. Schurr MJ, Fabian TC, Gavant M, et al. Management of blunt splenic trauma: computed tomographic contrast blush predicts failure of nonoperative management. *J Trauma* 1995;39(3):507-12;discussion 512-3.
5. Stylianos S. Evidence-based guidelines for resource utilization in children with isolated spleen or liver injury. The APSA Trauma Committee. *J Pediatr Surg* 2000;35(2):164-7; discussion 167-9.
6. Notrica DM, Eubanks JW 3rd, Tuggle DW, et al. Nonoperative management of blunt liver and spleen injury in children: Evaluation of the ATOMAC guideline using GRADE. *J*

- Trauma Acute Care Surg 2015;79(4):683-93.
7. Davies DA, Pearl RH, Ein SH, et al. Management of blunt splenic injury in children: evolution of the nonoperative approach. *J Pediatr Surg* 2009;44(5):1005-8.
  8. Safavi A, Beaudry P, Jamieson D, et al. Traumatic pseudoaneurysms of the liver and spleen in children: is routine screening warranted? *J Pediatr Surg* 2011;46(5):938-41.
  9. Martin K, Vanhouwelingen L, Bütter A. The significance of pseudoaneurysms in the nonoperative management of pediatric blunt splenic trauma. *J Pediatr Surg* 2011;46(5):933-7.
  10. Skattum J, Gaarder C, Naess PA. Splenic artery embolisation in children and adolescents--an 8 year experience. *Injury* 2014;45(1):160-3.
  11. van der Vlies CH, Saltzherr TP, Wilde JC, et al. The failure rate of nonoperative management in children with splenic or liver injury with contrast blush on computed tomography: a systematic review. *J Pediatr Surg* 2010;45(5):1044-9.
  12. Ingram MC, Siddharthan RV, Morris AD, et al. Hepatic and splenic blush on computed tomography in children following blunt abdominal trauma: Is intervention necessary? *J Trauma Acute Care Surg* 2016;81(2):266-70.
  13. Bansal S, Karrer FM, Hansen K, et al. Contrast blush in pediatric blunt splenic trauma does not warrant the routine use of angiography and embolization. *Am J Surg* 2015;210(2):345-50.
  14. Cloutier DR, Baird TB, Gormley P, et al. Pediatric splenic injuries with a contrast blush:



- successful nonoperative management without angiography and embolization. *J Pediatr Surg* 2004;39(6):969-71.
15. Moore EE, Cogbill TH, Jurkovich GJ, et al. Organ injury scaling: spleen and liver (1994 revision). *J Trauma* 1995;38(3):323-4.
16. Bird JJ, Patel NY, Mathiason MA, et al. Management of pediatric blunt splenic injury at a rural trauma center. *J Trauma Acute Care Surg* 2012;73(4):919-22.
17. Jesinger RA, Thoreson AA, Lamba R. Abdominal and pelvic aneurysms and pseudoaneurysms: imaging review with clinical, radiologic, and treatment correlation. *Radiographics* 2013;33(3):E71-96.
18. Linnaus ME, Langlais CS, Garcia NM, et al. Failure of nonoperative management of pediatric blunt liver and spleen injuries: A prospective Arizona-Texas-Oklahoma-Memphis-Arkansas Consortium study. *J Trauma Acute Care Surg* 2017;82(4):672-79.
19. Durkin N, Deganello A, Sellars ME, et al. Post-traumatic liver and splenic pseudoaneurysms in children: Diagnosis, management, and follow-up screening using contrast enhanced ultrasound (CEUS). *J Pediatr Surg* 2016;51(2):289-92.
20. Muroya T, Ogura H, Shimizu K, et al. Delayed formation of splenic pseudoaneurysm following nonoperative management in blunt splenic injury: multi-institutional study in Osaka, Japan. *J Trauma Acute Care Surg* 2013;75(3):417-20.
21. Uchida K, Mizobata Y, Hagawa N, et al. Can we predict delayed undesirable events after

- blunt injury to the torso visceral organs? *Acute Med Surg* 2018;5(2):160-65.
22. Haan JM, Marmery H, Shanmuganathan K, et al. Experience with splenic main coil embolization and significance of new or persistent pseudoaneurysm: reembolize, operate, or observe. *J Trauma* 2007;63(3):615-9.
23. Davies DA, Ein SH, Pearl R, et al. What is the significance of contrast "blush" in pediatric blunt splenic trauma? *J Pediatr Surg* 2010;45(5):916-20.
24. Lutz N, Mahboubi S, Nance ML, et al. The significance of contrast blush on computed tomography in children with splenic injuries. *J Pediatr Surg* 200;39(3):491-4.
25. Nwomeh BC, Nadler EP, Meza MP, et al. Contrast extravasation predicts the need for operative intervention in children with blunt splenic trauma. *J Trauma* 2004;56(3):537-41.
26. Østerballe L, Helgstrand F, Axelsen T, et al. Hepatic pseudoaneurysm after traumatic liver injury; is CT follow-up warranted? *J Trauma Manag Outcomes* 2014;8:18.
27. Coccolini F, Montori G, Catena F et al. Splenic trauma: WSES classification and guidelines for adult and pediatric patients. *World J Emerg Surg* 2017;12:40.
28. Olthof DC, Joosse P, Bossuyt PM et al. Observation Versus Embolization in Patients with Blunt Splenic Injury After Trauma: A Propensity Score Analysis. *World J Surg* 2016;40(5):1264-71.
29. Vo NJ, Althoen M, Hippe DS, et al. Pediatric abdominal and pelvic trauma: safety and efficacy of arterial embolization. *J Vasc Interv Radiol* 2014;25(2):215-20.
30. Hacker HW, Schwöbel MG, Allgayer B. Pseudoaneurysm rupture after liver injury in a

- 14-year-old boy. *Eur J Pediatr Surg* 2008;18(2):126-8.
31. Yi IK, Miao FL, Wong J, et al. Prophylactic embolization of hepatic artery pseudoaneurysm after blunt abdominal trauma in a child. *J Pediatr Surg* 2010;45(4):837-9.
32. Schuster T, Leissner G. Selective angioembolization in blunt solid organ injury in children and adolescents: review of recent literature and own experiences. *Eur J Pediatr Surg* 2013;23(6):454-63.
33. Katsura M, Gushimiyagi M, Takara H, et al. True aneurysm of the pancreaticoduodenal arteries: a single institution experience. *J Gastrointest Surg* 2010;14(9):1409-13.
34. Gross JL, Woll NL, Hanson CA, et al. Embolization for pediatric blunt splenic injury is an alternative to splenectomy when observation fails. *J Trauma Acute Care Surg* 2013;75(3):421-25.
35. Berrington de González A, Darby S. Risk of cancer from diagnostic X-rays: estimates for the UK and 14 other countries. *Lancet* 2004;363(9406):345-51.
36. Yoon LS, Haims AH, Brink JA, et al. Evaluation of an emergency radiology quality assurance program at a level I trauma center: abdominal and pelvic CT studies. *Radiology* 2002;224(1):42-6.
37. Safavi A, Skarsgard ED, Rhee P, et al. Trauma center variation in the management of pediatric patients with blunt abdominal solid organ injury: a national trauma data bank analysis. *J Pediatr Surg* 2016;51(3):499-502.