

Spindle-cell sarcoma of the heart: A rare cause for a cardiac mass

Sanjay Mehra, MD; Osman Ibrahim, MD; Mariam Moshiri, MD; John Cahill, MD; and Puneet Bhargava, MD

Primary cardiac tumors are rare and are usually diagnosed at an advanced stage due to nonspecific symptoms. We report a 46-year-old female who presented to our institution with shortness of breath and was diagnosed with a cardiac spindle-cell tumor. Wide surgical resection is the cornerstone for therapy for cardiac sarcomas. Our patient was considered inoperable due to the extent of the tumor.

Introduction

The incidence of primary cardiac tumors is between 0.0017% and 0.019%, with 25% of them being malignant (1-3). These tumors have a poor prognosis due to their diagnosis at an advanced stage, due to nonspecific symptoms and insufficient awareness about these lesions (4). Echocardiography, CT, and MRI are the primary diagnostic modalities, followed by tissue biopsy.

Case report

A 46-year-old African-American female presented to her primary care physician with worsening shortness of breath and palpitations of a few weeks' duration. Her past medical history was significant for right breast cancer, and she was status postmodified radical mastectomy with negative margins and negative lymph nodes. She was initially treated with azithromycin and a tapering dose of steroids. Her condition did not improve, and she then presented to the emergency department with worsening shortness of breath.

On admission, the patient was afebrile with mild sinus tachycardia and elevated blood pressure. On clinical examination, she had bilateral lower-extremity edema with no jugular venous distension and no rales on chest auscultation. A complete blood count showed leucocytosis, mainly neutrophilic with a microcytic anemia. Blood chemistry revealed normal renal function with mildly elevated liver-function tests, namely aspartate aminotransferase at 84U/L (reference level 10-31U/L) and alanine aminotransferase at 78U/L (reference level 10-41U/L). Cardiac biomarkers showed elevated serum troponin I at 0.20ng/mL (reference level <0.10ng/mL) and brain natriuretic peptide at 805pg/mL (reference level <100pg/mL).

Chest radiography showed mild cardiomegaly, with no focal consolidation or pleural effusion. The patient was treated with intravenous diuretics, and her symptoms improved with diuresis. Computed tomography angiography (CTA) of the chest was performed due to elevated d-dimer at 1.22mg/L (reference level <0.59mg/L). It showed no evidence of acute pulmonary thrombo-embolic disease but showed masslike low density along the anterolateral left ventricular walls at the mid and apical levels (Fig. 1). Differential considerations at that time included a thrombus, asymmetric hypertrophic cardiomyopathy, and a cardiac neoplasm. Transthoracic echocardiography showed an ejection fraction of 25-30%, with global hypokinesis of the left ventricle (Fig. 2). A large isoechoic mass was seen along the anterior to anteroseptal wall. There was mild systolic mitral regurgitation and moderate-to-severe tricuspid regurgitation. The right ventricular systolic pressure was 66 mmHg. Cardiac MRI was performed to further evaluate for a left-ventricular mass versus thrombus. It showed a large heterogeneous mass (Fig. 3) involving the anterior wall of the left ventricle from the base to apex and extending into the portions of the anterolateral and anteroseptal

Citation: Mehra S, Ibrahim O, Moshiri M, Cahill J, Bhargava P. Spindle-cell sarcoma of the heart: A rare cause for a cardiac mass. *Radiology Case Reports*. (Online) 2012;7:792.

Copyright: © 2012 The Authors. This is an open-access article distributed under the terms of the Creative Commons Attribution-NonCommercial-NoDerivs 2.5 License, which permits reproduction and distribution, provided the original work is properly cited. Commercial use and derivative works are not permitted.

Drs. Mehra, Ibrahim, and Cahill are in the Department of Cardiovascular Sciences at East Carolina University, Greenville, NC. Drs. Moshiri and Bhargava are in the Department of Radiology at the University of Washington School of Medicine, and Dr. Bhargava is also Staff Radiologist at the VA Puget Sound Health Care System, Seattle WA. Contact Dr. Mehra at msunny1973@yahoo.com.

Competing Interests: The authors have declared that no competing interests exist.

DOI: 10.2484/rcr.v7i4.792

Spindle-cell sarcoma of the heart: A rare cause for a cardiac mass

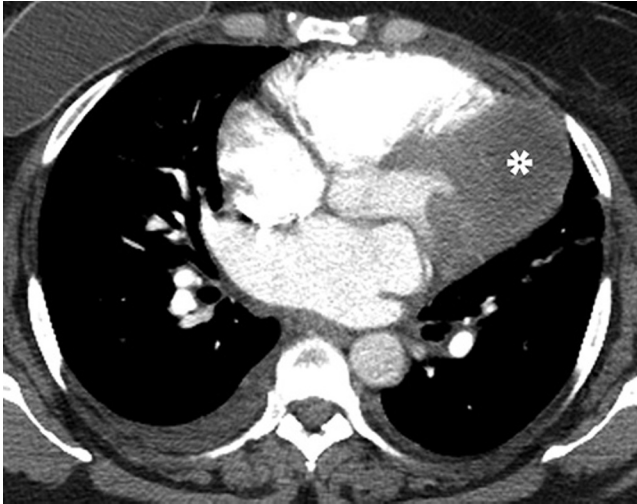


Figure 1. 46-year-old female with spindle-cell sarcoma of the heart. Axial CT angiography image showed a large mass (asterisk) in the region of the left ventricle. Incidentally noted were also a small right pleural effusion and a right breast implant.

walls. The mass was heterogeneous in signal intensity, with peripheral enhancement on the delayed images. Central areas of nonenhancement were seen, likely due to necrosis. LV was mildly dilated, with severe hypokinesis/akinesis of the basal to apical anterior wall. The estimated LVEF was 45-50%.

The cardiothoracic surgery unit recommended a PET-CT, which revealed hypermetabolic activity along the anterior and anterolateral wall of the left ventricle corresponding to the location of the mass seen on CT. Differential considerations included metastatic breast carcinoma and sarcoma. The patient subsequently underwent a left anterior thoracotomy. Intraoperatively, the mass on the anterior lateral surface of the left ventricle was identified, which was

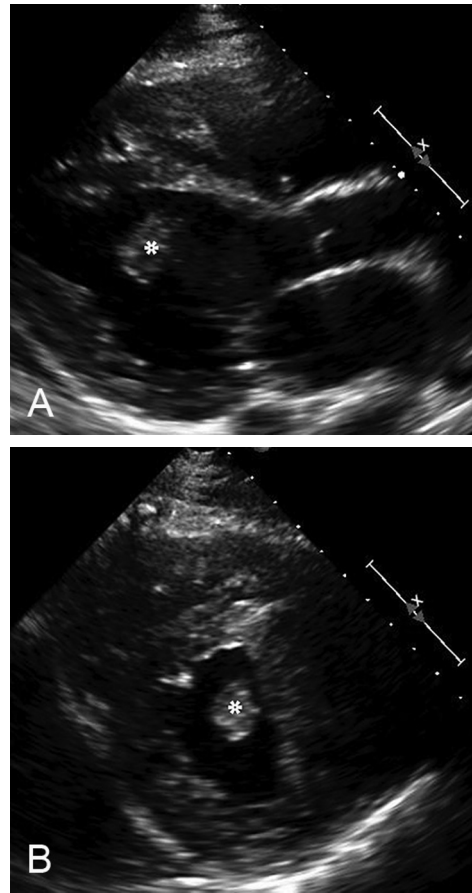


Figure 2. 46-year-old female with spindle-cell sarcoma of the heart. Parasternal long-axis (A) and short-axis (B) views showed an echogenic mass in the left ventricular lumen (asterisk) and thickening of the left ventricular wall.

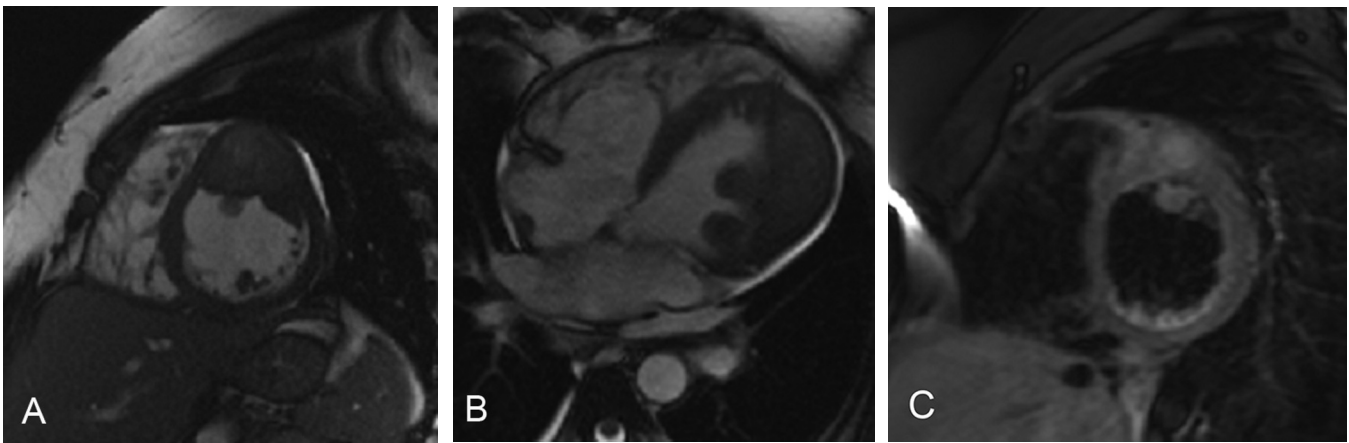


Figure 3. 46-year-old female with spindle-cell sarcoma of the heart. Short-axis (A) and 4-chamber (B) bright-blood MRI images showed a mass in the left ventricle with predominantly hyperintense T2 signal. A fat-suppressed, postcontrast, T1-weighted, short-axis image (C) showed heterogeneous enhancement in the mass lesion.

Spindle-cell sarcoma of the heart: A rare cause for a cardiac mass

lateral to the left anterior descending artery and superior from the apex. Neovascularity was noted on the surface of the mass. The location of the mass was confirmed by palpation on transesophageal echocardiography. The first set of specimens was sent for frozen section, the result of which was consistent with carcinoma with spindle-cell elements. After the frozen section, two additional core needle biopsies were taken. Postoperatively, the patient developed hypotension and acute kidney injury, for which she required vasopressor support and intravenous fluids. She improved gradually and was weaned off vasopressor support. Diuretic therapy resumed. Pericardial fluid cytology and cell block yielded reactive mesothelial cells and macrophages. Cells diagnostic of malignancy were not identified. A left-ventricular-mass core biopsy (Fig. 4) was performed. The tumor had a Ki-67 proliferative index of 80%. Tumor cells were negative for AE1/3, actin, desmin, ALK-1, HMB-45, CD31, CD34, and S-100. A preliminary diagnosis of unclassified, high-grade, spindle-cell sarcoma was made. Due to a large tumor burden, our patient was considered inoperable and is currently receiving chemotherapy. After chemotherapy, her surgical options will be re-evaluated.

Discussion

Transthoracic echocardiography (TTE) is the primary imaging modality for the initial diagnosis of intracardiac masses. TTE is noninvasive and inexpensive, and it provides functional information in addition to morphological details in multiple planes. However, its effectiveness can be limited by patient habitus and operator experience. Transesophageal echocardiography (TEE) provides better resolution, as it allows for use of higher-frequency transducers. However, besides being an invasive procedure, TEE also provides limited soft-tissue characterization and visualization of the mediastinum. Imaging with CT overcomes some of the limitations of echocardiography and provides superior soft-tissue contrast, with improved detection of fat and calcification. Cardiac MRI (CMRI) has even better soft-tissue characterization than CT and echocardiography, and allows functional assessment. CMRI is useful in the depiction of extracardiac involvement and intrinsic myocardial disease. The limitations of CMRI include cost and dependence on regular electrocardiographic rhythms and cardiac gating (5).

Metastatic cardiac tumors outnumber primary cardiac tumors by 20-40 times. The most common primary cardiac tumor is angiosarcoma, which tends to involve the pericardium and occurs most often in the right atrium. Rhabdomyosarcoma is the most common primary cardiac malignancy in children and tends to favor involvement of the valves. Undifferentiated sarcomas are most commonly seen to occur in the left atrium. Some of the other pathological types include fibrosarcoma, primary osteogenic cardiac sarcoma, leiomyosarcoma, liposarcoma, and primary cardiac lymphomas. Primary cardiac lymphomas are seen most commonly in immunocompromised individuals and may respond to chemotherapy. Leiomyosarcoma, primary osteogenic cardiac sarcoma, and fibrosarcoma tend to favor

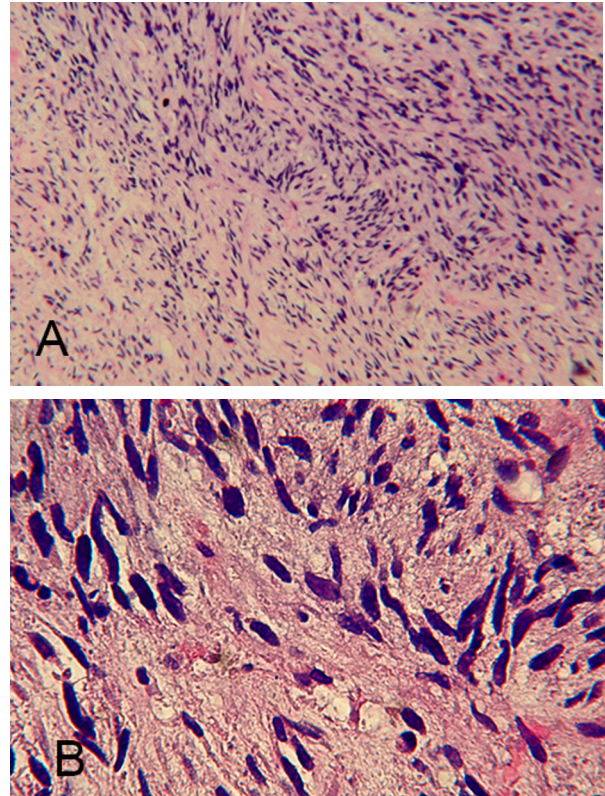


Figure 4. 46-year-old female with spindle-cell sarcoma of the heart. Low-power 4x (A) and high-power 40x (B) images. On pathology, highly cellular spindle-cell proliferation in a fascicular growth pattern was noted, along with hemangiopericytoma-like vasculature ("staghorn" configuration) surrounded by spindle cells. The cells had a scant amount of acidophilic cytoplasm, and the nuclei were cigar-shaped or blunt-ended and curved with variable atypia. Mitotic figures were common (6-10 per high-power field), and atypical mitosis was also seen.

the left atrium. Liposarcomas often present as large infiltrating masses, while osteogenic sarcomas may be distinguished by the frequent presence of calcification. Advances in imaging technology now allow for earlier detection of these rare malignancies (5).

Wide surgical resection is the cornerstone for therapy for cardiac sarcomas. Some cardiac tumors are sensitive to radiation and chemotherapy. Cardiac transplantation is sometimes considered for eligible patients with inoperable sarcomas. Park JH et al (6) have described a 59-year-old female who initially presented with chest pain and had coronary angiography, revealing critical stenosis of the left main coronary artery ostium. Subsequent echocardiography showed pericardial effusion; after that, coronary multidetector computed tomography (MDCT) angiography showed a cardiac mass compressing the left main coronary artery ostium. The patient was treated with radical surgical excision of the tumor mass. Microscopic examination of the tumor revealed spindle cells exhibiting nonspecific dif-

Spindle-cell sarcoma of the heart: A rare cause for a cardiac mass

ferentiation. Mayer F et al (7) described a series of 14 patients with sarcomas arising from the heart or the great vessels. One of the patients had a polymorphic spindle-cell sarcoma, which responded very well to complete resection and palliative chemotherapy with Doxorubicin and Ofosfamide. This patient had no evidence of disease at 156 months of followup. The median survival among patient in this case series was 17 months. Certain histological types, like Ewing's sarcoma and potential embryonal rhabdomyosarcoma (PNET), were more responsive to chemotherapy. Even if curative resection is not achievable, surgical debulking may provide hemodynamic relief.

Although we have made considerable advances in imaging techniques, early detection of cardiac sarcomas is limited by lack of early symptoms and subsequent delay in patient presentation. Prognosis depends on the histopathology as well as the location and extent of the specific tumors.

Acknowledgements:

We would like to acknowledge Rongqin Ren, PGY-2 Resident, Dept. of Pathology, ECU Greenville, NC, for her assistance in procuring the pathology images and in formulating the legends for the pathology images.

References

1. Straus MR. Primary tumors of the heart. *Arch Pathol* 1945; 39:74-78.
2. Reynen K. Cardiac myxomas. *N Engl J Med* 1995; 333:1610-1617. [[PubMed](#)]
3. Burke AP, Cowan D, Virmani R. Primary sarcomas of the heart. *Cancer* 1992; 69:387-395. [[PubMed](#)]
4. G. Shanmugam. Primary cardiac sarcoma. *European Journal of Cardio-thoracic Surgery* 2006; 29:925-932. [[PubMed](#)]
5. Araoz PA, Eklund HE, Welch TJ, Breen JF. CT and MR imaging of primary cardiac malignancies. *Radiographics* 1999; 19:1421-1434. [[PubMed](#)]
6. Park JH, Choe H, Jang WI, Hur G. Primary pericardial spindle cell sarcoma mimicking left main coronary artery disease. *European Journal of Cardio-Thoracic Surgery* 2012; 41:1179-1181. [[PubMed](#)]
7. Meyer F, Aebert H, Rudert M, et al. Primary malignant sarcomas of the heart and great vessels in adult patients - A single-center experience. *The Oncologist* 2007; 12:1134-1142. [[PubMed](#)]