



Case report

Glaucomatous optic disc changes despite normal baseline intraocular pressure in a child



Brent B. Hoffman^b, Eldar Rosenfeld^{a,c}, Alana L. Grajewski^a, Ta C. Chang^{a,*}

^a Bascom Palmer Eye Institute, The University of Miami Miller School of Medicine, 900 NW 17th Street 450N, Miami, FL, 33136, USA

^b The Brody School of Medicine at East Carolina University, 600 Moye Boulevard, Greenville, NC, 27834, USA

^c Tel Aviv Sourasky Medical Center, Weizmann St 6, Tel Aviv-Yafo, 6423906, Israel

ARTICLE INFO

Keywords:

Childhood glaucoma
Sickle cell disease
Normal-tension glaucoma
Optic disc cupping
Retinal nerve fiber layer

ABSTRACT

Purpose: We describe a case of normal tension glaucoma in the setting of sickle cell disease in a 9-year-old patient with a five-year follow up.

Observations: A 9-year-old male patient with a history of sickle cell disease presented initially at the age of 4 years for evaluation of a brief episode of nonspecific eye pain that had spontaneously resolved prior to the clinic visit. Over the course of several years, the patient was noted to have progressive optic disc cupping bilaterally, retinal nerve fiber layer thinning bilaterally, and has developed a corresponding inferior arcuate defect on automated visual field testing in the right eye, all without elevated intraocular pressures (IOP). After neuro-ophthalmic pathologies were ruled out, the patient was diagnosed with glaucoma associated with sickle cell disease and normal baseline IOP, and brimonidine therapy was initiated.

Conclusions and Importance: To our knowledge, this is the first reported case of normal-tension glaucoma in a pediatric patient. Normal-tension glaucoma may be a consideration in the evaluation of pediatric glaucoma suspects, but remains a diagnosis of exclusion.

1. Introduction

In the diagnosis of childhood glaucoma, elevated intraocular pressure (IOP) is one of the several defining characteristics.¹ To date, there have been no convincing documented cases of progressive, glaucomatous optic neuropathy in children without elevated IOP in the ophthalmic literature. In this report, we describe a child with progressive glaucoma in the setting of normal IOP.

2. Case report

A 4-year-old African American boy initially presented for evaluation of a brief episode of nonspecific eye pain that had spontaneously resolved prior to the clinic visit. The patient is a product of full-term gestation, delivered by spontaneous vaginal delivery without complications. Medical history includes sickle cell disease, autoimmune hepatitis, asthma, and mild chronic cardiac ventricular dilation. On exam, the patient was asymptomatic, had a best-corrected visual acuity (BCVA) of 20/30 right eye (OD) and 20/25 left eye (OS) at distance without correction. IOP by rebound tonometry was 21 mmHg both eyes (OU; Icare USA, Raleigh, NC, USA). Slit lamp examination of the

anterior segments were unremarkable. Dilated fundus exam revealed optic disc cupping with cup/disc ratio of 0.5 OD and 0.55 OS, and the posterior poles were otherwise normal. Given the sickle cell disease history, the patient was referred to a pediatric retinal specialist for routine surveillance of sickle cell retinopathy, and was asked to return in one year for a comprehensive eye exam.

Three months following the initial presentation, during the routinely scheduled retinal evaluation, the patient was noted to have a nontraumatic subhyaloid hemorrhage in the left eye. He was monitored closely without surgical intervention, and the hemorrhage resolved spontaneously after six weeks. Genetics evaluation confirmed sickle cell disease but revealed no other systemic syndromes or hematologic issues.

Thirteen months after initial presentation, the now 6-year-old patient returned for routine comprehensive examination. He had BCVA of 20/20 OU, with a mild myopic cycloplegic refraction (−1.75 sphere OU). IOP were 18 mmHg OD and 17 mmHg OS by both Tonopen (Reichert technologies, Depew, NY, USA) and rebound tonometry. Cup/disc ratio was noted as 0.55 OD and 0.6 OS. Contact pachymetry revealed central corneal thickness of 586 μm OD and 589 μm OS (DGH Technology, Inc., Eton, PA, USA). Optical coherence tomography

* Corresponding author. 900 NW 17th Street, 450N, Miami, FL, 33136, USA.

E-mail address: t.chang@med.miami.edu (T.C. Chang).

<https://doi.org/10.1016/j.ajoc.2018.12.012>

Received 4 October 2018; Received in revised form 26 November 2018; Accepted 13 December 2018

Available online 14 December 2018

2451-9936/© 2018 The Authors. Published by Elsevier Inc. This is an open access article under the CC BY-NC-ND license

(<http://creativecommons.org/licenses/by-nc-nd/4.0/>).

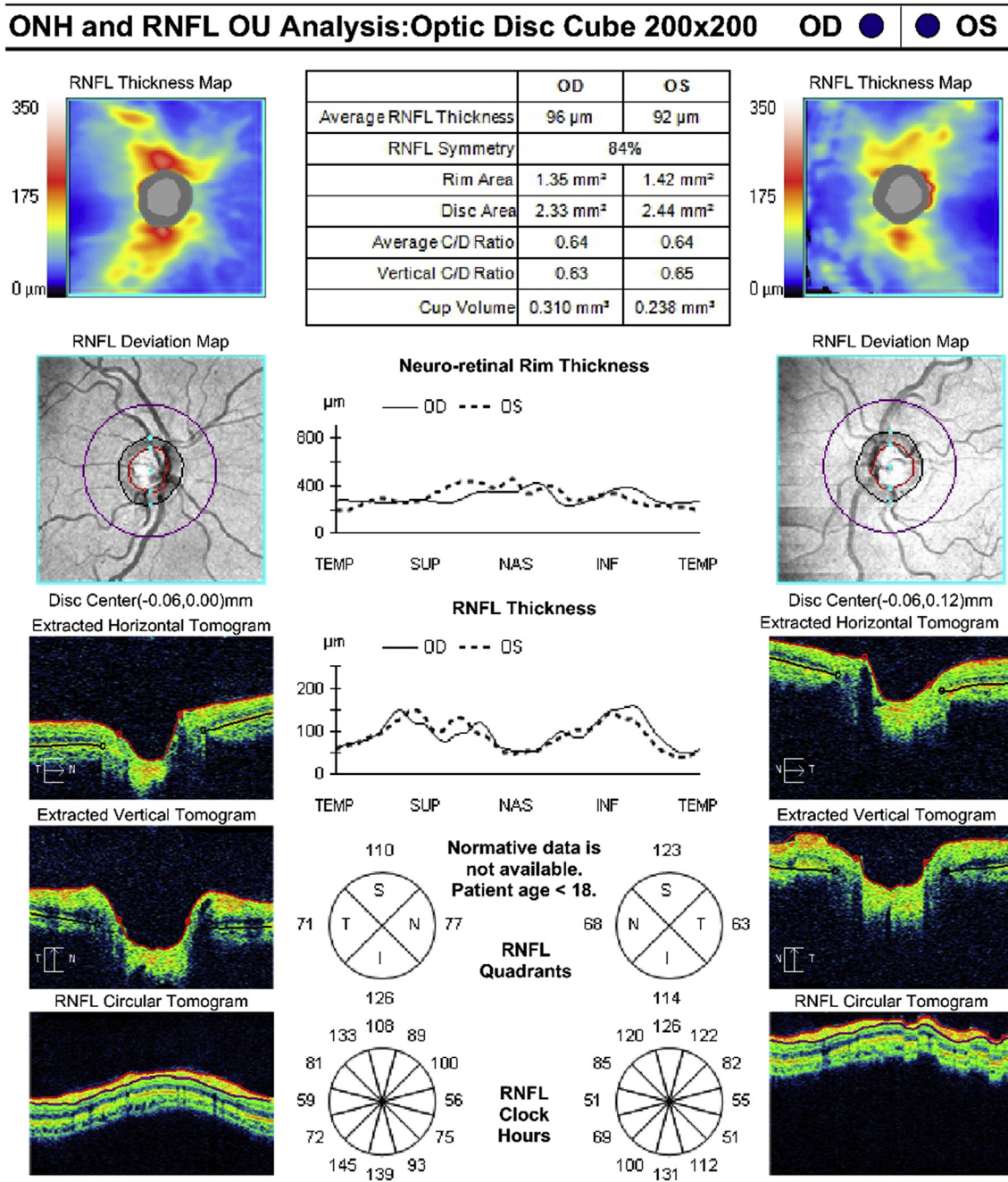


Fig. 1. Bilateral optical coherence tomographic retinal nerve fiber layer analyses at the age of 7 years. A. Right eye intraocular pressure at this visit was 17 mmHg, with an average retinal nerve fiber layer thickness of 96 μm . B. Left eye intraocular pressure at this visit was 16 mmHg, with an average retinal nerve fiber layer thickness of 92 μm .

(Cirrus HD-OCT, Carl Zeiss Meditec, Inc., Dublin, CA, USA) retina nerve fiber layer (OCT-RNFL) average thicknesses were 104 μm OD and 100 μm OS. The patient was thought to be a low-risk juvenile open angle glaucoma suspect due to the disc appearance, and was scheduled for routine exam with the pediatric glaucoma service in 6 months.

Over the next three years, the patient was seen seven times between the pediatric glaucoma and pediatric retina clinics, with stable BCVA of 20/25 OD and 20/20 OS (cycloplegic refraction was -4.75 diopters OD and -6.25 diopters OS) at the most recent follow up (age 9 years). IOP ranged from 14 to 21 mmHg OD and 14–22 mmHg OS (Tonopen and rebound tonometer) with visits that spanned both mornings and afternoons.

Over the same time period, serial OCT-RNFL examination revealed

progressive thinning from a baseline of 104/100 μm (right/left eyes, respectively) to 96/92 μm one year later (Fig. 1), 90/84 μm two years later (Fig. 2), and 84/80 μm three years later (Fig. 3). Concentric enlargement of the optic cup with superior thinning was noted in the right eye on serial stereo photographs (Fig. 4). Repeated automated visual field examination revealed an inferior arcuate defect in the right eye which corresponded to a focal superior thinning on OCT-RNFL, and is normal in the left eye (Fig. 5). Gonioscopy revealed bilaterally wide-open angles with rare iris processes and no pigment. A detailed review of medical history revealed no chronic steroid exposure.

The patient was referred to and evaluated by a pediatric neuro-ophthalmologist, who noted intact color vision and no other neuro-ophthalmic pathologies. Magnetic resonance imaging of the orbit and

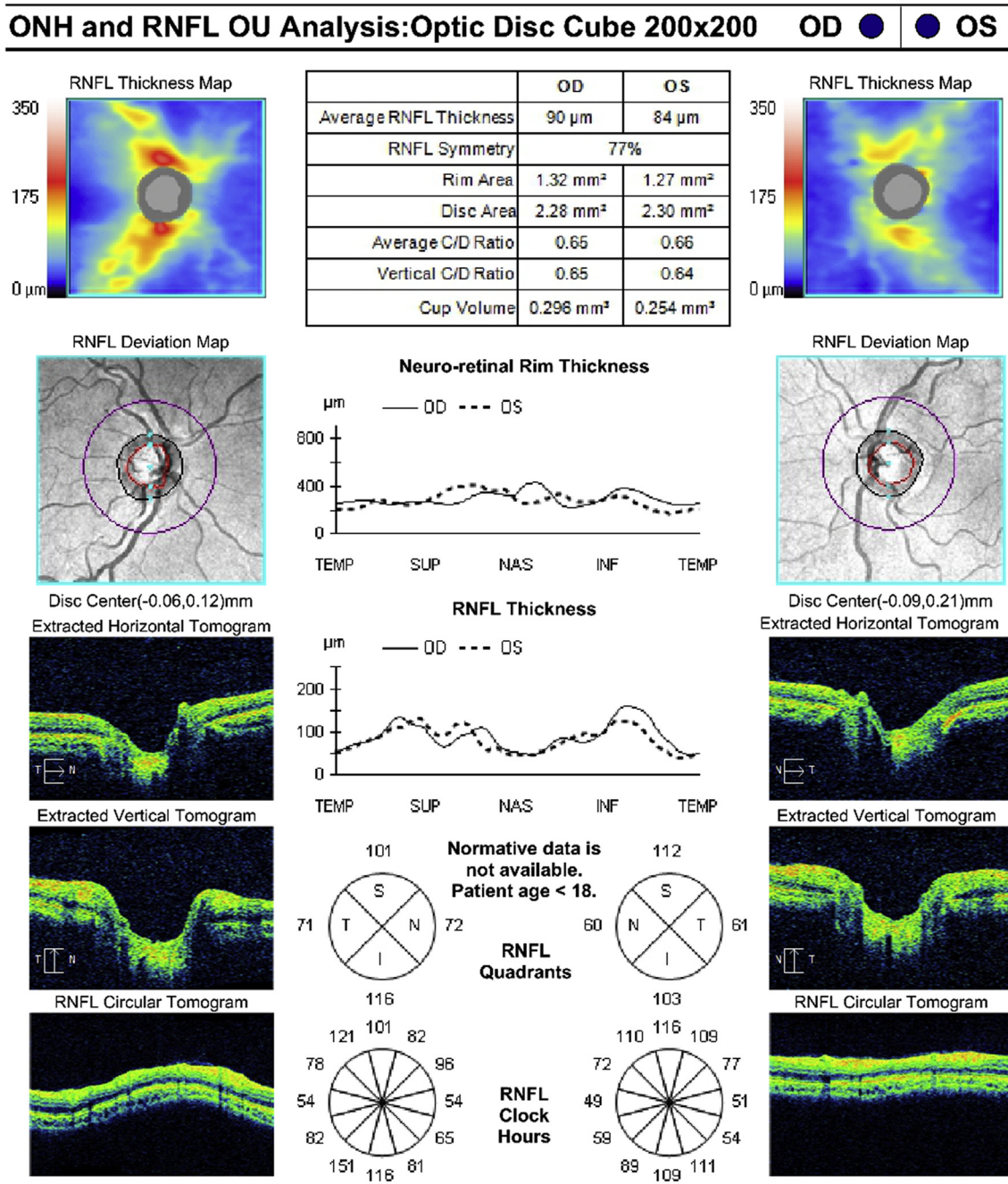


Fig. 2. Bilateral optical coherence tomographic retinal nerve fiber layer analyses at the age of 8 years. A. Right eye intraocular pressure at this visit was 17 mmHg, with an average retinal nerve fiber layer thickness of 90 μm . B. Left eye intraocular pressure at this visit was 17 mmHg, with an average retinal nerve fiber layer thickness of 84 μm .

brain were unremarkable. At this time, the patient was diagnosed with glaucoma associated with sickle cell disease and normal baseline IOP, and topical brimonidine (0.15%) therapy was initiated.

3. Discussion

When progressive optic disc cupping occurs with normal IOP in a young patient, there are several possibilities to consider. First, the cupping may be glaucomatous in a patient with labile IOP. Our patient does not have stigmata of entities that may result in intermittent IOP elevations, such as uveitis or pigment dispersion, which makes this scenario less likely. His myopic refraction (without spherophakia) in addition to his bilaterally open angles also make intermittent pupillary

block unlikely. The patient had a history of spontaneous subhyaloid hemorrhage and we cannot discount the possibility of intermittent, spontaneous hyphema and labile IOP causing progressive glaucomatous damage, although the patient has never demonstrated active neovascularization of the anterior segment on multiple examinations. While diurnal IOP assessment was not performed, our patient's clinic visits spanned both morning and afternoon hours and there were no significant IOP fluctuations. Second, the cupping may be non-glaucomatous, and the progressive RNFL thinning and concentric cupping may be due to a neuro-ophthalmic etiology. Our patient had undergone a comprehensive neuro-ophthalmic evaluation with neuroimaging, which failed to reveal secondary causes. Third, the cupping may be an artifactual finding, especially in a child with

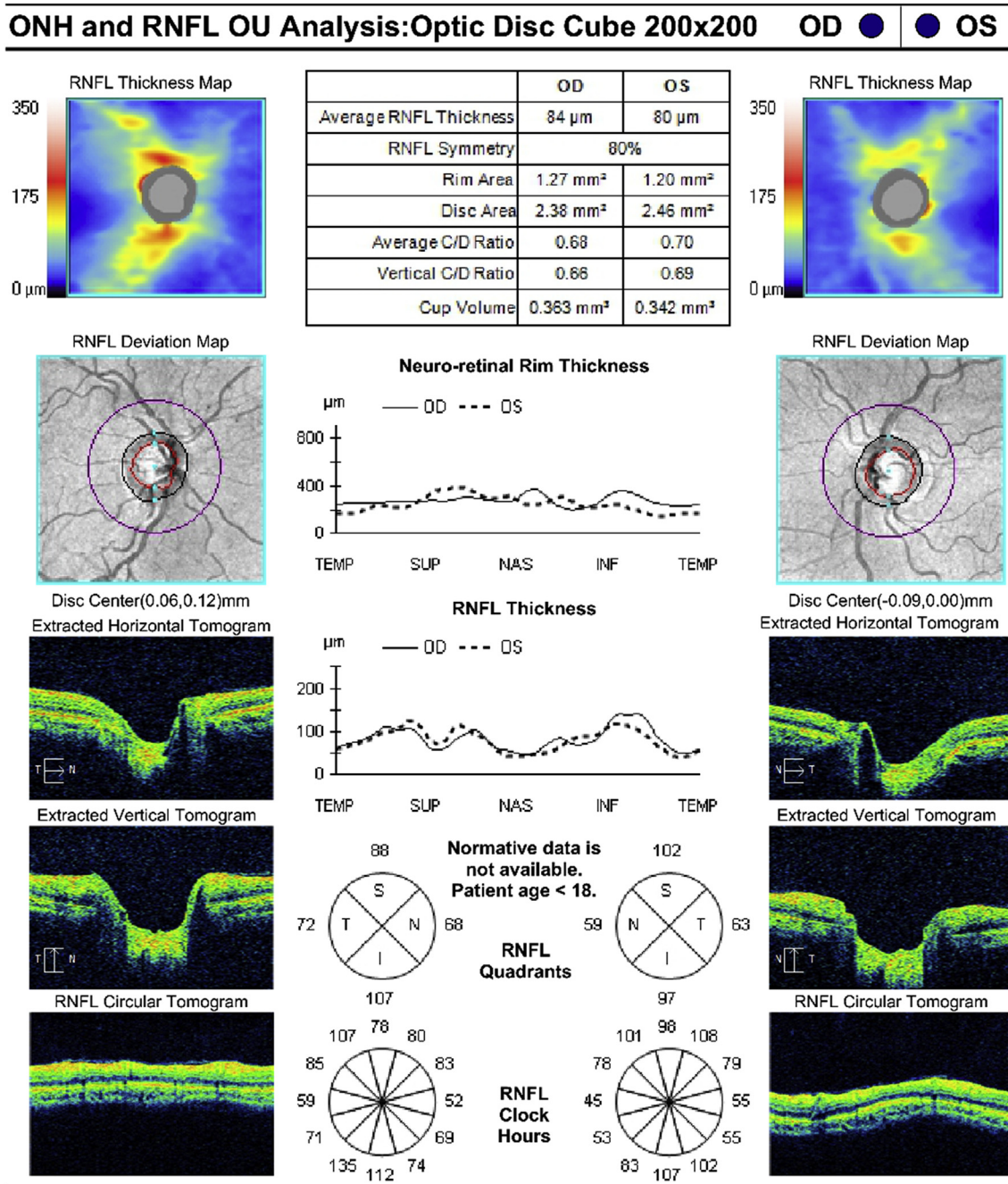


Fig. 3. Bilateral optical coherence tomographic retinal nerve fiber layer analyses at the age of 9 years documenting a bilateral decrease in the mean retinal nerve fiber layer thickness in the context of normal intraocular pressure bilaterally. A. Right eye intraocular pressure at this visit was 16 mmHg, with an average retinal nerve fiber layer thickness of 84 μm , a decrease from the baseline of 96 μm . B. Left eye intraocular pressure at this visit was 14 mmHg, with an average retinal nerve fiber layer thickness of 80 μm , a decrease from the baseline of 92 μm .

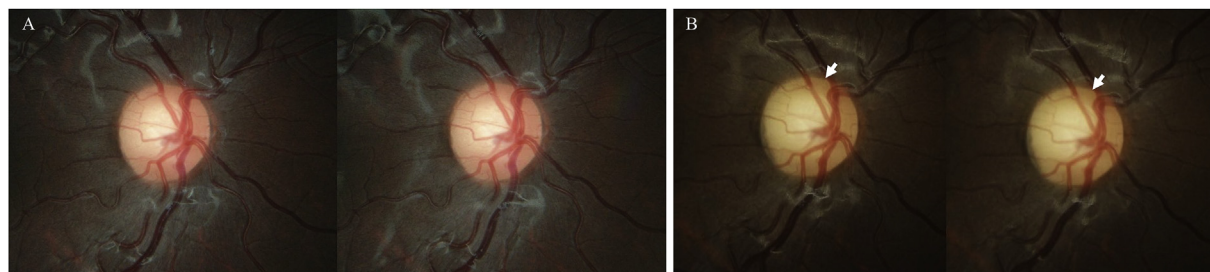


Fig. 4. A. Baseline photograph of the right optic disc taken at the age of 7 years, 3 years after initially presenting. B. Follow up photograph of the right optic disc taken at the age of 9 years, revealing concentric enlargement of the optic cup with thinning of the superior rim (arrow).

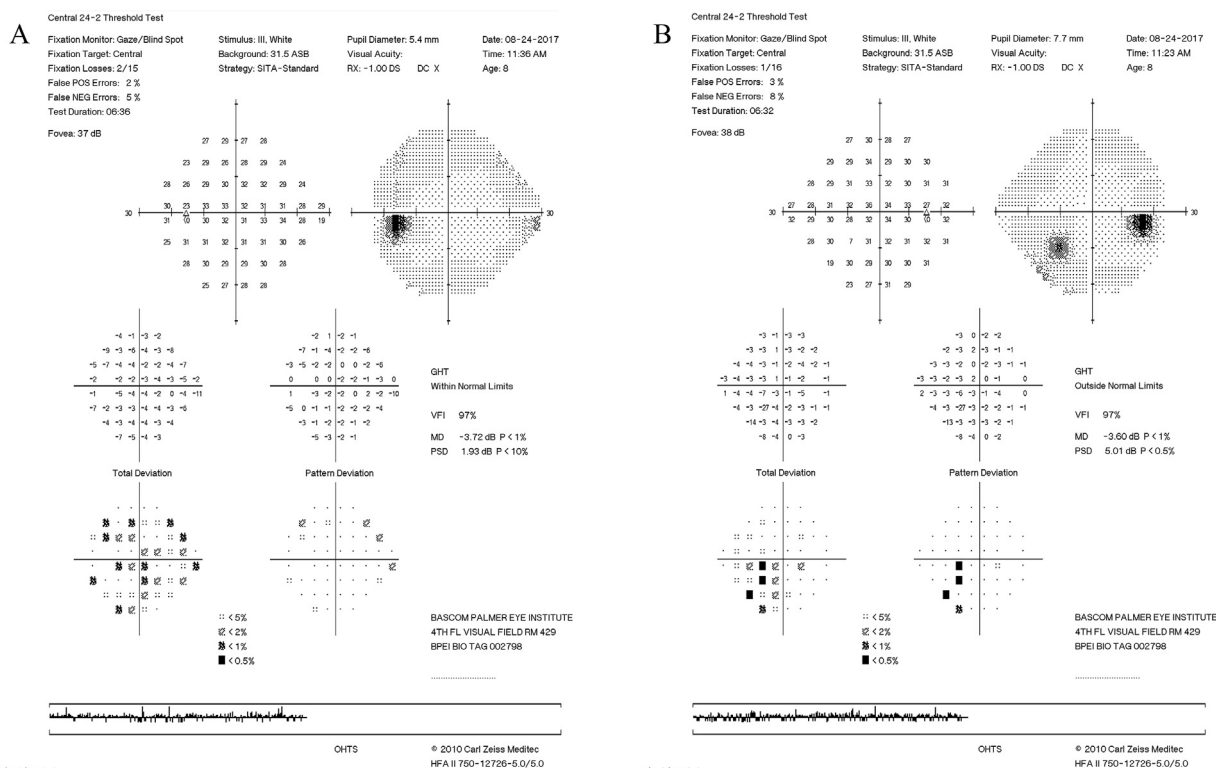


Fig. 5. A. A normal automated visual field examination of the left eye performed at the age of 8 years. B. Automated visual field examination of the right eye performed at the age of 8 years with a confirmed inferior arcuate defect.

progressive myopia, although the corroborating ancillary examinations findings (both OCT-RNFL and stereo photographs) as well as the appearance of a visual field defect that corresponds to the area of RNFL loss make this unlikely. Lastly, as a diagnosis of exclusion, the cupping maybe due to an ongoing glaucomatous process in the context of normal IOP.

In 2013, the 9th World Glaucoma Association Consensus panel, in conjunction with the Childhood Glaucoma Research Network (CGRN), established the diagnostic criteria for childhood criteria to include elevated IOP (> 21 mmHg on two or more occasions) in all diagnostic categories.¹ Since then, to our knowledge, there have been no convincing reports of normal-tension glaucomatous progression in a child in the ophthalmic literature until this current case. Our patient has multiple systemic issues stemmed from sickle cell disease, and the role of microangiopathy on the susceptibility of glaucomatous damage is uncertain, although vascular dysfunction and ischemia have been considered as important risk factors in the progression of normal-tension glaucoma.^{2–5} In one cross-sectional study comparing adult patients with and without sickle-cell hemoglobinopathies, sickle-cell patients had thinner macula and peripapillary retinal nerve fibers compare to controls.⁶ However, most glaucoma associated with sickle cell disease are due to elevated IOP caused by neovascular closure of the angle and/or recurrent hyphema.^{7,8}

4. Conclusion

Currently, while elevated IOP remains a diagnostic feature in childhood glaucoma, normal-tension glaucoma may be a rare but noteworthy entity in the evaluation of pediatric glaucoma suspects, especially in patients with microangiopathic risk factors.

Patient consent

This report does not contain any personal health information that could lead to the identification of the patient. A consent to use clinical

photographs and examination results for publication and educational purposes was obtained in writing prior to all ancillary tests.

Acknowledgements and disclosures

Funding

This study was supported by the Research to Prevent Blindness Unrestricted Grant (New York, New York) and by the National Eye Institute core grant P30-EY14801 (Bethesda, Maryland). The funding agencies had no role in the design or conduct of this research.

Conflicts of interest

The following authors have no financial disclosures: BBH, ER, ALG, and TCC.

Authorship

All authors attest that they meet the current ICMJE criteria for authorship.

Acknowledgements

None.

References

1. Beck A, Chang TC, Freedman S. Section 1: definition, classification, differential diagnosis. In: Weinreb RN, Grajewski A, Papadopoulos M, Grigg J, Freedman S, eds. *World Glaucoma Association Consensus Series – 9: Childhood Glaucoma*. Amsterdam, The Netherlands: Kugler Publications; 2013:3–10.
2. Collaborative Normal-Tension Glaucoma Study Group. Comparison of glaucomatous progression between untreated patients with normal-tension glaucoma and patients with therapeutically reduced intraocular pressures. *Am J Ophthalmol*. 1998 Oct;126(4):487–497 Erratum in: *Am J Ophthalmol* 1999 Jan;127(1):120. PubMed

- PMID: 9780093.
3. Flammer J, Orgül S, Costa VP, et al. The impact of ocular blood flow in glaucoma. *Prog Retin Eye Res.* 2002;21:359–393.
 4. Demailly P, Cambien F, Plouin PF, Baron P, Chevallier B. Do patients with low tension glaucoma have particular cardiovascular characteristics? *Ophthalmologica.* 1984;188:65–75.
 5. Tielsch JM, Katz J, Sommer A, Quigley HA, Javitt JC. Hypertension, perfusion pressure, and primary open-angle glaucoma. A population-based assessment. *Arch Ophthalmol.* 1995;113:216–221.
 6. Chow CC, Shah RJ, Lim JI, Chau FY, Hallak JA, Vajaranant TS. Peripapillary retinal nerve fiber layer thickness in sickle-cell hemoglobinopathies using spectral-domain optical coherence tomography. *Am J Ophthalmol.* 2013 Mar;155(3):456–464. <https://doi.org/10.1016/j.ajo.2012.09.015>. pub 2012 Dec 4 e2.
 7. Gharaibeh A, Savage HI, Scherer RW, Goldberg MF, Lindsley K. Medical interventions for traumatic hyphema. *Cochrane Database Syst Rev.* 2013 Dec;3(12):CD005431.
 8. Bergren RL, Brown GC. Neovascular glaucoma secondary to sickle-cell retinopathy. *Am J Ophthalmol.* 1992 Jun 15;113(6):718–719.