

IDH1 Expression via the R132H Mutation— Specific Antibody in Adrenocortical Neoplasias—Prognostic Impact in Carcinomas

Mirkka Pennanen,¹ Olli Tynnenen,¹ Soili Kytölä,² Pekka Ellonen,³ Harri Mustonen,⁴
Ilkka Heiskanen,⁴ Caj Haglund,^{4,5,*} and Johanna Arola^{1,*}

¹Department of Pathology, University of Helsinki and Helsinki University Hospital, 00014 Helsinki, Finland;

²Department of Genetics, University of Helsinki and Helsinki University Hospital, 00014 Helsinki, Finland;

³Institute for Molecular Medicine Finland, HiLIFE, University of Helsinki, 00014 Helsinki, Finland; ⁴Department of Surgery, University of Helsinki and Helsinki University Hospital, 00014 Helsinki, Finland; and ⁵Translational Cancer Medicine Research Program, Faculty of Medicine, University of Helsinki, 00014 Helsinki, Finland

*C.H. and J.A. share last authorship of this work.

Context: Mutations to isocitrate dehydrogenase (IDH) appear to play a prognostic or predictive role in several neoplasias. Immunohistochemical staining designed to detect a specific R132H mutation to IDH1 showed expression in the normal adrenal cortex, raising interest to study the potential role of IDH1 in the pathogenesis of adrenocortical tumors.

Objective: The objective of this work is to study the role of IDH1 and its mutations in adrenocortical tumors.

Design and patients: *IDH1* R132H immunohistological staining was performed on a cohort of 197 adrenocortical tumors. The exon of the *IDH1* gene was sequenced in 16 tumors.

Results: Positive IDH1 R132H immunohistochemical staining correlated with a better prognosis among patients with a malignant adrenocortical tumor. However, IDH1 R132H immunohistochemistry did not distinguish between local and metastasized tumors. We were unable to identify IDH1 mutations among our adrenocortical tumors using a targeted next-generation sequencing panel or via exon sequencing.

Conclusions: Among adrenocortical carcinomas, IDH1 R132H immunopositivity correlated with a better prognosis. Thus, IDH1 R132H immunohistochemical staining could serve as a prognostic or as a potential predictive marker in adrenocortical carcinomas. Further research is needed to identify the possible alterations in IDH1 that could explain our findings, because we identified no known mutations to the *IDH1* gene.

© Endocrine Society 2020.

This is an Open Access article distributed under the terms of the Creative Commons Attribution-NonCommercial-NoDerivs licence (<http://creativecommons.org/licenses/by-nc-nd/4.0/>), which permits non-commercial reproduction and distribution of the work, in any medium, provided the original work is not altered or transformed in any way, and that the work is properly cited. For commercial re-use, please contact journals.permissions@oup.com

Key Words: adrenocortical tumor, IDH1, adrenocortical carcinoma, IDH R132H

Abbreviations: FFPE, formalin-fixed paraffin-embedded; IDH, isocitrate dehydrogenase; TMA, tissue microarray.

Received 21 October 2019

Accepted 15 February 2020

First Published Online 18 February 2020

Corrected and Typeset 13 March 2020.

April 2020 | Vol. 4, Iss. 4

doi: 10.1210/jendso/bvaa018 | Journal of the Endocrine Society | 1–10

Adrenocortical tumors have emerged as an important clinical issue given the widespread use of high-resolution imaging and the increased prevalence of these lesions. Most adrenocortical tumors are benign adenomas that can be cured through the unilateral removal of the adrenal gland. Rare adrenocortical carcinomas are accompanied by a poor prognosis, and postoperative treatment options for them remain scarce. Understanding the pathogenesis of adrenocortical tumors would lead to the more accurate diagnosis of these tumors and may offer targets for the treatment of malignant tumors.

Isocitrate dehydrogenase (IDH) is a metabolic enzyme, ubiquitous in all cells of the body, responsible for the oxidation of isocitrate to α -ketoglutarate and the conversion of NAD(P)⁺ to NAD(P)H. IDH exists in 3 isoforms. Mutations of IDH isoforms 1 and 2 were first identified in gliomas [1], and have since been reported in several neoplasias [2–5]. The mutated form of IDH gains neomorphic activity, resulting in the conversion of α -ketoglutarate to an oncometabolite, D-2-hydroxyglutarate. The subsequent accumulation of the oncometabolite results in epigenetic dysregulation by inhibition of the α -ketoglutarate-dependent histone and DNA demethylases, and a block in cellular differentiation [6, 7].

In gliomas, the status of an IDH mutation is an important diagnostic and prognostic feature, determined during routine clinical practice. IDH mutations occur in most lower-grade gliomas and secondary glioblastomas, indicative of a distinctive pathogenesis and a better prognosis compared to primary glioblastomas. A specific R132H mutation to IDH1 accompanies approximately 80% of all IDH mutations in gliomas [8], and can be depicted from formalin-fixed, paraffin-embedded (FFPE) tissues through immunohistochemistry using an antibody against the mutated protein [9]. In adrenocortical tumors, IDH1 and IDH2 mutations have thus far remained unreported. Interestingly, another research group in Helsinki found an immunohistochemical positivity for IDH1 R132H in the normal adrenal cortex (oral communication). This finding piqued our interest in examining the IDH1 R132H expression in adrenocortical tumors.

Thus, we aimed to study the role of IDH1 and its possible mutations in a large cohort of clinically verified adrenocortical tumors.

1. Methods

A. Clinical Data and Tumor Material

We identified all adult patients who underwent surgery for a primary adrenocortical tumor at the Department of Surgery, Helsinki University Hospital between 1990 and 2003. The series comprised 195 patients with 197 tumors (2 patients had 2 separate tumors). The tumor specimens were taken from the archives of the Department of Pathology, and clinical data were collected from patient records. We gathered survival data and cause of death information from the Population Register Center and Statistics Finland. The Ethics Committee of Helsinki University Hospital and the National Supervisory Authority for Welfare and Health approved the study protocol.

The clinical characteristics of tumor patients are shown in Table 1. Among the 195 tumor patients, 14 died from adrenocortical carcinoma. These patients had metastatic disease and their survival time ranged from 0.30 to 6.84 years (median, 2.05 years; mean, 2.97 years) after primary surgery. During follow-up, 36 patients died of causes other than an adrenocortical tumor. Among patients alive at the end of the study, the follow-up time ranged from 7.84 to 21.83 years (median, 11.27 years; mean, 12.64 years).

B. Material for Genetic Analysis

To identify mutations of IDH1 at Arg132 using amplicon-based hot spot panel sequencing, we chose 10 tumors with Weiss scores of 3 to 9, 5 of which exhibited strong positive and 5 exhibited negative IDH1 R132H immunohistochemical staining (Fig. 1).

Table 1. Clinical and histological characteristics of tumors, and distribution of isocitrate dehydrogenase 1 R132H immunohistochemical staining

		All Tumors	Local Tumors	Metastatic Tumors	P
No. of tumors		197	183	14	
Age, y	Range	24-82	24-82	32-76	.777
	Mean	54.2	54.3	53.5	
	Median	55	54	55.5	
Sex ^a	Male	66	60	6	.560
	Female	129	121	8	
Side	Right	101	93	8	.784
	Left	96	90	6	
Size, cm	Range	0.5-28.0	0.5-28.0	4-22	< .001
	Mean	3.4	2.8	12.1	
	Median	2	2	12.5	
Hormonal secretion					
Aldosterone	No.	96	94	2	.010
	%	49	51	14	
Cortisol	No.	74	67	7	.394
	%	38	37	50	
Androgens	No.	11	7	4	.004
	%	6	4	29	
Inactive	No.	29	24	5	.038
	%	15	13	36	
Weiss score	0-2	164	164	0	< .001
	3-9	33	19	14	
Helsinki score ^b	< 8.5	177	177	0	< .001
	≥ 8.5	17	3	14	
IDH1 R132H score ^c	0	133	122	11	.359
	1-3	62	59	3	
	1	46	44	2	
	2	14	13	1	
	3	2	0		

Abbreviation: IDH1, isocitrate dehydrogenase 1.

^aOne man and one woman had 2 separate tumors.

^bThe Helsinki score was determined for 194 tumors.

^cIDH1 R132H immunohistochemistry was available for 195 tumors.

For *IDH1* gene sequencing from the FFPE tumor material, we chose an additional 10 tumors, 5 tumors with Weiss scores of 0 to 2 with positive IDH1 R132H immunohistochemistry, and 5 tumors with Weiss scores of 3 to 9 with low positivity. In total, we analyzed 20 tumors.

Among these 20 tumors, we had fresh-frozen tumor material available for *IDH1* gene sequencing for 16 tumors.

C. Histopathology

The histopathological diagnosis using the Weiss score [10, 11] for each tumor was reviewed by 2 endocrine pathologists (M.P. and J.A.) based on hematoxylin-and-eosin-(H&E) stained sections. The novel Helsinki score, introduced by the authors [12], was also determined. The Helsinki score consists of $3 \times$ mitotic rate ($> 5/50$ hpf) + $5 \times$ presence of necrosis + proliferation index (Ki67/mib index). A score greater than 8.5 indicates metastatic carcinoma with a sensitivity of 100%.

D. Tissue Microarray Construction

Tissue microarray (TMA) blocks were constructed from archived surgical formalin-fixed, paraffin-embedded specimens. Representative areas of each tumor were chosen from

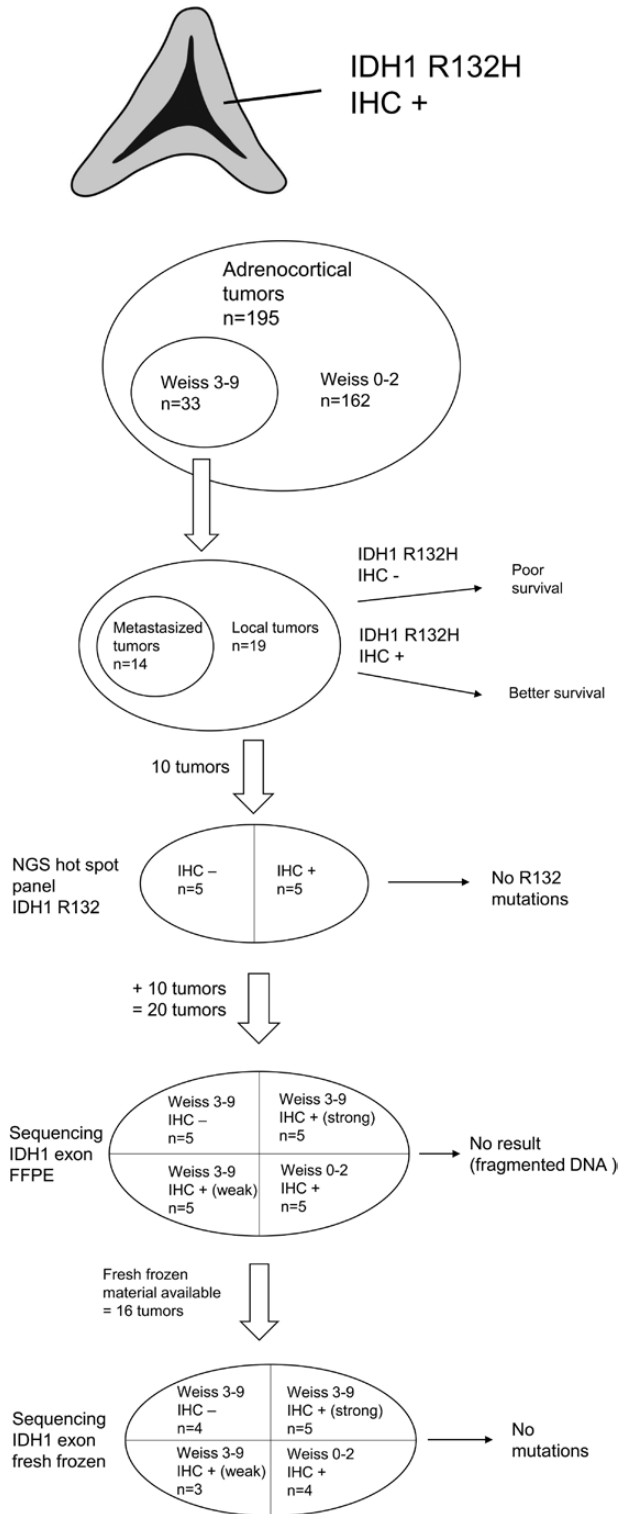


Figure 1. Infograph of our materials and results.

H&E-stained slides. Using a semiautomatic TMA instrument (Beecher Instruments), three 1-mm cores were obtained from each histologically benign (Weiss score 0-2) tumor, and 6 cores were taken from the histologically malignant (Weiss score 3-9) tumors. In addition, 2 cores from the normal adrenal cortex were taken from each specimen.

E. Immunohistochemistry

TMA blocks were cut into 4- μ m sections. For antigen retrieval, slides were treated in a PreTreatment module (Lab Vision Corp) in a Tris-EDTA (pH 9.0) buffer for 20 minutes at 98°C. Immunohistochemical staining was performed using the EnVision polymer detection kit (Dako) in a LabVision Autostainer (Thermo Fisher Scientific). Sections were incubated with the mouse monoclonal IDH1 R132H antibody (clone H09, Dianova) [13] at a dilution of 1:20 for 30 minutes at room temperature. The slides were counterstained with Mayer's Hematoxylin (Lillie's Modification; Dako) and mounted using Mountex (Histolab).

F. Interpretation of Immunohistochemical Staining

IDH1 R132H immunohistochemical expression was determined in 195 tumors. Staining was scored independently by 2 experienced pathologists (M.P. and O.T.). Any discrepancies between scores were resolved through consensus.

The intensity of the cytoplasmic staining of IDH1 R132H, that is the amount of positively staining granules, was scored on a scale from 0 to 3. The staining was fairly evenly distributed throughout the tumor tissue. Therefore, the extension of the staining was not scored. Negative cytoplasmic staining was scored as 0, weakly positive as 1, moderately strongly positive or a focally strong positivity as 2, and a strong positivity as 3. For all of the stained samples for each tumor, the highest score was used for further analysis.

G. Amplicon-Based Hot-Spot Panel Sequencing

DNA was extracted from 10 FFPE samples following deparaffinization using the Maxwell LEV Blood DNA Kit (Promega Corp) according to the manufacturer's instructions. The tumor content of each sample was evaluated from H&E-stained slides by an experienced pathologist (M.P.).

DNA was subjected to library preparation using the Ion AmpliSeq Cancer Hotspot Panel version 2, designed to target 2800 COSMIC mutations from 50 oncogenes and tumor suppressor genes, and sequenced on the Ion Torrent PGM System (Thermo Fisher Scientific). The panel covers 15 and 11 hot-spot regions in IDH1 including the *R132* and *IDH2* genes, respectively. Library preparation, template preparation, and sequencing were carried out according to the manufacturer's instructions (Life Technologies). Data analysis was performed using the Torrent Suite Software version 4.0. After trimming and alignment to the hg19 human reference genome, sequence variants were detected using the VariantCaller version 4.0. The Ion Reporter software version 4.0 was used to filter out noncoding and polymorphic variants.

H. Hybridization Capture-Based Targeted Sequencing

For preparing paired-end libraries, 7000 to 32 000 ng of DNA extracted from FFPE blocks (n = 20) were used. For fresh-frozen samples (n = 16), 2300 to 14 300 ng of DNA was used as the input (ThruPlex DNA-Seq Kit, Rubicon Genomics). Target enrichment was performed using the SeqCap EZ Comprehensive Cancer panel (Roche NimbleGen). The panel covers 9 exons and the 5' untranslated region of the *IDH1* gene, including the mutation sites of the Hot Spot Panel version 2. The enriched libraries were sequenced using the HiSeq2000 instrument with a paired-end 100-bp read length. Sequence analysis and variant calling were performed by an in-house bioinformatics pipeline (VCP, variant calling pipeline [14]). In addition to variant calling algorithms, IDH1 mutation hot-spot loci were also visually inspected from the .bam files using IGV (Integrative Genome Viewer [15]). The library preparation, sequencing, variant calling, and data analysis for this experiment were performed by the FIMM Sequencing Unit, HiLIFE, at the University of Helsinki.

I. Statistical Analysis

Results are stated as the median, range, or the number of patients. Comparison between groups was performed using the Mann-Whitney test and the Fisher exact test for continuous and dichotomous variables, respectively. Correlations were tested by calculating the Spearman rho correlation coefficient. The Kaplan-Meier method with the log-rank test was used to compare survival between groups. We considered a *P* value less than .05 as statistically significant and relied on 2-tailed tests. All analyses were performed using SPSS version 24 (IBM).

2. Results

A. Isocitrate Dehydrogenase 1 R132H Immunohistochemical Staining of Normal Adrenal Cortex and Adrenocortical Neoplasias

The IDH1 R132H immunohistochemical staining appeared as granular cytoplasmic positivity in adrenocortical tumors. A similar staining was seen in the normal adrenal cortex (Fig. 2). The intensity of the staining, that is the amount of positive granules, varied. Fig. 2 shows the pattern and differences in the IDH1 R132H stainings.

The IDH1 R132H staining appeared both in benign and malignant tumors, and negative vs positive staining could not distinguish between local and metastatic disease (*P* = .359). In the entire tumor material, the IDH1 R132H staining (negative vs positive) and Weiss score (0-2 vs 3-9) did not correlate (*P* = .312) nor did the IDH1 R132H staining and Helsinki score (< 8.5 vs ≥ 8.5; *P* = .212). In histologically malignant tumors (Weiss score 3-9), the IDH1 R132H staining (negative vs positive) correlated with the Helsinki score (< 8.5 vs ≥ 8.5; $R^2 = -0.437$, *P* = .012).

Aldosterone secretion of the tumor correlated with a weak IDH1 R132H staining ($R^2 = -0.163$, *P* = .023), whereas cortisol secretion correlated with a strong IDH1 R132H staining ($R^2 = 0.243$, *P* = .001). We found no correlation between the IDH1 R132H staining and testosterone secretion ($R^2 = 0.071$, *P* = .326) or with hormonal inactivity ($R^2 = -0.132$, *P* = .066).

B. Prognostic Significance of Isocitrate Dehydrogenase 1 R132H Immunohistochemistry in Adrenocortical Carcinomas

To examine the possible prognostic significance of the IDH1 R132H staining in adrenocortical carcinomas, we chose all 33 tumors with a Weiss score of 3 to 9, defined as malignant according to the World Health Organization's classification. Patients with a positive IDH1 R132H staining survived longer than patients with a negative staining (*P* = .031; Fig. 3).

C. Amplicon-Based Hot-Spot Panel Sequencing

The data analysis of the hot-spot mutations revealed no mutations in the *IDH1* or *IDH2* genes, with a sensitivity of 2%.

D. Hybridization Capture-Based Targeted Sequencing

From the FFPE-derived samples, we received no informative sequencing data. Initial sequencing provided the mean target coverage of the sequencing depth after the removal of duplicates. Sequencing delivered depths of 115 to 505×; yet, after polymerase chain reaction (PCR) duplicate removal, the informative depth diminished to 2 to 13×. Evidently, the samples contained sufficient DNA molecules (mass), but the mass was heavily cross-linked and/or fragmented, thereby preventing successful library preparation. Such DNA behaves

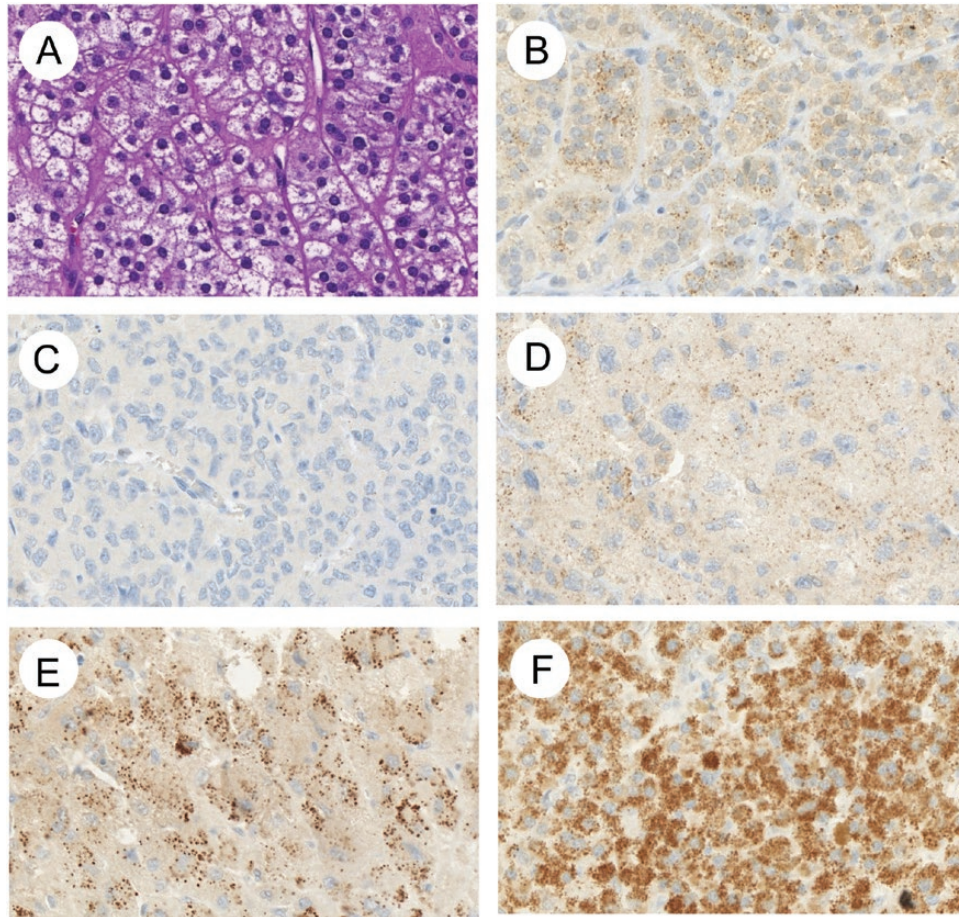


Figure 2. Staining pattern of isocitrate dehydrogenase 1 (IDH1) R132H immunohistochemistry (IHC) in normal adrenal cortex and adrenocortical tumors. A, Hematoxylin and eosin staining and B, IDH1 R132H IHC of normal adrenal cortex. C) Score 0, D, score 1, E, score 2, and F, score 3 of IDH1 R132H IHC. All images are shown at 400× magnification.

seemingly well in PCR amplicons–based methods, but lacks true somatic resolution given the limited number of accessible DNA template molecules.

Using the same protocol for the DNA from fresh-frozen samples, we yielded sequencing depths ranging from 100 to 500× after PCR duplicate removal, which enabled us to perform somatic mutation calling. We failed to identify any known hot-spot mutation or any novel variants in the *IDH1* gene or the untranslated regions [16].

3. Discussion

In a large cohort of adrenocortical tumors, we found that mutation-specific IDH1 R132H immunopositivity correlated with a better prognosis among adrenocortical carcinoma patients, suggesting a distinct pathogenic pathway among these tumors. However, IDH1 R132H immunohistochemistry did not correlate with the prognostic scoring systems used for adrenocortical tumors, such as the Weiss score or the Helsinki score, nor did it distinguish between local and metastasized disease. However, through genetic analysis, we failed to identify any known or novel IDH1 mutations in our adrenocortical tumor cohort.

The IDH1 R132H antibody used for the immunohistochemical staining was developed to specifically recognize the R132H mutated form of the IDH1 protein, the most frequent mutation seen in secondary glioblastomas. All reported pathogenic mutations of IDH1 are

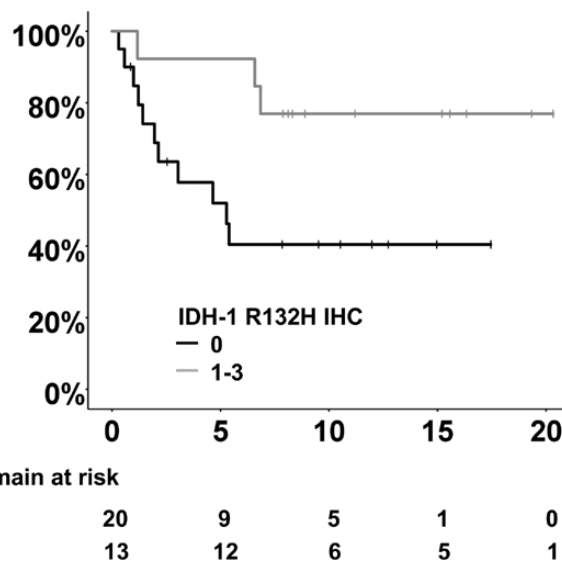


Figure 3. Survival according to isocitrate dehydrogenase 1 (IDH1) R132H immunopositivity for tumors with Weiss score greater than or equal to 3.

heterozygous missense point mutations that alter the conserved binding site of the homodimer enzyme. These most often occur at codon 132 by replacing arginine with another amino acid. To improve the diagnostic procedure of gliomas, Capper et al [9] developed the IDH1 R132H antibody that binds to IDH1, where histidine replaces arginine 132. This mutation-specific antibody does not detect other mutated forms of IDH1, such as R132S, R132C, R132G, or R132L, nor does it bind to or cross-react with wild-type IDH1. We found only one study that reported any positivity in tumor cells using the IDH1 R132H antibody in tumors negative for the R132H mutation through DNA sequencing. Amary and colleagues [4] studied IDH1 and 2 mutations in cartilaginous tumors, finding 5 R132H immunopositive tumors in which the mutation remained undetected through sequencing. They assumed that the amount and proportion of tumor cell DNA in the sample was too low for sequencing, concluding that the IDH1 R132H immunohistochemical staining was, in fact, more sensitive in identifying the mutation than sequencing. Against this background, we were surprised to find IDH1 R132H staining in the normal adrenal cortex and in adrenocortical tumors. Furthermore, we observed a granular cytosolic staining similar to that in IDH1 R132H-mutated gliomas, although less intensive. To verify the specific R132H mutation of IDH1 in these tumors, we performed a next-generation sequencing mutational analysis of codon 132, but failed to detect any of the previously reported mutations. Therefore, we searched for other possible mutations and sequenced the IDH1 exon of 16 tumors. This method revealed no relevant IDH1 mutations. Thus, the discrepancy between the positive immunohistochemical expression in the adrenal cortex and in the adrenocortical tumors and the negative mutation remains unclear. We speculate that there may be a posttranscriptional modification of the RNA or a conformational alteration of the protein.

Because adrenocortical carcinomas carry a poor prognosis and postoperative treatment options thus far remain limited, new treatment targets are needed. Mutated IDH offers a distinct target for specific, individualized therapies. Small-molecule inhibitors of mutated IDH and peptide vaccines are being investigated for treating IDH-mutated neoplasms [17, 18]. Binding of the IDH1 R132H antibody to a proportion of adrenocortical tumors indicates that the new IDH-targeted therapies could benefit this subset of tumor patients.

A major advantage to our study is the large cohort size and the comprehensive follow-up data available for all patients. The fact that IDH1 R132H immunohistochemical stainings revealed a significant difference in survival between immunopositive and immunonegative malignant tumors indicates that the antibody detects an epitope with clinical relevance.

The survival difference could be associated with the natural disease progression or the treatment response of different tumor subtypes. One weakness of our study stems from our inability to identify the epitope that the IDH1 R132H antibody binds to in adrenocortical tumors.

In conclusion, among adrenocortical carcinomas, IDH1 R132H immunopositivity correlated with a better prognosis. Thus, IDH1 R132H staining could serve as a prognostic or as a predictive marker in adrenocortical carcinomas, discerning a subset of tumors with a particular pathogenic pathway. Further research is needed to uncover the possible alterations in IDH1 that explain our findings, because we failed to find mutations to the *IDH1* gene.

Acknowledgments

We thank Eija Heiliö and Päivi Peltomäki for their technical support.

Financial Support: This work was supported by the Finnish Cancer Foundation (to M.P., C.H., and J.A.), the Liv & Hälsa Foundation, the Helsinki University Hospital Research Fund (to C.H. and J.A.), the Sigrid Jusélius Foundation (to C.H.), and Biocenter Finland (to P.E.).

Additional Information

Correspondence: Mirkka Pennanen, MD, Department of Pathology, Haartman Institute, PO Box 21, 00014 University of Helsinki, Finland. E-mail: mirkka.pennanen@helsinki.fi.

Disclosure Summary: The authors have nothing to disclose.

References and Notes

1. Parsons DW, Jones S, Zhang X, et al. An integrated genomic analysis of human glioblastoma multiforme. *Science*. 2008;**321**(5897):1807–1812.
2. Mardis ER, Ding L, Dooling DJ, et al. Recurring mutations found by sequencing an acute myeloid leukemia genome. *N Engl J Med*. 2009;**361**(11):1058–1066.
3. Borger DR, Tanabe KK, Fan KC, et al. Frequent mutation of isocitrate dehydrogenase (IDH)1 and IDH2 in cholangiocarcinoma identified through broad-based tumor genotyping. *Oncologist*. 2012;**17**(1):72–79.
4. Amary MF, Bacsi K, Maggiani F, et al. IDH1 and IDH2 mutations are frequent events in central chondrosarcoma and central and periosteal chondromas but not in other mesenchymal tumours. *J Pathol*. 2011;**224**(3):334–343.
5. Murugan AK, Bojdani E, Xing M. Identification and functional characterization of isocitrate dehydrogenase 1 (IDH1) mutations in thyroid cancer. *Biochem Biophys Res Commun*. 2010;**393**(3):555–559.
6. Chowdhury R, Yeoh KK, Tian YM, et al. The oncometabolite 2-hydroxyglutarate inhibits histone lysine demethylases. *EMBO Rep*. 2011;**12**(5):463–469.
7. Koivunen P, Lee S, Duncan CG, et al. Transformation by the (R)-enantiomer of 2-hydroxyglutarate linked to EGLN activation. *Nature*. 2012;**483**(7390):484–488.
8. Hartmann C, Meyer J, Balss J, et al. Type and frequency of IDH1 and IDH2 mutations are related to astrocytic and oligodendroglial differentiation and age: a study of 1,010 diffuse gliomas. *Acta Neuropathol*. 2009;**118**(4):469–474.
9. Capper D, Zentgraf H, Balss J, Hartmann C, von Deimling A. Monoclonal antibody specific for IDH1 R132H mutation. *Acta Neuropathol*. 2009;**118**(5):599–601.
10. Weiss LM. Comparative histologic study of 43 metastasizing and nonmetastasizing adrenocortical tumors. *Am J Surg Pathol*. 1984;**8**(3):163–169.
11. Weiss LM, Medeiros LJ, Vickery AL Jr. Pathologic features of prognostic significance in adrenocortical carcinoma. *Am J Surg Pathol*. 1989;**13**(3):202–206.
12. Pennanen M, Heiskanen I, Sane T, et al. Helsinki score—a novel model for prediction of metastases in adrenocortical carcinomas. *Hum Pathol*. 2015;**46**(3):404–410.
13. RRID:AB_2335716. https://scicrunch.org/resolver/AB_2335716. Accessed January 24, 2020.
14. Sulonen AM, Ellonen P, Almusa H, et al. Comparison of solution-based exome capture methods for next generation sequencing. *Genome Biol*. 2011;**12**(9):R94.

15. Robinson JT, Thorvaldsdóttir H, Winckler W, et al. Integrative genomics viewer. *Nat Biotechnol.* 2011;**29**(1):24–26.
16. Pennanen M. Data from: IDH1 exon sequencing. Sequence Read Archive 2020. Accession number: PRJNA603119. <https://www.ncbi.nlm.nih.gov/sra/PRJNA603119>. Accessed January 25, 2020.
17. Friedrich M, Bunse L, Wick W, Platten M. Perspectives of immunotherapy in isocitrate dehydrogenase-mutant gliomas. *Curr Opin Oncol.* 2018;**30**(6):368–374.
18. Golub D, Iyengar N, Dogra S, et al. Mutant isocitrate dehydrogenase inhibitors as targeted cancer therapeutics. *Front Oncol.* 2019;**9**:417.